
Atlas of Animal Anatomy and Histology

Péter Lőw • Kinga Molnár • György Kriska

Atlas of Animal Anatomy and Histology

 Springer

Péter Lőw
Department of Anatomy,
Cell and Developmental Biology
Institute of Biology
Eötvös Loránd University
Budapest
Hungary

Kinga Molnár
Department of Anatomy,
Cell and Developmental Biology
Institute of Biology
Eötvös Loránd University
Budapest
Hungary

György Kriska
Group for Methodology in Biology Teaching
Institute of Biology
Eötvös Loránd University
Budapest
Hungary

Danube Research Institute
Centre for Ecological Research
Hungarian Academy of Sciences
Budapest
Hungary

General professional reviewer

Zsolt Kovács
Department of Zoology
Faculty of Sciences and Technology
University of West Hungary
Szombathely
Hungary

Additional material to this book can be downloaded from <http://extras.springer.com>

ISBN 978-3-319-25170-7 ISBN 978-3-319-25172-1 (eBook)
DOI 10.1007/978-3-319-25172-1

Library of Congress Control Number: 2016931371

Springer Cham Heidelberg New York Dordrecht London
© Springer International Publishing Switzerland 2016

This work is subject to copyright. All rights are reserved by the Publisher, whether the whole or part of the material is concerned, specifically the rights of translation, reprinting, reuse of illustrations, recitation, broadcasting, reproduction on microfilms or in any other physical way, and transmission or information storage and retrieval, electronic adaptation, computer software, or by similar or dissimilar methodology now known or hereafter developed.

The use of general descriptive names, registered names, trademarks, service marks, etc. in this publication does not imply, even in the absence of a specific statement, that such names are exempt from the relevant protective laws and regulations and therefore free for general use.

The publisher, the authors and the editors are safe to assume that the advice and information in this book are believed to be true and accurate at the date of publication. Neither the publisher nor the authors or the editors give a warranty, express or implied, with respect to the material contained herein or for any errors or omissions that may have been made.

Printed on acid-free paper

Springer International Publishing AG Switzerland is part of Springer Science+Business Media (www.springer.com)

Preface

The purpose of this book is to provide an introduction to comparative anatomy and histology for biology undergraduates and for all those who are interested in the internal structure of animals. The information is presented in the form of colour photographs of step-by-step dissection stages integrated with histological sections of actual organs. A specialty of this atlas is that it contains only high-quality, accurate, and attractive photographs, not idealised line drawings. Dissection plays an important part in understanding the anatomy of an animal, and this book has been designed to make full use of the wealth of information made available through dissection. The accompanying text aims to outline the evolutionary and functional aspects of the anatomy revealed in the photographs. Our book encourages and facilitates active and self-directed learning by the students so that instructors can teach more effectively and efficiently. This manual emphasises dissection procedures that preserve as many structures as possible for later review of the entire specimens. Every effort has been made to give clear, lucid descriptions and instructions, and enough background material has been included to create interest in and understanding of the subject matter.

The animals dissected in this book have been chosen as representative examples of six invertebrate phyla and four classes of vertebrates. This book offers step-by-step illustrations and instructions for dissecting a roundworm, earthworm, snail, mussel, crayfish, cockroach, crucian, frog, chicken, and rat. The types included are commonly studied in undergraduate zoology courses. They can be used also as a guide to dissection of other animals in the same group. Dissections range from beginning to advanced and discuss the digestive, circulatory, respiratory, excretory, reproductive, and nervous systems. Skeletal material of vertebrate animals is also included to show the supporting framework of the body and its development during evolution.

Another valuable aspect of this atlas is that it features large-size, full-colour histological micrographs, with labels and legends that draw attention to details of microanatomy of the most important organs. The histological descriptions follow the anatomical pictures and explanation of an actual organ, and they are highlighted with a coloured background. In this way, students can correlate microscopic structures with the gross composition. Clear histological explanations give details of how tissues are structured and how they work. Students will learn to recognise different types of tissues easily. The detailed photographs enable the reader to gather microanatomical knowledge even in the lack of prepared light microscopic sections or microscopic facilities.

The digital annex of the book includes slide-shows and interactive tests that can be used to check the knowledge. A special item of the software is a stereoscopic (3D) application enabling to visualize three-dimensional (anaglyph) pictures on a monitor or by a projector. Anaglyph pictures should be viewed through red-cyan glasses. The slide-shows are also available on-line at <http://bszm.elte.hu/anatomy/>, optimized for mobile browsers.

Budapest, Hungary

Péter Lőw
Kinga Molnár
György Kriska

Points for Successful Dissection

It is always important to perform a dissection in an appropriate lab under the guidance of an experienced instructor. Do not do anything uncertainly; wait for specific instructions in the lab. Dissection is both a skill and an art. A good dissection requires time and patience. Always prepare for a dissection in advance, learn the structures you want to find, and work deliberately. Make small cuts and do not remove a piece of tissue unless you know what it is. Each dissection chapter in this book includes background information about the sample animal, availability and proper, species-specific anaesthesia of the animal.

The dissections should be performed in a wax-bottomed dish using small pins for attachment and display. Most of the structures described in this dissection guide will be best viewed with the aid of a stereomicroscope (dissecting microscope) or a hand lens. Dissecting tools will be used to open the body of the animal and unfold the structures. Learn the techniques of working with these instruments. The tools are very sharp, use them properly and be careful not to injure yourself. The development of good abilities at dissection depends upon practice and, above all, patience. A comprehensive dissecting kit (Fig. 1) includes the following tools for almost all types of knacks:

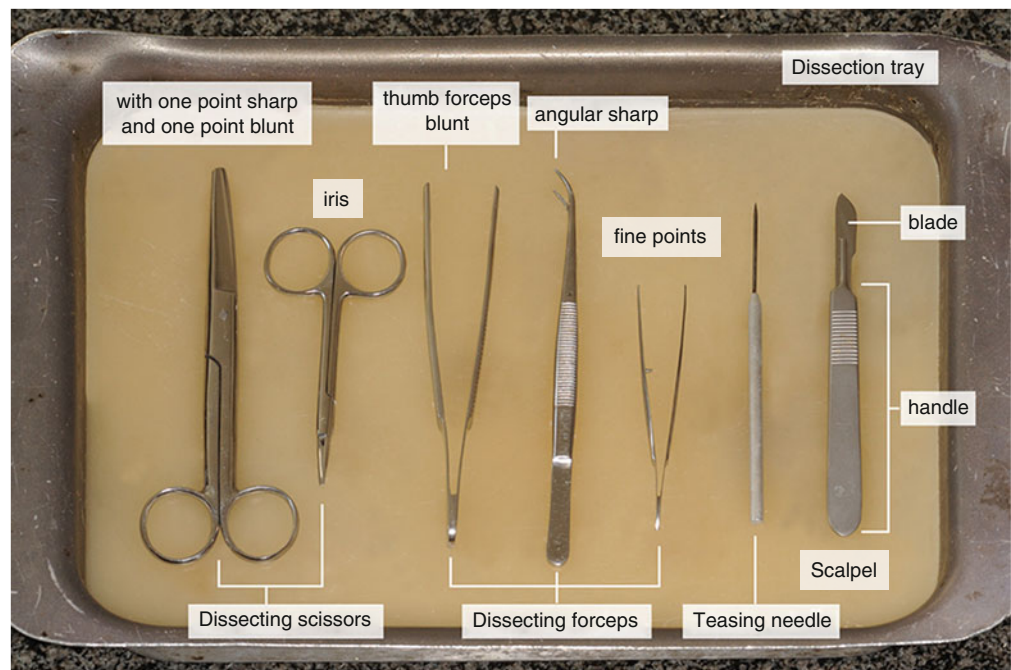


Fig. 1 A comprehensive dissecting kit arranged in a wax-bottomed dissecting dish

Dissecting scissors with one point sharp and one point blunt, 5.5 in.

Dissecting scissors, iris, 4.5 in.

Thumb forceps blunt, 5.5 in.

Forceps angular sharp, 5 in.

Forceps fine points, 4.5 in.
 Teasing needle straight with metal chuck
 Scalpel handle No. 4
 Scalpel blade No. 22

Although these instruments serve the requirements of nearly all kinds of dissecting situations for special tasks and fine, elaborate work, we recommend some further tools (Fig. 2):

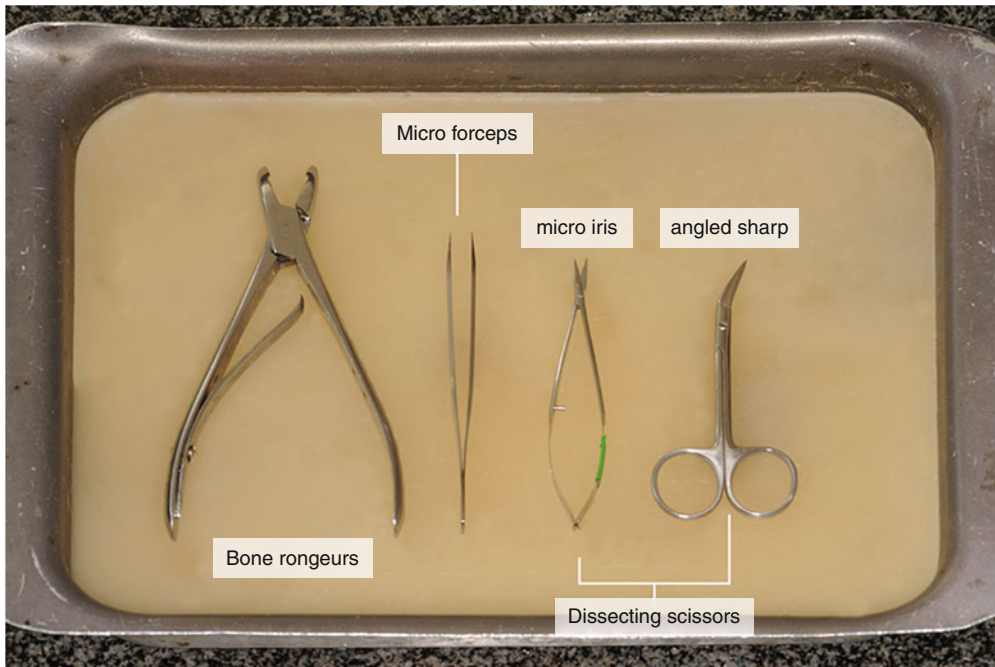


Fig. 2 Special dissection instruments for meticulous tasks

Bone rongeurs (Adson, Blumenthal, or Friedman type), 6 in.
 Micro forceps
 Dissecting scissors, micro iris (McPherson-Vannas), straight, sharp, 4.5 in.
 Dissecting scissors, angled sharp, 4.5 in.

Finally, it is well worth to use dissecting pins (insect pins) to position parts as you proceed with your examination of the specimen, so that you have a clearer view of the structure and organisation of the organism.

Keep in mind that dissecting does not mean “to cut up”; in fact, it means “to expose to view”. Careful dissecting techniques will be needed to observe all the structures and their connections to other structures. You will not need to use a scalpel very often. On the contrary to popular belief, a scalpel is not the best tool for dissection. Scissors are better because the point of the scissors can be pointed upwards to prevent damaging organs underneath. Always raise structures to be cut with your forceps before cutting, so that you can see exactly what is underneath and where the incision should be made. Never cut more than is absolutely necessary to expose a part. Sometimes the so-called blunt dissection is the most appropriate when you only tear connective tissue structures with forceps to reveal an underlying compact organ and do not cut anything.

When completed, clean up your dissection. Dispose of your materials according to the directions from your instructor. Pour your excess liquid into the sink and wrap the body parts in a paper towel before throwing them in the carcass container. Never dispose the body parts into ordinary communal waste. Immediately after use, rinse instruments under warm or cool running water to remove all blood, body fluids, and tissue. Dried soils may damage the instrument surface and make cleaning very difficult. Do not use hot water as this will coagulate proteinous substances. Clean up your work area and wash your hands before leaving the lab.

Histological Methods

Histological Sections

Histology is the study of the microscopic anatomy of cells and tissues of animals (or plants). During the routine procedure, the organs are fixed to prevent decay and embedded in paraffin (paraplast) to give support for cutting very thin (2–5 μm thick) sections. The sections are placed onto microscope slides and stained with histological stains, then covered with a coverslip and mounting medium for preservation. Histological slides are examined with light microscope.

Histological Stains

Histological stains are used to increase the typically minor differences in light refraction of biological samples. The procedure is based on the variances in binding of histological stains by tissue and cell components.

HE (haematoxylin – eosin) **stain:** It provides a general overview – haematoxylin stains the nucleic acids, and eosin stains the cytosol and the extracellular matrix.

Azan (azocarmine – aniline blue) **stain:** It provides a general overview – azocarmine stains the cell nucleus and the cytoplasm, aniline blue stains the connective tissue matrix and fibres and some mucous secret.

PAS (Periodic acid-Schiff reaction) **stain:** This reaction is used to detect structures containing a high proportion of carbohydrate macromolecules (glycoproteins, glycolipids, and polysaccharides). The reaction gives a purple-magenta colour typically in mucus gland cells, connective tissue, and basement membrane.

Semithin Sections

Plastic (epoxy resin) embedding is commonly used in the preparation of material for electron microscopy. Semithin sections (0.8–1 μm) are cut using glass knives. The sections are stained with toluidine blue and examined using a light microscope.

Important Technical Terms

Here we explain compass points of anatomy. Many of these are taken from Latin or Greek languages, and each has a very specific meaning. It is really important to understand the basic terms, which are used throughout the anatomical and histological descriptions.

Frontal plane: It is a vertical plane at right angle to median plane. If you draw a line from one ear to another from above the head and then divide the whole body along this line, the plane formed will be frontal plane. It is also known as coronal plane.

Median or mid-sagittal plane: This is the plane which divides the body into equal right and left halves.

Oblique plane: Any plane other than the above described planes will be oblique plane.

Sagittal plane: It is any plane parallel to the median plane. This plane divides the body into unequal right and left halves.

Transverse plane: It is the horizontal plane of the body. It is perpendicular to both frontal and median planes.

Directional terms describe the positions of structures relative to other structures or locations in the body:

Anterior: Towards the head end (e.g. the oesophagus is located anterior to the stomach)

Caudal: Away from the head, towards the tail end of the body

Cranial: Towards the head end of the body

Distal: Away from or farthest from the middle line of an organism or from the point of attachment (e.g. the hand is located at the distal end of the forearm)

Dorsal: Towards the back or upper part of the animal

Inferior: Lower

Lateral: Situated at the side away from the midline of the body (e.g. the little toe is located at the lateral side of the foot)

Longitudinal: Lengthwise; along the length of the body

Medial: Towards the midline of the body (e.g. the middle toe is located at the medial side of the foot)

Median: Along the middle of the long axis

Periferal: Referring to parts away from the centre

Posterior: Facing towards the tail end (e.g. the pelvic girdle is located on the posterior end of the backbone)

Proximal: Towards or nearest to the middle line of the organism or the point of origin of a part (e.g. the proximal end of the femur joins with the pelvic girdle)

Sagittal: along or parallel with the middle plane of the body

Superficial: On or near the surface

Superior: Upper

Transverse: Lying across or between or at right angles to the longitudinal axis

Ventral: Towards the abdominal surface

Acknowledgements

The authors wish to thank the many people who helped in the preparation of this book. In particular, thanks are due to Dr. György Csikós, Viktor Kis, Sarolta Pálfia, and Zsolt Pálfia of the Department of Anatomy, Cell and Developmental Biology, Eötvös University, Budapest, Hungary for their prepared specimens. We are indebted not only to them but also to Dr. Zsolt Kovács (Department of Zoology, Faculty of Sciences and Technology, University of West Hungary, Szombathely, Hungary) who revised the manuscript. Any inaccuracies remaining are, of course, our own responsibility. We are grateful for the excellent technical assistance to Eszter Papp. We thank Monika Truszka for the first-rate histological work from embedding to outstanding sections and brilliant staining. We thank András Barta for creating the on-line version of the slide-shows. We would also like to thank the cheerful and hardworking production team at Springer Verlag whose encouragement sustained us on several occasions.

P. Lőw
K. Molnár
G. Kriska

Contents

Part I Invertebrates

1 Examination of a Hydra	3
2 Examination of a Planarian	7
3 Dissection of a Roundworm (<i>Ascaris suum</i>)	11
4 Dissection of the Earthworm (<i>Lumbricus terrestris</i>)	27
5 Dissection of a Snail (<i>Helix pomatia</i>)	49
6 Dissection of a Freshwater Mussel (<i>Anodonta anatina</i>)	79
7 Dissection of a Crayfish (<i>Astacus astacus</i>)	101
8 Dissection of a Cockroach (<i>Blaberus sp.</i>)	139

Part II Vertebrates

9 Dissection of the Crucian (<i>Carassius carassius</i>)	173
10 Dissection of a Frog (<i>Rana sp.</i>)	213
11 Dissection of a Chicken (<i>Gallus domesticus</i>)	265
12 Dissection of the Rat (<i>Rattus norvegicus</i>)	325
Bibliography	401
Index	403