

## Subject index

- Abscess, paravertebral 23  
  prevertebral 20 f.
- Adamkiewicz artery 204 f.
- Aminoglycans 68, 71
- Amyloidosis 39, 45
- Aneurysmal bone cyst 43, 48, 205
- Angiography, improvements in 191  
  in bone and soft tissue-tumors 204–210  
  in musculo-skeletal traumas 196–203  
  of the spinal cord 204  
  precautions in 192  
  puncture site 191 f.  
  technique of 191–195
- Angioplasty 193
- Angiosarcoma 45
- Anulus fibrosis 63, 69, 134  
  bulging of 69
- Apophyseal joints, see Facet joints
- Arteriography, see Angiography
- Arteriovenous fistula 201 f.
- Arteriovenous malformation, vertebral 215
- Arthritis 51
- Biopsy of bone, open 44**
- Biopsy of bone, percutaneous 3–50**  
  complications of 37 f.  
  contraindications of 48  
  distribution of biopsy sites 38 f.  
  equipment and instrumentation 4–16  
  general considerations 17  
  hand-drill 33  
  immediate preparation 16  
  indications of 45–48  
  needles  
    Ackerman needle 4–8, 18, 26, 33  
    aspiration needles 15 f.  
    Chiba needles 15  
    Craig needle 4–6, 9, 18, 33  
    Harlow-Wood needle 5 f., 9, 18  
    Jamshidi needle 5 f., 12, 18  
    Laredo-Bard needles 5 f., 10 f., 18, 28, 33  
    MacLarnon needles 5 f., 12, 18  
    Mazabraud needles 5–7, 28  
    sure-cut needles 14, 18, 28
- Tanzer needle 5 f., 13, 18  
  trephine needles 5–13  
  tru-cut needles 5, 14, 18
- results of 38–44  
  in bone metastases 40  
  in bone tuberculosis 43  
  in primary neoplasm of bone 41–43  
  in pyogenic infections 44
- specimen handling 36, 45
- technique of 4–37  
  for cervical spine 26–28  
  for flat bones 32 f.  
  for lumbar spine 4, 17–23  
  for peripheral bones 32 f.  
  for sacroiliac joint 4, 28–31  
  for sclerotic lesions 33 f.  
  for thoracic spine 4, 23–25, 27  
  under fluoroscopic guidance 4, 17–34  
  under computed tomography guidance 4, 34–36
- tumor spread in 38
- Biopsy of soft tissue, percutaneous 35**  
  needles 13–15
- Biopsy of synovium, percutaneous 51–64**  
  complications of 61 f.  
  indications of 63 f.  
  needles  
    Franklin-Silverman needle 63  
    Jamshidi needle 52, 55  
    Parker and Pearson needle 51, 62  
    Tanzer needle 52, 55, 57  
    tru-cut needles 52, 55–57  
    Watanabe forceps 52
- results of 62 f.
- specimen handling 59
- technique of 52–60  
  Aignan 52  
  arthrography in 54  
  computed tomography in 53 f.  
  for the ankle 56–58  
  for the elbow 56, 58, 60 f.  
  for the hip 52–56  
  for the knee 52  
  for the shoulder 56–59
- for the wrist 56, 59
- Bone, biopsy, see Biopsy**
- cyst, see Single bone cyst
- infection 44 f., 48
- metastases of 28, 34, 38, 40 f., 45, 48, 205, 208  
  embolization of 205  
  of kidney cancer 48, 205, 208  
  of thyroid cancer 48, 205
- primary malignant tumors of 39, 41 f., 45, 47, 205  
  intraarterial treatment of 218–233  
  tuberculosis of 42 f., 48
- Brucella 44**
- Chemonucleolysis, cervical 123–129**  
  (see also Chymopapain)  
  anesthesia in 125  
  approach of the needle in 125 f.  
  aprotinin injection in 123  
  chymopapain injection in 126 f.  
  computed tomography in 124  
  contraindications of 128  
  discography in 126  
  electromyography in 124  
  indications of 128  
  myelography in 124  
  post-operative care in 127  
  results of 127 f.  
  selection of patients in 123 f.  
  technique of 125
- Chemonucleolysis, lumbar 67–122**  
  (see also Chymopapain)  
  anaphylactic shock in 72, 77, 91–99  
  curative treatment 99  
  preventive treatment 95  
  anesthesia in 91–100  
  operative monitoring 95–97
- collagenase 86
- complications of 72 f. (see also anaphylactic shock)  
  death 73  
  discitis 73  
  lumbar spasm 73  
  spinal infection 73  
  urinary retention 72
- computed tomography in 75, 77–80, 84
- discography in 75, 81, 103 f., 114–120

- epidural leak in 81  
 failures of 78, 80, 85  
 hexatrione 86  
 immunologic assessment 94  
   Prick-test in 94  
 indications of 73 f.  
   in low back pain 76 f.  
 instrumentation for 101–104  
   needles 101–103  
 magnetic resonance imaging in  
   71, 75, 85  
 myelography in 75, 78, 80, 101  
 post-operative monitoring in 97  
 radiological changes following  
   84 f.  
 results of 83–85  
 selection of patients in 74 f.  
 technique of 101–122  
   chymopapain injection 120 f.  
   for L4–5 interspace  
     106–113  
   for L5–S1 interspace  
     113–120  
   needle approach 104 f.  
   positioning of the patient  
     105  
   triamcinolone 86  
 Chemotherapy, intraarterial 193,  
   218–233  
 Chondroitin sulfate 68 f., 71  
 Chondrosarcoma 38, 43  
 Chordoma 38  
 Chymopapain 67, 69, 71 f., 76 f.,  
   102 f., 123–129 (see also Chemo-  
   nucleolysis)  
   anaphylactic shock to 72, 77, 91–  
   99  
   epidural leak of 71, 81  
   intradural injection of 72, 101  
   technique of injection for lumbar  
   chemonucleolysis 122  
 Collagenase 86  
 Degenerative disc disease 39, 45  
 Disc, see Intervertebral disc  
 Discectomy, see Percutaneous discec-  
   tomy  
 Embolization, intraarterial  
   accidents of 194 f.  
   antalgic 209 f.  
   chemotherapeutic 193  
   hemostatic 196, 204  
   in bone and soft tissue tumors  
     204–210, 218–222  
   in giant cell tumors 218–222  
   in hemorrhage of the lower limb  
     200–202  
   in internal hemorrhage 196–202  
   in musculo-skeletal traumas  
     196–203  
   in pelvic traumas 197 f.  
   in postoperative arteriovenous  
   fistulae 202 f.  
   in postoperative hemorrhage 202  
   in vascular injuries 196–203  
   material of 193  
   preoperative 205 f.  
   to reduce tumoral mass 205, 209  
 Endometriosis 35  
 Eosinophilic granuloma of bone  
   management of 244 f.  
   percutaneous biopsy of 48, 247  
   steroid injection in 237, 244–249  
   indications of 245  
   radiographic outcome after  
     245–248  
   results of 245–248  
   technique of 245  
 Epidural fibrosis 67  
 Escherichia coli 43 f.  
 Ewing tumor 41, 47  
 Facet joint, anatomy 157 f.  
   arthrography of 153–173, 178 f.  
   indications of 167–173  
   normal appearance of 167  
   technique of 159–167  
   degeneration of 76 f., 157–159  
   percutaneous radio frequency  
   denervation of, see Rhizo-  
   lysis  
   synovial cysts of 157, 159, 169–  
   172  
 Facet syndrome 167, 175  
 Fibrosarcoma 43  
 Fibrous dysplasia 44, 48  
 Giant cell tumors of bone 43, 48, 218–  
   223  
   angiographic appearance of 218–  
   222  
   embolization in 218–222  
   intraarterial treatment of 218–  
   223  
 Hemangiomas, see Vertebral heman-  
   giomas  
 Hemophilus influenzae 44  
 Hepatoma, bone metastases 40  
 Herniated disc, see Intervertebral disc  
 Hexatrione 86  
 Histiocytosis X 244  
 Hodgkin's disease 32  
 Humerus, osteomyelitis of 32  
 Hyaluronic acid 68  
 Infection, see Bone, infection, and  
   Spine, infection  
 Intervertebral disc, see also Chemo-  
   nucleolysis and Percutaneous  
   discectomy  
   cervical, herniation of 123–129  
   lumbar, bulging of 76  
   lumbar, degeneration of 68  
   lumbar, dehydration of 68  
   lumbar, herniation of 69–71, 74,  
   77 f., 81 f., 133–154  
   calcified 82  
   extruded 69 f., 81  
   large 81  
   migration of 69 f., 81  
   sequestered, sequestrated  
     69 f., 78, 80 f., 135  
   lumbar, narrowing of 71, 77  
   lumbar, protrusion of 68  
 Keratan sulfate 68 f., 71  
 Klebsellia pneumoniae 44  
 Lateral recess spinal stenosis 74, 78 f.  
 Ligament, longitudinal, posterior, of  
   vertebral column 69, 77, 81  
 Low back pain, chemonucleolysis in  
   76 f.  
 Lymphoma of bone 41, 45, 47  
 Metastases, see Bone, metastases,  
   and Spine, metastases  
 Myeloma 36, 39, 41, 45, 47  
 Needles, see specific techniques  
 Nerve root, compression 67, 74, 79  
   deficit 72  
 Nucleotome 144–147  
 Nucleotomy, see Percutaneous lum-  
   bar discectomy  
 Nucleus pulposus 67–69, 71, 134  
 Osteblastoma 43, 205  
 Osteomyelitis 32, 39, 45, 48  
 Osteoporosis 39, 45  
 Osteosarcoma 43, 205 f.  
   angiographic appearance of  
     222–230  
   intraarterial treatment of 222–  
   230  
   management of 224  
 Paget disease 44, 48  
 Percutaneous biopsy, see Biopsy  
 Percutaneous lumbar discectomy  
   133–139, 140–148, 149–154  
   and decompression 133–139  
   complications of 139  
   operative technique of 135–  
   139  
   results of 139  
   selection of patients 134 f.  
   automated 140–148  
   complications of 146 f.  
   computed tomography in  
     141, 143  
   discography in 142  
   operative technique of 142–  
   145  
   results of 145 f.  
   selection of patients 141 f.  
   lateral 149–154  
   complications of 153 f.  
   operative technique of 149  
   results of 150  
 Pheochromocytoma 205  
 Piriformis muscle, endometriosis of  
   35  
 Plasmocytoma, solitary 39, 41, 45,  
   205

- Prevertebral abscess, opacification of 22
- Primary malignant tumors 39, 41 f., 45, 47, 205
- Proteoglycans 68 f., 71
- Pseudomonas aeruginosa 46
- Psoriatic arthritis 48
- Pyogenic infection of bone 44
- Radiotherapy** 45
- Reiter's syndrome 48
- Rhabdomyosarcoma 207
- Rhizolysis, lumbar 175-188  
 anesthesia in 180  
 complications of 185  
 computed tomography in 178 f.  
 discography in 178 f.  
 discomanometry in 179  
 electromyography in 179  
 facet joint arthrography in 178 f.  
 instrumentation for 180  
 operative procedure 180-183  
 postoperative care 183  
 results of 183-185  
 selection of patients 177
- Rib, biopsy 33  
 metastasis 32
- Sacroiliac joint**  
 arthrography 31  
 biopsy 28, 31
- Sciatic pain 71
- Sclerotic bone lesions, biopsy 33
- Sequestered disc fragments, see Intervertebral disc
- Single bone cyst, steroid injections in 237-243  
 complications of 242  
 prognostic factors of 240 f.  
 radiographic outcome after 240 f.  
 recurrence after 237, 241
- Spinal stenosis, lumbar 74, 78, 135  
 of the central canal 74, 78 f.  
 of the lateral recess 74, 78 f.
- Spine, see also Biopsy**  
 amyloidosis of 39, 45  
 angiosarcoma 45  
 infection 20, 28, 37, 43, 45, 72 f.  
 post-chemonucleolysis 73  
 lymphoma 41, 45  
 metastasis 12, 39, 45  
 embolization of 205, 208 f.  
 myeloma 36, 39, 45  
 osteoporosis 39, 45  
 plasmocytoma, solitary, of 39, 45  
 primary malignant tumors of 39, 45  
 tuberculosis 22, 24, 26, 39, 45
- Staphylococcus** 73  
 albus 44  
 aureus 44
- Steroid injections**  
 in cervical foramina 253-257  
 in eosinophilic granulomas of bone 244-249  
 in facet joint 157-174  
 in single bone cysts 237-243  
 into calcific deposits of the rotator cuff 266
- Streptococcus** 44
- Synovium, percutaneous biopsy of, see Biopsy of synovium
- Triamcinolone** 86
- Trocar 5-13
- Tuberculosis, see Bone, tuberculosis, and Spine, tuberculosis
- Vertebral collapse** 48
- Vertebral hemangiomas** 211-217  
 asymptomatic 211 f.  
 compressive 213-217  
 computed tomography in 212, 214, 216  
 embolization of 213-215, 217  
 management of 216 f.  
 radiotherapy in 213 f.  
 selective arteriography in 211-217  
 symptomatic 212, 216 f.
- Watanabe forceps** 52
-

G. B. J. Andersson/T. W. McNeill

# Lumbar Spine Syndromes

## Evaluation and Treatment

1988. 108 figures. Approx. 250 pages.  
ISBN 3-211-82070-1

*To be published in Fall 1988*

Introduction

Investigations

Treatment Modalities

The Patient with Acute Low Back Pain

The Patient with Recurrent Low Back Pain

The Patient with Pain Radiating down the Leg (Sciatica?)

The Patient with Severe, Unremitting Low Back Pain

The Patient with Bilateral Sciatica who is Unable to Void

The Patient with Bilateral Leg Pain when Walking

The Patient with Chronic, Moderate Low Back Pain

The Patient with Spine Deformity and Low Back Pain

The Child with Back Pain

The Patient with Functional Back Pain/Malingering

The Patient with a Spine Tumor

The Patient with a Spine Infection

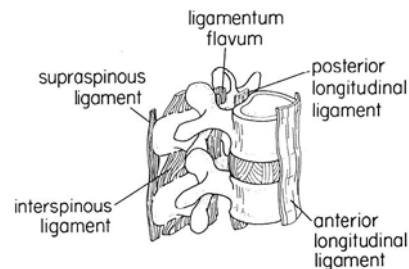
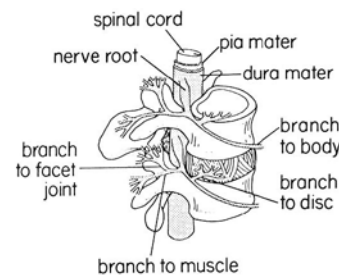
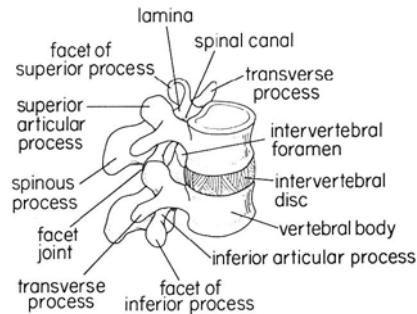
The Patient with Inflammatory Diseases of the Spine

The Patient with a Metabolic Spine Condition

Glossary

References

The title expresses most succinctly the subject of this book. No previous publication has attempted to present the differential diagnosis of low back pain, starting with the clinical presentation of the patient to the physician and carrying the discussion through to the conclusion of care in the correct sequential manner. The discussion of each of the syndromes center upon a decision analysis format which is also a new approach to this difficult subject. Readers will be able to develop the matrix for coherent thought and ease of future recall. Their patient care should then follow easily.



**Springer-Verlag Wien New York**

Moelkerbastei 5, A-1010 Wien · Heidelberger Platz 3, D-1000 Berlin 33

175 Fifth Avenue, New York, NY 10010, USA · 37-3, Hongo 3-chome, Bunkyo-ku, Tokyo 113, Japan



# Vascular Anatomy of the Spinal Cord

## Neuroradiological Investigations and Clinical Syndromes

By **Armin K. Thron**  
with collaboration of Ch. Rossberg  
and A. Mironov

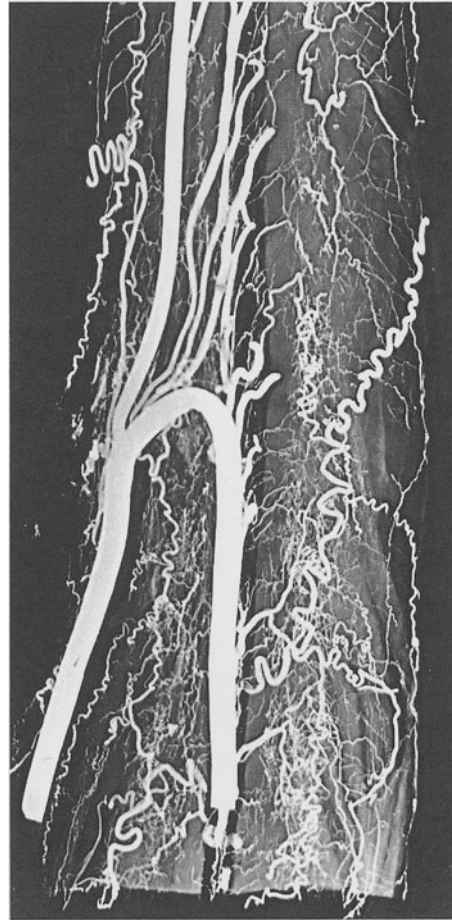
1988. 74 partly colored figures. VII, 114 pages.  
Cloth DM 98,-, öS 690,-  
ISBN 3-211-82015-9

*Prices are subject to change without notice*

The book summarizes the anatomic guidelines of external blood supply to the spinal cord. The basic principles of arterial supply and venous drainage are illustrated by explicit schemes for quick orientation.

In the first part of the book, systematic radiologic-anatomic investigations of the superficial and deep vessels of all segments of the spinal cord are introduced. The microvascular morphology is portrayed by numerous microradiographic sections in all three dimensions without overshadowing. The excellent three-dimensional representation of the vascular architecture illustrates elementary outlines and details of arterial territories, anastomotic cross-linking as well as the capillary system, particularly the hitherto unknown structure of the medullary venous system with its functionally important anastomoses and varying regional structures. These often new radiologic-anatomic findings are discussed as to their functional and pathophysiologic impact and constitute the basis on which to improve our modest understanding of vascular syndromes of the spinal cord. The neurosurgeon as well as the neuroradiologist familiar with endovascular techniques are offered information on microvascular morphology necessary for interventions at the spinal cord.

The second part of the book focuses on clinical syndromes and illustrates the present diagnostic contribution of spinal angiography with special reference to the diagnosis of spinal vascular anomalies and arteriovenous malformations. Though widely underrated in the past, the pathogenic role of the spinal venous system in direct or indirect circulatory disorders of the spinal cord is emphasized. The book fills an obvious void both from a pathologic-anatomic and a clinical point of view, and should therefore attract every physician remotely interested in neurology.



**Springer-Verlag Wien New York**

Moelkerbastei 5, A-1010 Wien · Heidelberger Platz 3, D-1000 Berlin 33  
175 Fifth Avenue, New York, NY 10010, USA · 37-3, Hongo 3-chome, Bunkyo-ku, Tokyo 113, Japan