

Extenuating the role of *Ficus virens* Ait and its novel bioactive compound on antioxidant defense system and oxidative damage in cigarette smoke exposed rats

Danish Iqbal^{1,2}, M. Salman Khan^{1*}, Amir Khan³, Saheem Ahmad¹

¹Clinical Biochemistry and Natural Product Research Laboratory, Department of Biosciences, Integral University Lucknow-226026, India

²Department of Medical Laboratory Sciences, College of Applied medical Sciences, Majmaah University, Al-majma'ah-11952, Saudi Arabia

³Department of Maxillofacial Surgery (Biochemistry), College of Dentistry, Taif University, KSA

*Corresponding author: mskhan@iul.ac.in

Received: 21 June 2016 / Accepted: 13 July 2016 / Published online: 26 July 2016

©The Author(s) 2016. This article is published with open access by BioMedPress (BMP)

Abstract— Introduction: Production of free radicals is associated with cigarette smoke (CS) which in turn generates oxidative stress, could be responsible for alterations in the activities of enzymatic and non-enzymatic antioxidants that links with atherosclerosis. **Methods:** Therefore, the putative preventive effects of *F. virens* extract and its bioactive compound (F18), n-Octadecanyl-O- α -D-glucopyranosyl(6'→1'')-O- α -D-glucopyranoside were investigated on overall enzyme and non-enzymatic defense system and in oxidative stress CS-exposed rats. **Results:** The enzymatic activities of hepatic and lung CAT, SOD, Gred and GST in CS exposed rats were significantly decreased, while Gpx activity in CS exposed rats was increased. Similarly, hepatic and lung GSH content was reduced when compared to value of normal control group. Simultaneous administration of FVBM extract (50 and 100 mg/rat) and F18 bioactive compound (1 mg/rat) significantly increases hepatic and lung CAT, SOD, Gred and GST activity as well GSH concentration coupled with decrease in Gpx level in CS-exposed stress rats. Moreover, our histological observations concludes the pulmonary congestion, thickening of interalveolar septa and foci of collapsed alveoli with subsequent dilation of the adjoining alveolar spaces as well as development of large irregular spaces in rats lung exposed to cigarette smoke. Similarly, the liver also showed morphological alterations with congestion in central vein, portal inflammation and necrosis in CS-exposed rats. These morphological changes reversed significantly after treatment with FVBM extract and F18 compound. **Conclusion:** Thus biochemical and histopathological studies suggested that, FVBM extract and F18 showed its protective nature against CS-exposed rats.

Keywords: Cigarette smoke, Oxidative stress, Antioxidant defense system, Histopathology, *Ficus virens*

INTRODUCTION

Oxidative stress is one of the major symptoms accompanying physiological functions and many pathological conditions such as cancer, diabetes, chronic obstructive pulmonary disease, cardiovascular and neurodegenerative diseases and also in the aging process itself (Aruoma, 1998; Santilli et al., 2015; Sen et al., 2010). Cigarette smoking (CS) contributes a considerable amount of free radicals, estimated as 10^{14} and 10^{15} free radicals/puff in the tar and gas phases (Church and Pryor, 1985) and is the major risk factor

as well as leading cause cardiovascular disease (CVD) (Messner and Bernhard, 2014; WHO, 2015).

Moreover, CS generate free radicals that could be responsible for alterations in the activities of enzymatic viz., superoxide dismutase (SOD), catalase (CAT), glutathione peroxidase (Gpx), glutathione reductase (Gred), glutathione-s-transferase (GST) and non-enzymatic, namely GSH, antioxidants (Ramesh et al., 2007; Ramesh et al., 2015; Thirumalai et al., 2011).

Various studies suggested that medicinal plants are source for the prevention of numerous oxidative stress related diseases (Akhter et al., 2013; Alvi et al., 2015; Khan et al., 2013; Salvamani et al., 2014). Thus, natural compounds with antioxidant properties could contribute to the protection of cell and tissue against deleterious effects caused by CS generated reactive oxygen species (ROS). *Ficus* species exhibits strong antioxidant and biological properties, known to diffuse the toxic free radical and can be used as a possible protective agent for treatment of oxidative stress related disorders (Iqbal et al., 2014a; Sirisha et al., 2010; T S et al., 2013). We have previously shown that *Ficus virens* bark methanolic (FVBM) extract contained large amount of antioxidant with significant hypolipidemic property (Iqbal et al., 2014b; Iqbal et al., 2015). The current investigation demonstrates the protective role of FVBM extract and its principal bioactive compound, n-Octadecanyl-O- α -D-glucopyranosyl(6'→1'')-O- α -D-glucopyranoside in cigarette smoke-induced oxidative stress.

MATERIALS AND METHODS

Chemical Reagents

Bradford dye was purchased from Sigma Aldrich, India, potassium dichromate, hydrogen peroxide (H₂O₂), glacial acetic acid was procured from Merck Pvt Ltd, India; capston cigarette from Capston, India Ltd. All other chemicals were procured either from Himedia Laboratories, Mumbai, India or of analytical grade.

Isolation of Bioactive compound

Bioactive compound; n-Octadecanyl-O- α -D-glucopyranosyl (6→1'')-O- α -D-glucopyranoside (F18) from FVBM extract was isolated by following the protocol (Iqbal et al., 2015).

Animals

Male Sprague-Dawley (SD) rats weighed around 100-150 gm were procured from Indian Institute of Toxicology Research Center, Lucknow. The proposed study was approved by Institutional Animal Ethics Committee (IAEC) (registration number: IU/Biotech/project/CPCSEA/13/11). The rats were housed 5 per cage for one week in the animal house for acclimatization at a temperature of 21-22°C with 12 hours light and dark cycle. The rats were given standard diet and water *ad libitum*.

Dose preparation

Sequentially extracted FVBM extract, its bioactive fraction (F18) and reference drug atorvastatin were dissolved in 10 % dimethyl sulfoxide (DMSO) at different concentrations and were homogenized with saline. The doses of the extracts were selected on the basis of previously published reports (Iqbal et al., 2015; T S et al., 2013).

Diet/exposure to cigarette smoke

FVBM extract, its bioactive fraction (F18) and atorvastatin suspension was administered through gastric intubation in two divided doses (morning and evening) of 0.5 ml each/rat/day. Rats in smoking control group received 0.5 ml of saline containing 10 % DMSO (vehicle) twice daily while rats in normal control group received 0.5 ml of saline containing 10 % DMSO twice daily. The rats were divided randomly and equally (5 rats in each group) in groups as illustrated in **Table 1**.

Table 1. Protocol for the treatment of cigarette smoke-induced oxidative stress in rats

Group	Treatment
N-C	Normal control
S-C	Cigarette smoking control + vehicle
FVT-1	Smoke-exposed + plant extract (FVBM) (50 mg/rat/day)
FVT-2	Smoke-exposed + plant extract (FVBM) (100 mg/ rat/day)
CT	Smoke-exposed + bioactive compound (F18) (1 mg/ rat/day)
AT	Smoke-exposed + standard (Atorvastatin) (1 mg/ rat/day)

Rats were exposed to cigarette smoke in the morning by keeping two rats in bottomless metallic container (10 x 11 x 16 inch), having two holes of 3 and 1.5 cm diameter, one on the either side. A burning cigarette was introduced through one hole (3 cm) and the other hole (1.5 cm) was used for ventilation. Animals were exposed to CS for 30 minutes, daily for 4 weeks with interval of 10 min between each 10 min exposure, using 3 cigarettes/day/2 rats in each group (Anbarasi et al., 2006).

Collection of different organs

Liver and lung were excised and kept in ice-cold saline. A portion of liver and lung were immediately fixed in 10 % neutral formalin for histopathological studies.

Preparation of homogenate and post mitochondrial supernatant

At the end of the experiment, liver and lung from the rats were promptly excised and chilled in ice-cold saline. After washing with saline, it was blotted and weighed. One gram of wet tissues was cut into pieces and homogenized with 9 ml of chilled 0.1 M sodium phosphate buffer, pH 7.4 (containing 1.17 % KCl) in a waring blender. The homogenate was centrifuged at 1,000 rpm for 10 min at 4°C, aliquoted and stored at -20°C. The remaining portion of the liver and lung homogenates was centrifuged at 12,000 rpm for 20 min at 4°C. The post mitochondrial supernatant (PMS) thus obtained was also aliquoted and stored at -20°C for future use.

Activities of antioxidant enzymes

The enzymatic activity of catalase in PMS of liver and lung was measured by adopting the procedure of Sinha (1972). Enzymatic activity of SOD in PMS fraction of liver and lung was determined by the method as described by Kakkar *et al.* (1984) based on the 50 % inhibition of the formation of nicotinamide adenine dinucleotide (NADH)-phenazine methosulphate-nitroblue tetrazolium formazan at 560 nm. Glutathione peroxidase activity in liver and lung homogenate was assayed by modifying of the previous protocols (Hafeman *et al.*, 1974; Mills, 1959). The enzymatic activity of Gred in liver and lung was determined according to the method of Carlberg and Mannervik (Eriksson *et al.*, 1975). Method of Habig *et al.* (1974) was used to measure the GST activity in PMS fraction of liver and lung.

Activity of non-enzymatic antioxidant

For the determination of GSH content in liver or lung homogenate, the previous methods were followed (Ellman, 1959; Sedlak and Lindsay, 1968).

Histopathological studies of liver and lung

For histopathological study, a portion of liver and lung were used. For microscopic preparation of the above tissues, method of Disbrey and Rach (1970) was used. Two formalin fixed samples from each tissue were embedded in paraffin and sectioned after block

preparation. The paraffin block was sectioned in 4-5 µm thickness by using a microtome to make a slide and then it was dyed with hematoxylin-eosin (H&E) and observed under a light microscope and photographs were taken (JA, 2001).

Protein estimation

The protein concentration of liver homogenate and PMS was analyzed by the method of Bradford (1976) using bovine serum albumin as standard. Aliquots of liver homogenates and PMS were first precipitated with 10 % TCA followed by centrifugation at 1500 rpm for 10 min. The protein pellets were dissolved in 0.5 N NaOH and used for protein determination.

Data analysis

For all assays, samples were analysed in triplicate and the results were expressed as mean ± SD. The results were evaluated using one-way analysis of variance (ANOVA) and two tailed Students T-test. Statistical significance were expressed as * $p < 0.05$, ** $p < 0.01$ and *** $p < 0.001$.

RESULTS

Regulatory effects of FVBM extract, F18 bioactive compound and atorvastatin on antioxidant defense system in smoke-exposed rats after 4 weeks of treatment

Free radicals released by cigarette smoke (CS) generate oxidative stress. This process could be responsible for alterations in the activities of enzymatic and non-enzymatic antioxidants and development of atherosclerosis. Since, protection against oxidative stress/ROS is provided by enzymatic and non-enzymatic antioxidants, therefore, the status of antioxidant enzymes, such as CAT, SOD, Gpx, GST and Gred including GSH concentrations in liver and lung of experimental smoke-exposed rats are important.

Impact on the regulation of hepatic and lung catalase, superoxide dismutase, glutathione peroxidase, glutathione reductase, glutathione-s-transferase activities and reduced glutathione content

The enzymatic activities of hepatic CAT, SOD, Gred and GST in S-C rats were significantly decreased from N-C values of 62.28, 7.65, 18.29 and 132.8 U/mg protein to 32.45, 4.8, 11.28 and 68.12 U/mg protein,

respectively, while Gpx activity in S-C rats was increased from N-C values of 44.2 to 57.28 U/mg protein (Fig. 1). The restoration in above enzymatic activities of hepatic CAT, SOD, Gred and GST in FVT-2 treated rat was 24, 32, 48 and 36 % of respective normal control values. The values of these enzymes in C-T group, in comparison to S-C values, were significantly increased by 35, 53, 60 and 43 % respectively. In contrast the hepatic Gpx activity was

significantly decreased by 14, 18, 20 and 10 % in FVT-1, FVT-2, C-T and A-T rats. As depicted in fig. 3, the hepatic GSH content were reduced by 43 % when compared to value of N-C group. Administration of FVBM extract, F18 bioactive compound and atorvastatin to CS-exposed rats resulted in a significant increase in GSH content by 22, 32, 45 and 18 % respectively.

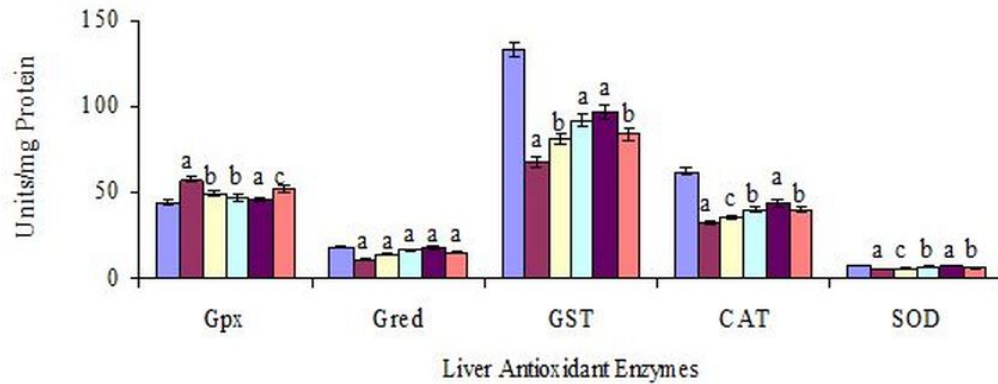


Figure 1. Impact of FVBM extract, F18 bioactive compound and atorvastatin on Liver CAT, SOD, Gpx, Gred and GST activities in cigarette smoke-exposed rats after 4 weeks of treatment. One unit (U/ mg protein) of Gpx activity is defined as nmole oxidized glutathione formed/min/mg homogenate protein. One unit (U/ mg protein) of Gred activity is defined as nmole NADPH oxidized/min/mg PMS protein. One unit (U/ mg protein) of GST activity is defined as the nmole of 1-chloro 2,4-dinitrobenzene (CDNB) conjugate formed/min/mg PMS protein. One unit (U/mg protein) of CAT activity is defined as the μmoles of H₂O₂ decomposed/min/mg protein. One unit (U/mg protein) of SOD activity is defined as the amount of enzyme required to inhibit O.D. at 560 nm of chromogen production by 50 % in one minute. Values are mean ± SD from homogenate/PMS fraction of liver of 5 rats in each group. Significantly different from N-C at *p<0.001, significantly different from S-C at ^ap<0.001, significantly different from S-C at ^bp<0.01, significantly different from S-C at ^cp<0.05.

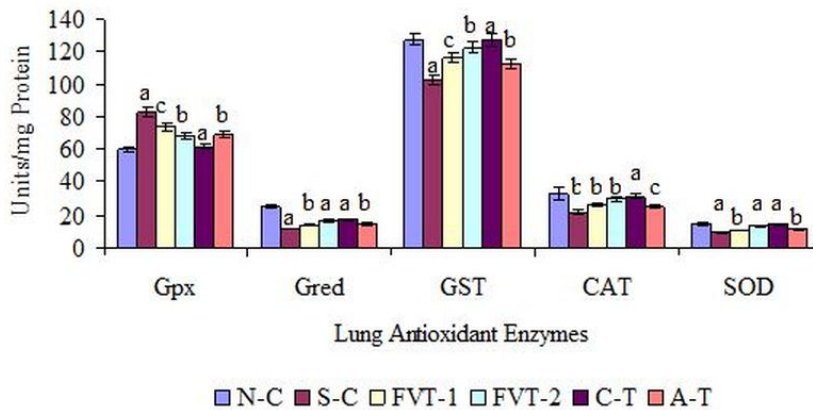


Figure 2. Impact of FVBM extract, F18 bioactive compound and atorvastatin on lung CAT, SOD, Gpx, Gred and GST activities in cigarette smoke-exposed rats after 4 weeks of treatment. One unit (U/ mg protein) of Gpx activity is defined as nmole oxidized glutathione formed/min/mg homogenate protein. One unit (U/ mg protein) of Gred activity is defined as nmole NADPH oxidized/min/mg PMS protein. One unit (U/ mg protein) of GST activity is defined as the nmole of 1-chloro 2,4-dinitrobenzene (CDNB) conjugate formed/min/mg PMS protein. One unit (U/mg protein) of CAT activity is defined as the μmoles of H₂O₂ decomposed/min/mg protein. One unit (U/mg protein) of SOD activity is defined as the amount of enzyme required to inhibit O.D. at 560 nm of chromogen production by 50 % in one minute. Values are mean ± SD from homogenate/PMS fraction of Lung of 5 rats in each group. Significantly different from N-C at *p<0.001. Significantly different from N-C at ^bp<0.01. Significantly different from S-C at ^ap<0.001. Significantly different from S-C at ^bp<0.01. Significantly different from S-C at ^cp<0.05.

Moreover, similar pattern was observed in lung enzymatic and non-enzymatic antioxidant defense system. As depicted in Fig. 2 the enzymatic activities of lung CAT, SOD, Gred and GST in S-C rats were significantly decreased from N-C value of 32.5, 14.7, 24.3 and 127.7 U/mg protein to 21.86, 9.56, 11.78 and 102.47 U/mg protein (Fig. 2). Whereas, lung Gpx activity in S-C rats was significantly increased from N-C values of 59.68 to 82.73 U/mg protein. The restoration in above enzymatic activities of lung CAT, SOD, Gred and GST in FVT-2 treated rat was 34, 40, 41 and 20 % of respective N-C values. The values of these enzymes in C-T group, in comparison to N-C values were significantly increased by 42, 50, 47 and 24 % respectively. In contrast the lung Gpx activity was significantly decreased by 11, 17, 26 and 16 % in FVT-1, FVT-2, C-T and A-T treated rats. Similarly, lung GSH content which was

significantly reduced by 33 % in S-C rats as significantly increased by 20, 37, 46 and 28 % after administration of FVBM extract, F18 bioactive compound and atorvastatin (Fig. 3). Here it is interesting to mention that atorvastatin also exhibited significant amelioration in all the enzymatic and non-enzymatic activities but is considered to be less effective than higher dose of FVBM extract and F18 bioactive compound.

In summary, hepatic and lung CAT, SOD, Gred, GST enzymes and non-enzymatic GSH, which constitute a mutually supportive team of defense against ROS, are significantly ameliorated after feeding of FVBM extract and F18 bioactive compound as well as substantially quenches the free radicals, thus positively normalizing the above enzyme levels close to normal values.

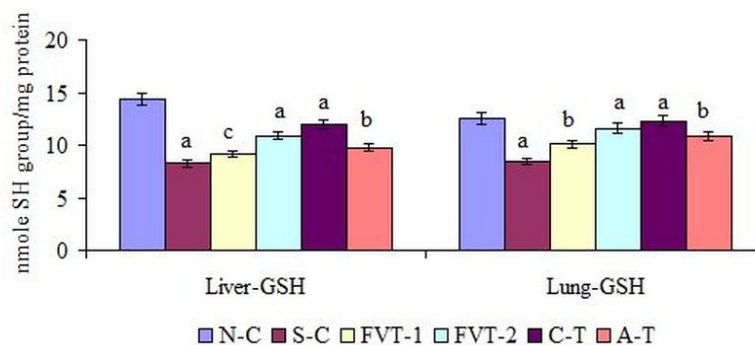


Figure 3. Effect of FVBM extract, F18 bioactive compound and atorvastatin on liver and lung GSH content in cigarette smoke-exposed rats after 4 weeks of treatment. Values are mean (nmole SH group/mg protein) \pm SD from homogenate of liver or lung of 5 rats in each group. Significantly different from N-C at $^a p < 0.001$. Significantly different from S-C at $^b p < 0.001$. Significantly different from S-C at $^c p < 0.01$. Significantly different from S-C at $^d p < 0.05$.

Histopathological studies of liver and lung

It is apparent from Fig. 4A that histopathology of the liver of the control rats showed normal looking uniform hepatocytes with small vesicular nuclei and abundant eosinophilic granular cytoplasm with distinct cell boundaries. Architecture of liver is well maintained. Normal Interstitial cells with vascularity. CS-exposed rats showed smaller hepatocytes with small vesicular or pyknotic nuclei and reduced granularity of cytoplasm. Cytoplasmic boundaries are relatively indistinct. Architecture not well maintained. Interstitial cells increased and vascularity is reduced (Fig. 4B). Administration of FVBM extract at lower dose has shown smaller hepatocytes with smaller vesicular nuclei and eosinophilic cytoplasm with indistinct cell

boundaries showing proliferation. Architecture not well maintained but vascularity has relatively increased (Fig. 4C). Moreover, liver section of FVT-2 rats (higher dose) (Fig. 4D) showed proliferated normal hepatocytes with normal vesicular nuclei and abundant eosinophilic cytoplasm with distinct cell boundaries. Architecture well maintained with normal interstitial cell and vascularity. Similarly, liver section of C-T rats showed proliferative hepatocytes with normal morphology as well as architecture. Interstitial cells normal with normal vascularity, also no toxic effects noted (Fig. 4E). Furthermore, liver section of A-T rats showed normal hepatocytes with normal vesicular nuclei and abundant eosinophilic cytoplasm along with well maintained normal architecture and vascularity (Fig. 4F).

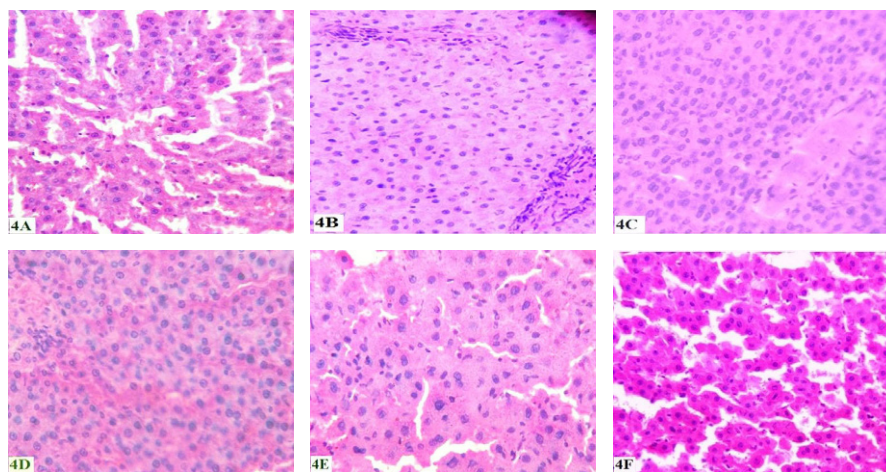


Figure 4. Histology of liver section. A. Microphotograph of liver section from normal control rats, B. Microphotograph of liver section from cigarette smoke-exposed rats after 4 weeks of cigarette smoke exposure, C. Microphotograph of liver section from cigarette smoke-exposed rats after 4 weeks of FVBM-50 treatment, D. Microphotograph of liver section from cigarette smoke-exposed rats after 4 weeks of FVBM-100 treatment, E. Microphotograph of liver section from cigarette smoke-exposed rats after 4 weeks of F18 bioactive compound treatment, F. Microphotograph of liver section from cigarette smoke-exposed rats after 4 weeks of atorvastatin treatment. Figures were captured at 100X.

Histopathology of lung in N-C group shows normal lung stroma and characteristic spongy appearance of the lung with normal looking numerous alveolar spaces, had normal blood vessels and bronchi. The bronchoalveolar unit parenchyma in the normal lung was within the limits (**Fig. 5A**). The lung section of CS-exposed rats showed the increased volume of stroma with presence of few collections of stromal cells with reduced alveolar spaces, reduced vascularity and constricted bronchi (**Fig. 5B**). There was obliteration of most alveoli and subsequently compensatory dilatation and expansion of the contiguous ones with destruction of alveolar wall. On treatment with lower dose of FVBM extract, section of lung shows reduced stroma, increased alveolar spaces, vascularity with patent blood vessels and dilated bronchi (**Fig. 5C**). On the other hand, treatment with higher dose, section of lung showed changes as described above but bronchi are relatively constricted (**Fig. 5D**). In addition, in lung section of C-T rat observed that stroma is further reduced with presence of large alveolar spaces. Blood vessels were normal but smaller bronchi were further constricted (**Fig. 5E**). Furthermore, lung slice of atorvastatin treated group showed the alveolar spaces comparatively less than normal with corresponding increase in stromal elements. Blood vessels and bronchi were normal in the presence of few constricted smaller bronchi (**Fig. 5F**).

DISCUSSION

Cigarette smoking (CS) is the foremost cause of morbidity and mortality worldwide (Alam et al., 2013; Jha et al., 2008) and is considered to be the preventable risk factor for CVD (Ambrose and Barua, 2004). Oxidative stress caused by CS are responsible for enhanced lipid peroxidation, protein oxidation, DNA damage and endothelial damage that could results in various diseases such as CVD, stroke, different types of cancer and diabetes (Messner and Bernhard, 2014; Mohod et al., 2014; Valavanidis et al., 2009; Willi et al., 2007).

Cigarette smoke is a complex situation possessing an array of free radicals and ROS (Pryor and Stone, 1993). These, free radicals are highly reactive molecules occurs in normal consequence of a variety of biochemical reactions (S, 2011). And their overload from exogenous sources like, smoking, alcohol abuse, UV radiations and air pollution added to the endogenous production of free radicals that results in oxidative stress and oxidative damage to the tissues (Ghobashy et al., 2010; Mohod et al., 2014; Wu and Cederbaum, 2003) as well as to DNA, proteins and membrane lipids (Cosmas Achudume and Aina, 2012; Wu and Cederbaum, 2003).

Under oxidative stress conditions, the antioxidant enzyme levels are altered, in order to cope with the

tremendous increase in the production of ROS (Anbarasi et al., 2006; McCord, 1993; Mohod et al., 2014). However, after prolonged exposure, the toxic effects of cigarette smoke emerge to override the adaptive mechanism of the body tissues, as indicated by a decrement in the levels of these enzymes (Hulea et al., 1994). It is clear from the above discussion CS induces paramount oxidative stress and is consistent with our results that demonstrate significant decrease in liver and lung enzymatic activity of SOD, CAT, Gred, GST including the GSH level, while Gpx activity was significantly increased in CS-exposed rats.

In antioxidant defense system SOD is known to be the first enzyme, responsible for scavenging the superoxide radicals to form H_2O_2 (Andersen et al., 1997). Furthermore, H_2O_2 is scavenged by catalase/GSH (glutathione peroxidase) or it facilitate in the development of highly reactive oxygen species

(Inoue et al., 2013; Mohod et al., 2014). The tar phase of cigarette smoke contains quinone-semiquinone radicals which are capable of reducing molecular oxygen to superoxide radicals whose extreme generation inactivates this enzyme (Church and Pryor, 1985; Durak et al., 2002). The proposed decrease in SOD activity in CS-exposed rats could have resulted from its inactivation by tar phase oxidants. The presence and production of the free radicals from smoke lower enzymatic activity of CAT, leading to accumulation of H_2O_2 and lipid hydroperoxides which further deteriorate the tissue damage (Pryor and Stone, 1993). Inhibition of CAT activity in rat liver and lung by cigarette smoke was observed during the present study which is in conjunction of previous reports (Luchese et al., 2009; Ramesh et al., 2007; Ramesh et al., 2010).

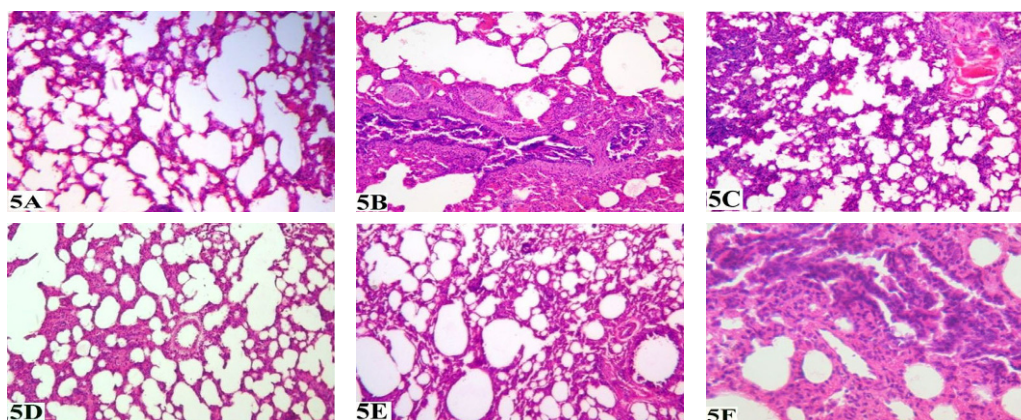


Figure 5. Histology of lung section. A. Microphotograph of lung section from normal control rats, B. Microphotograph of lung section from cigarette smoke-exposed rats after 4 weeks of cigarette smoke exposure, C. Microphotograph of lung section from cigarette smoke-exposed rats after 4 weeks of FVBM-50 treatment, D. Microphotograph of lung section from cigarette smoke-exposed rats after 4 weeks of FVBM-100 treatment, E. Microphotograph of lung section from cigarette smoke-exposed rats after 4 weeks of F18 bioactive compound treatment, F. Microphotograph of lung section from cigarette smoke-exposed rats after 4 weeks of atorvastatin treatment. Figures were captured at 100X.

However, a decrease in the activity of CAT in the present study suggests the *in-vivo* decrease in antioxidant level which in turn unable to defend the oxidative stress generated via cigarette smoke. Treatment with FVBM extract and F18 bioactive compound to smoke-exposed rats resulted in a significant increase in both liver and lung SOD and CAT activity which further strengthen the potent free

radical scavenging property of plant extract and bioactive compound. Reduced glutathione play an important role in glutathione-dependent antioxidant system that most probably act as free radicals scavenger or a substrate for Gpx and GST during the detoxification of H_2O_2 (Masella et al., 2005). Glutathione is maintained in body from its oxidized form by the enzyme Gred, which requires NADPH as

a cofactor (Carmel-Harel and Storz, 2000). Previously it has been reported that GSH was depleted during CS-exposure in various tissues. Meanwhile, the decrease in tissue GSH levels in CS-exposed rats may be because of declined Gred activity and probably reduced NADPH supply (Masella et al., 2005). GST is involved in the detoxification of ROS and toxic compounds from cigarette smoke, by conjugating them to GSH. This conjugation reaction results in depletion of the intracellular GSH that may further enhances oxidant injury probably due to non-availability of GSH for antioxidant enzymes such as Gpx. Recent experimental data support the assumption that CS exposure increases oxidative stress and act as a potential mechanism for initiating cardiovascular dysfunction (Ambrose and Barua, 2004).

Our data is well in agreement with above discussed reports and observed the significant decline in GSH, Gred and GST level in contrast the Gpx activity in liver and lung of CS-exposed rats was significantly increased which is due to inability of CAT to cope with the oxidative stress. Helen and Vijayammal (1997) also observed a similar decrease in the activity of SOD, CAT, Gred and an increase in Gpx in rats exposed to cigarette smoke. Gpx is also a scavenging enzyme, but an increase in its activity in tissues of CS-exposed rats may further reduce the GSH content. In addition, an increased Gpx activity represents a compensatory mechanism to degrade H_2O_2 . Simultaneous administration of FVBM extract (50 and 100 mg/rat) and F18 bioactive compound (1 mg/rat) significantly increases CAT, SOD, Gred and GST activity as well GSH concentration coupled with decrease in Gpx level in CS-exposed stress rats. Thus, it has been concluded that administration of FVBM extract at higher dose and F18 bioactive compound to CS-exposed rats restore the enzymatic (SOD, CAT, Gred, GST and Gpx) and non-enzymatic (GSH) antioxidant defense system and thus protect liver and lung cells against oxidative stress-induced damage by directly counteracting ROS/free radicals and by activating the overall antioxidant defense systems.

Histological observations noticed the pulmonary congestion and thickening of interalveolar septa in rats exposed to cigarette smoke. The present study showed

devastation of some alveolar walls and foci of collapsed alveoli with subsequent dilation of the adjoining alveolar spaces and development of large irregular spaces (emphysematous changes). Cigarette smoking causes endothelial dysfunction due to increased oxidative stress (Messner and Bernhard, 2014). Our results coincided with those who interrelated the thickening of the alveolar septa to modification in the vascular bed resulting in inflammatory infiltration and oedema (Hora et al., 2003). Chronic cigarette smoke exposure causes lung tissue destruction might be due to increased production of metalloproteinases (MMP) proteolytic enzymes by macrophages (Barnes et al., 2003; Taraseviciene-Stewart and Voelkel, 2008). The liver showed congestion in central vein, portal inflammation and necrosis in CS-exposed rats. These morphological changes were significantly reversed after treatment with FVBM extract and F18 compound. Thus, biochemical and histopathological studies suggested that, FVBM extract and F18 showed its protective nature against CS-exposed rats.

CONCLUSION

In conclusion, our combined results clearly demonstrated the protective role of FVBM extract and F18 compound in CS-induced severe oxidative stress. The results are well supported by histopathological observations and indicates that F18/FVBM extract are highly promising natural antioxidant as well as can be used as an antioxidant and antiatherogenic agent. However, further large-scale clinical trials in smokers with and without coronary heart disease are required to substantiate their antioxidative, atheroprotective properties.

Acknowledgements

The Authors like to thank Prof. S.W. Akhtar, vice chancellor, for providing state-of-the-art research laboratory and animal house for smooth succession of this work. The author would also like to thank Deanship of Scientific Research at Majmaah University for their support and contribution to this study.

Competing Interests

The authors declare they have no competing interests.

Open Access

This article is distributed under the terms of the Creative Commons Attribution License (CC-BY 4.0) which permits any use, distribution, and reproduction in any medium, provided the original author(s) and the source are credited.

References

- Akhter, F., Hashim, A., Khan, M.S., Ahmad, S., Iqbal, D., Srivastava, A.K., and Siddiqui, M.H. (2013). Antioxidant, α -amylase inhibitory and oxidative DNA damage protective property of Boerhaavia diffusa (Linn.) root. *South African Journal of Botany* 88, 265-272.
- Alam, D.S., Jha, P., Ramasundarahettige, C., Streatfield, P.K., Niessen, L.W., Chowdhury, M.A.H., Siddiquee, A.T., Ahmed, S., and Evans, T.G. (2013). Smoking-attributable mortality in Bangladesh: proportional mortality study. *Bulletin of the World Health Organization* 91, 757-764.
- Alvi, S.S., Iqbal, D., Ahmad, S., and Khan, M.S. (2015). Molecular rationale delineating the role of lycopene as a potent HMG-CoA reductase inhibitor: in vitro and in silico study. *Natural Product Research*, 1-4.
- Ambrose, J.A., and Barua, R.S. (2004). The pathophysiology of cigarette smoking and cardiovascular disease. *Journal of the American College of Cardiology* 43, 1731-1737.
- Anbarasi, K., Vani, G., Balakrishna, K., and Devi, C.S.S. (2006). Effect of bacoside A on brain antioxidant status in cigarette smoke exposed rats. *Life Sciences* 78, 1378-1384.
- Andersen, H.R., Nielsen, J.B., Nielsen, F., and Grandjean, P. (1997). Antioxidative enzyme activities in human erythrocytes. *Clinical chemistry* 43, 562-568.
- Aruoma, O.I. (1998). Free radicals, oxidative stress, and antioxidants in human health and disease. *Journal of the American Oil Chemists' Society* 75, 199-212.
- Barnes, P.J., Shapiro, S.D., and Pauwels, R.A. (2003). Chronic obstructive pulmonary disease: molecular and cellular mechanisms. *Eur Respir J* 22, 672-688.
- Carmel-Harel, O., and Storz, G. (2000). Roles of the Glutathione- and Thioredoxin-Dependent Reduction Systems in the Escherichia Coli and Saccharomyces Cerevisiae Responses to Oxidative Stress. *Annual Review of Microbiology* 54, 439-461.
- Church, D.F., and Pryor, W.A. (1985). Free-radical chemistry of cigarette smoke and its toxicological implications. *Environ Health Perspect* 64, 111-126.
- Cosmas Achudume, A., and Aina, F. (2012). Oxidative Stress and Oxidative Damage in Male Rat Erythrocytes Associated with Prolonged Exposure to Smoke Pollution. *Journal of Environmental Protection* 03, 414-419.
- Durak, İ., Elgün, S., Bingöl, N.K., Burak Çimen, M.Y., Kaçmaz, M., Büyükköçak, S., and Öztürk, H.S. (2002). Effects of cigarette smoking with different tar content on erythrocyte oxidant/antioxidant status. *Addiction Biology* 7, 255-258.
- Ellman, G.L. (1959). Tissue sulfhydryl groups. *Archives of Biochemistry and Biophysics* 82, 70-77.
- Eriksson, S., Askeloef, P.E.R., Axelsson, K., Carlberg, I., Guthenberg, C., and Mannervik, B. (1975). ChemInform Abstract: Resolution of glutathione-linked enzymes in rat liver and evaluation of their contribution to disulfide reduction via thiol-disulfide interchange. *Chemischer Informationsdienst* 6, no-no.
- Ghobashy, H.A., Elmeleegy, U.A.G., and Seleem, H.S. (2010). Histological, Histochemical, Immunohistochemical and Morphometric Study of Adult Male Albino Rat's Lung Following Exposure to Air Pollution. *The Egyptian Journal of Histology* 33, 140-155.
- Hafeman, D., Sunde, R., and Hoekstra, W. (1974). Effect of dietary selenium on erythrocyte and liver glutathione peroxidase in the rat. *The Journal of nutrition* 104, 580-587.
- Hora, K., Fonseca, A., Valença, S., Santos, R., and Porto, L. (2003). Lung morphometry in rats treated with intraperitoneal nicotine. *Acta Microscopica* 12.
- Hulea, S., Olinescu, R., Nita, S., Crocnan, D., and Kummerow, F. (1994). Cigarette smoking causes biochemical changes in blood that are suggestive of oxidative stress: a case-control study. *Journal of environmental pathology, toxicology and oncology: official organ of the International Society for Environmental Toxicology and Cancer* 14, 173-180.
- Inoue, M., Nagi, S., Chadeka, E., Mutungi, F., Osada-Oka, M., Ono, K., Oda, T., Tanaka, M., Ozeki, Y., and Yombo, K.D.J. (2013). Relationship between mycobacterium tuberculosis and hookworm infections among school children in Mbita, Kenya. *J Trop Dis* 1, 2.
- Iqbal, D., Khan, M.S., Khan, A., Khan, M.S., Ahmad, S., Srivastava, A.K., and Bagga, P. (2014a). In Vitro Screening for β -Hydroxy- β -methylglutaryl-CoA Reductase Inhibitory and Antioxidant Activity of Sequentially Extracted Fractions of Ficus palmata Forsk. *BioMed Research International* 2014, 1-10.
- Iqbal, D., Khan, M.S., Khan, M., Ahmad, S., and Srivastava, A.K. (2014b). An In Vitro and Molecular Informatics Study to Evaluate the Antioxidative and β -hydroxy- β -methylglutaryl-CoA Reductase Inhibitory Property of Ficus virens Ait. *Phytotherapy Research* 28, 899-908.
- Iqbal, D., Khan, M.S., Khan, M.S., Ahmad, S., Hussain, M.S., and Ali, M. (2015). Bioactivity guided fractionation and hypolipidemic property of a novel HMG-CoA reductase inhibitor from Ficus virens Ait. *Lipids Health Dis* 14.
- JA, K. (2001). *Histological and Histochemical Methods: Theory and Practice* (Publication City/Country: London: Hodder Arnold).
- Jha, P., Jacob, B., Gajalakshmi, V., Gupta, P.C., Dhingra, N., Kumar, R., Sinha, D.N., Dikshit, R.P., Parida, D.K., Kamadod, R., et al. (2008). A Nationally Representative Case-Control Study

- of Smoking and Death in India. *New England Journal of Medicine* 358, 1137-1147.
- Khan, M., Khan, M.A., Ansari, I., and Arif, J. (2013). Dietary phytochemicals as potent chemotherapeutic agents against breast cancer: Inhibition of NF-KB pathway via molecular interactions in rel homology domain of its precursor protein p105. *Pharmacognosy Magazine* 9, 51.
- Luchese, C., Pinton, S., and Nogueira, C.W. (2009). Brain and lungs of rats are differently affected by cigarette smoke exposure: Antioxidant effect of an organoselenium compound. *Pharmacological Research* 59, 194-201.
- Masella, R., Di Benedetto, R., Vari, R., Filesi, C., and Giovannini, C. (2005). Novel mechanisms of natural antioxidant compounds in biological systems: involvement of glutathione and glutathione-related enzymes. *The Journal of Nutritional Biochemistry* 16, 577-586.
- McCord, J.M. (1993). Human disease, free radicals, and the oxidant/antioxidant balance. *Clinical Biochemistry* 26, 351-357.
- Messner, B., and Bernhard, D. (2014). Smoking and Cardiovascular Disease: Mechanisms of Endothelial Dysfunction and Early Atherogenesis. *Arteriosclerosis, Thrombosis, and Vascular Biology* 34, 509-515.
- Mills, G.C. (1959). The purification and properties of glutathione peroxidase of erythrocytes. *Journal of Biological Chemistry* 234, 502-506.
- Mohod, K., Ninghot, A., Ansari, A.K., and Garg, N. (2014). Circulating Lipid Peroxide and Antioxidant Status in Cigarette Smokers: An Oxidative Damage Phenomena. *International Journal of Health Sciences and Research (IJHSR)* 4, 59-65.
- Pryor, W.A., and Stone, K. (1993). Oxidants in Cigarette Smoke Radicals, Hydrogen Peroxide, Peroxynitrate, and Peroxynitrite. *Ann NY Acad Sci* 686, 12-27.
- Ramesh, T., Mahesh, R., and Begum, V.H. (2007). Effect of *Sesbania grandiflora* on Lung Antioxidant Defense System in Cigarette Smoke Exposed Rats. *International Journal of Biological Chemistry* 1, 141-148.
- Ramesh, T., Sureka, C., Bhuvana, S., and Begum, V.H. (2015). Brain oxidative damage restored by *Sesbania grandiflora* in cigarette smoke-exposed rats. *Metabolic Brain Disease* 30, 959-968.
- Ramesh, T., Sureka, C., Bhuvana, S., and Hazeena Begum, V. (2010). *Sesbania grandiflora* diminishes oxidative stress and ameliorates antioxidant capacity in liver and kidney of rats exposed to cigarette smoke. *Journal of Physiology and Pharmacology* 61, 467.
- S, V. (2011). Free radicals in health and diseases. *Pharmacol online* 1: 1062-1077.
- Salvamani, S., Gunasekaran, B., Shaharuddin, N.A., Ahmad, S.A., and Shukor, M.Y. (2014). Antiatherosclerotic Effects of Plant Flavonoids. *BioMed Research International* 2014, 1-11.
- Santilli, F., Guagnano, M.T., Vazzana, N., Barba, S., and Davi, G. (2015). Oxidative Stress Drivers and Modulators in Obesity and Cardiovascular Disease: From Biomarkers to Therapeutic Approach. *CMC* 22, 582-595.
- Sedlak, J., and Lindsay, R.H. (1968). Estimation of total, protein-bound, and nonprotein sulfhydryl groups in tissue with Ellman's reagent. *Analytical Biochemistry* 25, 192-205.
- Sen, S., Chakraborty, R., Sridhar, C., Reddy, Y., and De, B. (2010). Free radicals, antioxidants, diseases and phytomedicines: current status and future prospect. *International Journal of Pharmaceutical Sciences Review and Research* 3, 91-100.
- Sirisha, N., Sreenivasulu, M., Sangeeta, K., and Chetty, C.M. (2010). Antioxidant properties of *Ficus* species—a review. *Int J PharmTech Res* 2, 2174-2182.
- T S, L., N B, S., S M, D., Pattar, J., and K, S. (2013). Repeated dose 28-day oral toxicity study of raw areca nut extract in rats *Int Res J Pharm* 4, 238-240.
- Taraseviciene-Stewart, L., and Voelkel, N.F. (2008). Molecular pathogenesis of emphysema. *Journal of Clinical Investigation* 118, 394-402.
- Thirumalai, T., David, E., Therasa, S.V., and Elumalai, E.K. (2011). Restorative effect of *Eclipta alba* in CCl₄ induced hepatotoxicity in male albino rats. *Asian Pacific Journal of Tropical Disease* 1, 304-307.
- Valavanidis, A., Vlachogianni, T., and Fiotakis, K. (2009). Tobacco Smoke: Involvement of Reactive Oxygen Species and Stable Free Radicals in Mechanisms of Oxidative Damage, Carcinogenesis and Synergistic Effects with Other Respirable Particles. *International Journal of Environmental Research and Public Health* 6, 445-462.
- WHO (2015). World Health Organization (WHO) Cardiovascular diseases. In Fact Sheet No 317 (Available at: <http://www.who.int/mediacentre/factsheets/fs317/en/>. Updated January, 2015).
- Willi, C., Bodenmann, P., Ghali, W.A., Faris, P.D., and Cornuz, J. (2007). Active Smoking and the Risk of Type 2 Diabetes. *JAMA* 298, 2654.
- Wu, D., and Cederbaum, A.I. (2003). Alcohol, oxidative stress, and free radical damage. *Alcohol Research and Health* 27, 277-284.

Cite this article as:

Iqbal, D., Khan, M., Khan, A., & Ahmad, S. (2016). Extenuating the role of *Ficus virens* Ait and its novel bioactive compound on antioxidant defense system and oxidative damage in cigarette smoke exposed rats. *Biomedical Research and Therapy*, 3(7), 723-732.