

Intranasal versus systemic corticosteroids in treatment of otitis media with effusion in the presence or absence of adenoid hypertrophy in children

Sayed M.S. Kadah, Tawfik A.E. Elkholy, Hebatullah K.E. Tammam

Department of Otorhinolaryngology, Faculty of Medicine for Girls, Al-Azhar University, Cairo, Egypt

Correspondence to Sayed M.S. Kadah, Department of Otorhinolaryngology, Faculty of Medicine for Girls, Al-Azhar University, Cairo, Egypt. Tel: +201005367894; e-mail: ss_kadah@yahoo.com

Received 22 January 2019

Accepted 10 March 2019

The Egyptian Journal of Otolaryngology 2019, 35:288–299

Background

Otitis media with effusion (OME) is defined as the presence of fluid in the middle ear without signs or symptoms of acute infection. The condition is common and affects ~90% of children before school age, who develop an average of four episodes of OME per year, most often between the ages of 6 months and 4 years.

Aim

The aim of this study was to investigate the role of systemic versus local corticosteroids in treatment of OME in the presence or the absence adenoid hypertrophy in children.

Patients and methods

In our study, 60 children who fulfilled the inclusion criteria were divided into two equal groups: group A included children with OME with adenoidal hypertrophy and group B included children with OME without adenoidal hypertrophy. Then, each group was subdivided into two groups, where one received topical intranasal steroids (A1 and B1), and the other one received oral steroids (A2 and B2). Tympanograms were done for all patients every 2 weeks.

Results

The final result is that both topical intranasal and systemic steroids are effective in the treatment of OME in children, without significant difference between the two methods, so oral steroid complications could be avoided by using local steroid spray, and the effectiveness of steroids (oral or topical) in treatment of OME is better in absence of adenoidal hypertrophy than in the presence of adenoidal hypertrophy.

Conclusion

Both topical intranasal and oral steroids are effective adjunctive treatment for OME in children in the short term.

Keywords:

otitis media with effusion, systemic steroids, topical nasal steroids

Egypt J Otolaryngol 35:288–299

© 2019 The Egyptian Journal of Otolaryngology 1012-5574

Introduction

Otitis media with effusion (OME) is largely asymptomatic, and many episodes are therefore undetected, including those with hearing difficulties or school performance issues, so the indirect costs are likely much higher [1]. Acute otitis media is usually diagnosed with its typical symptoms such as pain or fever. In contrast, OME is often called middle ear fluid; the lay term can help parents and families better understand why it occurs and how it differs from acute middle ear infections [1]. The effusion may be serous, mucoid, purulent, or a combination of these [2]. OME may occur during an upper respiratory tract infection, spontaneously because of poor Eustachian tube function or as an inflammatory response following acute otitis media [3].

Children should be screened for OME by the age of 5–6 years during the primary school, as approximately one of eight children is found to have fluid in one or both ears. The prevalence of OME in children with

Down syndrome or cleft palate is much higher, ranging from 60 to 85% [4]. OME persists for 1 month in 30–50% of children, for 2 months in 15–25%, and for 3 months in 8–15% [3]. The presence of middle ear effusion (MEE) should be determined by the combined use of otoscopy, pneumatic otoscopy, and tympanometry [5].

The current treatment options for OME include eliminating the risk factors; follow-up without treatment, as many patients with OME require no specific treatment; use of antibiotics, which have a negligible effect on the long-term resolution of MEE, and/or decongestant medication, steroids, or antihistamines; and maneuvers to open the Eustachian tubes, such as Valsalva maneuver. However, if medical

This is an open access journal, and articles are distributed under the terms of the Creative Commons Attribution-NonCommercial-ShareAlike 4.0 License, which allows others to remix, tweak, and build upon the work non-commercially, as long as appropriate credit is given and the new creations are licensed under the identical terms.

treatment fails, tympanostomy tube placement with or without adenoidectomy is done [6].

The effect of systemic and topical intranasal steroids on OME in children has been the subject of randomized and controlled clinical trials [7]. The decision regarding surgery for OME depends largely on hearing status, associated symptoms, child's developmental risk, and anticipated chance of timely spontaneous resolution of the effusion [8].

Aim

This study aimed to investigate the role of systemic versus local corticosteroids in treatment of OME in the presence or the absence adenoid hypertrophy in children.

Patients and methods

Patients

This is a prospective study of 60 patients with bilateral secretory otitis media (SOM) attending ENT Departments of Alzahraa University Hospital, Faculty of Medicine for Girls, Al-Azhar University, El-Maadi Armed Forces Medical Complex, and Air Force Specialized Hospital, during the period from October 2017 till November 2018. Patients were divided into two equal groups: group A included patients who had SOM with adenoid hypertrophy and group B without. Each group is subdivided into further two subgroups, where one received an intranasal mometasone furoate spray once daily for 6 weeks, and another received oral steroids in tapering doses for 6 weeks, plus systemic antibiotics for 10 days; nasal decongestants were used for 5 days for both groups. Tympanogram has been done every 2 weeks for all patients. Informed written consent was obtained from the parents of the children studied after explanation of the research purpose.

The study protocol and consent form were approved by the research review committee.

Inclusion criteria

The following were the inclusion criteria:

- (1) Children aged from above 2 years up to 10 years old.
- (2) Patients with bilateral OME and documented by otoscopic examination and tympanometry (bilateral type B tympanogram) at the time of entry to the study.
- (3) Patients with OME causing conductive hearing loss in pure tone audiometry if possible (above the age of 6 years) supporting the diagnosis of OME.

- (4) Patients who had symptoms of adenoid hypertrophy.

Exclusion criteria

The following were the exclusion criteria:

- (1) Patients who have taken systemic or topical intranasal steroids in the previous 3 months.
- (2) Patients who previously underwent operative procedures for treatment of their OME.
- (3) Patients who underwent adenoidectomy.

Methods

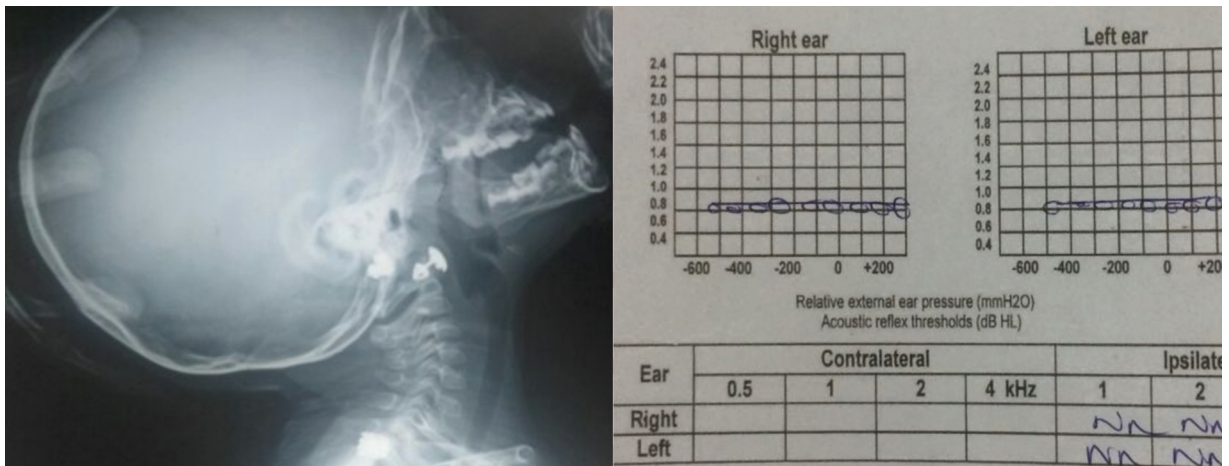
All patients had been subjected to the following diagnostic workup:

- (1) Full medical history, including diminution of hearing, tinnitus, earache, or any associated complaint.
- (2) Full clinical examination including general examination and otoscopic examination.
- (3) Basic audiological evaluation to diagnose OME:
- (4) Tympanometry: using low-frequency probe tone of 226 Hz for pressure applied to the external canal between +300 and -300 daPa.
- (5) Pure tone audiometry (if possible): in children older than 6 years, to diagnose the degree of hearing loss.
- (6) Radiological assessment to diagnose the presence or absence of adenoid by doing plain radiography on nasopharynx lateral view.

Children meeting entry criteria were divided into two equal groups:

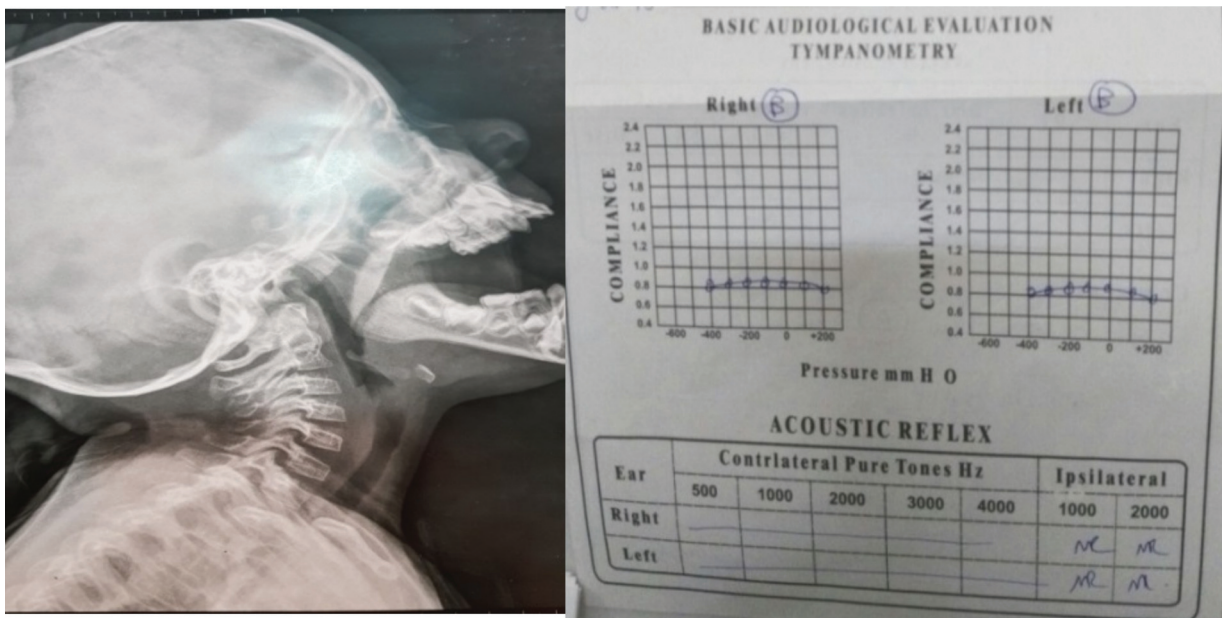
- (1) Group A (30 children) included children with bilateral OME with significant adenoidal hypertrophy (Fig. 1). The group was subdivided into two subgroups: group A1 (15 children) received 50 µg of topical intranasal mometasone furoate, once a day for 6 weeks (one puff) in each nostril (total daily dose 100 µg) and group A2 (15 children) received oral prednisolone in syrup form of 1 mg/kg/day in tapering doses for 6 weeks.
- (2) Group B (30 children) included children with bilateral OME without significant adenoidal hypertrophy (Fig. 2). The group is subdivided into two subgroups, where group B1 (15 children) received 50 µg of topical intranasal mometasone furoate, once a day for 6 weeks (one puff) in each nostril (total daily dose 100 µg) and group B2 (15 children) received oral prednisolone in syrup form of 1 mg/kg/day in tapering doses for 6 weeks.

Figure 1



An example of group A shows a female patient of 2 years old presented with bilateral otitis media with effusion and adenoid hypertrophy.

Figure 2



An example of group B shows a male patient of 4 years old presented with bilateral otitis media with effusion without adenoid hypertrophy.

In addition, both groups received systemic antibiotic (amoxicillin) for 10 days and nasal decongestants (xylometazoline) for 5 days.

All patients were evaluated at 0, 2, 4, and 6 weeks.

The assessment of each patient included history, otoscopic examination, a tympanogram, and a pure tone audiogram (above the age of 6 years).

The appropriate method of using the intranasal steroid spray was demonstrated at the baseline visit to children’s parents. The parent’s use of the spray was observed and assessed. This was intended to produce maximal local anti-inflammatory effects on the posterior nasal airway.

At the follow-up visits (every 2 weeks), subjective improvement of the symptoms and otoscopic examination findings was recorded as well as the tympanometry evaluation.

The outcome of the study

- (1) Resolution or cure of bilateral glue ear was defined by complete bilateral improvement (type A tympanogram) at any stage.
- (2) Incomplete improvement was defined by type C tympanogram.
- (3) No improvement was defined by persistence of type B tympanogram.

Statistical analysis

Recorded data were analyzed using the statistical package for social sciences, version 20.0 (SPSS Inc., Chicago, Illinois, USA). Quantitative data were expressed as mean±SD. Qualitative data were expressed as frequency and percentage.

The following tests were done:

- (1) Independent-samples *t*-test of significance was used when comparing between two means.
- (2) χ^2 -test of significance was used to compare proportions between qualitative parameters.
- (3) The confidence interval was set to 95% and the margin of error accepted was set to 5%. So, the *P* value was considered significant as follows:
- (4) *P* value less than 0.05 was considered significant.
- (5) *P* value less than or equal to 0.001 was considered as highly significant.
- (6) *P* value more than 0.05 was considered insignificant.

Results

The age of the patients ranged from 2 to 6 years, with mean of 3.68±0.77 years. Participants comprised 45% female and 55% male (Table 1).

Regarding examination by otoscopy, there was bilateral retracted tympanic membrane (TM) (88.3%), opaque TM (81.0%), air fluid level (5.0%), air bubbles (3.3%), and reduction of TM movement (58.0%) of the patients; moreover, tympanograms at the start of treatment were type B effusion (100%) (Table 2).

The tympanograms after 2 weeks showed improvement in five (8.3%), incomplete improvement in three (5.0%), and no improvement in 52 (86.7%); after 4 weeks showed improvement in seven (11.7%), incomplete improvement in four

(6.6%), and no improvement in 49 (81.7%); and after 6 weeks showed improvement in 28 (46.7%), incomplete improvement in six (10.0%), and no improvement in 26 (43.3%) (Table 3).

There was no statistically significant difference between group A, with adenoid, and group B, without adenoid, according to demographic data (Table 4).

There was a statistically significant difference between group A, with adenoid, and group B, without adenoid, according to tympanograms after 6 weeks (Table 5).

There was a statistically significant difference between improvement tympanogram through times in each group (Table 6).

There was no statistically significant difference between group A1, with adenoid on intranasal steroid, and group A2, with adenoid on oral steroid, according to tympanograms. However, there was a statistically significant difference between improvement in tympanogram through times in each subgroup (Table 7).

There was no statistically significant difference between group B1, without adenoid on intranasal steroid, and group B2, without adenoid on oral

Table 1 Sociodemographic data distribution of the study groups

Sociodemographic data	N=60 [n (%)]
Age (years)	
2	12 (20.0)
3	18 (30.0)
4	15 (25.0)
5	7 (11.7)
6	8 (13.3)
Range (mean±SD)	2–6 (3.68±0.77)
Sex	
Female	27 (45.0)
Male	33 (55.0)

Table 2 Diagnostic tools distribution of the study groups

Diagnostic tools	N=60 [n (%)]
By otoscopy	
Bilateral retracted TM	53 (88.3)
Opaque TM	49(81.0)
Air fluid level	3 (5.0)
Air bubbles	2 (3.3)
Reduction of TM movement	35 (58.0)
Tympanograms at start of treatment	
Effusion (type B)	60 (100.0)

TM, tympanic membrane.

Table 3 Tympanogram distribution of the study groups

Follow-up tympanograms	N=60 [n (%)]
After 2 weeks	
Improvement	5 (8.3)
Incomplete improvement	3 (5.0)
No improvement	52 (86.7)
After 4 weeks	
Improvement	7 (11.7)
Incomplete improvement	4 (6.6)
No improvement	49 (81.7)
After 6 weeks	
Improvement	28 (46.7)
Incomplete improvement	6 (10.0)
No improvement	26 (43.3)

Table 4 Comparison between group A, with adenoid, and group B, without adenoid, according to demographic data

Demographic data	Group A: with adenoid (n=30) [n (%)]	Group B: without adenoid (n=30) [n (%)]	Test	P value
Sex				
Female	14 (46.7)	13 (43.3)	$\chi^2=0.067$	0.795
Male	16 (53.3)	17 (56.7)		
Age (years)				
Range	2–6	2–6	$t=0.015$	0.614
Mean±SD	3.61±0.67	3.57±0.67		

t, independent sample *t*-test. $P>0.05$, NS.

Table 5 Comparison between group A, with adenoid, and group B, without adenoid, according to tympanograms

Tympanograms	Group A: with adenoid (n=30) [n (%)]	Group B: without adenoid (n=30) [n (%)]	χ^2	P value
At start of treatment				
Effusion	30 (100.0)	30 (100.0)	0.000	1.000
After 2 weeks				
Improvement	2 (6.7)	3 (10.0)	0.610	0.737
Incomplete Improvement	1 (3.3)	2 (6.7)		
No improvement	27 (90.0)	25 (83.3)		
After 4 weeks				
Improvement	3 (10.0)	4 (13.3)	1.327	0.515
Incomplete Improvement	1 (3.3)	3 (10.0)		
No improvement	26 (86.7)	23 (76.7)		
After 6 weeks				
Improvement	15 (50.0)	13 (43.3)	6.758	0.034*
Incomplete Improvement	0 (0.0)	6 (20.0)		
No improvement	15 (50.0)	11 (36.7)		

$P>0.05$, NS. * $P<0.05$, significant.

steroid, according to tympanograms. However, there was a statistically significant difference between improvement in tympanogram through times in each subgroup (Table 8).

There was no statistically significant difference between group A1, with adenoid on intranasal steroid, and group B1, without adenoid on intranasal steroid, according to tympanograms. However, there was a statistically significant difference between improvement in tympanogram readings through times in each subgroup (Table 9).

There was no statistically significant difference between group A2, with adenoid on oral steroid, and group B2, without adenoid on oral steroid, according to tympanograms. However, there was a statistically significant difference between improvement in tympanograms through different times in each subgroup (Table 10).

There was a statistically significant relation between tympanograms after 6 weeks and age (years) (Table 11).

An example of tympanogram of patient with OME without adenoid hypertrophy treated by intranasal

steroid (group B1) after 4 weeks of treatment showing improvement (bilateral type A tympanogram) is shown in Fig. 3.

An example of tympanogram of patient with OME with adenoid hypertrophy treated by oral steroids (group A2) after 2, 4, and 6 weeks of treatment showing no improvement (bilateral type B tympanogram) after 2 weeks, and then incomplete improvement after 4 weeks and then no improvement after 6 weeks is shown in Fig. 4.

Discussion

The mean age of the participants was 3.68±0.77 years, with minimum age of 2 years and maximum of 10 years. The most frequent symptoms were lack of attention noted by parents, loud TV volume, and sometimes mild otalgia. No one reported with lack of balance.

In this study, the most frequent finding in the examination before the start of the treatment was bilateral retracted TM (88.3%), opaque TM (81.0%), air fluid level (5.0%), air bubbles (3.3%), reduction of TM movement (58.0%), and bilateral type B tympanogram in all cases, denoting effusion.

Table 6 Comparison between improvement in tympanogram through different times within each group separately

Tympanograms	Group A: with adenoid (n=30) [n (%)]	P value ^a	Group B: without adenoid (n=30) [n (%)]	P value ^a
At start of treatment				
Effusion	30 (100.0)		30 (100.0)	
After 2 weeks				
Improvement	2 (6.7)	0.206	3 (10.0)	0.065
Incomplete improvement	1 (3.3)		2 (6.7)	
No improvement	27 (90.0)		25 (83.3)	
After 4 weeks				
Improvement	3 (10.0)	0.117	4 (13.3)	<0.001**
Incomplete Improvement	1 (3.3)		3 (10.0)	
No improvement	26 (86.7)		23 (76.7)	
After 6 weeks				
Improvement	15 (50.0)	<0.001**	13 (43.3)	<0.001**
Incomplete improvement	0 (0.0)		6 (20.0)	
No improvement	15 (50.0)		11 (36.7)	
χ^2 -test	45.554		39.620	
P value	<0.001**		<0.001**	

^aSignificant difference between at start of treatment and time by improvement. $P>0.05$, NS. ** $P<0.001$, highly significant.

Table 7 Comparison between group A1, with adenoid on intranasal steroid, and group A2, with adenoid on oral steroid according to tympanograms

Tympanograms	Group A1: with adenoid on intranasal steroid (n=15) [n (%)]	Group A2: with adenoid on oral steroid (n=15) [n (%)]	χ^2 -test	P value
At start of treatment				
Effusion	15 (100.0)	15 (100.0)	0.000	1.000
After 2 weeks				
Improvement	1 (6.7)	1 (6.7)	1.037	0.595
Incomplete Improvement	1 (6.7)	0 (0.0)		
No improvement	13 (86.7)	14 (93.3)		
After 4 weeks				
Improvement	2 (13.3)	1 (6.7)	1.333	0.513
Incomplete Improvement	0 (0.0)	1 (6.7)		
No improvement	13 (86.7)	13 (86.7)		
After 6 weeks				
Improvement	8 (53.3)	7 (46.7)	0.030	0.862
Incomplete Improvement	0 (0.0)	0 (0.0)		
No improvement	7 (46.7)	8 (53.3)		
χ^2 -test		27.692		26.615
P value ^a		<0.001**		<0.001**

^aSignificant difference between time by improvement. $P>0.05$, NS. ** $P<0.001$, highly significant.

Tympanogram distribution of the all study group during the period of treatment showed that tympanograms after 2 weeks showed improvement in five (8.3%), incomplete improvement in three (5.0%), and no improvement in 52 (86.7%); after 4 weeks showed improvement in seven (11.7%), incomplete improvement in four (6.6%), and no improvement in 49 (81.7%); and after 6 weeks showed improvement in 28 (46.7%), incomplete improvement in six (10.0%), and no improvement in 26 (43.3%).

There was no statistically significant difference between group A, with adenoid, and group B, without adenoid, according to demographic data.

In this study, there was a highly significant improvement ($P<0.001$) of OME regarding tympanometric results through different times that occurred within each subgroup separately (A1, which included children with SOM with adenoid hypertrophy on intranasal steroid treatment, and A2, which included children with SOM with adenoid hypertrophy on oral steroid treatment), with no significant difference ($P>0.05$) in improvement between the two subgroups. This indicates the effectiveness of both oral and topical steroids in the treatment of OME in presence of adenoid hypertrophy.

Table 8 Comparison between group B1, without adenoid on intranasal steroid, and group B2, without adenoid on oral steroid according to tympanograms

Tympanograms	Group B1: without adenoid on intranasal steroid (n=15) [n (%)]	Group B2: without adenoid on oral steroid (n=15) [n (%)]	χ^2 - test	P value
At start of treatment				
Effusion	15 (100.0)	15 (100.0)	0.000	1.000
After 2 weeks				
Improvement	1 (6.7)	2 (13.3)	0.373	0.829
Incomplete Improvement	1 (6.7)	1 (6.7)		
No improvement	13 (86.7)	12 (80.0)		
After 4 weeks				
Improvement	2 (13.3)	2 (13.3)	0.377	0.828
Incomplete Improvement	2 (13.3)	1 (6.7)		
No improvement	11 (73.3)	12 (80.0)		
After 6 weeks				
Improvement	7 (46.7)	6 (40.0)	0.168	0.919
Incomplete Improvement	3 (20.0)	3 (20.0)		
No improvement	5 (33.3)	6 (40.0)		
χ^2 -test		21.657		18.699
P value ^a		<0.001**		<0.001**

^aSignificant difference between time by improvement. $P>0.05$, NS. ** $P<0.001$, highly significant.

Table 9 Comparison between group A1, with adenoid on intranasal steroid, and group B1, without adenoid on intranasal steroid, according to tympanograms

Tympanograms	Group A1: with adenoid on intranasal steroid (n=15) [n (%)]	Group B1: without adenoid on intranasal steroid (n=15) [n (%)]	χ^2 - test	P value
At start of treatment				
Effusion	15 (100.0)	15 (100.0)	0.000	1.000
After 2 weeks				
Improvement	1 (6.7)	1 (6.7)	0.000	1.000
Incomplete Improvement	1 (6.7)	1 (6.7)		
No improvement	13 (86.7)	13 (86.7)		
After 4 weeks				
Improvement	2 (13.3)	2 (13.3)	2.167	0.339
Incomplete Improvement	0 (0.0)	2 (13.3)		
No improvement	13 (86.7)	11 (73.3)		
After 6 weeks				
Improvement	8 (53.3)	7 (46.7)	3.400	0.183
Incomplete Improvement	0 (0.0)	3 (20.0)		
No improvement	7 (46.7)	5 (33.3)		
χ^2 -test		23.261		21.657
P value ^a		<0.001**		<0.001**

^aSignificant difference between time by improvement. $P>0.05$, NS. ** $P<0.001$, highly significant.

This is nearly similar to a study done by Thomas *et al.* [9] in a systematic review, who concluded that both oral and topical intranasal steroids alone or in combination with an antibiotic lead to a quicker resolution of OME in the short term; however, there is no evidence of long-term benefit.

Moreover, it is nearly similar to a prospective, controlled, randomized, clinical study done by

Cengel and Akyol [10] on 122 children (3–15-year-old) on the waiting list for adenoidectomy and/or ventilation tube placement divided into a case group and a control group. The study group (67 patients with adenoid hypertrophy; 34 of them with OME) received intranasal mometasone furoate monohydrate of 100 mcg/day, one spray in each nostril once a day for 6 weeks. The control group (55 patients with adenoid hypertrophy; 29 of them with OME) was followed up

Table 10 Comparison between group A2, with adenoid on oral steroid, and group B2, without adenoid on oral steroid according to tympanograms

Tympanograms	Group A2: with adenoid on oral steroid (n=15) [n (%)]	Group B2: without adenoid on oral steroid (n=15) [n (%)]	χ^2 - test	P value
At start of treatment				
Effusion	15 (100.0)	15 (100.0)	0.000	1.000
After 2 weeks				
Improvement	1 (6.7)	2 (13.3)	1.487	0.475
Incomplete Improvement	0 (0.0)	1 (6.7)		
No improvement	14 (93.3)	12 (80.0)		
After 4 weeks				
Improvement	1 (6.7)	2 (13.3)	0.373	0.829
Incomplete Improvement	1 (6.7)	1 (6.7)		
No improvement	13 (86.7)	12 (80.0)		
After 6 weeks				
Improvement	7 (46.7)	6 (40.0)	3.363	0.186
Incomplete Improvement	0 (0.0)	3 (20.0)		
No improvement	8 (53.3)	6 (40.0)		
χ^2 -test		22.357		18.699
P value ^a		<0.001**		<0.001**

^aSignificant difference between time by improvement. $P>0.05$, NS. ** $P<0.001$, highly significant.

Table 11 Relation between tympanograms after 6 weeks and demographic data in all patients

Demographic data	Tympanograms after 6 weeks [n (%)]			χ^2 -test	P value
	Improvement (n=28)	Incomplete improvement (n=6)	No improvement (n=26)		
Age (years)					
2	7 (25.0)	0 (0.0)	5 (19.2)	16.902	0.031*
3	13 (46.4)	0 (0.0)	5 (19.2)		
4	2 (7.1)	3 (50.0)	10 (38.5)		
5	3 (10.7)	2 (33.3)	2 (7.7)		
6	3 (10.7)	1 (16.7)	4 (15.4)		
Sex					
Female	12 (42.9)	4 (66.7)	11 (42.3)	1.266	0.531
Male	16 (57.1)	2 (33.3)	15 (57.7)		

without any treatment. No other medication was allowed during the study in either group. Resolution of OME in the study group (42.2%) was significantly higher than that in the control group (14.5%). A total of 45 (67.2%) patients with adenoid hypertrophy in the study group showed significant decreases in adenoid size according to the endoscopic evaluation compared with the control group.

A significant improvement in obstructive symptoms was seen in the treatment group. These results indicated that nasal mometasone furoate monohydrate treatment can significantly reduce adenoid hypertrophy and obstructive symptoms and is a useful alternative to surgery, at least in the short term, for OME.

In addition, it was nearly similar to another clinical study done by El-Anwar *et al.* [11], which was conducted on 60 patients with OME who were

divided into three groups: in group 1, 20 patients received mometasone furoate spray, one puff in each nostril daily, for 3 months; in group 2, 20 patients received oral prednisolone, 5 mg three times per day for the first 3 weeks; and in group 3, 20 patients received nasal saline spray, one puff in each nostril daily for 3 months. A highly significant difference between systemic or topical (nasal spray) steroid therapy and saline nasal spray was detected ($P<0.001$), and the difference between systemic and topical steroid was nonsignificant ($P>0.05$), concluding that nasal steroid spray is an effective treatment for OME, showing a result similar to systemic steroid, and nasal steroid could also be helpful in controlling the adenoid size, which is a contributing factor in developing and recurring OME.

However, this is against a study done by Simpson *et al.* [12], who in a systematic review concluded that

although oral steroids, especially when used in combination with an oral antibiotic, lead to a quicker resolution of OME in the short term, there is no evidence of long-term benefit and no evidence that they relieve symptoms of hearing loss. Moreover, they also found no evidence of benefit from treatment of OME with topical intranasal steroids, alone or in combination with an antibiotic, at either short-term or long-term follow-up.

In this study, there was a highly significant improvement ($P < 0.001$) of OME regarding tympanometric results through different times that occurred within each subgroup separately (i.e. B1, which include children with SOM without adenoid hypertrophy on intranasal steroid treatment, and B2, which include children with SOM without adenoid hypertrophy on oral steroid treatment), with no significant difference ($P > 0.05$) in improvement between the two subgroups. This indicates the

effectiveness of both oral and topical steroids in treatment of OME in absence of adenoid hypertrophy.

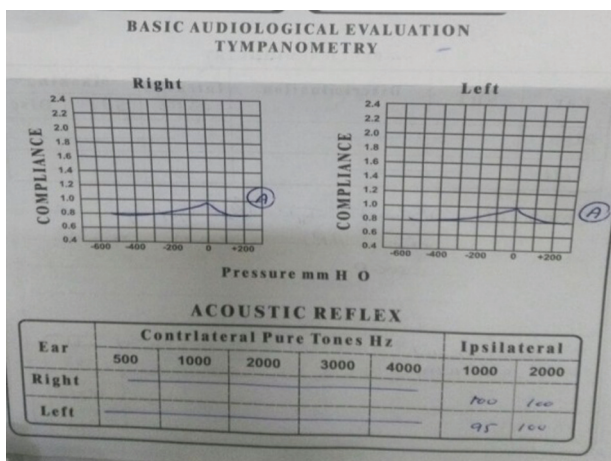
This is nearly similar to a study done by Thomas *et al.* [9] in a systematic review, which concluded that both oral and topical intranasal steroids alone or in combination with an antibiotic lead to a quicker resolution of OME in the short term; however, there is no evidence of longer term benefit.

Moreover, our result is nearly similar to another clinical study done by El-Anwar *et al.* [11] on 60 patients with OME who were divided into three groups: in group 1, 20 patients received mometasone furoate spray, one puff in each nostril daily, for 3 months; in group 2, 20 patients received oral prednisolone, 5 mg three times per day for the first 3 weeks; and in group 3, 20 patients received nasal saline spray, one puff in each nostril daily for 3 months. They concluded that nasal steroid spray is an effective treatment for OME, showing a result similar to systemic steroid, and also nasal steroid could also be helpful in controlling nasal allergy, which is a contributing factor in developing and recurring OME.

However, this is against a study done by Simpson *et al.* [12] in a systematic review, which concluded that although oral steroids, especially when used in combination with an oral antibiotic, lead to a quicker resolution of OME in the short term, there is no evidence of long-term benefit and no evidence that they relieve symptoms of hearing loss. Moreover, they also found that there is no evidence of benefit from treatment of OME with topical intranasal steroids, alone or in combination with an antibiotic, at either short-term or long-term follow-up.

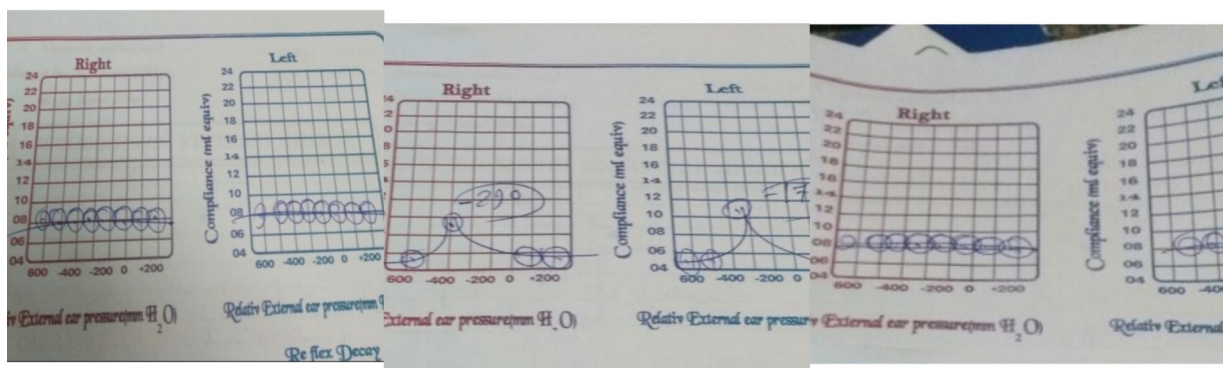
In this study, there was a highly significant improvement ($P < 0.001$) of OME regarding

Figure 3



Tympanogram after 4 weeks of treatment showing improvement (bilateral type A tympanogram).

Figure 4



Tympanogram after 2, 4, and 6 weeks of treatment.

tympanometric results through different times that occurred within each subgroup separately (i.e. A1, which included children with SOM with adenoid hypertrophy on intranasal steroid treatment and B1, which include children with SOM without adenoid hypertrophy on intranasal steroid treatment), with no significant difference ($P>0.05$) in improvement between the two subgroups. This indicates the effectiveness of topical intranasal steroid in treatment of OME in presence or absence of adenoid hypertrophy.

This is nearly similar to a randomized, placebo-controlled trial study done by Shapiro *et al.* [13] on 45 children with persistent Eustachian tube dysfunction (documented with abnormal tympanometry) owing to allergic rhinitis, aged from 2 to 10 years, who failed to respond to 4 weeks of oral antihistamine and decongestants. They were subjected to aerosolized dexamethasone one spray in each nostril three times a day for 3 weeks ($n=21$) versus aerosolized placebo ($n=24$). Within the dexamethasone group, there were statistically significant increases in patients achieving normal middle ear pressure and TM mobility and position in one or both ears, supporting some therapeutic efficacy for nasal aerosolized dexamethasone. The observation showed that most improvement occurred in the first 2 weeks and that some worrisome cortisol changes occurred, suggesting that dexamethasone therapy should be limited to 2 weeks and should be undertaken with caution.

Our result is nearly similar to another randomized, placebo-controlled trial by Tracy *et al.* [14] on 61 children, aged 3–11 years, with persistent MEE greater than 3 months, who were randomized into three treatment groups: (1) prophylactic antibiotics; (2) prophylactic antibiotics plus intranasal beclomethasone (336 g/day); and (3) prophylactic antibiotics plus intranasal placebo. Patients were evaluated with aeroallergen skin tests at entry, and tympanogram, otoscopic examination, and symptom questionnaire at 0, 4, 8, and 12 weeks. The beclomethasone plus antibiotics group improved all three measures more rapidly than the antibiotics-alone and placebo nasal spray plus antibiotics groups over the first 8 weeks and concluded that intranasal beclomethasone may be a useful adjunct to prophylactic antibiotic treatment of chronic MEE.

Our result was also nearly similar to another study by Cengel and Akyol [10], which concluded that nasal mometasone furoate monohydrate treatment can significantly reduce adenoid hypertrophy and

obstructive symptoms and is a useful alternative to surgery, at least in the short term, for OME.

Moreover, it was nearly similar to another randomized, prospective clinical trial by Barati *et al.* [15] using amoxicillin and a decongestant for both groups and nasal beclomethasone spray only for the case group. They concluded that the administration of nasal beclomethasone spray as an adjuvant for the treatment of OME not only improved the results but also increased the resolution of symptoms and the patients' quality of hearing.

It was also nearly similar to another prospective, clinical study done by Menon *et al.* [16] on 22 children aged between 4 and 15 years. The study concluded the efficacy of mometasone furoate monohydrate topical nasal spray in the resolution of middle ear fluid in children aged between 4 and 15 years with OME to be significant (52.7%). A significant improvement in the overall symptoms was seen in the treatment group.

In addition, it was nearly similar to a study done by El-Anwar *et al.* [11], which concluded that nasal steroid spray is an effective treatment for OME, and also nasal steroid could also be helpful in controlling nasal allergy and the adenoid size, which are contributing factors in developing and recurring OME.

However, it was against a double-blind study done by Lildholdt and Kortholm [17] analyzing drug versus placebo on 70 children with MEE, aged 4–14 years, sprayed each nostril twice daily for 1 month. Among them, 35 children received a daily dose of 400 µg of the beclomethasone. The results of tympanometry, audiometry, and otomicroscopy were compared in the two groups, and the statistical analysis revealed P values of around 0.5. The conclusion is that the active drug had no effect on MEE in the population investigated.

In addition, it was against another randomized, placebo-controlled trial done by Williamson *et al.* [18] on 217 children aged 4–11 years presenting with 1 or more episodes of otitis media or ear-related problems in previous 12 months and with bilateral OME enrolled into two groups. The study group received topical nasal steroid mometasone furoate (50 mcg) in each nostril versus placebo group used once daily for 3 months. Overall, 41% of the topical steroid group and 45% of the placebo group were cured in one or both ears at 1 month, and at 3 months, 58% of the topical steroid group and 52% of

the placebo group were cured. They, although concluded that topical steroids are unlikely to be an effective treatment for OME in general practice.

Moreover, it was against a systematic review done by Simpson *et al.* [12], which concluded no evidence of benefit from treatment of OME with topical intranasal steroids, alone or in combination with an antibiotic, either at short-term or long-term follow-up.

In this study, there was a highly significant improvement ($P < 0.001$) of OME regarding tympanometric results through different times that occurred in each subgroup separately (A2, which included children with SOM with adenoid hypertrophy on oral steroid treatment, and B2, which included children with SOM without adenoid hypertrophy on oral steroid treatment), with no significant difference ($P > 0.05$) in improvement between the two subgroups. This indicates the effectiveness of oral steroid in treatment of OME in presence or absence of adenoid hypertrophy.

This is nearly similar to a randomized double-blinded controlled study done by Waldron *et al.* [19] on 380 participants (children of 2–8 years of age) with symptoms for at least 3 months that are attributable to OME and with confirmed bilateral hearing loss at study entry. Participants are randomized to a course of oral steroid or a matched placebo for 1 week. The aim of the trial is to determine if a short course of oral steroids improves the hearing of children with OME in the short term and long term. Outcomes include audiometry, tympanometry, and otoscopy assessments; symptoms; adverse effects; functional health status; quality of life; resource use; and cost effectiveness. Participants are followed up at 5 weeks and at 6 and 12 months after the day of randomization. The primary outcome is audiometry-confirmed satisfactory hearing at 5 weeks.

In this study, there was a highly significant difference in improvement ($P < 0.001$) of OME regarding tympanometric results between at start of treatment and time after 6 weeks within group A, which include children with SOM with adenoid hypertrophy. This indicates the effectiveness of steroids (oral or topical) in treatment of OME in presence of adenoid hypertrophy. There was a highly significant difference in improvement ($P < 0.001$) of OME regarding tympanometric results between at start of treatment and time after 4 weeks and after 6 weeks within group B, which include children with SOM without adenoid hypertrophy. This indicates the effectiveness of steroids (oral or topical) in treatment of OME in absence of adenoid hypertrophy.

This is nearly similar to a systematic review done by Christopher *et al.* [20], which concluded that steroids alone or combined with an antibiotic lead to a quicker resolution of OME in the short term.

In addition, it was found to be similar to another study done by Thomas *et al.* [9], which concluded that both oral and topical intranasal steroids alone or in combination with an antibiotic lead to a quicker resolution of OME in the short term; however, there is no evidence of long-term benefit.

In this study, there was significant difference in improvement ($P < 0.05$) of OME regarding tympanometric results between group A, which include children with SOM with adenoid hypertrophy, and group B, which include children with SOM without adenoid hypertrophy, according to tympanograms after 6 weeks of treatment. This indicates that the effectiveness of steroids (oral or topical) in treatment of OME is better in absence of adenoidal hypertrophy (group B) than in the presence of adenoidal hypertrophy (group A).

The final result of our study shows that both oral and topical steroids are effective in treatment of OME. Moreover, the effectiveness of steroids (oral or topical) in treatment of OME is better in absence of adenoidal hypertrophy (group B) than in the presence of adenoidal hypertrophy (group A).

Conclusion

Both topical intranasal and oral steroids are effective adjunctive treatment for OME in children in the short term.

Oral steroid complications could be avoided by using local steroid spray.

The effectiveness of steroids (oral or topical) in treatment of OME is better in absence of adenoidal hypertrophy than in the presence of adenoidal hypertrophy.

Further studies are needed to investigate their role in treatment of OME in the presence or absence of adenoidal hypertrophy for longer duration and in larger group of patients.

Financial support and sponsorship

Nil.

Conflicts of interest

There are no conflicts of interest.

References

- 1 Lieberthal AS, Carroll AE, Chonmaitree T. The diagnosis and management of acute otitis media. *Pediatrics* 2013; 131:e964–e999.
- 2 Tewfik TL, MD. Eustachian tube function: Overview, embryology of the eustachian tube, anatomy of the eustachian tube; 2018. updated form <https://emedicine.medscape.com/article/874348-overview/3/11>.
- 3 Lack G, Caulfield H, Penagos M. The link between otitis media with effusion and allergy: a potential role for intranasal corticosteroids. *Pediatr Allergy Immunol* 2011;22:258–266.
- 4 Maris M, Wojciechowski M, van de Heyning P, Boudewyns A. A cross-sectional analysis of otitis media with effusion in children with Down syndrome. *Eur J Pediatr* 2014; 173:1319–1325.
- 5 Rosenfeld RM, Goldsmith AJ, Tetlus L, Balzano A. Quality of life for children with otitis media. *Arch Otolaryngol Head Neck Surg* 1997; 123:1049.
- 6 American Academy of Family Physicians, American Academy of Otolaryngology-Head and Neck Surgery and American Academy of Pediatrics, Subcommittee on Otitis Media with Effusion. Otitis media with effusion. *Pediatrics* 2004; 113:1412–1429.
- 7 Simon F, Haggard M, Rosenfeld RM, Jia H, Peer S, Calmels MN, *et al.* International Consensus (ICON) on management of otitis media with effusion in children. *Eur Ann Otorhinolaryngol Head Neck Dis* 2018; 135: S33–S39.
- 8 Capaccio P, Torretta S, Marciante GA, Marchisio P, Forti S, Pignataro L. Endoscopic adenoidectomy in children with otitis media with effusion and mild hearing loss. *Clin Exp Otorhinolaryngol* 2016; 9: 33.
- 9 Thomas CL, Simpson SA, Butler CC, van der Voort J, Lewis R. Oral or topical nasal steroids for hearing loss associated with otitis media with effusion in children. *Cochrane Database Syst Rev* 2006; 2006: CD001935.
- 10 Cengel S, Akyol MU. The role of topical nasal steroids in the treatment of children with otitis media with effusion and/or adenoid hypertrophy. *Int J Pediatr Otorhinolaryngol* 2006; 70: 639–645.
- 11 El-Anwar MW, Nofal AA, Khazbak AO, Sayed AE, Hassan MR. The efficacy of nasal steroids in treatment of otitis media with effusion: a comparative study. *Int Arch Otorhinolaryngol* 2015; 19: 298–301.
- 12 Simpson SA, Lewis R, van der Voort J, Butler CC. Oral or topical nasal steroids for hearing loss associated with otitis media with effusion in children. *Cochrane Database Syst Rev* 2011: CD001935.
- 13 Shapiro GG, Bierman CW, Furukuwa CT, Pierson WE, Berman R, Donaldson J. Treatment of persistent Eustachian tube dysfunction with aerosolised nasal dexamethasone phosphate versus placebo. *Ann Allergy* 1982; 49: 81–85.
- 14 Tracy JM, Demain JG, Hoffman KM, Goetz DW. Intranasal beclomethasone as an adjunct to treatment of chronic middle ear effusion. *Ann Allergy Asthma Immunol* 1998; 80: 198–206.
- 15 Barati B, Omrani MR, Okhovat AR, Kelishadi R, Hashemi M, Hassanzadeh A, *et al.* Effect of nasal beclomethasone spray in the treatment of otitis media with effusion. *J Res Med Sci* 2011; 16: 509–515.
- 16 Menon SS, Rahman A, Balakrishnan R, Nayak DR, Pujary K. Efficacy of mometasone nasal spray in the treatment of otitis media with effusion in the pediatric age group: a preliminary study. *Indian J Otol* 2013; 19: 114.
- 17 Lildholdt T, Kortholm B. Beclomethasone nasal spray in the treatment of middle-ear effusion – a double-blind study. *Int J Pediatr Otorhinolaryngol* 1982; 4:133–137.
- 18 Williamson I, Benge S, Barton S. Topical intranasal corticosteroids in 4–11 year old children with persistent bilateral otitis media with effusion in primary care: double blind randomised placebo controlled trial. *Clin Otolaryngol* 2010; 35:125–133.
- 19 Waldron CA, Thomas-Jones E, Cannings-John R, Hood K, Powell C, Roberts A, Tomkinson A, *et al.* Oral steroids for the resolution of otitis media with effusion (OME) in children (OSTRICH): study protocol for a randomised controlled trial. *Trials* 2016; 17:115.
- 20 Christopher C, Butler BA, Judith H. Steroids for otitis media with effusion. *Arch Pediatr Adolesc Med* 2001; 155:641–647.