

# Unilateral lung hyperlucency in an adult: an unusual cause

Parul Kodan, Abanti Das, Surabhi Vyas, Animesh Ray, Surinder K. Sharma

We report a case of young adult with unilateral lung hyperlucency. His radiological features were suggestive of Swyer–James syndrome. The condition is uncommon in adults. We report this rare case with discussion on clinical presentation, diagnosis, and management of Swyer–James syndrome. The report also throws light on various other causes of unilateral lung hyperlucency and its approach.

*Egypt J Bronchol* 2018 12:273–275

© 2018 Egyptian Journal of Bronchology

*Egyptian Journal of Bronchology* 2018 12:273–275

**Keywords:** bronchiectasis, pulmonary artery hypoplasia, unilateral lung hyperlucency

All India Institute of Medical Sciences, New Delhi, India

Correspondence to Dr. Animesh Ray, 46 C, Masjid Moth, Phase 1  
New Delhi 1100048, India. Tel: 9560093190;  
e-mail: doctoranimeshray@gmail.com

**Received** 7 August 2017 **Accepted** 12 November 2017

## Case report

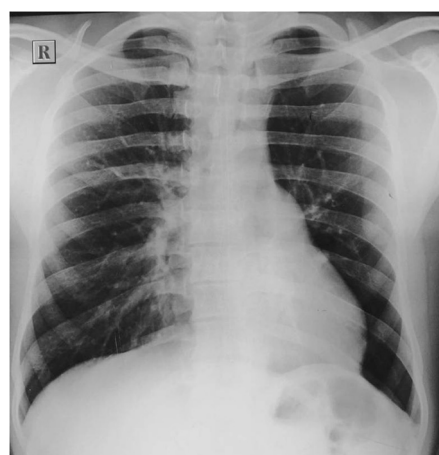A 21-year-old male patient presented with exertional, nonprogressive shortness of breath since childhood, modified medical research council dyspnea scale – grade 2, nonprogressive without associated wheeze/stridor. On examining, he revealed history of multiple prolonged respiratory infections in childhood. However, no previous medical records were available. On examination, breath sounds were mildly reduced on left side. Other systemic examination finding was normal. Chest radiographs showed diffuse hyperlucency in the left hemithorax (Fig. 1). High-resolution computed tomography (CT) of the thorax also showed left-sided hyperlucency with presence of bronchiectasis (Fig. 2). There was also evidence of air trapping in the left side on an expiratory scan. CT pulmonary angiography revealed narrowed left branch of pulmonary artery (Figs. 3 and 4). This combination led us to the diagnosis of Swyer–James syndrome [1].

Virtual bronchoscopy done showed slight narrowing of the left main bronchus without any luminal compromise. Virtual bronchoscopy did not show any significant compromise of the bronchial lumen.

Spirometry showed that forced expiratory volume in 1s was reduced (1.5 l/65% of predicted) and forced vital capacity was reduced (1.8 l), with a normal forced expiratory volume 1/forced vital capacity ratio of 0.83. However, body plethysmography showed normal total lung capacity (6.1 l) with an increased residual volume (4.23 l), suggestive of air trapping. This nonspecific pattern of ventilatory defect as seen in our case has been described in association with obstructive lung diseases.

The patient was managed with bronchodilators, and regular follow-up was done for timely and prompt

**Figure 1**



Chest X-ray Showing lung hyperlucency.

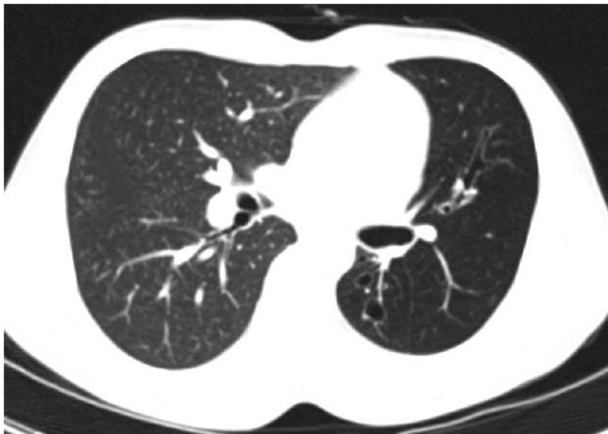
management of any infection. The patient was also advised pneumococcal and annual influenza vaccinations. The patient improved with conservative management and is on regular follow-up.

## Discussion

Swyer–James syndrome or Mcleod or Bret syndrome is a unilateral hyperlucent lung syndrome which was first described by Swyer, James, and Mcleod in Canada and independently by Dr Bret from France [1]. A childhood history of infections in the form of viral bronchiolitis or pneumonitis can usually be traced in these patients [2]. The etiology of this disorder has been linked to childhood infection leading to abnormality of the bronchial

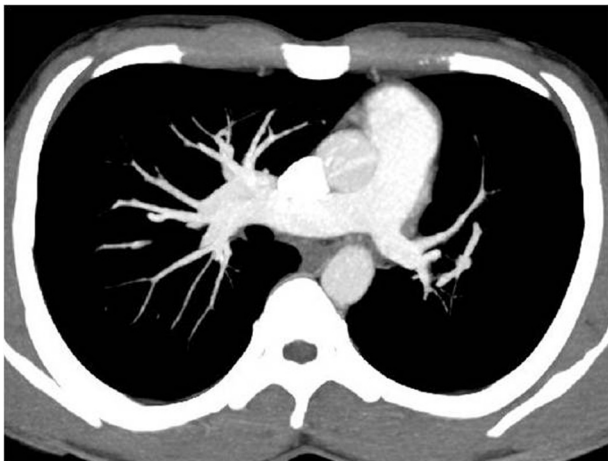
This is an open access journal, and articles are distributed under the terms of the Creative Commons Attribution-NonCommercial-ShareAlike 4.0 License, which allows others to remix, tweak, and build upon the work non-commercially, as long as appropriate credit is given and the new creations are licensed under the identical terms.

Figure 2



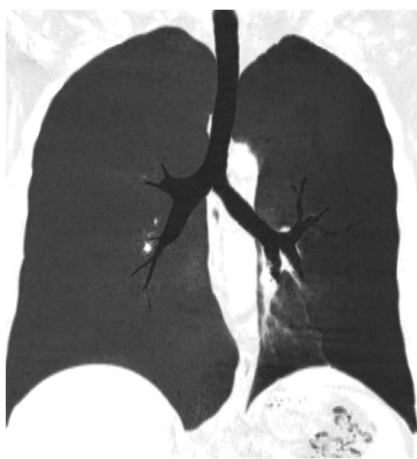
CT Scan showing left sided hyperlucency with presence of bronchiectasis.

Figure 3



CT pulmonary angiography showing narrowed left branch of pulmonary artery.

Figure 4



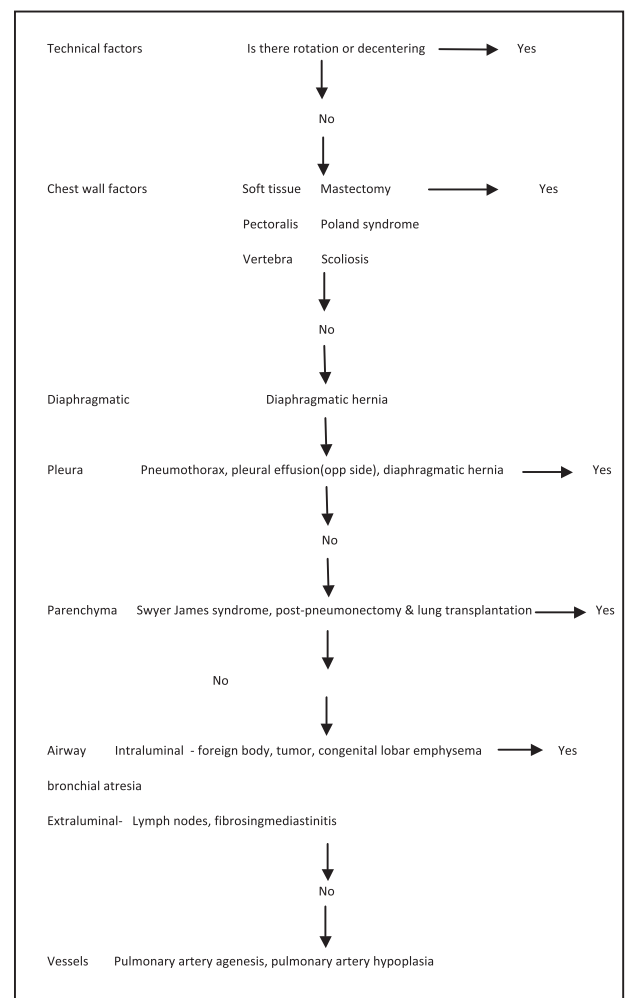
Virtual bronchoscopy showing slight narrowing of the left main bronchus without any luminal compromise.

architecture leading to secondary pulmonary artery hypoplasia. Alternatively, it is thought that primary pulmonary arterial abnormality predisposes the patient to respiratory tract infection and subsequent airway/alveolar changes. Pathologically, bronchiolitis obliterans can be appreciated in the affected lung.

Patient may be asymptomatic or present with dyspnea on exertion, cough, or history of repeated chest infections. A plain radiograph usually reveals single lung hyperlucency with a normal or decreased hemithorax with a small unilateral hilum. CT scan is the diagnostic modality of choice to clinch the diagnosis, and it reveals hyperlucent lung with diminished vascularity [3].

All cases of unilateral hyperlucency should be systematically evaluated (Flowchart 1 and Tables 1 and 2). Any unilateral hyperlucency should prompt the physician to look for the accurate cause relevant to the history. Unilateral hyperlucency can be attributed to just a technical factor like malrotation, to decreased chest

Flowchart 1



Approach to unilateral lung hyperlucency.

**Table 1 Pathophysiologically unilateral transradiancy of the hemithorax can be caused by a number of factors**

Technical factors: malrotation, lateral decentering
Decreased translucency of the contralateral side: contralateral pleural effusion/lung collapse or fibrosis
Decreased unilateral chest wall thickness: mastectomy and Poland syndrome
Obstructive hyperinflation: foreign body, Swyer–James syndrome, and congenital lobar emphysema
Compensatory hyperinflation: contralateral lung fibrosis/atelectasis
Congenital vascular causes: pulmonary artery hypoplasia
Acquired vascular causes: pulmonary artery embolism, pulmonary arterial occlusion by tumor, etc.

**Table 2 The differentiating points between the different causes of lung hyperlucency**

	Correct technique	C/L altered lucency	U/L lung volume	C/L lung volume	Air trapping	Vascular patency
Technical factors	No	No	Normal	Normal	No	Normal
C/L reduced translucency	Yes	Yes	Normal	Normal/abnormal	No	Normal
Chest wall abnormality	Yes	No	Normal	Normal	No	Normal
Obstructive hyperinflation	Yes	No	Normal/increased	Normal	Yes	Normal
Compensatory hyperinflation	Yes	Yes	Normal	Abnormal	No	Normal
Congenital vascular causes	Yes	No	Decreased	Normal	No	Abnormal
Acquired vascular causes	Yes	No	Normal	Normal	No	Abnormal

C/L, contralateral; U/L unilateral.

wall thickness in relevant history of mastectomy or in Poland syndrome, or to any other etiology such as obstructive causes like Swyer–James syndrome, as in our case. Swyer–James syndrome should be considered as one of the differential factors in any case of obstructive hyperinflation. In Swyer–James syndrome, expiratory scan will reveal features of air trapping. Bronchiectasis is usually present in long-standing cases but is not a universal finding. CT pulmonary angiography will show evidence of narrowed pulmonary artery of the affected side [4]. Pulmonary function studies may show features of obstructive ventilatory defect. Pulmonary ventilation and perfusion scan usually demonstrates matched ventilation and perfusion defects. Management of Swyer–James syndrome includes the early control of lung infections, bronchodilators, and preventive vaccinations. In severe cases, even lung resection has been attempted as a last resort [5].

## Conclusion

Swyer–James syndrome should be considered as a differential diagnosis in case of unilateral lung hyperlucency. Diminished lung vascularity and bronchiectasis along with features of unilateral air trapping on the affected side can help us clinch the diagnosis [1,4]. Prevention of respiratory infections and symptomatic care should remain the key management strategy.

## Declaration of patient consent

The authors certify that they have obtained all appropriate patient consent forms. In the form the patient(s) has/have given his/her/their consent for his/her/their images and other clinical information to be reported in the journal. The patients understand that their names and initials will not be published and due efforts will be made to conceal their identity, but anonymity cannot be guaranteed.

## Financial support and sponsorship

Nil.

## Conflicts of interest

There are no conflicts of interest.

## References

- 1 Capela C, Gouveia P, Sousa M, Regadas MJ. Adult diagnosis of Swyer–James–MacLeod syndrome: a case report. *J Med Case Reports* 2011; 5:2.
- 2 Fregonese L, Girosi D, Battistini E, Fregonese B, Rizzo FM, Bava GL, *et al.* Clinical, physiologic, and roentgenographic changes after pneumonectomy in a boy with Macleod/Swyer–James syndrome and bronchiectasis. *Pediatr Pulmonol* 2002; 34:412–416.
- 3 Moore AD, Godwin JD, Dietrich PA, Verschakelen JA, Henderson WR Jr. Swyer–James syndrome: CT findings in eight patients. *Am J Roentgenol* 1992; 158:1211–1215.
- 4 Marti-Bonmati L, Ruiz Perales F, Catala F, Mata JM, Calonge E. CT findings in Swyer–James syndrome. *Radiology* 1989; 172:477–480.
- 5 Koyama T, KOsada H, Kitanaka Y, Funaki S, Hiekata T. Surgically treated Swyer–James syndrome. *Jpn J Thorac Cardiovasc Surg* 2001; 49: 671–674.