

Transthoracic ultrasound in the diagnosis of bronchiectasis: is it valuable?

Mohamed Fawzy Abdel Ghany

Objectives The purpose of this study was to evaluate the diagnostic accuracy of transthoracic ultrasound in patients with bronchiectasis and compare it with high-resolution computed tomography (HRCT) chest.

Patients and methods Sixty-one patients with bronchiectasis underwent transthoracic ultrasound. Radiological severity of bronchiectasis was assessed using a modified Reiff score (number of lobes involved in six lobes multiplied by the degree of bronchial dilatation) (tubular=1, varicose=2, cystic=3). Transthoracic findings were compared with that of the HRCT and pulmonary function tests.

Results Two patterns of sonographic abnormalities were detected: B-line pattern and c-profile (consolidation) pattern. The first was detected in 42 (68.8%) patients and the later was detected in seven (11.1%) patients. Twelve (19.7%) patients had normal sonographic examination. There was significant positive correlation between severity of bronchiectasis by the modified Reiff score pattern. The highest score correlated with the c-profile pattern and the lower score correlated with the B-line pattern ($P \leq 0.001$), while patients with very low

score (≤ 20) had normal examination. There was a negative correlation between HRCT score, ultrasound pattern, and Partial pressure of oxygen tension (PO_2) ($P \leq 0.001$).

Conclusion Bronchiectasis can be assessed by chest ultrasound; pattern of sonography is correlated to the radiological severity and functional impairment of the disease. *Egypt J Bronchol* 2019 13:303–308
© 2019 Egyptian Journal of Bronchology

Egyptian Journal of Bronchology 2019 13:303–308

Keywords: bronchiectasis, high-resolution computed tomography, lung ultrasound, pulmonary function test

Department of Chest and Tuberculosis, Assiut University Hospital, Assiut, Egypt

*Correspondence to Mohamed F. Abdel Ghany, MD, Assiut University Hospital, Assiut University, Assiut 71515, Egypt. Tel: +20 882 146 826; fax: +20 882 333 327; e-mail: mfawzy2013@hotmail.com

Received 4 January 2019 **Accepted** 19 May 2019

Introduction

Bronchiectasis is a pathologic description of a disease process that has a number of possible causes. The characteristic features are abnormally dilated thick-walled bronchi that carry the criteria of inflammation and are colonized by bacteria. Symptoms include chronic cough, mucopurulent sputum production, hemoptysis, breathlessness, and tiredness. The incidence is perceived to have declined over recent decades, but significant numbers of patients continue to present to respiratory physicians.

The chest high-resolution computed tomography (HRCT) signs of bronchiectasis include dilatation of the peripheral bronchi, bronchial wall thickening tree-in-bud appearance, air-fluid levels in the distended bronchi, and grape-like clusters in the peripheral airways [1,2].

Recent literature has reported that variations of the pulmonary content and balance between air and fluids in the lung can be detected by chest ultrasound with high sensitivity [1].

Ultrasound abnormalities have been studied mainly in the alveolar, interstitial syndromes and in extra lung water overload. To our knowledge, the presence of sonographic abnormalities in bronchiectasis and its correlation with severity has not been yet established.

The simplicity and high feasibility of ultrasound make it an attractive and easy-to-use diagnostic tool at the bedside for the pulmonologist in the diagnosis of different lung diseases and bronchiectasis [2].

The aim of this study was to investigate the abnormal findings during ultrasound examination of a group of patients diagnosed radiologically as bronchiectasis with different degrees.

Patients and methods

This analytic cross-sectional study was done in Assiut University Hospital during the period from January 2017 to February 2018 on 61 patients diagnosed as suffering from bronchiectasis.

Diagnosis was based on history, clinical examination, chest HRCT, and all required immunological and laboratory investigations. Transthoracic ultrasound, pulmonary function tests (PFTs), and HRCT chest were performed for all patients at the Chest and Radiology Departments, Assiut University Hospital. An informed consent was obtained from each patient

This is an open access journal, and articles are distributed under the terms of the Creative Commons Attribution-NonCommercial-ShareAlike 4.0 License, which allows others to remix, tweak, and build upon the work non-commercially, as long as appropriate credit is given and the new creations are licensed under the identical terms.

and the study was approved by the Faculty of Medicine Ethics Committee.

Radiological assessment (high-resolution computed tomography)

The chest HRCT was done in the supine position using an Aquilion 64 Helical Scanner (Toshiba, Otawara, Japan), without intravenous contrast with thin sections obtained at 10-mm interval and 1 mm collimation sections. The tube current was 180–260 mA and the average tube voltage was 120–140 kV. Radiological severity of bronchiectasis was assessed using the modified Reiff score, we assessed the number of lobes involved (with the lingula considered to be a separate lobe) and then multiplied it by the degree of dilatation of bronchi (tubular=1, varicose=2, and cystic=3). The maximum score is 18 and the minimum score is 1 [3–5]. HRCT scans were interpreted and graded for bronchiectasis score by two consultant radiologists who were blind to the clinical details.

Pulmonary function test

Assessment of forced expiratory volume in the first second (FEV₁), forced vital capacity (FVC), and FEV₁/FVC was done in all patients by using Cosmed SrL (Quark PFTs ergo, P/N Co9035-12-99, Italy). partial pressure of oxygen tension (PO₂) was measured by a blood gas analyzer (Rapid Lab 850; Chiron Diagnostics, Halstead, UK) by taking an arterial sample from radial artery under room air condition.

Transthoracic ultrasonography

Chest ultrasound was performed using an ultrasound (Aloka Echo Camera SSD-3500; Aloka, Prosound, Yokohama, Japan) equipped with a 3.5 MHz convex probe.

The site showing the ultrasound abnormality was considered the site of interest. First, we examined the anterior parts of the chest in the supine position and then the posterior parts were examined in the sitting position; the examination for each patient included eight lung region 'scans.' During examination, the number of positive scans and the pattern of abnormality were evaluated precisely. The sonographic findings were then classified into [6]:

- (1) Normal: normal examination with no abnormal findings.
- (2) B-lines: defined as laser-like vertical reverberation artifacts that arise from the pleural line and extends to the end of the screen without fading, and moves in synchrony with the lung movement.

- (3) C-profile (consolidation): defined as the presence of a subpleural echo-poor region with tissue-like echo texture whose dimensions remained unchanged throughout the respiratory cycle and sometimes contains hyperechoic punctiform images which represent air bronchogram.

Statistical analysis

Statistical Package for the Social Sciences (version 20, Chicago, USA) software was used for analysis of the results. The results were expressed as mean±SD or number and percentage. The difference was considered significant when *P* value less than 0.05. Correlations were measured using Pearson's test, Spearman's test, χ^2 test, and Kruskal–Wallis test.

Results

Descriptive and clinical characteristics of the study population are displayed in Table 1.

About 81% of patients had positive findings. Two patterns were detected by chest sonography, B-line pattern, and c-profile (consolidation) pattern in 42 (68.8%) and seven (11.5%) patients, respectively. However, 12 (19.7%) patients' showed normal examination. By HRCT chest, cylindrical type of bronchiectasis significantly correlated with the presentation with B-lines (57.1%), while the cystic type of bronchiectasis correlated with the presentation with consolidation sonographically (100.0%).

Radiological score by the modified Reiff score significantly correlated with chest ultrasonographic pattern, where normal pattern, B-line pattern, and

Table 1 Demographic data of all study population

Variables	Study population (N=61)
Age	54.32±13.42
Sex	
Male	49 (80.3)
Female	12 (19.7)
Smoking	
Smoker	16 (26.2)
Ex-smoker	6 (9.8)
Nonsmoker	39 (64)
Type of bronchiectasis as regards their etiology	
Idiopathic bronchiectasis	33 (54.1)
Primary ciliary dyskinesia	2 (3.3)
ABPA	4 (6.6)
Posttuberculous	12 (19.6)
Postinfective	7 (11.4)
Rheumatoid arthritis	3 (5)

ABPA, allergic bronchopulmonary aspergillosis. Data are expressed as mean±SD or *n* (%).

consolidation pattern scores were 5.17 ± 2.29 , 9.79 ± 3.35 , 16.71 ± 1.60 , respectively. *P* values are 0.000, 0.000, and 0.000, respectively (Table 2).

A negative significant correlation was found between the degree of hypoxemia (PO_2) and oxygen saturation together and chest ultrasonographic pattern assessed by the presence of B-lines and consolidation pattern ($P=0.000$ and 0.007), respectively, as shown in Table 3.

As regards PFTs a significant correlation was found between the presence of abnormal sonographic pattern (normal pattern vs. B-lines vs. consolidation pattern) and FEV_1 (55.92 vs. 51.50 vs. 44.00) ($P=0.014$) and FEV_1/FVC ratio (65.25 vs. 55.77 vs. 51.43) ($P=0.023$) as shown in Table 4. Figures 1 and 2 illustrate two cases with comparable ultrasound and HRCT patterns.

Discussion

The role of chest sonography in the assessment of chest diseases has gained wide acceptance in the last few years [7].

Volpicelli *et al.* [6] reported different abnormal sonographic patterns such as B-line pattern and consolidation pattern which was found to correlate with alveolo-interstitial syndromes and pneumonia, respectively. This is the first study to evaluate the presence of abnormal chest sonographic signs in patients with bronchiectasis, in comparison with gold-standard HRCT.

In this study, B-line pattern was the most common pattern in patients with bronchiectasis (81%). B-lines were reported to be observed in certain diseases

Table 2 Correlation between chest ultrasound and high-resolution computed tomography in patients with bronchiectasis

Number of patients (61)	Chest ultrasonographic pattern			<i>P</i> value ^a	<i>P</i> value ^b	<i>P</i> value ^c
	Normal (N=12)	B-lines (N=42)	C-profile (consolidation) (N=7)			
Bronchiectasis type [<i>n</i> (%)]						
Tubular	4 (33.3)	7 (16.7)	0 (0.0)	0.237	0.245	0.573
Cylindrical	6 (50.0)	24 (57.1)	0 (0.0)	0.661	0.044*	0.010*
Cystic	2 (16.7)	11 (26.2)	7 (100.0)	0.708	0.001*	0.000*
Bronchiectasis extent						
Mean±SD	2.92±1.08	4.81±1.13	5.57±0.53	0.000*	0.000*	0.108
Median (range)	3.0 (1.0–4.0)	5.0 (3.0–6.0)	6.0 (5.0–6.0)			
Radiological score (modified Reiff score)						
Mean±SD	5.17±2.29	9.79±3.35	16.71±1.60	0.000*	0.000*	0.000*
Median (range)	4.0 (1.0–9.0)	9.5 (5.0–18.0)	18.0 (15.0–18.0)			

^a*P* value significance between normal pattern and B-line pattern regarding high-resolution computed tomography pattern. ^b*P* value significance between normal pattern and consolidation pattern regarding high-resolution computed tomography pattern. ^c*P* value significance between B-line pattern and consolidation pattern regarding high-resolution computed tomography pattern. *Significant.

Table 3 Correlation between chest ultrasonographic pattern and blood gas parameters in all study population

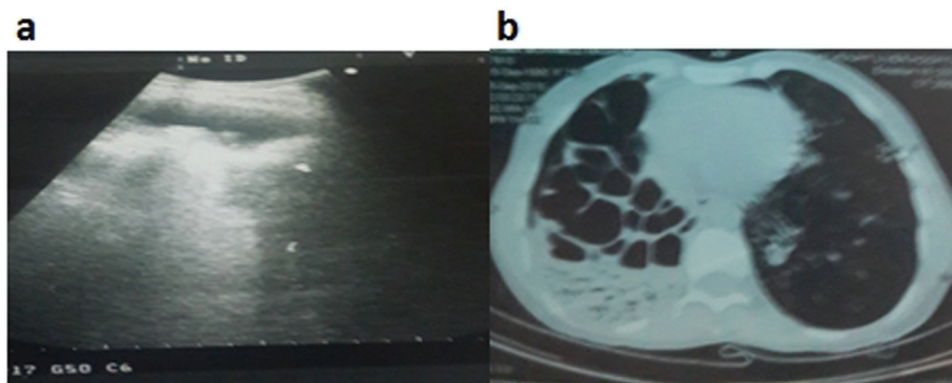
Number of patients (N=61)	Chest ultrasonographic pattern			<i>P</i> value ^a	<i>P</i> value ^b	<i>P</i> value ^c
	Normal (N=12)	B-lines (N=42)	C-profile (consolidation) (N=7)			
PaO ₂						
Mean±SD	57.33±6.53	53.35±7.99	40.57±2.37	0.123	0.000*	0.000*
Median (range)	58.0 (46.0–66.0)	52.0 (40.0–71.0)	41.0 (38.0–45.0)			
PaCO ₂						
Mean±SD	52.08±14.54	55.23±12.28	72.29±6.42	0.492	0.007*	0.001*
Median (range)	52.0 (32.0–71.0)	55.5 (35.0–78.0)	71.0 (63.0–79.0)			
pH						
Mean±SD	7.41±0.06	7.38±0.07	7.37±0.14	0.056	0.832	0.977
Median (range)	7.4 (7.3–7.5)	7.4 (7.3–7.5)	7.4 (7.1–7.5)			
HCO ₃						
Mean±SD	32.07±6.81	31.38±4.22	30.86±3.13	0.369	0.345	0.886
Median (range)	33.5 (20.2–38.0)	30.5 (24.1–43.0)	32.0 (27.0–34.0)			
SaO ₂						
Mean±SD	85.91±6.30	84.11±5.36	74.57±6.53	0.110	0.007*	0.001*
Median (range)	88.0 (70.9–92.0)	86.0 (68.9–92.0)	78.0 (66.0–81.0)			

^a*P* value significance between normal pattern and B-lines pattern regarding blood gases. ^b*P* value significance between normal pattern and consolidation pattern regarding blood gases. ^c*P* value significance between B-lines pattern and consolidation pattern regarding blood gases. *Significant.

Table 4 Correlation between chest ultrasound pattern and pulmonary function test in patients with bronchiectasis

Number of patients (N=61)	Chest ultrasonographic pattern			P value ^a	P value ^b	P value ^c
	Normal (N=12)	B-lines (N=42)	C-profile (consolidation) (N=7)			
FEV₁						
Mean±SD	55.92±12.82	51.50±11.21	44.00±3.83	0.211	0.014*	0.072
Median (range)	58.0 (29.0–78.0)	52.0 (32.0–77.0)	45.0 (36.0–47.0)			
FVC						
Mean±SD	54.50±8.45	59.55±13.17	65.57±15.09	0.282	0.171	0.345
Median (range)	60.0 (35.0–60.0)	59.0 (38.0–80.0)	60.0 (53.0–92.0)			
FEV₁/FVC						
Mean±SD	65.25±10.81	55.77±11.47	51.43±9.91	0.007*	0.023*	0.296
Median (range)	65.0 (44.0–82.0)	58.0 (27.0–78.0)	52.0 (38.0–66.0)			

FEV₁, forced expiratory volume in the 1stst second; FVC, forced vital capacity. ^aP value significance between normal pattern and B-lines pattern regarding pulmonary function test. ^bP value significance between normal pattern and consolidation pattern according to pulmonary function test. ^cP value significance between B-lines pattern and consolidation pattern regarding pulmonary function test. *Significant.

Figure 1

(a) Lung ultrasound showing the pattern of consolidation in the right infrascapular region. (b) High-resolution computed tomography (HRCT) of the chest showing severe unilateral cystic bronchiectasis, some with air-fluid levels affecting the right middle and lower lobes.

involving the interstitium such as cardiogenic pulmonary edema, pulmonary fibrosis, and ARDS [8].

The pathophysiology of sonographic B-lines has been explained by thickening of the interlobular septae by water in pulmonary edema and by collagen fibers in pulmonary fibrosis which becomes reflected on the lung pleural interface.

This previously described thickening creates a phenomenon of resonance which results from a difference in acoustic impedance between the thickened interstitium and that of the air in the surrounding lung, leading to the appearance of B-lines or 'comet-tail artifacts' [9,10].

We suggest that bronchiectasis has the same pathophysiology where the airway walls are thickened and dilated due to inflammation, peribronchial thickening, and mucus plugging, which are all hallmarks of bronchiectasis; this leads to a difference in acoustic impedance and in turn generation of B-lines defined as (narrow-based laser-

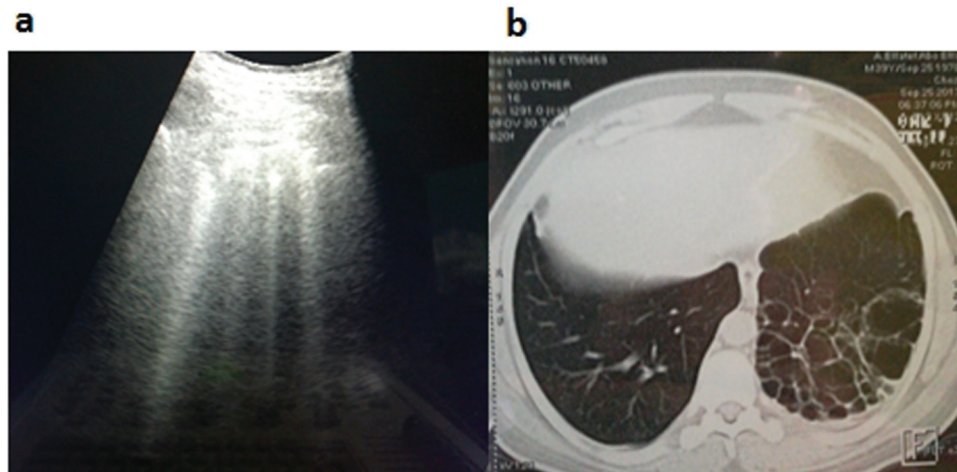
like ray extending from the lung surface to the edge of the screen).

The consolidation pattern was described in only seven (11.5%) patients. Parlamento and colleagues and others have previously reported a high accuracy of lung ultrasound in the diagnosis of lung consolidation in comparison with chest radiograph and HRCT [11–15].

Consolidation seen by lung ultrasound in diseases such as lobar pneumonia, lobar atelectasis, and pulmonary contusion has been explained by loss of lung aeration which leads to the appearance of an echo-poor tissue structure that is wedge shaped and poorly defined, sometimes containing hyperechoic punctiform images representing the air-filled airways 'consolidation' [6].

In this study, all the seven cases presented sonographically with the pattern of consolidation having extensive cystic bronchiectasis characterized by marked loss of aeration, reduced lung tissue,

Figure 2



(a) Lung ultrasound showing a pattern of B-lines in the right infrascapular region. (b) High-resolution computed tomography (HRCT) of the chest showing mild cystic bronchiectasis affecting mainly the left lingula and the left lower lobe.

honeycombing, and three cases with concomitant fibrosis which represent a late irreversible stage of the disease.

In the present study, cases presented with severe cystic forms of bronchiectasis with high mean modified Reiff score (16.71) displayed a consolidation pattern during sonographic examination while cases with lower scores (9.79) took the sonographic pattern of B-lines. Moreover, the 12 patients with a modified Reiff score of less than 5.17 had normal sonography and did not show any abnormality during their examination.

In the present study also, the pattern of consolidation significantly correlated with the lowest measured mean partial pressure of oxygen tension and saturation PO_2 (40.57 mmHg), oxygen saturation (74.57%) which may represent the more advanced and severe forms of bronchiectasis, as well; the B-line pattern significantly correlated with better mean PO_2 (53.35 mmHg) and oxygen saturation (84.11%), most of which represented an early less severe extent form of the disease.

Ooi and colleagues concluded that there were highly significant correlations between FEV_1 and the extent of bronchiectasis, the severity of bronchiectasis, the severity of bronchial wall thickening, and the extent of decreased attenuation on expiration. Very similar relationships ($P < 0.005$) were observed between all four CT variables and other indices of airflow obstruction (negative correlations with FEV_1/FVC , MEF50, MEF25; positive correlations with RV, RV/TLC) [16]. In the current study also, when

analyzing the spirometric pattern of the studied group, a significant correlation was found between the sonographic patterns and the corresponding spirometric pattern, as well as with the radiological score in all studied patients. The wide different pathology of bronchiectasis from inflammatory bronchiolitis as a cause of obstruction to retained secretions as a cause of restriction in bronchiectasis explains the wide variation of sonographic patterns and the corresponding spirometric patterns [17,18].

A limitation of the present study is the small sample size; therefore, additional studies with a larger number of patients representing more different types and degrees of bronchiectasis are required to validate our results. Moreover; the observation and analysis of chest ultrasound signs are subjective and experience dependent; therefore, clear indexes of quantitative interpretation are needed to be established.

Conclusion

Chest ultrasound is a valuable tool for the assessment of bronchiectasis; the pattern of chest ultrasonography [normal pattern, B-line pattern, and c-profile (consolidation) pattern] is correlated not only to the radiological severity defined by type and extent of bronchiectasis, but also to functional impairment assessed by spirometry.

Acknowledgements

The author acknowledges the workers and the nursing staff of the Chest Department at Assiut University Hospitals and everyone shared in the work till the completion of this study.

The abstract was presented as a thematic poster in European Respiratory Society conference in 2015, Amsterdam.

Financial support and sponsorship

Nil.

Conflicts of interest

There are no conflicts of interest.

References

- Volpicelli G. Lung sonography. *J Ultrasound Med* 2013; **32**:165–171.
- Bove T, Oppizzi M, Marino G, Zangrillo A, Margonato A and Picano E. Ultrasound comet-tail images: a marker of pulmonary edema: a comparative study with wedge pressure and extravascular lung water. *Chest J* 2005; **127**:1690–1695.
- Pasteur MC, Helliwell SM, Houghton SJ, Webb SC, Foweraker JE, Coulden RA, *et al.* An investigation into causative factors in patients with bronchiectasis. *Am J Respir Crit Care Med* 2000; **162**:1277–1284.
- Chalmers JD, Mchugh BJ, Doherty C, Smith MP, Govan JR, Kilpatrick DC, *et al.* Mannose-binding lectin deficiency and disease severity in non-cystic fibrosis bronchiectasis: a prospective study. *Lancet Respir Med* 2013; **1**:224–232.
- Reiff DB, Wells AU, Carr DH, Cole Pand Hansell D. CT findings in bronchiectasis: limited value in distinguishing between idiopathic and specific types. *Am J Roentgenol* 1995; **165**:261–267.
- Volpicelli G, Elbarbary M, Blaivas M, Lichtenstein DA, Mathis G, Kirkpatrick AW, *et al.* International evidence-based recommendations for point-of-care lung ultrasound. *Intensive Care Med* 2012; **38**:577–591.
- Piette E, Daoust R, Denault A. Basic concepts in the use of thoracic and lung ultrasound. *Curr Opin Anesthesiol* 2013; **26**:20–30.
- Sayed S, Agmy G, Said A, Kasem A. Assessment of transthoracic sonography in patients with interstitial lung diseases. *Egypt J Bronchol* 2016; **10**:105–112.
- Hasan A, Makhoul H. B-lines: transthoracic chest ultrasound signs useful in assessment of interstitial lung diseases. *Ann Thorac Med* 2014; **9**:99–103.
- Lichtenstein D, MÈziÈre G, Biderman P, Gepner A, BarrÈ O. The comet-tail artifact. *Am J Respir Crit Care Med* 1997; **156**:1640–1646.
- Gehmacher O, Mathis G, Kopf A, Scheier M. Ultrasound imaging of pneumonia. *Ultrasound Med Biol* 1995; **21**:1119–1122.
- Lichtenstein DA, Lascols N, Mezière G, Gepner A. Ultrasound diagnosis of alveolar consolidation in the critically ill. *Intensive Care Med* 2004; **30**:276–281.
- Mathis G, Blank W, Reißig A, Lechleitner P, Reuß J, Schuler A, *et al.* Thoracic ultrasound for diagnosing pulmonary embolism: a prospective multicenter study of 352 patients. *Chest J* 2005; **128**:1531–1538.
- Parlamento S, Copetti R, Di Bartolomeo S. Evaluation of lung ultrasound for the diagnosis of pneumonia in the ED. *Am J Emerg Med* 2009; **27**:379–384.
- Reissig A, Kroegel C. Sonographic diagnosis and follow-up of pneumonia: a prospective study. *Respiration* 2007; **74**:537–547.
- Ooi GC, Khong PL, Chan-Yeung M, Ho JC, Chan PK, Lee JC, *et al.* High-resolution CT quantification of bronchiectasis: clinical and functional correlation. *Radiology* 2002; **225**:663–672.
- Landau L, Phelan P, Williams H. Ventilatory mechanics in patients with bronchiectasis starting in childhood. *Thorax* 1974; **29**:304–312.
- Kang EY, Miller R, Müller NL. Bronchiectasis: comparison of preoperative thin-section CT and pathologic findings in resected specimens. *Radiology* 1995; **195**:649–654.