

# Enormous thymolipoma: A case report

Hoda A. Eid<sup>a</sup>, Ahmed E. Ali<sup>b</sup>, Mohamed A. Elsabry<sup>b</sup>

Thymolipoma is unusual benign mediastinal, slow-growing, encapsulated tumor of the anterior mediastinum with no tendency to recur after a complete surgical excision. Here, we report the case of an adult female who presented with progressive dyspnea of 2 months' duration especially on lying down. Chest radiograph showed opacity occupying the entire left side. Computed tomography of the chest revealed a large mass on the left side with fat attenuation. Computed tomography-guided biopsy obtained was diagnosed as hyperplastic thymic tissue. The tumor was successfully removed surgically, and histopathological examination confirmed thymolipoma.

*Egypt J Bronchol* 2017 11:165–167

© 2017 Egyptian Journal of Bronchology

*Egyptian Journal of Bronchology* 2017 11:165–167

**Keywords:** mediastinum mass, thymic neoplasm, thymolipoma

<sup>a</sup>Chest Department, <sup>b</sup>Cardiothoracic Department, Faculty of Medicine for Girls, Al Azhar University, Cairo, Egypt

Correspondence to Hoda A. Eid, MD, Chest Disease Department, Al-Zahraa University Hospital, Abbaseya 11517 Cairo, Egypt; Tel: +2026854947; fax: +20222638357; E-mail: asaadhoda7@gmail.com

The abstract was presented at the Al-Azhar Grand Round in February 2016, Cairo, Egypt.

**Received** 13 June 2016 **Accepted** 8 July 2016

## Introduction

Thymolipoma accounts for 2–9% of all thymic neoplasm, composed of mature adipose tissue and benign thymic tissue. The majority of these tumors are clinically quiescent; however, they may reach large dimensions and manifest themselves clinically with compression of adjacent structures. Complete surgical excision is curative [1].

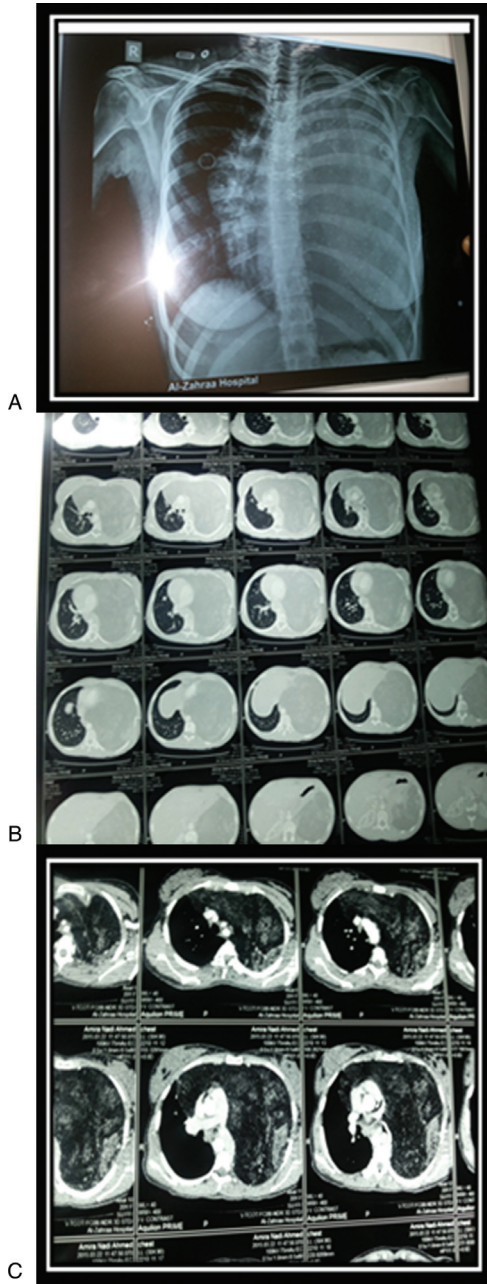
## Case report

A 21-year-old female patient presented to the hospital with complains of gradually progressive dyspnea of 2 months' duration associated with productive cough. The patient had no history of hemoptysis, loss of weight, loss of appetite, or other constitutional symptoms. Clinically, there was no abnormality detected on general examination. Local examination revealed limitation in chest movement with a decrease in Tactile vocal fremitus (TVF) on the entire left side. On percussion, there was dullness all over the left side, 2, 3, 4, 5 at right midclavicular line and bare area. Chest auscultation detected decreased breath sounds on the left side. Routine blood investigations were within normal limits. A chest radiograph revealed an opacity occupying the entire hemithorax and shifting mediastinum to opposite side (Fig. 1a). A computed tomography scan of the thorax revealed a large mass occupying the entire left side with fat attenuation (–80 to –120 HU) compressing and shifting mediastinal structures to the opposite side (Fig. 1b). Spirometry confirmed the presence of a restrictive defect. Chest ultrasound showed that the echoes in the mass were homogeneous but of higher intensity than those of

liver parenchyma with no effusion. Ultrasound-guided tru-cut biopsy was performed, and pathological examination for core biopsy showed lymphoid infiltrate. Flexible bronchoscopy was performed and reported narrowing of the main, lobar, and segmental bronchi (slit like) with intact healthy mucosa. Computed tomography-guided biopsy detected hyperplastic thymic tissue. The patient was referred to the cardiothoracic department. Posterolateral thoracotomy incision (fifth intercostal space) was made. A very large (giant), soft, well-defined, encapsulated mass of about 5 kg, with smooth surface occupying the whole left hemithorax, originating from the thymus gland without any invasion to the adjacent structures, was noticed. Manipulation of the mass was very difficult and so we could not remove it as one structure. Its capsule was opened by means of diathermy and the mass was removed in pieces. Thereafter, we excised the thymus gland with the mass capsule; after mass removal the secondary hypoplastic lung was another problem. We tried to reduce cavity space with positive ventilation of the lung, sixth rib excision, and ablation of the left phrenic nerve. Physiotherapy was started on the first postoperative day with incentive spirometry and exercise training, with oxygen therapy, and applying low suction on chest drains, and follow-up with clinical examination and chest radiography daily was carried out. The diagnosis was confirmed

This is an open access article distributed under the terms of the Creative Commons Attribution-NonCommercial-ShareAlike 3.0 License, which allows others to remix, tweak, and build upon the work noncommercially, as long as the author is credited and the new creations are licensed under the identical terms.

Figure 1



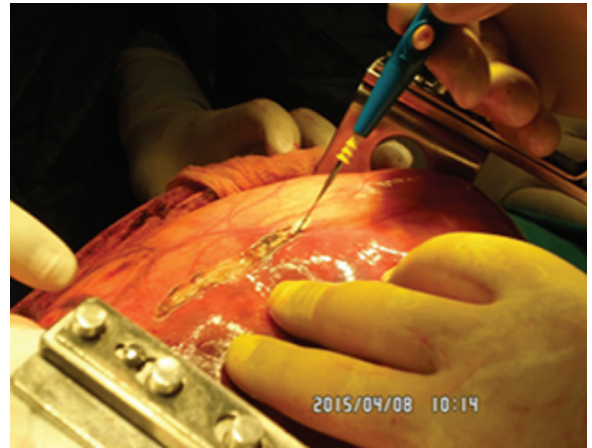(a) Plain radiograph of the chest P-A view. (b) Computed tomography (lung window). (c) Computed tomography (mediastinal window).

by histopathological examination as thymolipoma. Ten-month postoperative, the lung filled the pleural cavity and the residual space improved (Figs. 2–5).

**Discussion**

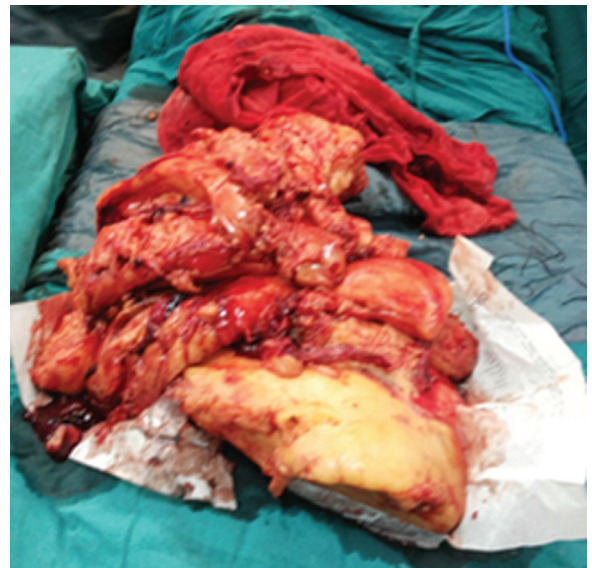
Thymolipoma is a rare condition with an incidence of about 0.12 cases per 100 000 per year. The first case of a thymolipoma was reported by Lange in 1916 [2]. It appears as a mass composed of mature adipose tissue and benign thymic tissue. The thymic tissue component in thymolipomas

Figure 2



Mass capsule.

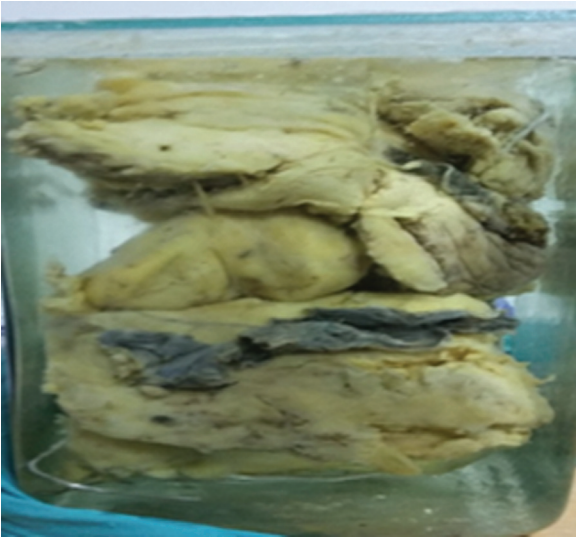Figure 3



Excised mass.

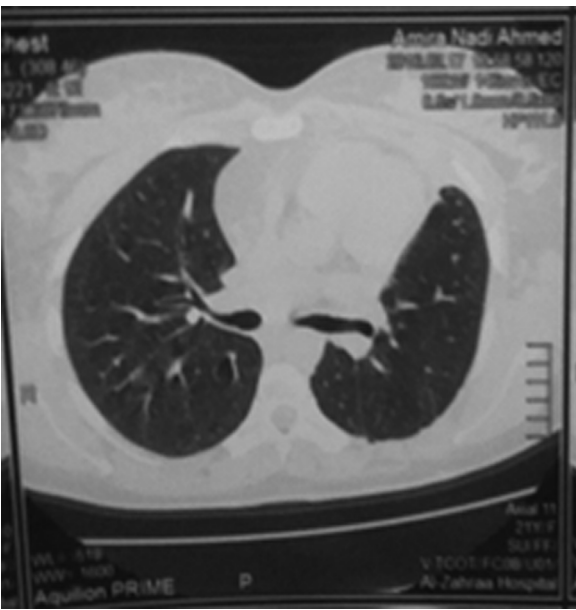is separated by large amounts of mature fat, with no atypia and no mitotic activity. There is no recognized sex predilection. Reported age range is between 3 and 6 years, with a mean age of 22 years [1]. The radiologic features can mimic several conditions, including cardiomegaly, pleural tumors, pericardial effusion, pericardial tumors, basal atelectasis, and pulmonary sequestration. The majority of these tumors are clinically quiescent; however, they may reach large dimensions and manifest themselves clinically by compression of adjacent structures [3]. The pathogenesis of thymolipomas has not been elucidated. Some theories suggest that it is a variant of a thymoma, or hyperplasia of mediastinal fat, or neoplasm of mediastinal fat, which engulfs thymic tissue and

Figure 4



Jar of excised mass.

Figure 5



Cut of computed tomography (CT) of the chest (after 10 months).

thymic hamartoma; however, the most interesting theory is that a thymolipoma represents a benign tumor of specialized thymic stroma (fat), arising in relationship to the thymic epithelium. [4]. Thymolipomas can occasionally be associated with myasthenia gravis. Histopathological examination revealing admixture of mature adipose tissue and microscopically normal thymus tissue with Hassal's corpuscles is diagnostic [5]. Surgically local resection is curative. There are no reports of recurrence, metastasis, or mortality.

### Conclusion

It is important to consider mediastinal tumors in the differential diagnosis of patients presenting with progressive dyspnea without any apparent cardiac illness but chest radiograph showing enlarged cardiac silhouette [6].

### Financial support and sponsorship

Nil.

### Conflicts of interest

There are no conflicts of interest.

### References

- 1 Ringe B, Dragojevic D, Frank G, Borst HG. Thymolipoma – a rare, benign tumor of the thymus gland, two case reports and review of the literature. *Thorac Cardiovasc Surg* 1979; **27**:6.
- 2 Damadoglu E, Salturk C, Takir HB, Ertugrul M, Yilmaz A, Atasalihi A, Yilmaz A. Mediastinal thymolipoma: an analysis of 10 cases. *Respirology* 2007; **12**:924–927.
- 3 Teplick JG, Nedwich A, Haskin ME. Roentgenographic features of thymolipoma. *Am J Roentgenol Radium Ther Nucl Med* 1973; **117**: 873–880.
- 4 Toyama T, Mizuno T, Masaoka A, Shibata K, Yamakawa Y, Niwa H, Torii K. Pathogenesis of thymolipoma: report of three cases. *Surg Today* 1995; **25**:86–88.
- 5 Moran CA, Rosado-de-Christenson M, Suster S. Thymolipoma: clinicopathologic review of 33 cases. *Mod Pathol* 1995; **8**:741–744.
- 6 Mohan Rao PS, Moorthy N, Shankarappa RK, Bhat P, Nanjappa MC. Giant mediastinal thymolipoma simulating cardiomegaly. *J Cardiol* 2009; **54**: 326–329.