

Role of chest ultrasonography in differentiating between acute cardiogenic pulmonary edema and acute respiratory distress syndrome

Taher El-Naggar^a, Samar H. Sharkawy^a, Hossam Mohamed Abdel-Hamid^a, Haitham S. El-Din Mohamad^a, Rasha Mustafa A. Mohamed^b

Introduction Sometimes it is difficult to differentiate between acute cardiogenic pulmonary edema (APE) and acute respiratory distress syndrome (ARDS) on clinical basis only. Chest ultrasonography (CUS) may be helpful in providing ultrasonographic pleuropulmonary signs, which aids in such differentiation.

Aim The aim of this study was to evaluate the role of CUS in differentiating between ARDS and APE through the characterization of comparative peculiar ultrasonographic pleuropulmonary signs.

Patients and methods On admission, CUS was performed in Ain Shams University Hospital and Al-Abbassia Chest Hospital ICUs on 28 consecutive patients who presented with ARDS (15 cases) or APE (13 cases). CUS examination focused on the detection of the following pleuropulmonary signs in both ARDS and APE: alveolar–interstitial syndrome (AIS), pleural line abnormalities, absent or reduced lung sliding, consolidation, and pleural effusion.

Results AIS was found in 100% of patients with ARDS and in 100% of patients with APE. Pleural line abnormalities were observed in 100% of patients with ARDS and in 0% of patients with APE ($P=0.001$). Absent or reduced lung sliding was observed in 100% of patients with ARDS and in 0% of patients with APE ($P=0.001$). Consolidations were present in 93.3% of

patients with ARDS in 7.5% of patients with APE ($P=0.001$). Pleural effusion was present in 40% of patients with ARDS and in 76.9% of patients with APE ($P=0.049$).

All pleuropulmonary signs, except the presence of AIS, presented a statistically significant difference in presentation between ARDS and APE, resulting peculiar ultrasonographic pleuropulmonary signs of ARDS.

Conclusion CUS represents a useful tool for differentiating ARDS from APE in ICU patients. In fact, the presence of absent or reduced lung sliding, pleural line abnormalities, and lung consolidations on a background of AIS seems diagnostic of ARDS.

Egypt J Bronchol 2016 10:319–323

© 2016 Egyptian Journal of Bronchology

Egyptian Journal of Bronchology 2016 10:319–323

Keywords: acute cardiogenic pulmonary edema, acute respiratory distress syndrome, chest ultrasonography

^aDepartment of Chest Diseases, Faculty of Medicine, Ain Shams University, Egypt, ^bAl Abbassia Chest Hospital, Abbassia Nasr City, Cairo, Egypt

Correspondence to Rasha Mustafa A. Mahamad, MSc, MBBCh, Flat 4, 4 El Qalaa Street, 11636 Cairo, Egypt, Tel: +20 114 411 6660
E-mail: rashacheeko@yahoo.com

Received 5 August 2016 **Accepted** 6 August 2016

Introduction

Rapid and accurate identification of thoracic emergencies may be a challenging task to pulmonary critically ill physicians. Traditionally, relying on historical and physical examination findings in the preliminary differential diagnosis of acute respiratory distress may be unreliable. Thus, sometimes it is difficult to differentiate between acute cardiogenic pulmonary edema (APE) and acute respiratory distress syndrome (ARDS) [1–3].

A new definition of ARDS, the Berlin definition, has been published. ARDS is an acute diffuse, inflammatory lung injury, leading to increased pulmonary vascular permeability, increased lung weight, and loss of aerated lung tissue with hypoxemia and bilateral radiographic opacities, associated with increased venous admixture, increased physiological dead space, and decreased lung compliance [4].

Chest ultrasonography (CUS) is increasingly used in the management of ICU patients [5,6]. CUS has a higher diagnostic accuracy for pleural effusion, consolidation, and interstitial syndrome when compared with bedside

chest radiography in patients with ARDS [7]. Different studies have addressed the ultrasonographic appearance of ARDS, but few studies have been able to give a detailed characterization of the syndrome, permitting a differential diagnosis from the ultrasonographic appearance of APE [2].

This study aimed to evaluate the role of CUS in differentiating between ARDS and APE through the characterization of comparative peculiar ultrasonographic pleuropulmonary signs.

Patients and methods

This prospective study was conducted in the Respiratory ICU of Ain Shams University Hospital and Al-Abbassia Chest Hospital during the period between December 2013 and December 2014 and consecutive patients admitted and fulfilling Berlin ARDS definition and

This is an open access article distributed under the terms of the Creative Commons Attribution-NonCommercial-ShareAlike 3.0 License, which allows others to remix, tweak, and build upon the work noncommercially, as long as the author is credited and the new creations are licensed under the identical terms.

diagnostic criteria of ARDS were recruited [4]. In addition, patients consecutively admitted with the diagnosis of APE on the basis of clinical signs and symptoms, ECG, chest radiography, and echocardiography (not in all cases) were also included in the study.

As CUS is now part of routine diagnostic procedures in our unit, no informed consent or approval of ethics committee was requested.

All patients underwent CUS on the first day of admission and after being diagnosed based on clinical and radiological data. A convex (curvilinear) probe operates at a frequency between 2 and 8 MHz and a linear probe operates at a frequency of 5–10 MHz [Sonoline G20 Ultrasound Imaging System (Siemens, Mountain View, California, USA) at Al-Abbassia Chest Hospital and Mindray M5 (Mindray M5Bio-Medical Electronics Co., Shenzhen, China) at Respiratory ICU, Ain Shams University Hospital] were used for lung examination.

The examination was performed at patient bedside. Lateral or seated positions were used to scan the posterior thorax. In patients in whom the seated position was not possible, a lateral decubitus position was used to examine posterior lung regions [2]. Probes were placed horizontally and/or vertically along each intercostal space (the parasternal line, anterior axillary line, and posterior axillary line) on both sides. Data were displayed on a screen. Each hemithorax should be divided into five zones: two anterior zones separated by the third intercostal space, two lateral zones, and one posterior zone [8].

For each echographic acquisition, we investigated the following four ultrasonographic markers:

- (1) Lung gliding or sliding was defined as evidence of pleural movement; lung gliding presence indicates a pulmonary region in contact with the thoracic wall and excludes pneumothorax [9].
- (2) A lines, defined as horizontal reverberation (transduce reverberation), reflect the pleural line in depth; the presence of A lines is a normal finding [9].
- (3) Ultrasound lung comets or B lines, defined as ring down, vertical reverberation, extend to the inferior margin of the screen, masking A lines. They define interstitial syndrome (pulmonary edema and interstitial disease) [9].
- (4) Alveolar syndrome, defined as organization (hepatization) of the pulmonary field with a

solid appearance, can sometimes show evidence of aerated bronchi (air bronchogram), which, when present, indicates a consolidation or a partially aerated alveolar syndrome [10].

Chest ultrasonography pleuropulmonary finding characteristics

- (1) Alveolar–interstitial syndrome (AIS) is defined as the presence of more than three ultrasound lung comet means (B lines) or ‘white lung’ appearance for each examined area [2].
- (2) Pleural line abnormalities are defined as thickenings greater than 2 mm, evidence of small subpleural consolidations, or coarse appearance of the pleural line; its presence means that a process, either consolidations or inflammatory process, is present as in cases of ARDS, and its absence means acute process is present as in APE [2].
- (3) Areas with absent or reduced ‘sliding’ sign with respect to adjacent or contralateral zones at the same level on the opposite hemithorax [2].
- (4) Consolidations are defined as areas of hepatization (tissue pattern) with the presence of air bronchograms [2].
- (5) Pleural effusion, which appeared as anechoic areas limited by diaphragm and the costal pleura [10].

Statistical analysis

The collected data were revised, coded, tabulated, and introduced into a PC using statistical package for the social sciences (SPSS 15.0.1 for Windows, 2001; SPSS Inc., Chicago, Illinois, USA). Descriptive statistics was performed and parametric numerical data were presented as mean±SD and range, whereas as median and interquartile range for nonparametric numerical data. Non-numerical data were presented as frequency and percentage. Analytical statistics was performed and Student’s *t*-test was used to assess the statistical significance of the difference between two study group means. The χ^2 -test was used to examine the relationship between two qualitative variables. Fisher’s exact test was used to examine the relationship between two qualitative variables when the expected count is less than 5 in more than 20% of cells. A *P* value of more than 0.05 was considered as nonsignificant, *P* value of less than 0.05 as significant, and *P* value of less than 0.01 as highly significant.

Results

The study included 28 patients. Fifteen met the criteria for the diagnosis of ARDS and 13 had APE.

There were 13 (46%) male and 15 (54%) female patients. The demographic characteristics of studied patients are shown in Table 1.

Comparison between ARDS and APE cases as regards ultrasonographic findings are shown in Table 2. AIS was present in all of our study populations (ARDS and APE), indicating its high sensitivity in the diagnosis of increased extravascular lung water. AIS of ARDS appear dyshomogeneous, whereas that of APE appears homogeneous. All other ultrasonography signs presented a statistically significant difference in presentation between the two groups.

Figures 1–4 show different ultrasonographic findings in ARDS and APE patients.

The sensitivity and specificity of each ultrasonographic sign in ARDS and APE, respectively, are illustrated in Tables 3 and 4.

Discussion

This study demonstrated the ability of CUS in the identification of characteristic pleuropulmonary signs useful in the diagnosis of ARDS and APE. The presence of ultrasonographic pleuropulmonary

signs of dyshomogeneous AIS, such as absent or reduced lung sliding, pleural line abnormalities, and lung consolidations, is strongly predictive of ARDS diagnosis.

Standard chest radiograph is still performed in the assessment of patients presenting with ARDS. Chest radiograph interpretation is unreliable and compares poorly with computed tomography (CT) scanning in patients with ARDS [4,11]. Chest CT scanning use has led to a better understanding, diagnosis, and management of ARDS. CT scanning allows understanding that alveolar filling, consolidation, and atelectasis occur predominantly in dependent lung zones, whereas other areas may be relatively spared with nonuniformity of degree of lung injury severity in different lung areas [12,13]. CT scanning has disadvantages in ARDS assessment, such as the high dose of radiation exposure to the patient, being expensive, the need to move the patient into the radiology room, and the lack of CT scanning in some hospitals [14].

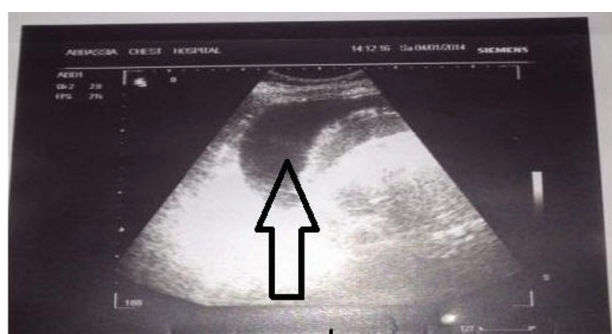
The benefits of ultrasonography use in pulmonary critically ill patients is that it is rapid, noninvasive, inexpensive, portable, and nonirradiating tool. CUS became a very important diagnostic tool nowadays [15].

Table 1 Demographic characteristics of study population

	ARDS (n=15)	APE (n=13)
Age (mean±SD) (years)	47.32±16.20	47.32±16.20
Sex (male/female)	6/9	6/7
Cause of disease etiology	Pneumonia (7 patients) Malignancy (2 patients) Suppurative lung diseases (3 patient) Structural lung disease (1 patient) Collagen diseases (1 patient) Alveolar proteinosis (1 patient)	Ischemic heart disease (2 patients) Cardiomyopathy (8 patients) Rheumatic heart disease (1 patient) Hypertensive pulmonary edema (1 patient) Arrhythmias (1 patient)
Mechanical ventilation	10 patients	4 patients

APE, acute cardiogenic pulmonary edema, ARDS, acute respiratory distress syndrome.

Figure 1



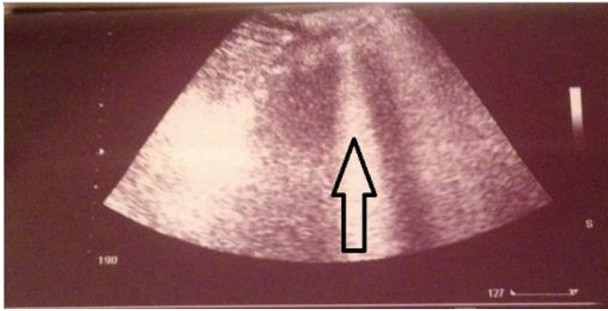
(arrow) indicates Pleural effusion detected in both groups.

Table 2 Comparison between acute respiratory distress syndrome and acute cardiogenic pulmonary edema cases as regards ultrasonographic findings

	ARDS (N=15) [N (%)]	APE (N=13) [N (%)]	P
AIS	15 (100)	13 (100)	NS
Pleural line abnormalities	15 (100)	0 (0)	0.001
Absent or reduced lung sliding	15 (100.0)	0 (0)	0.001
Consolidation	14 (93.3)	1 (7.7)	0.001
Pleural effusion	6 (40.0)	10 (76.9)	0.049

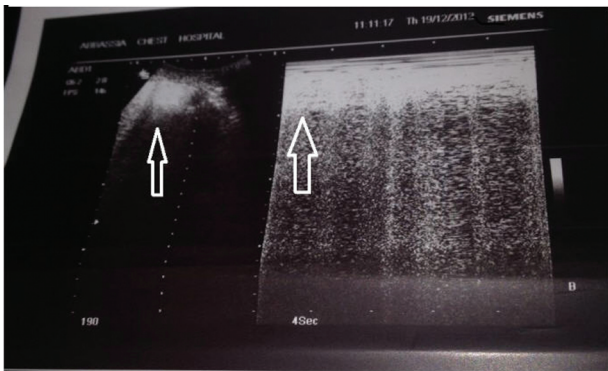
AIS, alveolar–interstitial syndrome; APE, acute cardiogenic pulmonary edema; ARDS, acute respiratory distress syndrome.

Figure 2



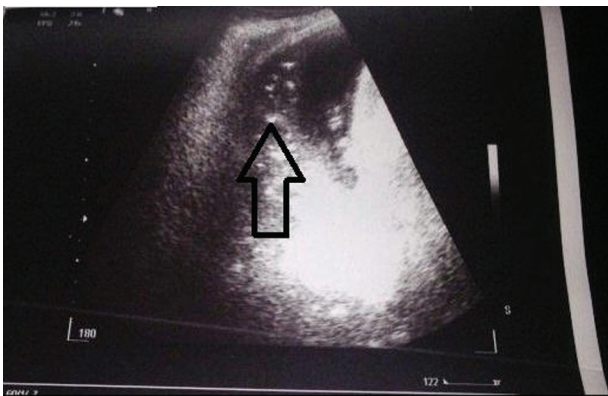
B lines (arrow) indicating alveolar-interstitial syndrome.

Figure 3



Arrows show Pleural line abnormalities.

Figure 4



Arrow indicates Lung consolidation with air bronchogram in ARDS.

As regards ARDS, it is sometimes difficult to be differentiated from APE. This study searched for characteristic ultrasonographic pleuropulmonary signs helpful in the differentiation between ARDS and APE.

It has been previously stated that ultrasonographic signs of AIS is a marker of pulmonary edema being present both in acute lung injury (ALI) or ARDS and APE patients [8]. In the present study, both ARDS and APE patients had AIS, which is diffuse B-line profile. This is in agreement with the study by Copetti *et al.* [2] on 58 patients fulfilling

Table 3 Sensitivity and specificity of each ultrasonographic signs in acute respiratory distress syndrome

	Sensitivity (%)	Specificity (%)	PPV (%)	NPV (%)	Accuracy (%)
Pleural line abnormalities	100	100	100	100	100
Absent or reduced lung sliding	100	100	100	100	100
Consolidation	93.3	92.3	93.3	92.3	92.8
Pleural effusion	40.0	23.1	37.5	25	32.1

NPP, negative predictive value; PPV, positive predictive value.

Table 4 Sensitivity and specificity of each ultrasonographic signs in acute cardiogenic pulmonary edema

	Sensitivity (%)	Specificity (%)	PPV (%)	NPV (%)	Accuracy (%)
Pleural line abnormalities	0	0	0	0	0
Absent or reduced lung sliding	0	0	0	0	0
Consolidation	7.7	6.7	6.6	7.7	7.2
Pleural effusion	76.9	60	62.5	75	67.9

NPP, negative predictive value; PPV, positive predictive value.

criteria for either ALI/ARDS (18 cases) or APE (40 cases), which revealed diffuse B lines in all patients (2). Similar findings were reported by Zanobetti *et al.* [3], who studied 404 patients presented to the ED with dyspnea independently from the underlying disease. They compared CUS findings in some diseases in relation to chest radiography. They found that the presence of diffuse B-line profile was the characteristic ultrasonographic pattern of diffuse AIS, which is often a sign of APE. Moreover, this is in agreement with study by Daabis *et al.* [16], who studied 100 ICU patients presenting with acute respiratory failure. ARDS was present in 10 cases. They compared CUS with current diagnostic tools for diagnosing the etiology of acute respiratory failure. They found characteristic ultrasound B profile in all of the ARDS cases [16].

In the current study, characteristic ultrasonographic signs of consolidation were found in 53.6% of cases, which was nearly comparable to that reported by Zanobetti *et al.* [3], who found that consolidation was found in 60% of cases. On comparing between noncardiogenic (ARDS) and cardiogenic (APE) origin of consolidation, the present study found that consolidation was seen in 93.3% of ARDS and never seen in APE (0%). This correlated with the study by Copetti *et al.* [2], who found that lung consolidation was seen in 83.3% of cases of ARDS in comparison with 0% of cases of APE.

Pleural effusions were more frequently seen in APE than in ARDS. Similar results were reported by Copetti *et al.* [2] and Kataoka *et al.* [17]. Thus, their presence cannot be relied on solely for differential diagnosis.

Absence or reduced lung sliding and pleural line abnormalities seem peculiar for ARDS with sensitivity and specificity for both signs 100% in the current study. This is comparable to the findings of Copetti *et al.* [2], who studied 58 consecutive ICU patients affected by ALI/ARDS or APE. Reduction or absence of lung sliding was observed in 100% of patients with ALI/ARDS and in 0% of patients with APE, whereas pleural line abnormalities were observed in 100% of patients with ALI/ARDS and in 25% of patients with APE [2].

There was a statistically significant difference between ultrasonographic pleuropulmonary signs, except the presence of AIS, detected in current study between the ARDS and APE, leading to peculiar ultrasonographic characterization of ARDS. Similar results and peculiar sonographic signs were reported by Copetti *et al.* [2].

On the basis of the sensitivity and specificity of ultrasonographic pleuropulmonary signs detected in ARDS patient, peculiar findings for ARDS is reached. In case of AIS, the presence of absent or reduced lung sliding, pleural line abnormalities, and lung consolidations is strongly predictive of ARDS.

Small sample size, lack of echocardiography validation in all cases for APE diagnosis, and lack of CT scanning for verification of findings are the apparent limitations for current study.

Future studies comparing CUS-specific ultrasonographic findings with CT are needed to validate our results. This validation may limit CT use in ICU.

Conclusion

Our results demonstrate that CUS represents a useful tool for differentiating ARDS from APE in critically ill ICU patients. In fact, the presence of absent or reduced lung sliding, pleural line abnormalities, and lung consolidations on a background of AIS seems diagnostic of ARDS.

Financial support and sponsorship

Nil.

Conflicts of interest

There are no conflicts of interest.

References

- 1 Wang CS, FitzGerald JM, Schulzer M, Mak E, Ayas NT. Does this dyspneic patient in the emergency department have congestive heart failure? *JAMA* 2005; **294**(15):1944–1956.
- 2 Copetti R, Soldati G, Copetti P. Chest sonography: a useful tool to differentiate acute cardiogenic pulmonary edema from acute respiratory distress syndrome. *Cardiovasc Ultrasound* 2008; **6**:16.
- 3 Zanobetti M, Poggioni C, Pini R. Can chest ultrasonography replace standard chest radiography for evaluation of acute dyspnea in the ED?. *Chest* 2011; **139**(5):1140–1147.
- 4 Ranieri VM, Rubenfeld GD, Thompson BT, Ferguson ND, Caldwell E, Fan E, *et al.* ARDS Definition Task Force Acute respiratory distress syndrome: the Berlin Definition. *JAMA* 2012; **307**(23):2526–2533.
- 5 Bouhemad B, Zhang M, Lu Q, Rouby JJ. Clinical review: Bedside lung ultrasound in critical care practice. *Crit Care* 2007; **11**(1):205
- 6 Lichtenstein DA, Mezière GA. Relevance of lung ultrasound in the diagnosis of acute respiratory failure: the BLUE protocol. *Chest* 2008; **134**(1):117–125.
- 7 Lichtenstein D, Goldstein I, Mourgeon E, Cluzel P, Grenier P, Rouby JJ. Comparative diagnostic performances of auscultation, chest radiography, and lung ultrasonography in acute respiratory distress syndrome. *Anesthesiology* 2004; **100**(1):9–15.
- 8 Volpicelli G, Mussa A, Garofalo G, Cardinale L, Casoli G, Perotto F, *et al.* Bedside lung ultrasound in the assessment of alveolar-interstitial syndrome. *Am J Emerg Med* 2006; **24**(6):689–696.
- 9 Lichtenstein DA, Mezière GA, Lagoueyte JF, Biderman P, Goldstein I, Gepner A. A-lines and B-lines: lung ultrasound as a bedside tool for predicting pulmonary artery occlusion pressure in the critically ill. *Chest* 2009; **136**(4):1014–1020.
- 10 Lichtenstein D. Lung ultrasound in the critically ill. *Clin Intensive Care* 2005; **16**:79–87.
- 11 Figueroa-Casas JB, Brunner N, Dwivedi AK, Ayyappan AP. Accuracy of the chest radiograph to identify bilateral pulmonary infiltrates consistent with the diagnosis of acute respiratory distress syndrome using computed tomography as reference standard. *J Crit Care* 2013; **28**(4):352–357.
- 12 Gattinoni L, Caironi P, Pelosi P, Goodman LR. What has computed tomography taught us about the acute respiratory distress syndrome? *Am J Respir Crit Care Med* 2001; **164**(9):1701–1711.
- 13 Gattinoni L, Caironi P, Cressoni M, Chiumello D, Ranieri VM, Quintel M, *et al.* Lung recruitment in patients with the acute respiratory distress syndrome. *N Engl J Med* 2006; **354**(17):1775–1786.
- 14 Pesenti A, Tagliabue P, Patroniti N, Fumagalli R. Computerised tomography scan imaging in acute respiratory distress syndrome. *Intensive Care Med* 2001; **27**(4):631–639.
- 15 Liteplo AS, Marill KA, Villen T, Miller RM, Murray AF, Croft PE, *et al.* Emergency thoracic ultrasound in the differentiation of the etiology of shortness of breath (ETUDES): sonographic B-lines and N-terminal pro-brain-type natriuretic peptide in diagnosing congestive heart failure. *Acad Emerg Med* 2009; **16**(3):201–210.
- 16 Daabis R, Banawan L, Rabae A, Elnakedy A, Sadek A. Relevance of chest sonography in the diagnosis of acute respiratory failure. *Egypt J Chest Dis Tuberc* 2014; **63**:979–985.
- 17 Kataoka H, Takada S. The role of thoracic ultrasonography for evaluation of patients with decompensated chronic heart failure. *J Am Coll Cardiol* 2000; **35**(6):1638–1646.