

Can chest ultrasonography differentiate between benign and malignant effusions?

Wafaa A. Hassan, Atef F. Alkarn, Mahmoud Kamel

Background The differential diagnosis of exudative pleural effusion is a major challenge for chest physicians particularly in a country with limited financial resources.

Objective The aim of this study was to evaluate the role of the sonographic features in the prediction of exudative malignant pleural effusion.

Design This was a prospective cross-sectional study.

Setting This study was carried out between May 2013 and June 2014 in the Chest Department of Assiut University Hospital.

Patients The patients enrolled included 25 patients with malignant pleural effusion and 25 patients with other different benign causes.

Main outcome measures The sonographic appearances of pleural effusions were defined in terms of five patterns: anechoic, complex septated, complex nonseptated, pleural thickening, and pleural nodules.

Results Among the 25 malignant exudative pleural effusions, a complex nonseptated pattern is a useful diagnostic predictor, with sensitivity, specificity, positive

predictive value, and negative predictive value of 60, 68, 65, and 63%, respectively. Pleural nodules were only found in malignant effusion (100% specificity). If we define the complex septated sonographic pattern as a predictor for benign effusion, we can achieve sensitivity, specificity, positive predictive value, and negative predictive value of 52, 88, 81, and 65%, respectively.

Conclusion Pleural nodules and a complex nonseptated pattern in the sonographic appearance are useful predictors of malignant pleural effusions, whereas a complex septated pattern is a useful predictor in nonmalignant effusion. *Egypt J Broncho* 2015 9:165–169

© 2015 Egyptian Journal of Bronchology.

Egyptian Journal of Bronchology 2015 9:165–169

Keywords: malignant effusion, pleural nodules, septations, sonography

Department of Chest Diseases, Assiut University Hospital, Assiut University, Assiut, Egypt

Correspondence to Wafaa A. Hassan, MD, Department of Chest Diseases, Assiut University Hospital, Assiut University, PO Box (1), 71111 Assiut, Egypt
Tel: 01006368362; fax: +20 088 2368377;
e-mail: atef_darwish@yahoo.com

Received 20 January 2015 **Accepted** 07 March 2015

Introduction

Pleural effusion is a highly common clinical presentation in malignant and benign diseases. The differential diagnosis is broad and includes heart failure, parapneumonic effusion, empyema, pulmonary emboli, inflammatory disease, and malignancies. The differentiation between malignant and nonmalignant pleural effusions has often been made with cytologic examinations of pleural effusions, histologic examinations of pleural biopsies, helpful biomarkers, and even pleural biopsy [1–3].

With the advances in imaging technology and computerized functions, the chest sonographic examination has been used widely in the diagnosis and management of lung cancer, uncommon pulmonary consolidations, mediastinal tumors, and pleural diseases. Chest sonography is a very useful imaging tool for assessing the nature of pleural effusions [4].

Aim of the work

The aim of this study was to evaluate the role of the sonographic features in the prediction of malignant pleural effusion.

Patients and methods

We prospectively recruited patients with the diagnosis of malignant and nonmalignant exudative pleural effusion from May 2013 to June 2014. The study was approved by the ethical committee of Assiut University. A total of 25 patients with malignant pleural effusion and 25 patients with nonmalignant exudative pleural effusion were enrolled. There were 32 men and 18 women whose ages ranged from 23 to 75 years (mean 49 years).

All patients included in the study were subjected to the following:

- (1) Full assessment of medical history and clinical examination.
- (2) Complete blood count, blood urea and serum creatinine, liver, and renal function tests.
- (3) Radiological examination: chest radiography and multislice computer tomographic scan of the chest whenever needed.
- (4) Sputum cytology for the detection of inflammatory or malignant cells.
- (5) Diagnostic thoracentesis; about (300–500 ml) of pleural fluid was aspirated for the following:
 - (a) Chemical examination including protein level and lactate dehydrogenase level.

- (b) Total and differential cell count and adenosine deaminase if tuberculosis was suspected.
- (c) Bacteriological examination.
- (d) Cytological examination for malignant cells.
- (6) Pathological examination of the specimens obtained by bronchoscopy, closed pleural biopsy, thoracoscopy, or lymph node biopsy.
- (7) Other relevant investigations to make a final diagnosis.

Procedure of chest ultrasound

A real-time ultrasound scanner, high-resolution linear probe was used to provide a description of chest wall, pleura, and lung. Pictures were saved in a JPG format. The size of effusion was assessed by posteroanterior chest radiograph. Pleural effusions were defined as minimal if they occupied less than 1/3 of the hemithorax, moderate if they occupied more than 1/3 and less than 2/3 of the hemithorax, and massive if they occupied more than 2/3 of the hemithorax.

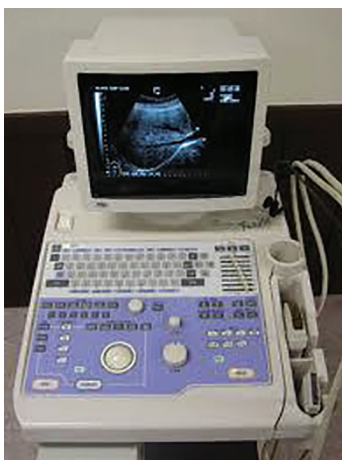Chest sonographic examination, and sonographic appearances

All patients underwent chest sonographic examination with the Aloka ultrasound machine in the Chest Department of Assiut University Hospital (Figs 1 and 2).

Sonographic appearances were classified as follows:

- (1) Anechoic pattern (no echogenicity in the effusion).
- (2) Complex septated pattern (hyperechoic stands within the effusion).
- (3) Complex nonseptated pattern (internal echoes moving in fluid).
- (4) Pleural nodules: in parietal, visceral, or diaphragmatic pleura.
- (5) Pleural thickening: in parietal, visceral, or diaphragmatic pleura.

Fig. 1



Aloka ultrasound machine.

Statistical analysis

Sonographic appearances of each group were categorized and analyzed for comparison between each of them. Statistical analysis of the data was carried out using the SPSS 16 software package under (SPSS 16, IPM, Chicago, USA) the Windows7 operating system. Categorical data parameters were presented as frequency and percent. Quantitative data were expressed as mean and SD. Comparison was performed using the Z-test and χ^2 for categorical data and a paired *t*-test for quantitative data. Probability level (*P*-value) was assumed to be significant if it was equal to or less than 0.05 and highly significant if the *P*-value was equal to or less than 0.001.

Results

Twenty-five patients with malignant pleural effusions and 25 patients with nonmalignant pleural effusions were enrolled in our series. The underlying diseases, of nonmalignant pleural effusion, included empyema [$n=9$ (36%)], tuberculosis [$n=6$ (24%)], parapneumonic [$n=6$ (24%)], and pulmonary embolism [$n=4$ (16%)]. In malignant effusion, metastatic adenocarcinoma was the most common [$n=17$ (68%)], followed by mesothelioma [$n=6$ (24%)], and poorly differentiated nonsmall cell, large cell carcinoma in one case for each type [$n=2$ (8%)]. On assessment of the amount of pleural effusions, there were massive pleural effusions in most of the malignant effusion [$n=18$ (72%)] (Tables 1 and 2).

Sonographic patterns between malignant and nonmalignant pleural effusions

As shown in Table 3, 25 malignant pleural effusions had the following sonographic appearances: an anechoic pattern in 28% (7/25), a complex nonseptated pattern in 60% (15/25), and a complex septated pattern in 12%

Fig. 2



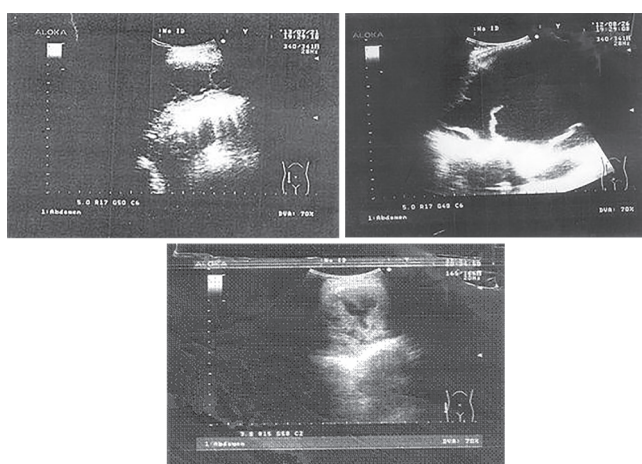
High-resolution ultrasound probe.

Table 1 Demographic data and amount of pleural effusion of the patients studied

Parameter	Groups		P-value
	Nonmalignant effusion (group 1) (n = 25)	Malignant effusion (group 2) (n = 25)	
Age [mean ± SD (range)] (years)	52.4 ± 13.6 (23–73)	64.0 ± 8.1 (45–75)	0.001
Sex [n (%)]			
Male	19 (76.0)	13 (52.0)	0.077
Female	6 (25.0)	12 (48.0)	
Residence			
Urban	8 (32.0)	4 (16.0)	0.185
Rural	17 (68.0)	21 (84.0)	
Special habits			
Nonsmoker	8 (32.0)	4 (16.0)	0.032
Passive smoker	7 (28.0)	2 (8.0)	
Heavy smoker	10 (40.0)	19 (76.0)	
Amount of pleural effusion			
Minimal	7 (28.0)	0	0.000
Moderate	13 (52.0)	7 (28.0)	
Massive	5 (20.0)	18 (72.0)	

Table 2 Final diagnosis of all patients

Item	Groups [n (%)]	
	Nonmalignant effusion (group 1) (n = 25)	Malignant effusion (group 2) (n = 25)
Pulmonary embolism	4 (16.0)	0
Parapneumonic effusion	6 (24.0)	0
Empyema	9 (36.0)	0
Tuberculosis pleural effusion	6 (24.0)	0
Mesothelioma	0	6 (24.0)
Metastatic adenocarcinoma	0	17 (68.0)
Poorly differentiated nonsmall cell carcinoma	0	1 (4.0)
Large cell carcinoma	0	1 (4.0)

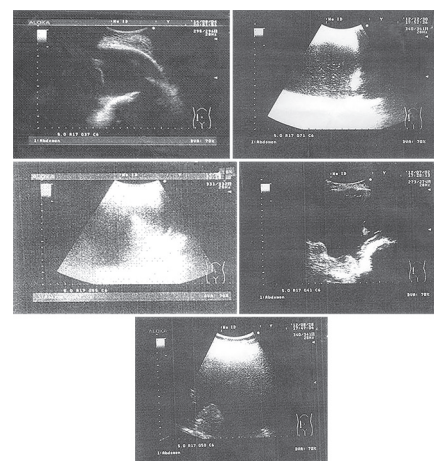
Fig. 3

Sonographic appearances of nonmalignant pleural effusion. (a) Complex septated effusion with some fibrin strands. (b) Complex septated effusion with more strands. (c) Complex septated effusion with multiple septations.

(3/25). The 25 nonmalignant pleural effusions had the sonographic appearances of an anechoic pattern in 16% (4/25), a complex nonseptated pattern in 32% (8/25), and a complex septated pattern in 52% (13/25). Apparently, a complex septated pattern (Fig. 3) in exudative effusion is a useful diagnostic predictor for differentiating benign from malignant causes ($P = 0.046$). If we define the complex septated pattern as a predictor of nonmalignant pleural effusions, we can achieve sensitivity, specificity, positive predictive value, and negative predictive value of 52, 88, 81, and 65%, respectively (Table 4). Interestingly, for the complex nonseptated sonographic pattern (Fig. 4) of malignant exudative pleural effusions, the differentiation between malignant and nonmalignant was also significant ($P = 0.002$). If we define the complex nonseptated pattern as a predictor of malignant pleural effusions, we can achieve sensitivity, specificity, positive predictive value, and negative predictive value of 60, 68, 65, and 63%, respectively (Table 5). The presence of pleural nodules was found in all cases of malignant pleural effusion with the highest specificity (100%). Pleural thickening was detected in both malignant (88%, 22/25) and nonmalignant pleural effusion (52%, 13/25), but it was significantly higher in malignant effusion ($P = 0.005$) and could predict malignant effusion with higher values than nonmalignant effusion (Tables 4 and 5).

Discussion

Clinically, exudative effusion is a challenge and a daily problem for the differential diagnosis between its different etiologies, especially in an area with

Fig. 4

Sonographic appearances of malignant pleural effusion. (a) Anechoic pleural effusion in a case of mesothelioma. (b) Complex nonseptated effusion in a case of mesothelioma. (c) Complex nonseptated effusion, diffuse pleural thickening in a case of metastatic adenocarcinoma. (d) Anechoic pleural effusion associated with pleural nodules (in parietal, visceral, and diaphragmatic pleurae). (e) Complex nonseptated effusion associated with pleural nodules (in visceral pleura).

Table 3 Sonographic data of all patients

Item	Groups [n (%)]		P-value
	Nonmalignant effusion (group 1) (n = 25)	Malignant effusion (group 2) (n = 25)	
Anechoic	4 (16.0)	7 (28.0)	0.307
Complex nonseptated	8 (32.0)	15 (60.0)	0.046
Complex septated	13 (52.0)	3 (12.0)	0.002
Pleural nodules	0	10 (40.0)	0.000
Pleural thickening	13 (52.0)	22 (88.0)	0.005

Table 4 Sensitivity, specificity, PPV, and NPV of sonographic criteria in the prediction of nonmalignant pleural effusion

Parameters	Sensitivity (%)	Specificity (%)	PPV	NPV
Complex nonseptated	32	40	35	37
Complex septated	52	88	81	65
Pleural thickening	52	12	37	20

NPV, negative predictive value; PPV, positive predictive value.

Table 5 Sensitivity, specificity, PPV, and NPV of sonographic criteria in the prediction of malignant pleural effusion

Parameters	Sensitivity (%)	Specificity (%)	PPV	NPV
Complex nonseptated	60	68	65	63
Complex septated	12	48	19	35
Pleural nodules	40	100	100	63
Pleural thickening	88	48	63	80

NPV, negative predictive value; PPV, positive predictive value.

limited financial resources. Yang *et al.* [5] defined and classified the sonographic patterns of pleural effusions as anechoic, complex nonseptated, complex septated, and homogeneous. Transudates were often anechoic, whereas an anechoic pattern of effusions could be either a transudate or an exudate. Pleural effusions appearing with complex septated, complex nonseptated, or homogeneously echogenic patterns were almost always exudates [5]. Tu *et al.* [6] reported that complex nonseptated and relatively hyperechoic, complex septated, and homogeneously echogenic patterns of pleural effusions might predict the possibility of empyema. Chian *et al.* [7] also published findings in which the echogenic swirling pattern of pleural effusions could predict malignant pleural effusions in patients with malignancies.

From our study, we have found that complex septated sonographic patterns of exudative effusion can aid the early diagnosis of nonmalignant effusion. Certainly, our results require a larger sample size and multicenter studies for confirmation of these findings.

Fibrinous bands appear in various causes of pleuritis and divide the effusions into a network of septa [8]. Chung *et al.* [9] found that repeated thoracentesis may cause pleural inflammation and may lead to fibrin formation in malignant effusions. Thus, we also analyzed the

sonographic septations in pleural effusions and focused on whether septations in exudative pleural effusions could actually be useful in predicting the inflammatory nature of nonmalignant effusion (empyema, tuberculosis, parapneumonic), particularly tuberculosis, as because of a higher inflammatory reaction.

The complex septated sonographic patterns of pleural effusions were not specific for tuberculosis. As reported, tuberculous pleural effusions and empyema commonly had complex septated sonographic appearances [5,10,11]. However, the differentiation between empyema and tuberculosis can be made easily on the basis of clinical criteria. Therefore, we studied different varieties of nonmalignant pleural effusion.

In our results, the complex septated sonographic pattern as a predictor for nonmalignant pleural effusions had sensitivity, specificity, positive predictive value, and negative predictive values of 52, 88, 81, and 65%, respectively. Thus, when complex septated sonographic appearances are found in exudative pleural effusions, the possibility of a nonmalignant cause of pleural effusions is high. In tuberculosis, a sputum acid-fast stain may also be useful. If the diagnosis is not conclusive, pleural biopsy should be performed or antituberculous chemotherapy should be attempted, and a follow-up clinical course closely 2 to 4 weeks later [12].

Conversely, a complex nonseptated sonographic pattern was found in most of our cases with malignant effusions. Sensitivity, specificity, negative, and positive predictive values were 60, 68, 65, and 63%, respectively. Therefore, repeated thoracentesis for effusion cytologic examination, and sometimes transbronchial biopsy or sonographically guided transthoracic biopsy increase the diagnostic yield [13].

On reviewing the published literature, Philip-Joët *et al.* [14] and Hua *et al.* [15] reported that plasminogen activator inhibitor and von Willebrand factor levels were significantly higher in patients with empyema or tuberculosis than in those with cancer or cardiac failure, and they also found increased levels of tissue-type plasminogen activators in some malignant pleural effusions. This means that fibrinolytic activity is higher in malignant pleural effusions than nonmalignant pleural effusions, and confirms our findings that fibrins were less common in malignant pleural effusions. In this study, only 12% of patients with malignant pleural effusions had a complex septated sonographic appearance compared with 52% of patients with nonmalignant exudative effusion. Certainly, one of the limitations of this study was the lack of study of the fibrinolytic activities in our enrolled patients. Another typical finding on

ultrasound has been associated with malignancy is pleural nodules. In a study involving 54 patients with pleural effusion [16], the presence of nodular thickening of the diaphragm was associated with malignancy in all cases [15 of 15].

Ultrasound has a sensitivity of 73% and a specificity of 100% in distinguishing malignant pleural effusions from other causes on the basis of pleural thickening, pleural nodularity, diaphragmatic thickening, and an echogenic swirling pattern visible in the pleural fluid [3,4].

We found pleural nodules in 10 cases; all of them were malignant. Pleural nodules could predict malignant effusion with 100% specificity and positive predictive values. Pleural thickening was another significant sonographic finding in 22 cases of malignant effusion ($P = 0.005$) with 88% sensitivity and 80% specificity.

Conclusion

The sonographic appearances of septations are often present in nonmalignant pleural effusions, whereas absence of septations or the presence of pleural nodules and thickening are good predictors in malignant exudative pleural effusions. Transthoracic ultrasound is useful in differentiating malignant from nonmalignant pleural exudates and may become an important step in the diagnostic pathway.

Acknowledgements

Conflicts of interest

None declared.

References

- 1 Maskell NA, Butland RJ. BTS guidelines for the investigation of a unilateral pleural effusion in adults. *Thorax* 2003; 58 Suppl 2:8–17.
- 2 Ocaña I, Martínez-Vázquez JM, Segura RM, Fernández-De-Sevilla T, Capdevila JA. Adenosine deaminase in pleural fluids. Test for diagnosis of tuberculous pleural effusion. *Chest* 1983; 84:51–53.
- 3 Hiraki A, Aoe K, Eda R, Maeda T, Murakami T, Sugi K, Takeyama H. Comparison of six biological markers for the diagnosis of tuberculous pleuritis. *Chest* 2004; 125:987–989.
- 4 Beckh S, Bölskei PL, Lessnau KD. Real-time chest ultrasonography: a comprehensive review for the pulmonologist. *Chest* 2002; 122:1759–1773.
- 5 Yang PC, Luh KT, Chang DB, Wu HD, Yu CJ, Kuo SH. Value of sonography in determining the nature of pleural effusion: analysis of 320 cases. *Am J Roentgenol* 1992; 159:29–33.
- 6 Tu CY, Hsu WH, Hsia TC, Chen HJ, Tsai KD, Hung CW, Shih CM. Pleural effusions in febrile medical ICU patients: chest ultrasound study. *Chest* 2004; 126:1274–1280.
- 7 Chian CF, Su WL, Soh LH, Yan HC, Perng WC, Wu CP. Echogenic swirling pattern as a predictor of malignant pleural effusions in patients with malignancies. *Chest* 2004; 126:129–134.
- 8 Reuss J. The pleura. In: Mathis G, Lessnau KD, eds. *Atlas of chest sonography*. 1st ed. Berlin, Germany: Springer, 2003:17–35.
- 9 Chung CL, Chen YC, Chang SC. Effect of repeated thoracenteses on fluid characteristics, cytokines, and fibrinolytic activity in malignant pleural effusion. *Chest* 2003; 123:1188–1195.
- 10 Carazo Martínez O, Vargas Serrano B, Rodríguez Romero R. Real-time ultrasound evaluation of tuberculous pleural effusions. *J Clin Ultrasound* 1989; 17:407–410.
- 11 Chen KY, Liaw YS, Wang HC, Luh KT, Yang PC. Sonographic septation: a useful prognostic indicator of acute thoracic empyema. *J Ultrasound Med* 2000; 19:837–843.
- 12 Lee CH, Wang WJ, Lan RS, Tsai YH, Chiang YC. Corticosteroids in the treatment of tuberculous pleurisy. A double-blind, placebo-controlled, randomized study. *Chest* 1988; 94:1256–1259.
- 13 Light RW, Erozan YS, Ball WC Jr. Cells in pleural fluid. Their value in differential diagnosis. *Arch Intern Med* 1973; 132:854–860.
- 14 Philip-Joët F, Alessi MC, Philip-Joët C, Aillaud M, Barriere JR, Arnaud A, Juhan-Vague I. Fibrinolytic and inflammatory processes in pleural effusions. *Eur Respir J* 1995; 8:1352–1356.
- 15 Hua CC, Chang LC, Chen YC, Chang SC. Proinflammatory cytokines and fibrinolytic enzymes in tuberculous and malignant pleural effusions. *Chest* 1999; 116:1292–1296.
- 16 Qureshi NR, Rahman NM, Gleeson FV. Thoracic ultrasound in the diagnosis of malignant pleural effusion. *Thorax* 2009; 64:139–143.