

# Primary synovial chondromatosis of the first tarsometatarsal joint: a rare case report

Mohd. Faizan, Sohail Ahmed, Latif Z. Jilani, Kafil Akhtar, Ravindra Mohan, Mazhar Abbas

Department of Orthopaedic Surgery, Jawahar Lal Nehru Medical College, Aligarh Muslim University, Aligarh 202002, Uttar Pradesh, India

Correspondence to Mohd. Faizan, MS (Orthopaedics), Department of Orthopaedic Surgery, Jawahar Lal Nehru Medical College, Aligarh Muslim University, Aligarh 202002, Uttar Pradesh, India Tel: + 91 706 088 7815; e-mail: mohdfaizan2002@gmail.com

Received 16 June 2016

Accepted 8 August 2016

**Egyptian Rheumatology & Rehabilitation**  
2016, 43:196–198

Primary synovial chondromatosis is a rare condition and commonly involves a single large joint, although it may involve any synovial joint. It occurs as a result of metaplasia and focal formation of cartilage in the intimal layer of the synovial membrane. Diagnosis could be made after thorough clinical and radiological assessment. Diagnosis must be confirmed by histopathological examination, because malignant transformation has been reported. Here, we report a case of primary synovial chondromatosis on an extremely rare location involving the first tarsometatarsal joint.

## Keywords:

malignant transformation, primary synovial chondromatosis, tarsometatarsal joint

Egypt Rheumatol Rehabil 43:196–198

© 2016 Egyptian Society for Rheumatology and Rehabilitation  
1110-161X

## Introduction

Synovial chondromatosis is a rare condition of unidentified etiology. It occurs as a result of metaplasia and focal formation of cartilage in the intimal layer of the synovial membrane. These focal cartilage metaplastic formations with time get separated into the synovial cavity as loose bodies, and become calcified. Synovial chondromatosis characteristically involves a single joint. The knee joint is the most common joint and is involved in more than half of the cases [1]. The hip, shoulder, elbow, and ankle are the other larger joints to be involved. Involvement of a smaller joint has also been mentioned in the literature. It has also been reported in tendon sheath and periarticular bursa. The diagnoses of these cases are delayed because of the overlapping and vague symptoms. Primary synovial chondromatosis could be diagnosed by clinicoradiological examination. It occurs extremely rare in the foot, and very few cases of tarsometatarsal joint involvement have been reported. On 'Pubmed' search for similar cases recorded earlier, we found that Young-In Lee *et al.* [2] reported synovial chondromatosis of the foot involving the calcaneocuboid, tibiotalar, naviculocuneiform, and metatarsophalangeal joints. Khan *et al.* [3] also reported the involvement of the first metatarsophalangeal joint, and Harish *et al.* [4] reported a multifocal involvement of the foot with dislocation of the second Lisfrancs joint or second tarsometatarsal joint. To the best of our knowledge, primary synovial chondromatosis of the first tarsometatarsal joint has not been recorded before. Here, we report the primary synovial chondromatosis of the first tarsometatarsal joint.

## Case report

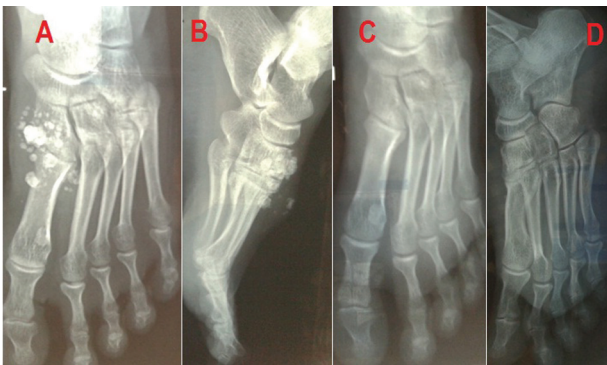A 32-year-old woman presented with mid-foot pain in the left foot since 1 year. Pain was insidious in onset, on

and off initially, and became continuous after 3 months of onset. Pain aggravated on walking and relieved with rest or analgesic. The patient also noticed swelling over the dorsum of the mid-foot, which was gradually increasing in size. In the last 6 months, the patient could palpate something hard in the swelling. There was no history of trauma, diabetes mellitus, or pain in other joints. On local examination, there was swelling over the first tarsometatarsal joint, which was firm in nature and few loose bodies were palpable. Swelling was localized and tender and the overlying skin was normal. There were no signs of inflammation and effusion. Range of motion at the ankle was normal and at first tarsometatarsal it was painfully restricted. Distal neurovascular status was intact. Clinical diagnosis of mid-foot compound ganglionic cyst or tenosynovitis was considered. Plain radiographs of the left foot in anteroposterior and lateral views showed multiple radio-opaque loose bodies around the first tarsometatarsal joint on the dorsomedial aspect (Fig. 1a and b). We made a diagnosis of synovial chondromatosis after clinicoradiological examination. It was further confirmed on histopathological examination, which showed atrophied stratified squamous epithelium, thick collagenous band in the papillary dermis, and atrophied foci of synovium with amorphous basophilic masses (H&E  $\times 10$ ), and multiple nodules of calcific masses of synovium in the corium with fibrosis and foreign body reaction (H&E  $\times 40$ ) (Fig. 2a and b). We could not perform MRI due to financial constrain.

This is an open access article distributed under the terms of the Creative Commons Attribution-NonCommercial-ShareAlike 3.0 License, which allows others to remix, tweak, and build upon the work noncommercially, as long as the author is credited and the new creations are licensed under the identical terms.

Other physical examination and routine blood investigations (serum rheumatoid factor (RA) factor, C-reactive protein, white blood cell count, serum uric acid, and alkaline phosphatase) were carried out and revealed normal findings. Surgical excision of loose bodies along with synovium was made under ankle block (Fig. 3). We found multiple loose bodies scattered around the first tarsometatarsal joint and a bunch of smaller loose bodies was encased in the synovial sac. We sent all excised materials for histopathological examination. Postoperatively, the patient was symptom free, and ankle and foot physiotherapy was started after 2 weeks. The patient remained free of symptoms for the last 2 years. She was followed up every 6 months and underwent clinicoradiological examination on every visit for recurrence. The patient remained free of symptoms for the last 2 years and there was no sign of recurrence.

Figure 1



(a, b) Preoperative radiograph (anteroposterior and lateral) showing multiple radio-opaque loose bodies scattered around the first tarso-metatarsal joint, mainly on the dorsomedial aspect, and (c, d) post-operative radiographs showing removal of all loose bodies.

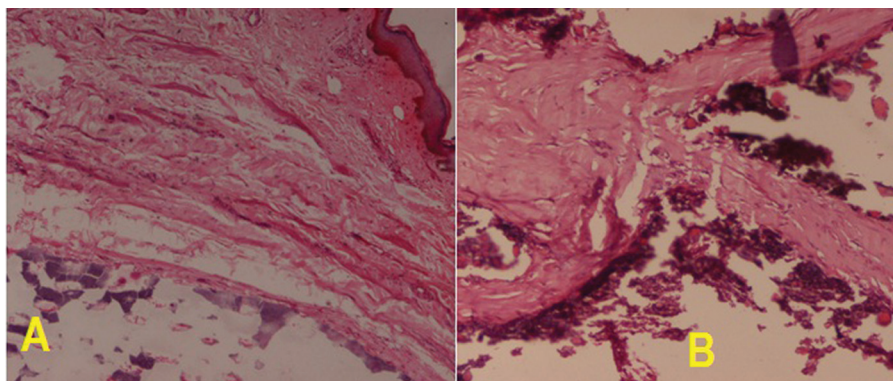
## Discussion

Primary synovial chondromatosis develops in a joint without any previous pathology, as in present case. Subsequently, it may lead to degenerative arthritis with mechanical wear and tear in the joint. Detached loose bodies continue to grow in size because these are getting their nutrition from synovial fluid. It is a progressive and self-limiting disorder, and loose bodies tend to resorb spontaneously. Primary synovial chondromatosis has propensity to recur. Secondary synovial chondromatosis usually found in already diseased joint and previous disease may be degenerative, inflammatory, or noninflammatory. It showed no recurrence after treatment [1].

Synovial chondromatosis commonly occurs in the age group of 30–50 years and occasionally occurs in children. It affects the male population more commonly compared with the female population. Usual presentation is pain, swelling, and limitation of movements of the involved joint, as in our patient. Diagnosis can be easily made after thorough clinical and radiological assessment as in present case. Plain radiographs are useful in phase III only. If feasible, MRI is the investigation of choice to assess the location and extension of disease more accurately [5] and histopathological examination usually confirms the diagnosis. There are various alternative names for this condition, such as synovial osteochondromatosis, synovial chondrosis, synoviochondrometaplasia, and articular chondrosis.

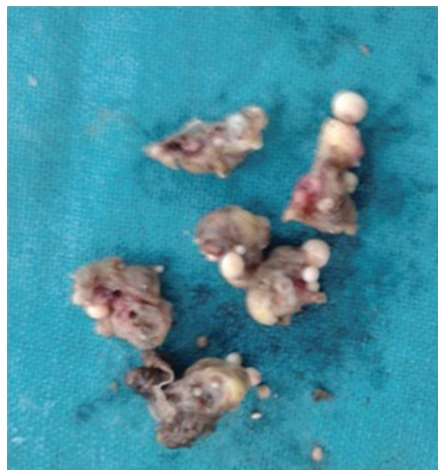Synovial chondromatosis is a result of metaplastic changes in synovial tissue into chondrocyte. This process is divided into three phases. In phase I, metaplasia of the synovial intima occurs with active synovitis and nodule formation,

Figure 2



(a) Atrophied stratified squamous epithelium, thick collagenous band in papillary dermis, and atrophied foci of synovium with amorphous basophilic masses (H&E  $\times 10$ ), and (b) multiple nodules of calcific masses of synovium in the corium with fibrosis and foreign body reaction (H&E  $\times 40$ ).

Figure 3



Excised multiple loose bodies.

but without calcifications. In phase II, nodular synovitis and cartilaginous loose bodies are usually present. In phase III, united and calcified loose bodies with resolved synovitis are present [6]. Malignant transformation into chondrosarcoma has been reported in 5% of cases. Synovial chondromatosis must be differentiated from other conditions such as pigmented villonodular synovitis, osteochondritis dissecans, rheumatoid arthritis, soft-tissue calcification, chondrosarcoma, and lipoma arborescence with osseous metaplasia [1,6]. Treatment in symptomatic patients must be surgical and it depends upon the severity of symptoms and functional demand of the patient. In younger patients, arthroscopic surgery should be preferred for better rehabilitation and early return to work. If arthroscopic facility is not available, open surgical excision of loose bodies with or without synovectomy is the only option as in present case. In phase III, only loose body excision is adequate treatment. In the presence of synovitis, chances of recurrence are usually high. Recurrence rate after surgical procedure ranging from 7 to 23% has been mentioned in the literature [7].

Asymptomatic patients should not be subjected to operative procedures because loose bodies tend to resorb spontaneously. Patient should be followed up carefully for recurrence and malignant transformation.

### Conclusion

Primary synovial chondromatosis is extremely rare around the first tarsometatarsal joint. This condition could be diagnosed after thorough clinical and radiological examination. Plain radiographs are helpful only after calcification – that is, phase III. If feasible, MRI is the investigation of choice. Malignant transformation has been reported, and hence diagnosis must be confirmed by histopathological examination. We should monitor this condition cautiously for recurrence and malignant transformation for years.

### Financial support and sponsorship

Nil.

### Conflicts of interest

There are no conflicts of interest.

### References

- 1 Udasimath SS, Vijay PM, Purushotham R, Kumar Naik H, Nagesha KR. Bilateral primary synovial chondromatosis: a case report. *J Clin Diagn Res* 2012; 6 (Suppl 1):475–477.
- 2 Young-In Lee F, Hornicek FJ, Dick HM, Mankin HJ. Synovial chondromatosis of the foot. *Clin Orthop* 2004; 423:186–190.
- 3 Khan Z, Yousri T, Chakrabarti D, Awasthi R, Ashok N. Primary synovial osteochondromatosis of the first metatarsophalangeal joint, literature review of a rare presentation and a case report. *Foot Ankle Surg* 2010; 16:e1–e3.
- 4 Harish S, Saifuddin A, Cannon SR, Flanagan AM. Synovial chondromatosis of the foot presenting with Lisfranc dislocation. *Skeletal Radiol* 2005; 34:736–739.
- 5 Frick MA, Wenger DE, Adkins M. MR imaging of synovial disorders of the knee: an update. *Radiol Clin North Am* 2007; 45:1017–1031.
- 6 Miligram JW. Synovial osteochondromatosis. *J Bone Joint Surg* 1977; 59-A:792.
- 7 Krebbs VE. The role of hip arthroscopy in the treatment of synovial disorders and loose bodies. *Clin Orthop Relat Res* 2003; 406:48–59.