

# The value of endoscopic examination at the end of conventional adenoidectomy

Mohamed A. Abdelhamid, Hazem M. Dewidar, Ahmad M. Nassar, Ahmad M. Elteley

Department of Otorhinolaryngology, Faculty of Medicine, Cairo University, Cairo, Egypt

Correspondence to Ahmad M.H. Nassar, MD, Department of Otorhinolaryngology, Faculty of Medicine, Cairo University, Cairo 11562, Egypt; Tel: +20 122 290 3321; e-mail: ahmednassar\_79@hotmail.com

Received 5 September 2015

Accepted 29 September 2015

The Egyptian Journal of Otolaryngology  
2017, 33:24–30

## Aim

The aim of this study was to evaluate the value of the use of endoscopes after a conventional curettage adenoidectomy for detecting any residual adenoid tissue and to determine whether removing any residual, if present, affects the recurrence or not.

## Patients and methods

Fifty patients were divided randomly into two equal groups. Group A underwent a conventional curettage adenoidectomy, followed by an endoscopic examination of the nasopharynx to detect and remove any residual adenoid tissue. Group B underwent a conventional curettage adenoidectomy only. Both groups were followed up for recurrence of symptomatic adenoid at fixed follow-up intervals at 10 days, 1, 3, and 6 months postoperatively.

## Results

There was a significant difference in the rate of adenoid recurrence between both groups 6 months postoperatively. Two (8%) patients in group A and nine (36%) patients in group B developed recurrence. The *P* value was statistically significant at 0.04.

## Conclusion

Endoscopic examination after a conventional adenoidectomy is a safe and essential step for complete removal of the adenoid, thus reducing the recurrence rate.

## Keywords:

adenoid, adenoid recurrence, endoscopic examination

Egypt J Otolaryngol 33:24–30

© 2017 The Egyptian Journal of Otolaryngology  
1012-5574

## Introduction

Adenoid is the upper part of the Waldeyer's ring and is situated at the junction of the superior and posterior nasopharyngeal walls [1]. Adenoid hypertrophy is involved in many pathological conditions such as recurrent otitis media, otitis media with effusion, bilateral nasal obstruction, and recurrent pharyngeal infections [2]. The cornerstone for treatment is adenoidectomy. The procedure is classically performed using the adenoid curette, but has recently been updated with the use of endoscopic sinus surgery instruments [3]. Several other methods have been described such as the use of the curved microdebrider shaver or the curved suction electrical coagulator through a transoral approach [4]. The drawbacks of the standard curettage adenoidectomy include injury to the nasopharyngeal structures and incomplete removal, which may eventually cause recurrence [5].

The aim of this study was to evaluate the value of the use of endoscopes after a conventional curettage adenoidectomy for detecting any residual adenoid tissue and to determine whether removing any residual, if present, affects the recurrence or not.

## Patients and methods

This randomized-controlled trial included 50 patients, of both sexes, with hypertrophied adenoid tissue who presented clinically with mouth breathing, snoring, bilateral nasal obstruction, and/or discharge and confirmed radiologically with a plain radiography film lateral view to the nasopharynx. All patients presented to the Kasr Al Ainy Hospital, ENT Outpatient Clinic, from February through November 2013, seeking medical care for their complaints. Patients were divided randomly into two equal groups. Randomization was computer based. Group A included patients who underwent a conventional curettage adenoidectomy, followed by an endoscopic examination of the nasopharynx, with subsequent removal of any residual adenoid tissue. Group B included patients who underwent a conventional curettage adenoidectomy only.

This is an open access article distributed under the terms of the Creative Commons Attribution-NonCommercial-ShareAlike 3.0 License, which allows others to remix, tweak, and build upon the work noncommercially, as long as the author is credited and the new creations are licensed under the identical terms.

**Inclusion criteria**

Inclusion criteria were as follows:

- (1) Patients' ages range from 3 to 12 years.
- (2) Adenoid was the only cause for nasal obstruction.
- (3) History of mouth breathing, snoring, bilateral nasal obstruction, and/or bilateral nasal discharge.
- (4) Radiographic confirmation of adenoid hypertrophy encroaching onto the airway column.

**Exclusion criteria**

Exclusion criteria were as follows:

- (1) Patients younger than 3 years of age and older than 12 years of age.
- (2) Recurrent cases.
- (3) Adenoid hypertrophy was not the only cause for nasal obstruction.

All patients' guardians provided their consent.

**Procedure**

All patients were subjected to the following protocol:

- (1) Preoperative preparation:
  - (a) Careful and detailed history was obtained from the guardians:
    - (i) Personal history.
    - (ii) Complaint and history of the present illness.
    - (iii) Past history.
  - (b) Clinical examination:
    - (i) General examination.
    - (ii) Local examination.
  - (c) Investigations:
    - (i) Routine laboratory preoperative labs.
    - (ii) Radiographic soft tissue lateral view for the nasopharynx with the mouth opened and the neck extended.
- (2) Operative technique:
  - (a) Group A: This included 25 patients.
    - (i) General anesthesia with oral endotracheal intubation.
    - (ii) Patient placed in the Rose position.
    - (iii) A Bowel–Davis mouth gag was used to open the mouth and depress the tongue.
    - (iv) The soft palate was inspected for bifid uvula and digitally palpated for submucous cleft.
    - (v) The nasopharynx was palpated digitally to examine for adenoid.
    - (vi) Using the conventional curette, the adenoid tissue was removed.
  - (b) Group B: This included 25 patients.
    - (i) Patients in this group underwent the same technique as above, but without an endoscopic examination of the nasopharynx after ensuring hemostasis and pack removal.
- (3) Postoperative protocol:
  - (a) All patients received the same medical treatment.
  - (b) All patients were followed up at 10 days, 1, 3, and 6 months postoperatively.
  - (c) The incidence of reactionary postoperative bleeding was also reported.
- (4) Adenoid recurrence was evaluated on the basis of the following:
  - (a) Clinical manifestations of bilateral nasal obstruction, bilateral nasal discharge, snoring, nasal tone of voice, and mouth breathing.
- (vii) The nasopharynx was re-evaluated by digital palpation for any residual. If a residual was detected, it was then removed by revision curettage and/or manual rubbing of the operative field with the index finger covered with dry gauze until the sensation of complete removal was achieved by digital palpation of the nasopharynx.
- (viii) Hemostasis was achieved by packing the nasopharynx with dry gauze.
- (ix) After complete hemostasis and pack removal, an endoscope, rigid type, 0° 2.7 or 4.0 mm introduced transnasally or 70° 4.0 mm introduced transorally, was used to examine the nasopharynx for residual adenoid tissue at the following sites:
  - Adenoid bed.
  - Both choanae.
  - Both Eustachian tube orifices.
- (x) Any residual adenoid tissue was removed under direct endoscopic visualization using the forward-biting Blakesley forceps, upward-biting Blakesley forceps, straight artery forceps, curved artery forceps, an adenoid curette, or a microdebrider shaver.
- (xi) Hemostasis was achieved again by dealing with any bleeding point by the bipolar coagulator under direct endoscopic visualization.

For both groups, the operative time was determined. All patients were operated upon by the same surgeon.

- (b) Endoscopic evaluation: a scoring system composed of four grades for adenoid obstruction [6]. In first-degree obstruction, the adenoid occupied the upper segment in the rhinopharyngeal cavity; therefore, choanal openings were free. In second-degree obstruction, the adenoid was confined to the upper half of the rhinonasal cavity (<50% obstruction of the choanae). In third-degree obstruction, the adenoid extended over the rhinopharynx (50–75%) with obstruction of choanal openings and partial closure of tube ostium. In fourth-degree obstruction, the obstruction was almost total. As a consequence, both the tube ostium and the lower choanal border could not be observed. Third-degree and fourth-degree choanal obstruction were considered recurrent obstructive adenoid.
- (c) Radiological assessment: plain radiograph of nasopharynx with soft tissue radiation dose with the mouth opened and the neck extended was performed for all patients to detect adenoid recurrence. Adenoid thickness compared with the rest of the airway was defined as the perpendicular distance from the pharyngeal tubercle to the highest convexity of the adenoid tissue. Afterward, the ratio of airway to adenoid thickness was calculated from the above-mentioned adenoid tissue and the superior surface of the soft palate adenoid tissue. The amount of obstruction was categorized into four grades (grade 0=0–25%, grade 1=25–50%, grade 2=50–75%, and grade 3=75–100%). Grades 2 and 3 were considered recurrent obstructive adenoid [7].

#### Statistical analysis

Precoded data were entered into the computer using 'Microsoft Office Excel Software' program (2010; Redmond, Washington, USA) for Windows. Data were then transferred to the statistical package for the social science software program (version 21; SPSS Inc., Armonk, New York, USA), for statistical analysis.

Data were summarized using mean and SD for quantitative variables and frequency and percentage for qualitative variables.

Comparison between groups was performed using an independent-sample *t*-test for quantitative variables and the Fisher exact test for qualitative variables.

Paired qualitative variables were tested using the McNemar test within each group separately.

*P* values less than 0.05 were considered statistically significant.

Graphs were used to present some information.

#### Results

This study included 50 patients, divided randomly into two equal groups. Their ages ranged from 3 to 12 years. The patients in group A underwent an endoscopic examination of the nasopharynx after a conventional adenoidectomy, with subsequent removal of any residual adenoid tissue. The patients in group B underwent a conventional adenoidectomy only without endoscopic examination of the nasopharynx. All patients were followed up for adenoid recurrence at intervals of 10 days, 1, 3, and 6 months post-operatively. Adenoid recurrence was assessed clinically, radiologically, and sometimes endoscopically in inconclusive cases.

Table 1 and Figs 1 and 2 present a comparison of both groups in terms of the demographic distribution.

Group A included 10 (40%) males and 15 (60%) females, whereas group B included 14 (56%) males and 11 (44%) females. There was no statistically significant difference in the sex distribution in both groups ( $P=0.4$ ).

The mean age of the patients in group A was 7.2, whereas it was 6.9 for the patients in group B. This difference was statistically insignificant ( $P=0.8$ ).

Table 2 and Figs 3 and 4 present the operative endoscopic findings for group A. Residual adenoid was found in 20 (80%) patients.

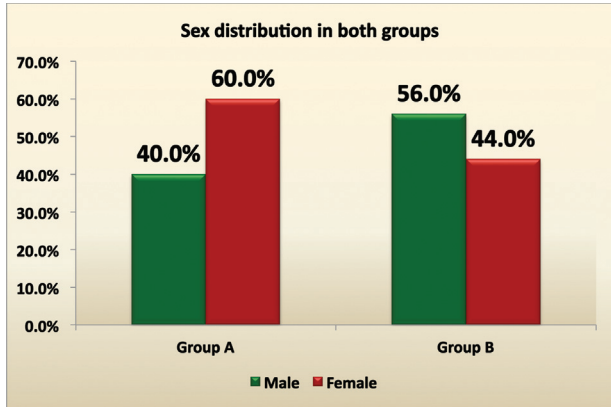
The most common site for residual adenoid tissue was the adenoid bed, where 15 (75%) patients had a residual. The second most common site was the Eustachian tube openings, where three (15%) patients had a residual. The least common site was the choanal opening, where two (10%) patients had a residual.

**Table 1 Comparison between both groups as regards the demographics**

	Group A (n=25)		Group B (n=25)		<i>P</i> value
Sex [n (%)]					
Male	10	40.0	14	56.0	0.4 (NS) <sup>a</sup>
Female	15	60.0	11	44.0	
Age					
Mean±SD	7.2±2.9		6.9±3.0		0.8 (NS) <sup>b</sup>

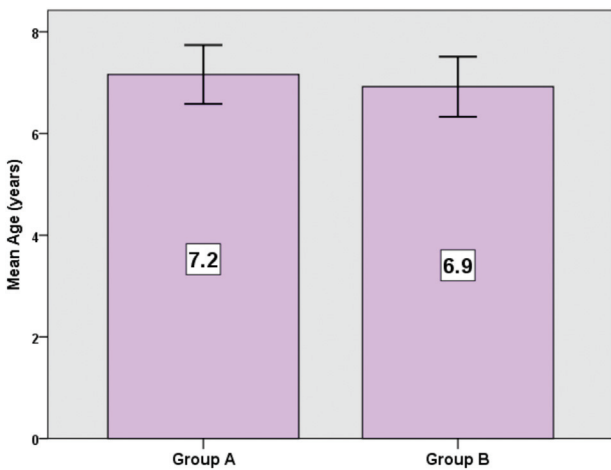
<sup>a</sup>Fisher's exact test. <sup>b</sup>Independent sample *t*-test.

Figure 1



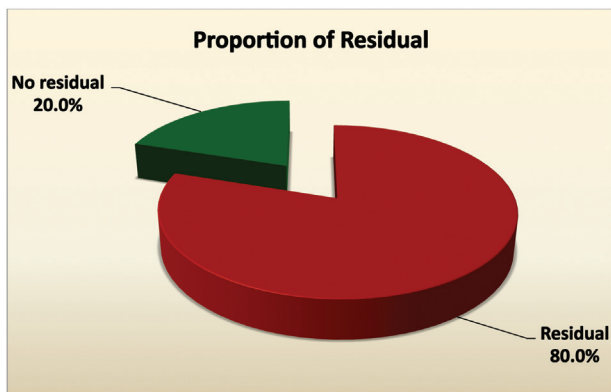
Gender distribution in both groups showing no statistical difference.

Figure 2



The mean age for both groups.

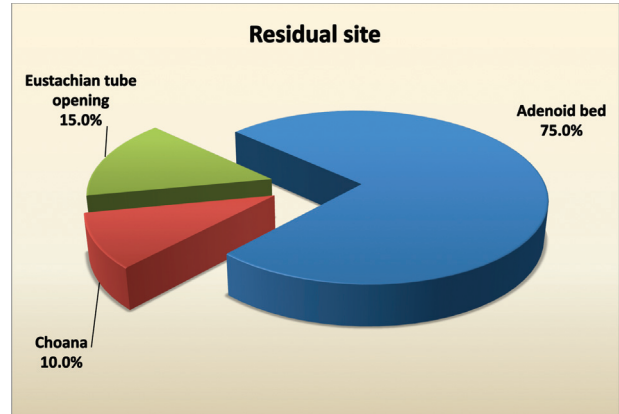
Figure 3



Significant number of patients had residual adenoid.

Tables 3 and 4 and Fig. 5 present a comparison of both groups in terms of the adenoid recurrence rate. No patients developed adenoid recurrence during the first three follow-up intervals in both groups. During the

Figure 4



The main site for adenoid residual was the adenoid bed.

Table 2 Description of residual adenoid tissue in group A only

	Frequency (%) (n=25)
Residual	
Present	20 (80.0)
Absent	5 (20.0)
Site of residual	
Adenoid bed	15 (75.0)
Eustachian tube opening	3 (15.0)
Choana	0.8 (10.0)

Table 3 Comparison between both groups as regards adenoid recurrence at different time intervals

Recurrence at	Group A (n=25) [N (%)]	Group B (n=25) [N (%)]	P value <sup>a</sup>
10 days	0 (0.0)	0 (0.0)	1.0 (NS)
1 month	0 (0.0)	0 (0.0)	1.0 (NS)
3 months	0 (0.0)	0 (0.0)	1.0 (NS)
6 months	2 (8.0)	9 (36.0)	0.04 (S)

S, significant. <sup>a</sup>Fisher's exact test.

Table 4 Comparison of adenoid recurrence development in each group separately

Recurrence at	Group A (n=25) [N (%)]	Group B (n=25) [N (%)]
10 days	0 (0.0)	0 (0.0)
6 months	2 (8.0)	9 (36.0)
P value <sup>a</sup>	0.5 (NS)	0.004 (HS)

<sup>a</sup>McNemar test.

last follow-up interval, 6 months postoperatively, two (8%) patients in group A and nine (36%) patients in group B developed adenoid recurrence. The difference in the recurrence rate between both groups was statistically significant (P=0.04).

For group A, there was no statistical difference in the recurrence rate between the first and the last follow-up intervals. For group B, there was a statistically

significant difference in the recurrence rate between the same follow-up intervals ( $P=0.004$ ).

Figure 6 shows a comparison of the mean operative time for both groups. For group A, the mean operative time was 30.1, with a SD of 8.4 min. For group B, the mean operative time was 20.2, with a SD of 8.9 min. The difference in the mean operative time between both groups was statistically significant ( $P=0.001$ ) as the procedure was longer for the patients in group A than for the patients in group B.

Table 5 and Fig. 7 show a comparison of the difference between both groups in the incidence of reactionary postadenoidectomy hemorrhage. In group A, no patients developed reactionary postoperative bleeding. In group B, two patients developed reactionary

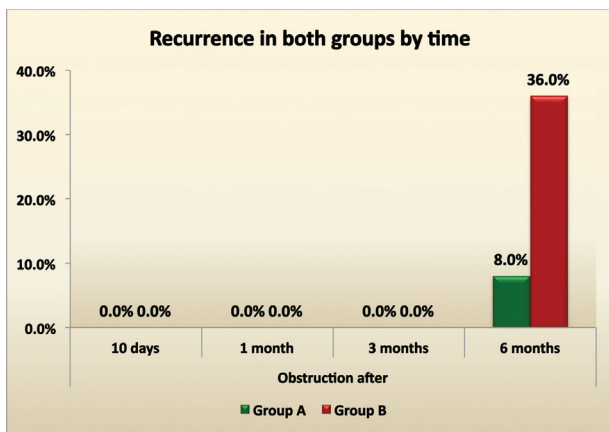
postoperative bleeding. Both patients were immediately readmitted to the operating room and hemorrhage control was achieved successfully under general anesthesia. The first patient had bipolar coagulation under direct endoscopic visualization whereas the second patient had posterior nasal packing. The difference between both groups in the incidence of reactionary postoperative bleeding was statistically insignificant ( $P=0.5$ ) (Figs 8 and 9).

**Discussion**

Adenoid is considered one of the factors in the etiology of several conditions such as recurrent otitis media, rhinosinusitis, and otitis media with effusion [8].

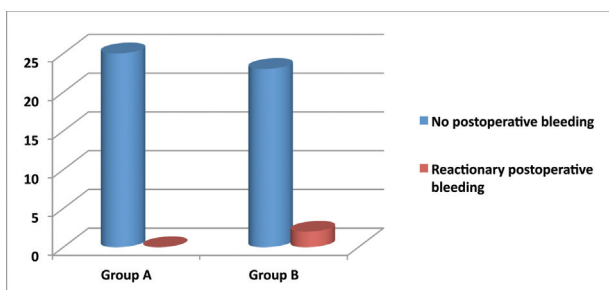
Conventional curettage adenoidectomy alone could not achieve complete removal of the adenoid tissue in a considerable number of the patients, especially if

**Figure 5**



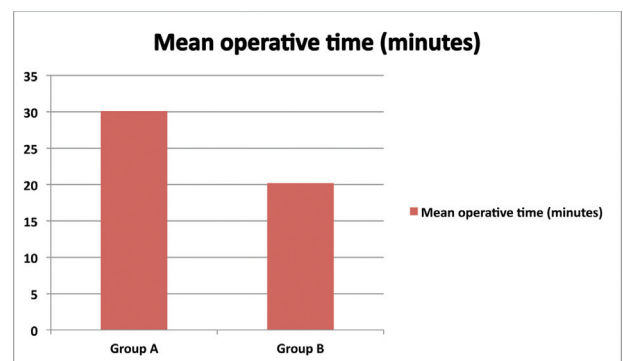
Rate of adenoid recurrence for both groups showed significant difference.

**Figure 7**



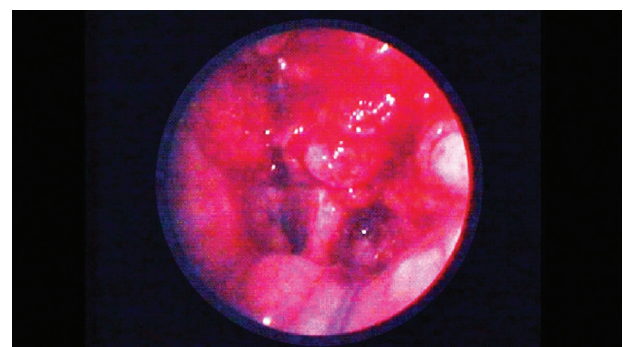
Comparison between the postoperative bleeding between both groups.

**Figure 6**



Comparison between the mean operative time for both groups.

**Figure 8**

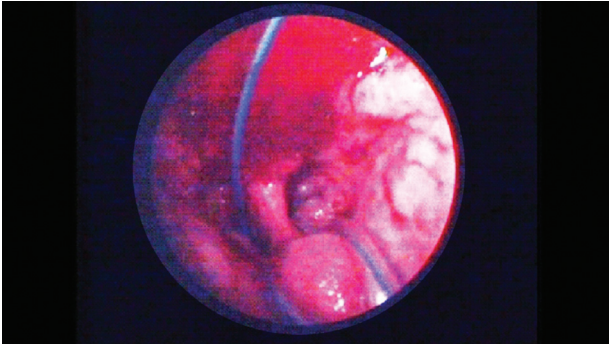


Endoscopic view of adenoid bed postoperative.

**Table 5 Reactionary postoperative bleeding in both groups**

	Groups [N (%)]		P value
	Group A (n=25)	Group B (n=25)	
Postoperative bleeding	0 (0)	2 (8)	0.4989 (NS)

Figure 9



Endoscopic view of adenoid bed postoperative.

there was intranasal extension or bulky part of the adenoid in the roof of the nasopharynx [9]. For complete removal of the adenoid tissue, the obstacle of the relatively blind technique has to be overcome. Direct/indirect visualization of the operative field during the operation is a mandatory part of the operation [10]. This target was achieved using an angled mirror or an endoscope [11].

In the present study, 50 patients were divided randomly into two equal groups. The patients in group A underwent a conventional curettage adenoidectomy; then, the rigid endoscope was used either transorally or transnasally for direct visualization of the operative field and subsequent removal of any residual adenoid tissue. The patients in group B underwent a conventional curettage adenoidectomy alone without visualization of the operative field with the endoscope. The rate of adenoid recurrence was evaluated at fixed follow-up intervals of 10 days, 1, 3, and 6 months postoperatively. At the last follow-up interval, two (8%) patients in groups A and nine (36%) patients in group B developed adenoid recurrence. The difference in the recurrence rate between both groups was statistically significant ( $P=0.04$ ). In group A, 20 (80%) patients had residual adenoid tissue as detected by the endoscope during the operation.

The most common site for residual adenoid was the adenoid bed, where 15 (75%) patients had residual adenoid. The second most common site was the pharyngeal opening of the Eustachian tube, where three (15%) patients had residual adenoid. The least common site for residual adenoid was the choanal opening, where two (10%) patients had residual adenoid tissue. In the present study, no patients developed reactionary postoperative bleeding in group A, whereas two patients in group B developed bleeding. This difference was statistically insignificant ( $P=0.5$ ); however, the investigators believe that this lack of significance is mainly because of the small

sample size. The intraoperative control of bleeding under direct endoscopic visualization was much easier and more effective in group A than in group B.

Regmi *et al.* [12] evaluated the nasopharynx before and after curettage adenoidectomy for 41 patients. They concluded that curettage adenoidectomy alone is insufficient to completely remove all of the adenoid tissue from the nasopharynx. Some patients had residual adenoid tissue in mixed sites. The sites for adenoid residual were the choanal openings (67.2%), the pharyngeal openings of the Eustachian tubes (63%), the nasopharyngeal roof (61.78%), and the fossa of Rosenmuller (61%) [12]. The authors used an endoscope for evaluation of the nasopharynx and the adenoid before curettage adenoidectomy. This step is not included in the present study and it may explain the difference in the rates of adenoid residual occurrence.

A classic transoral adenoid curette was used to remove the adenoid from the nasopharynx in 143 patients. This was followed by an endoscopic transnasal assessment of the nasopharynx for residual adenoid. Residual tissue was found in 70 (48.9%) patients and it was removed using the microdebrider under direct endoscopic control. Follow-up of the patients after 24 months showed that there was no recurrence of symptomatic adenoid in any of them. The mean curettage time with an endoscopic assessment of the nasopharynx was 9.1 min and in case of completion with a microdebrider, it was 14.6 min. No other complications were recorded either intraoperatively or postoperatively [13].

In the present study, the mean operative time was relatively longer than that in the previously mentioned study. This difference may be attributed to the differences in the operating surgeon's expertise and the constant use of a microdebrider for adenoid residual removal.

Of 425 patients undergoing curettage adenoidectomy, 288 (68%) had residual adenoid as observed with nasopharyngoscopy, of whom 104 (24%) had significant obstruction. Nasopharyngoscopy after curettage adenoidectomy was recommended as an additional safe and easy step for the completion of an adenoidectomy [14].

The difference in the percentage of residual adenoid between the previously mentioned study and the present study may be attributed to the difference in the sample size.

It is clear that the present study and all of the previously mentioned studies advocate endoscopic evaluation of

the nasopharynx with subsequent endoscopic-assisted removal of the residual adenoid tissue for better results. They all concluded that curettage adenoidectomy alone usually misses a considerable amount of residual adenoid, which can lead to an increase in the rate of recurrence.

---

## Conclusion

Despite the prolongation in the operative time when using an endoscope to explore and to aid in residual adenoid tissue removal from the nasopharynx at the end of a conventional adenoidectomy, the authors strongly advocate the inclusion of this step because of its additional usefulness in reducing the recurrence of symptomatic adenoid, easier control of intraoperative bleeding, and reducing the incidence of reactionary postoperative bleeding.

## Financial support and sponsorship

Nil.

## Conflicts of interest

The authors have no conflicts of interest to be declared.

---

## References

- 1 Gross C, Harrison S. Tonsils and adenoids pediatrics. *Pediatr Rev* 2000; 21:75–78.
- 2 Paulussen C, Claes J, Jorissen M. Adenoids and tonsils indications for surgery and immunological consequences of surgery. *Acta Otorhinolaryngol Belg* 2000; 54:403–408.
- 3 Havas T, Lowinger D. Obstructive adenoid tissue: an indication for powered shaver adenoidectomy. *Arch Otolaryngol Head Neck Surg* 2002; 128:789–791.
- 4 Koltai P, Chan J, Younes A. Power-assisted adenoidectomy: total and partial resection. *Laryngoscope* 2002; 112:29–31.
- 5 Bross-Soriano D, Schimelmitz-Idi J, Arrieta-Gómez J. Endoscopic adenoidectomy; use or abuse of the technology?. *Cir Cir* 2004; 72: 15–19.
- 6 Cassano P, Gelardi M, Cassano M, Fiorella M, Fiorella R. Adenoid tissue rhinopharyngeal obstruction grading based on fiberendoscopic findings: a novel approach to therapeutic management. *Int J Pediatr Otorhinolaryngol* 2003; 67:1303–1309.
- 7 Saedi B, Sadeghi M, Mojtahed M, Mahboubi H. Diagnostic efficacy of different methods in the assessment of adenoid hypertrophy. *Am J Otolaryngol Head Neck Med Surg* 2011; 32:147–151.
- 8 Emerick K, Cunningham M. Tubal tonsil hypertrophy: a cause of recurrent symptoms after adenoidectomy. *Arch Otolaryngol Head Neck Surg* 2006; 132:153–156.
- 9 Elluru R, Johnson L, Myer C III. Electrocautery adenoidectomy compared with curettage and power-assisted methods. *Laryngoscope* 2002; 112: 23–25.
- 10 Ark N, Kurtaran H, Ugur K, Yilmaz T, Ozboduroglu A, Mutlu C. Comparison of adenoidectomy methods: examining with digital palpation vs. visualizing the placement of the curette. *Int J Pediatr Otorhinolaryngol* 2010; 74: 649–651.
- 11 Discolo C, Younes A, Koltai P. Current techniques of adenoidectomy. *Oper Tech Otolaryngol Head Neck Surg* 2001; 12:199–203.
- 12 Regmi D, Mathur N, Bhattarai M. Rigid endoscopic evaluation of conventional curettage adenoidectomy. *J Laryngol Otol* 2011; 125:53–58.
- 13 Pagella F, Matti E, Colombo A, Giourgos G, Mira E. How we do it: a combined method of traditional curette and power-assisted endoscopic adenoidectomy. *Acta Otolaryngol* 2009; 129:556–559.
- 14 Saxby A, Chappel C. Residual adenoid tissue post-curettage: role of nasopharyngoscopy in adenoidectomy. *ANZ J Surg* 2009; 79:809–811.