

Case Report

Vanishing bone disease of chest wall and spine with kyphoscoliosis and neurological deficit: A case report and review of literature

Sudhir Kumar Srivastava, Rishi Anil Aggarwal, Pradip Sharad Nemade, Sunil Krishna Bhoale

ABSTRACT

Vanishing bone disease is an extremely rare disorder of unknown etiology characterized by idiopathic osteolysis of bone. We describe a case of vanishing bone disease of chest wall and spine with kyphoscoliosis and neurological deficit. A 17-year-old male presented with gradually progressive deformity of back and dorsal compressive myelopathy with nonambulatory power in lower limbs. Radiographs revealed absent 4th–7th ribs on the right side with dorsal kyphoscoliosis and severe canal narrowing at the apex. The patient was given localized radiotherapy and started on a monthly infusion of 4 mg zoledronic acid. Posterior instrumented fusion with anterior reconstruction via posterolateral approach was performed. The patient had a complete neurological recovery at 5 weeks following surgery. At 1 year, anterior nonunion was noted for which transthoracic tricortical bone grafting was done. Bone graft from the patient's mother was used both times. At 7 months following anterior grafting, the alignment was maintained and the patient was asymptomatic; however, fusion at graft-host interface was not achieved. Bisphosphonates and radiotherapy were successful in halting the progress of osteolysis.

Key words: Chest wall, Gorham disease, idiopathic osteolysis, kyphosis, vanishing bone disease

MeSH terms: Osteolysis, spine, chest wall, kyphosis, grafting, bone

INTRODUCTION

Vanishing bone disease, popularly known as Gorham's disease (GD), is an extremely rare disorder of unknown etiology. The pathogenesis and treatment of this disorder is still a mystery. Though known as Gorham–Stout disease, it was first described by Jackson in 1838.¹ In 1955, Gorham and Stout described a series of 24 patients giving the first detailed description of this disorder and hence it got the name.² Since then, it has been known as disappearing bone disease, acute bone resorption, phantom bone disease, vanishing bone disease, and idiopathic massive osteolysis.³

The hallmark of this disease is osteolysis of the involved bone in the absence of infective/malignant or immunological etiology. GD is a diagnosis of exclusion. The criteria for diagnosis suggested by Heffez *et al.* and modified by Choma *et al.* are shown in Table 1.^{4,5} Nonoperative treatment options include bisphosphonates, radiotherapy, and various drugs used alone or in combination. Operative reconstruction of the affected bone has high failure rates due to resorption of the bone graft used.⁶ We describe the nonoperative and operative management of a patient with GD involving chest wall and spine, who presented with kyphoscoliosis and neurological deficit.

CASE REPORT

A 17-year-old male presented with history of gradually progressive deformity in the back since 3 months and

Department of Orthopaedics, Seth G.S. Medical College and KEM Hospital, Mumbai, Maharashtra, India

Address for correspondence: Dr. Rishi Anil Aggarwal, Department of Orthopaedics, Seth G.S. Medical College and KEM Hospital, Parel, Mumbai - 400 012, Maharashtra, India.
E-mail: ris1987@gmail.com

Access this article online

Quick Response Code:



Website:
www.ijoonline.com

DOI:
10.4103/0019-5413.197559

This is an open access article distributed under the terms of the Creative Commons Attribution-NonCommercial-ShareAlike 3.0 License, which allows others to remix, tweak, and build upon the work non-commercially, as long as the author is credited and the new creations are licensed under the identical terms.

For reprints contact: reprints@medknow.com

How to cite this article: Srivastava SK, Aggarwal RA, Nemade PS, Bhoale SK. Vanishing bone disease of chest wall and spine with kyphoscoliosis and neurological deficit: A case report and review of literature. *Indian J Orthop* 2017;51:107-14.

weakness in both lower limbs since 3 days. He had no history of trauma, fever, or similar complaints in the family. There was no significant medical/surgical history. On examination, he had dorsal scoliosis with convexity to the right with angular proximal dorsal kyphosis. His chest was flattened on the right side and the 4th–7th ribs on the right side were absent on palpation. He had non-ambulatory power in his lower limbs (power around the hip and knee was 2/5 and power around ankle and in toes was 3/5) with spasticity and exaggerated deep tendon reflexes. Hypoesthesia below D7 was noted and

bowel bladder sensation was preserved. Plantar response was extensor.

An X-ray taken elsewhere 6 months prior to presentation to OPD showed mild scoliosis with few ribs absent on the right side [Figure 1a]. Due to suboptimal quality of the X-ray, we could not count which ribs were absent. X-ray taken in our OPD demonstrated dorsal scoliosis with convexity to the right side, apex at D6, and Cobbs angle of 41° with angular dorsal kyphosis with apex at D5–D6. The 4th to 7th ribs on the right side were absent with destruction in the lower ribs more as compared to the X-ray taken 6 months back [Figure 1b].

Computed tomography (CT) scan further illustrated the pathoanatomy of the disorder. All X-ray findings were confirmed. Three-dimensional reconstruction showed a complete absence of the right 4th–7th ribs [Figure 1c]. There was a severe narrowing of the canal at the apex. In addition, right-sided pedicles and right half of vertebral bodies proximal to the apex showed osteolysis [Figure 1e and f]. There was severe narrowing of the canal at the apex of kyphosis [Figure 1d]. Magnetic resonance imaging (MRI) showed stretching and compression of the cord at

Table 1: Hefez criteria for diagnosis of Gorham’s disease (modified by Choma)

Positive biopsy for angiomatous tissue
Absence of cellular atypia
Minimal or no osteoblastic response and absence of dystrophic calcification
Evidence of local and progressive osseous resorption
Nonexpansile, nonulcerative lesion
Absence of visceral involvement
Osteolytic radiographic pattern
Negative hereditary, metabolic, neoplastic, immunologic, or infectious etiology
Spread to adjacent soft tissue
Development of fibrous tissue

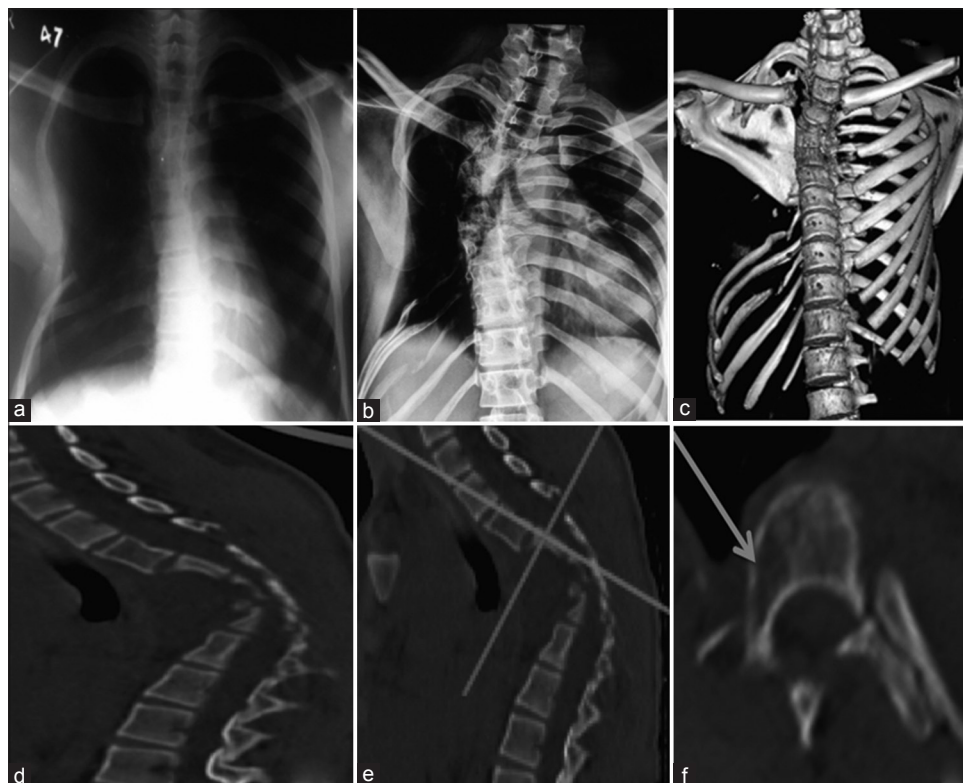


Figure 1: (a) Chest X-ray taken 6 months prior to presentation to us showing mild scoliosis and few absent ribs on the right side (b) X-ray at presentation to us showed right-sided scoliosis with Cobb’s angle 41°. Destruction of ribs has increased as compared to Figure 1a. (c) Three-dimensional reconstruction of the chest (Sternum has been digitally subtracted for better visualization of chest wall,) showing absent ribs on (R) side (4th to 7th rib) (d) Sagittal view showing severe narrowing of the canal at the apex of kyphosis. (e) Dicom image showing the level at which image in Figure 1f has been taken. (f) Axial cut showing osteolysis (arrow) in body and pedicle of vertebrae proximal to the apex

the apex of the deformity. There was no evidence of abscess/inflammation. Angiography did not reveal any abnormality.

The patient was given zoledronic acid infusion (4 mg) every month. Zoledronic acid was stopped at 18 months and patient was switched to weekly alendronate with a dose of 70 mg per week. He was also given radiotherapy at a dose of 8 Gy (single dose) 2 weeks prior to surgery. This dose was given after consultation with a senior radiotherapy consultant at a tertiary care hospital specializing in cancer treatment.

The patient was taken for surgery in prone position under general anesthesia. Following midline exposure, bilateral T8–T12 pedicle screws were passed. Pedicle screws were passed on the left side from T1 to T3. The right-sided pedicle and body were cystic as confirmed by palpating with a ballpoint probe. Hence, MRI-compatible sublaminar cables were passed from T1 to T3 on the right side. D5 and D6 laminae were soft and were excised. Thorough cord decompression was done. D4 and D5 bodies were excised. The excised bones were sent for histopathological examination. Contoured rod was applied and sequentially tightened. The deformity was fully corrected following fixation. The proximal end of the right-sided rod was bent and the bent part was put between the spinous process of C7 and T1 to provide additional stability.

Bilateral fibulae and cancellous graft from right posterior iliac crest were harvested from the patient's mother after both patient and mother were found to be ABO and Rh compatible in preoperative blood testing. The mother's bone was used as there were chances that the harvested patient's bone might get resorbed. Anterior reconstruction was done via posterolateral approach using cancellous bone graft and two pieces of strut fibulae. Posterior fusion was done using two long struts of fibula bridging the laminectomy defect. Additional matchstick graft prepared from remaining fibulae was placed posteriorly [Figure 2c]. The wound was closed over a drain.

Histopathology revealed decreased bony trabeculae with irregular vascular formations. The bony trabeculae seemed to be replaced by fibrous tissue. The fibrous tissue demonstrated not only increased number of blood vessels but also the absence of cellular atypia/granulomas. The number of osteoclastic giant cells were increased. The material was negative for any fungal or bacterial organisms. No specific diagnosis was obtained on histology. Due to the unavailability of facility to take microscopic images at our institute, the pathology images could not be provided.

Postoperative X-ray showed full correction of deformity [Figure 2a and b]. The drain was removed on 4th postoperative day. The patient started regaining power on 7th postoperative day and had a complete neurological recovery at 5-week postoperatively. The patient was mobilized with a total contact brace. X-rays at followup showed that resorption of ribs had not progressed. X-ray at 1-year postoperatively showed that alignment is maintained [Figure 3a and b]; however, consolidation of the anterior graft was not seen. A CT scan showed an anterior void and the fibulae had not united with the host bone [Figure 3c].

The patient was taken for surgery in the lateral position and the nonunion site exposed via left transthoracic approach. No rib was excised and the plane between the 5th and 6th rib was utilized to reach the nonunion site. Both fibulae struts were removed and fibrous tissue excised. The mother's tricortical iliac crest bone graft was harvested and used for anterior reconstruction.

At 7-month followup, the patient has no neurological deficit and walks with a total contact brace. Radiographs revealed maintained alignment [Figure 4a and b]. CT showed that anterior strut graft has not resorbed; however, it still has not united with the host bone [Figure 4c]. Since patient remained asymptomatic, we have kept the patient on monthly monitoring with X-ray check.

DISCUSSION

The mechanism of bone resorption in GD is still unclear. Increased activation of local osteoclasts is the foremost theory. Heyden *et al.* noticed that perivascular cells in areas of osteolysis might act as osteoclast precursors as

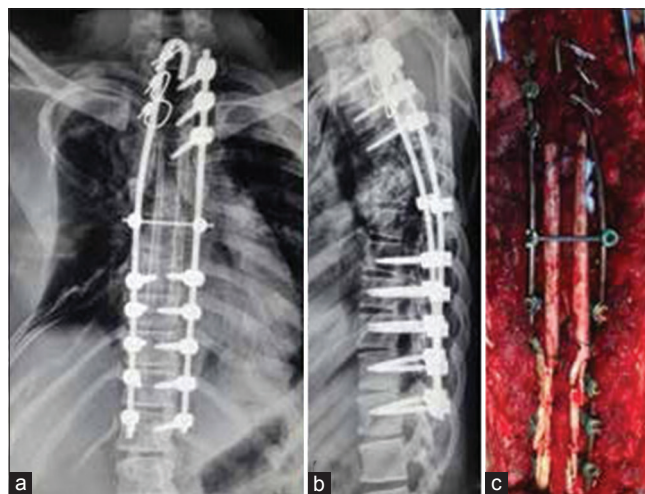


Figure 2: (a and b) Postoperative X-ray dorsal spine anteroposterior and lateral views showing full correction of scoliosis with implant *in situ* (c) Peroperative photograph showing posterior fixation and reconstruction using fibulae

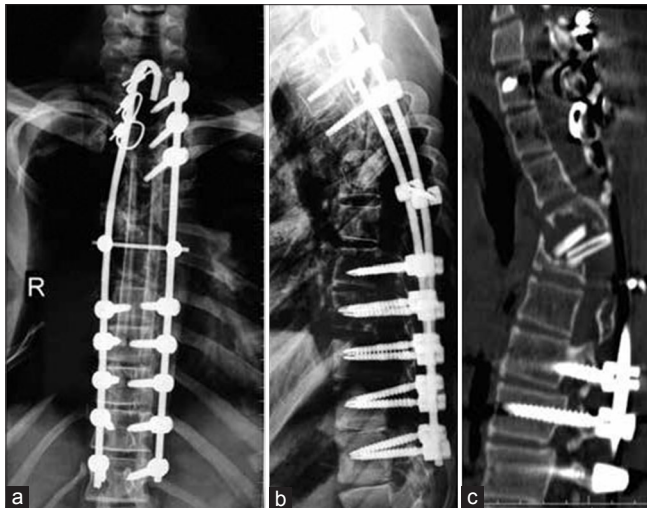

Figure 3: (a and b) Radiographs of dorsal spine anteroposterior and lateral views at 1 year followup showing maintenance of alignment; however, anterior fusion is not seen. (c) Computed tomography scan at one year showing anterior void and fibulae had not united

they demonstrate strong acid phosphatase and leucine aminopeptidase activities.⁷ This leads to an increase in local osteoclastic activity causing resorption of bone. Histologic studies have shown increased proliferation of vascular and lymphatic tissues in areas of osteolysis. Although the exact mechanism of this proliferation is not known, cytokines involved in angiogenic pathways such as platelet-derived growth factor, interleukin 6 (IL-6), vascular endothelial growth factor (VEGF), and lymphatic vessel endothelial hyaluronan receptor 1 may be involved.⁸ Mechanical pressure caused by increased vascular tissue may be one of the causes of resorption of bone. Other mechanisms proposed are dysplasia of local lymphatic and blood vessels, primary aberration of vascular tissue due to granulation tissue in bone, and activation of local hydrolytic enzymes due to local hypoxia and acidosis induced by angiomas.^{3,9,10}

Four stages have been described for the radiologic appearance of GD.³ The first stage involves the appearance of intramedullary and subcortical radiolucent foci resembling patchy osteoporosis. Concentric shrinkage in tubular bones with tapering of the involved ends occurs in the second stage. This results in a “sucked candy” appearance. In the third phase, cortical erosion along with local invasion of the angiomas into the adjacent soft tissue appears. The fourth stage is characterized by the disappearance of the remaining bone. Progression of the osteolytic process into multiple contiguous bones may occur at this stage.

Gorham and Stout described a marked increase in the number of capillaries first within the affected bones, which are found to be dilated and filled with red blood cells.² They noticed that these vessels do not disappear after bone

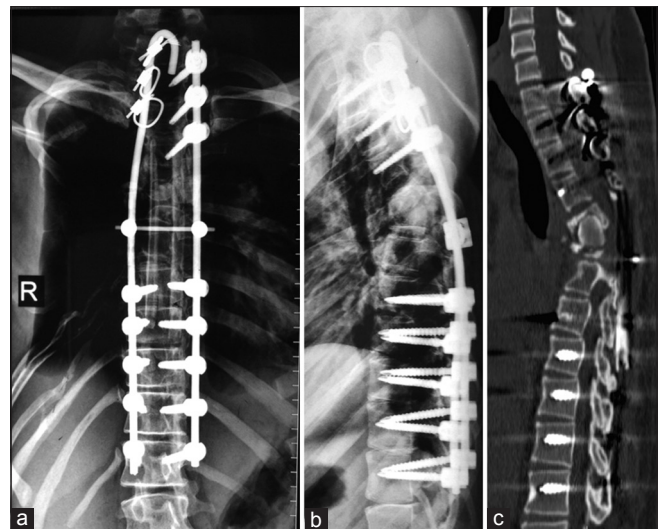


Figure 4: (a and b) Anteroposterior and lateral radiographs of dorsal spine at 7 months followup showing maintenance of alignment. (c) Computed tomography scan at 7 months following anterior reconstruction showing that tricortical graft has not resorbed but no fusion at graft host bone interface

resorption but remain as a vascular growth closely resembling that found within the marrow spaces, or as a sponge-like meshwork of anastomosing vascular spaces. Histological examination of the affected bone shows replacement of absorbed bone by fibrous connective tissue, with marked proliferation of thin-walled vessels and anastomosing dilated endothelium-lined spaces that sometimes contain red blood cells. King suggested “hemangiomas” for description of these pathological findings.¹¹

Multiple reports have shown the efficacy of bisphosphonates in the treatment of GD.^{6,9,12,13} Some histologic studies have suggested that osteolysis in GD is due to increased local number of stimulated osteoclasts. By inhibiting the action of osteoclasts, bisphosphonates prevent resorption of bone. In addition to this, bisphosphonates may normalize serum levels of IL-6, thus reducing the osteoclastic activity.⁸ Bisphosphonates have also shown to be having good analgesic effect. Bisphosphonates have not shown to cause bone formation in areas of osteolysis, but they have demonstrated efficacy in prevention of further resorption of bone and reduction of local symptoms. However, the dosage and duration for which bisphosphonates are to be used is uncertain. A case report showed the use of bisphosphonates for a period of 17 years with moderate success.¹² Another report showed the efficacy of monthly dose of 4 mg of zoledronic acid given for a period of 12 months.¹⁴ We used 4 mg zoledronic acid infusion every month for 18 months while closely monitoring for any side effects. Usually, zoledronic acid is given at a dose of 4 mg once a year. The long term effects of monthly infusion of zoledronic acid are not known as such high dose has been

rarely used. There have been previous reports which have shown the efficacy of oral bisphosphonates in the treatment of GD. In addition, indoor admission is needed for giving IV infusion and due to financial constraints, our patient could not afford monthly infusions of zoledronic acid. Due to these reasons, after 18 months the patient was started on oral alendronate at a dose of 70 mg weekly.

Localized radiotherapy has also shown to be effective in halting the progression of disease with a few reports also showing new bone formation.^{3,6,15} The exact mechanism is not known but it is postulated that radiotherapy may arrest endothelial cell proliferation and limit the progression of disease.^{16,17} Radiation doses of 40–45 Gy in 2 Gy fractions have been shown to yield remission rates as high as 60%. Radiotherapy may also be used in patients who are poor surgical candidates and also patients who have failed surgical treatments. Recalcification which is exceedingly rare with other treatment modalities was shown by Choma *et al.* in 5 of 18 cases of GD treated with radiotherapy.⁵ Following the use of bisphosphonates and radiotherapy, we noted a halt in the progression of osteolysis [Figure 5].

Among other medical therapies, interferon alpha-2b has been used.^{17,18} The proposed mechanism of action is down-regulation of VEGF, which leads to the inhibition of vascular proliferation. It may also inhibit proliferation and migration of lymphatic endothelial cells. It suppresses the growth of both osseous and soft tissue lesions. If used for treatment, long term use has to be done (usually more than 1 year) as symptoms tend to improve after 10–16 months. Moreover, it has many side effects like hematological toxicity, hepatotoxicity, nausea, and psychiatric side effects. Thus, it has to be used with caution and strict monitoring. Bevacizumab is another VEGF inhibitor which has been

successfully used in one pediatric patient with GD.¹⁹ There is no current evidence for its use for GD in adults.

GD of spine is extremely rare. Aizawa *et al.* published a review of 28 cases of GD of spine in 2005.⁶ To the best of our knowledge, 13 cases of GD of spine have been reported after 2005.^{8,20-31} A brief review of these cases with treatment and outcome has been shown in Table 2. Out of the total 41 reported cases of GD of spine, cervical spine is the most commonly affected with 11 cases involving only cervical spine and additional 6 cases involving cervicothoracic spine. Thoracic spine is the second most commonly affected area. Majority of the patients with spine involvement are less than 20 years old. GD of spine is more common in males ($n = 28$) as compared to females ($n = 13$).

Pleural effusion has been reported in 22 of the 41 cases of GD of spine. Of these, 9 patients expired (mortality of 41%). Most of these effusions were due to chylothorax. Chylothorax is thought to be due to disruption of thoracic duct or pleural lymphatics by adjoining osteolysis. Due to high mortality, any evidence of pleural effusion or respiratory discomfort must not be ignored and investigated promptly.

Out of the 41 cases reported, surgical management was done in 18 patients. Neurological deficit is the most common indication for surgery. Posterior instrumented fusion is the most common surgery performed; however, the rates of fusion are very poor. Only 4 of the patients have documented fusion following the first surgery and fusion was not accomplished in nearly half of the patients even after multiple surgeries.⁶ Use of bone morphogenetic protein-2 (BMP-2) may enhance fusion rates.⁸ Due to financial constraints, we could not use allograft or BMP-2 in our patient. Autografts have high rates of resorption when used for reconstruction. Hence, his mother's bone was utilized for reconstruction after ABO and Rh compatibility testing. Two long pieces of fibula from the mother were placed posteriorly to bridge the affected area. The grafted bone did not get resorbed but probably due to the pathological bone at graft-host interface, the anterior union could not be achieved following the first surgery. Posterior fusion could not be assessed on CT scan due to interference from the implant. A second transthoracic anterior grafting using mother's tricortical iliac crest graft was done. CT scan at 7 months still showed that although the graft did not get resorbed, the union at the graft-host interface was not present.

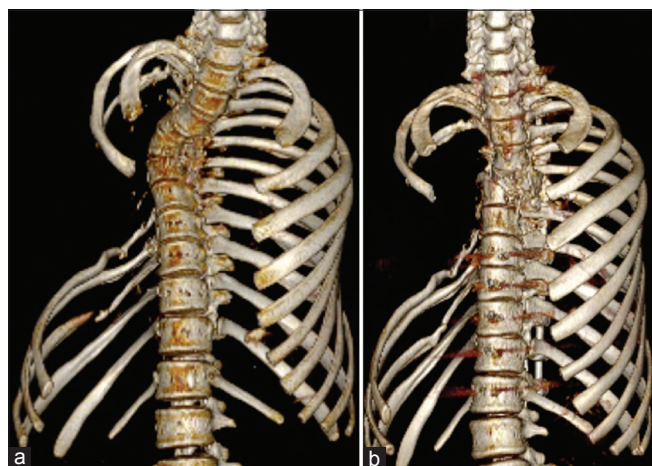


Figure 5: Three-dimensional reconstruction of chest wall before (a) and 18 months after (b) radiotherapy and monthly zoledronic acid (scapula and sternum digitally subtracted) showing that osteolysis in the ribs has not progressed

After managing this case, we learned that in the presence of neurological deficit, decompressive surgery must be done even though fusion rates are poor. Adequate decompression

Table 2: Review of cases of Gorham disease of spine reported in the last 10 years

Author (year)	Age	Sex	Affected vertebra	Neurological deficit	Treatment for spine and adjuvant medical management	Pleural effusion	Results
Adler <i>et al.</i> (2011)	7	Female	Lumbosacral, pelvis with CSF leakage	Nil	Interferon alpha-2b + zoledronate for 12 months followed by oral calcium supplementation and alendronate CT-guided blood patch done thrice to stop CSF leak	Not mentioned	Continues to have mild positional headaches and evidence of intracranial hypotension
Sahoo <i>et al.</i> (2012)	12	Male	D1-D2 with kyphosis	Myelopathy	Decompression and fusion. Details of adjuvant treatment not available	Absent	Followup details are not available
Sekharappa <i>et al.</i> (2013)	15	Male	D6 collapse with kyphosis. Absent 3 rd -7 th rib on the left side	Myelopathy	Decompression, pedicular screw fixation, and fusion. Details of adjuvant treatment not available	Absent	Fusion achieved, no progression of osteolysis
Sekharappa <i>et al.</i> (2013)	23	Male	Kyphosis at D1-D2 with lytic lesions in multiple vertebrae	Myelopathy	Stage 1: Pedicular screw and decompression. Patient had neurological recovery but presented with implant breakage after 15 months Stage 2: Revision fixation. Patient developed complete paraplegia Stage 3: Decompression done on same day as revision fixation Stage 4: Revision decompression after 3 days Details of adjuvant treatment not available	Present	No clinical progression of disease. Neurological deficit improved minimally. Mobilized with orthosis
Esmailiejah <i>et al.</i> (2013)	32	Female	L3 lesion	Cauda equine compression	Anterior approach. Decompression and fixation. Reconstruction with mesh cage. Details of adjuvant treatment not available	Present	No progression of disease. Neurological improvement. Status of fusion on mentioned
Barman <i>et al.</i> (2013)	23	Male	Midthoracic kyphosis with lytic lesions in multiple vertebrae	Myelopathy	Stage 1: Cervicothoracic stabilization. Had near complete neurological recovery Stage 2: Breakage of both rods at 9 months. Revision surgery was done. Patient developed complete paraplegia postoperative Oral ibandronate 150 mg (duration and frequency of dosing not mentioned)	Present	Regained minimal motor power. However, was not independently mobile
Huang <i>et al.</i> (2013)	34	Male	Thoracolumbar kyphosis with collapse T12-L1. Absent multiple ribs on left side. Multiple vertebral lytic lesions	Early myelopathy	Deformity correction instrumented posterior fusion with strut allografting. Details of adjuvant treatment not available Patient received intensive care due to respiratory complications	Present	Long term ICU and ventilator support needed due to respiratory complications. Followup not mentioned
Kilicoglu <i>et al.</i> (2013)	35	Male	Rarefaction of the osseous structures of the occipital bone, clivus, and the first two cervical vertebrae	Nil	Craniocervical fixation and fusion attempted 4 times. Details of adjuvant treatment not available	Not mentioned	The desired result could not be achieved. The patient had to mobilize with a cervical collar
Maillot <i>et al.</i> (2014)	30	Female	T4 pathological fracture with localized kyphosis	Myelopathy	Deformity correction, pedicular screw fixation, fusion using local bone graft plus BMP-2 Intravenous zoledronic acid for 3 years (frequency of dosing not mentioned)	Present	Full neurological recovery. Fusion achieved
Suero Molina <i>et al.</i> (2014)	26	Male	T12-L1 lytic lesion with compression fracture	Nil	Posterior instrumented fusion. Subcutaneous interferon alpha-2b and monthly pamidronic acid infusions	Present	The patient developed CSF leakage 4 years after surgery. Treated surgically. Recovered fully
Kakuta <i>et al.</i> (2014)	49	Male	L4 lytic lesion with an aortic aneurysm	Nil	Anterior debridement, reconstruction with cage (filled with local bone graft) plus posterior instrumented fusion. Details of adjuvant treatment not available	Not mentioned	Fusion achieved

Contd...

Table 2: Contd...

Author (year)	Age	Sex	Affected vertebra	Neurological deficit	Treatment for spine and adjuvant medical management	Pleural effusion	Results
Carbó <i>et al.</i> (2015)	10	Male	Lytic lesions in multiple vertebrae	Nil	L3, L4 vertebroplasty Radiation therapy, intravenous zoledronic acid, and interferon alpha-2b was unsuccessful	Not mentioned	No progression of disease. Pain relieved
Kim <i>et al.</i> (2015)	12	Male	Cervical spine lytic lesion with extensive maxillofacial involvement	Nil	Biopsy from mandible Pamidronate 30 mg monthly for 21 months radiotherapy 25 Gy then stopped Interferon alpha-2b	Present	Died due to respiratory failure

CSF=Cerebrospinal fluid, BMP-2=Bone morphogenetic protein-2, CT=Computed tomography, ICU=Intensive Care Unit

and deformity correction gives excellent neurological recovery. Bisphosphonates and localized radiotherapy are effective in halting the progression of osteolysis. A regular followup and CT scan are necessary to diagnose nonunion at the earliest. If left untreated, nonunions are known to cause implant failure, hence revision surgery and bone grafting using strut graft must be done if required.

Vanishing bone disease is extremely rare and its etiology and pathogenesis is still not clear. Bisphosphonates and local radiotherapy are effective in halting the progress of osteolysis. Since pedicles and body might be cystic, one must be prepared to use sublaminar wires for fixation. Achieving union in such patients is difficult and multiple surgeries may be needed to achieve union.

Financial support and sponsorship

Nil.

Conflicts of interest

There are no conflicts of interest.

REFERENCES

- Jackson JB. A boneless arm. *Boston Med Surf* 1838;18:368-9.
- Gorham LW, Stout AP. Massive osteolysis (acute spontaneous absorption of bone, phantom bone, disappearing bone); its relation to hemangiomas. *J Bone Joint Surg Am* 1955;37-A:985-1004.
- Daneshvar Kakhaki A, Khodadad K, Pejhan S, Karimi S, Arab M, Saghebi R, *et al.* Gorham's disease with chest wall involvement: A case report and a review of the literature. *Iran Red Crescent Med J* 2014;16:e12180.
- Heffez L, Doku HC, Carter BL, Feeney JE. Perspectives on massive osteolysis. Report of a case and review of the literature. *Oral Surg Oral Med Oral Pathol* 1983;55:331-43.
- Choma ND, Biscotti CV, Bauer TW, Mehta AC, Licata AA. Gorham's syndrome: A case report and review of the literature. *Am J Med* 1987;83:1151-6.
- Aizawa T, Sato T, Kokubun S. Gorham disease of the spine: A case report and treatment strategies for this enigmatic bone disease. *Tohoku J Exp Med* 2005;205:187-96.
- Heyden G, Kindblom LG, Nielsen JM. Disappearing bone disease. A clinical and histological study. *J Bone Joint Surg Am* 1977;59:57-61.
- Maillot C, Cloche T, Le Huec JC. Thoracic osteotomy for Gorham-Stout disease of the spine: A case report and literature review. *Eur Spine J* 2014. [Epub ahead of print].
- Young JW, Galbraith M, Cunningham J, Roof BS, Vujic I, Gobien RP, *et al.* Progressive vertebral collapse in diffuse angiomatosis. *Metab Bone Dis Relat Res* 1983-1984;5:53-60.
- Thompson JS, Schurman DJ. Massive osteolysis. Case report and review of literature. *Clin Orthop Relat Res* 1974;(103):206-11.
- King DJ. A case resembling hemangiomas of the lower extremity. *J Bone Joint Surg Am* 1946;28:623-8.
- Lehmann G, Pfeil A, Böttcher J, Kaiser WA, Füller J, Hein G, *et al.* Benefit of a 17-year long term bisphosphonate therapy in a patient with Gorham-Stout syndrome. *Arch Orthop Trauma Surg* 2009;129:967-72.
- Patel DV. Gorham's disease or massive osteolysis. *Clin Med Res* 2005;3:65-74.
- Avelar RL, Martins VB, Antunes AA, de Oliveira Neto PJ, Andrade ES. Use of zoledronic acid in the treatment of Gorham's disease. *Int J Pediatr Otorhinolaryngol* 2010;74:319-22.
- Hu P, Yuan XG, Hu XY, Shen FR, Wang JA. Gorham-Stout syndrome in mainland China: A case series of 67 patients and review of the literature. *J Zhejiang Univ Sci B* 2013;14:729-35.
- Heyd R, Micke O, Surholt C, Berger B, Martini C, Füller J, *et al.* Radiation therapy for Gorham-Stout syndrome: Results of a national patterns-of-care study and literature review. *Int J Radiat Oncol Biol Phys* 2011;81:e179-85.
- Dunbar SF, Rosenberg A, Mankin H, Rosenthal D, Suit HD. Gorham's massive osteolysis: The role of radiation therapy and a review of the literature. *Int J Radiat Oncol Biol Phys* 1993;26:491-7.
- Dupond JL, Bermond L, Runge M, de Billy M. Plasma VEGF determination in disseminated lymphangiomas- Gorham-Stout syndrome: A marker of activity? A case report with a 5-year followup. *Bone* 2010;46:873-6.
- Grunewald TG, Damke L, Maschan M, Petrova U, Surianinova O, Esipenko A, *et al.* First report of effective and feasible treatment of multifocal lymphangiomas (Gorham-Stout) with bevacizumab in a child. *Ann Oncol* 2010;21:1733-4.
- Adler F, Gupta N, Hess CP, Dowd CF, Dillon WP. Intraosseous CSF fistula in a patient with Gorham disease resulting in intracranial hypotension. *AJNR Am J Neuroradiol* 2011;32:E198-200.
- Sahoo RK, Jagannathan B, Palanichamy G, Natarajan V. Anaesthetic consideration in patients with Gorham's syndrome: A case report and review of the literature. *Indian J Anaesth* 2012;56:391-3.
- Sekharappa V, Arockiaraj J, Amritanand R, Krishnan V,

- David KS, David SG. Gorham's disease of spine. *Asian Spine J* 2013;7:242-7.
23. Esmailiejah AA, Kamalian N, Abbasian M. Temporary paraplegia resulting from Gorham's disease involving the third lumbar vertebra and proximal femur: A five-year followup and review of the literature. *Arch Iran Med* 2013;16:686-90.
 24. Barman A, Bhide R, Viswanathan A, George J, Thomas R, Tharion G. Gorham's disease of the spine. *NeuroRehabilitation* 2013;33:121-6.
 25. Huang SY, Lee YM, Tzeng ST, Su CP, Huang SF, Wu YK, *et al.* Gorham syndrome with postoperative respiratory failure and requiring prolonged mechanical ventilation. *Respir Care* 2013;58:e144-8.
 26. Lala S, Mulliken JB, Alomari AI, Fishman SJ, Kozakewich HP, Chaudry G. Gorham-Stout disease and generalized lymphatic anomaly – Clinical, radiologic, and histologic differentiation. *Skeletal Radiol* 2013;42:917-24.
 27. Kilicoglu ZG, Kizildemir Kis N, Vardar Aker F, Berkman MZ, Simsek MM. Gorham disease of the craniocervical junction: X-ray, computed tomography, and magnetic resonance imaging findings. *Spine J* 2013;13:e11-4.
 28. Suero Molina EJ, Niederstadt T, Ruland V, Kayser G, Stummer W, Ewelt C, *et al.* Cerebrospinal fluid leakage in Gorham-Stout disease due to dura mater involvement after progression of an osteolytic lesion in the thoracic spine. *J Neurosurg Spine* 2014;21:956-60.
 29. Kakuta Y, Iizuka H, Kobayashi R, Iizuka Y, Takahashi T, Mohara J, *et al.* Gorham disease of the lumbar spine with an abdominal aortic aneurysm: A case report. *Spine J* 2014;14:e5-9.
 30. Carbó E, Riquelme Ó, García A, González JL. Vertebroplasty in a 10-year-old boy with Gorham-Stout syndrome. *Eur Spine J* 2015;24 Suppl 4:S590-3.
 31. Kim MK, Hong JR, Kim SG, Lee SK. Fatal progression of Gorham disease: A case report and review of the literature. *J Oral Maxillofac Surg* 2015. pii: S0278-239100822-8.