Behavior Research Methods & Instrumentation
1977, Vol. 9 (6), 501-502

A method of cannula implantation for young chickens

LARRY B. WALLNAU and SUSAN SUAREZ-LIUZZI
State University of New York, Albany, New York 12222

A method is described for securely anchoring cannula implantations on 2- to 4-week-old chickens.

Due to confounding peripheral effects and problems related to the blood-brain barrier, the intraventricular administration of drugs is often the most straightforward manipulation for the study of the neurochemical bases of behavior (e.g., Iverson & Iverson, 1975; Wallnau & Gallup, 1977). Such studies have been performed on young chickens (e.g., Harston, Sibley, Gallup, & Wallnau, 1976), but not without losing animals due to dislodged cannula assemblies. As opposed to older birds, the skulls of younger animals are not fully developed and it is troublesome to securely anchor an implantation assembly to the soft and spongy cranial surface with the standard technique of small screws and cement. Not only does the age of the animal (2-4 weeks) pose a problem, but in some instances they must be socially housed following recovery from anesthesia. Social housing is necessary because isolated chickens often display atypical behaviors, for example, in aggressive behavior (Rejecki, Ivins, & Rein, 1976) and predator defense (Gagliardi & Gallup, Note 1). Group housing necessitates a securely anchored implantation device because socially housed animals tend to peck the implants of their cage mates. A method of anchoring intraventricular devices is described.

METHOD

A 14-mm length of 23-ga stainless steel serves as a cannula guide. A 3.5-cm length of surgical steel suture wire (Pitman-Moore, 4-0 veterinary sutures) is then wrapped once around the cannula guide, 6 mm from the top of the guide barrel. Using stainless steel solder and flux, the wire is soldered in place (see Figure 1). Prior to surgery, animals are given 1.5 ml of Chloropent anesthesia (Fort Dodge) intraperitoneally. This initial injection serves to maintain anesthetization during surgery and mildly sedate the animal prior to an otherwise aversive intravenous injection. Approximately 5 min later, animals receive an additional injection of Chloropent via the wing vein (*V. cutanea ulnaris*). This injection is administered slowly (longer than 60 sec) until a firm pinch of the animal's comb no longer elicits reflexive responding. Occasionally the chickens (about 10% of subjects) require an additional intravenous injection of Chloropent during surgery.

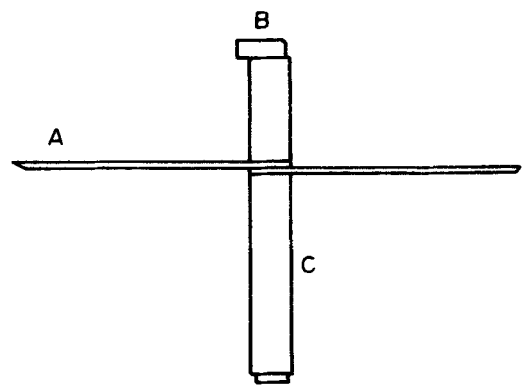

Figure 1. Cannula assembly: (A) anchor wire, (B) filler wire, (C) guide cannula.

With a small level placed on the three cranial crests of the exposed skull, the chicken's head is made level relative to the stereotaxic frame. A trephine hole is drilled on the midline and 2 mm anterior to the frontal-parietal suture for the cannula guide. Two additional holes are made, one on each frontal crest. All trephine holes are drilled with a hand chuck fitted with a .067-in. drill bit. The bit is partially covered with a plastic sleeve to prevent it from entering brain tissue.

The cannula guide is lowered stereotactically into the appropriate trephine hole (about 5-6 mm ventral to the cranial surface for 2- to 4-week-old chickens). The ends of the surgical wire are trimmed and small loops are made on each end with forceps. These loops are then inserted into the trephine holes on each frontal crest (Figure 2). Dental cement is applied to the cranial surface around the cannula guide and built up until the anchor wire is covered. As with any implantation, a clean and dry cranial surface is essential. The incision is closed with suture thread (nonabsorbable nylon, Size 00), using approximately 15 sutures to close a 1.5- to 2-cm incision. The use of densely packed sutures

Requests for reprints should be sent to Larry B. Wallnau, Department of Psychology, SUNYA, Albany, New York 12222.
The authors wish to thank Dr. A. van Tienhoven for instructions on anesthetization and carotid perfusion of domestic fowl and Dr. Gordon G. Gallup, Jr. for comments on an earlier version of this paper.

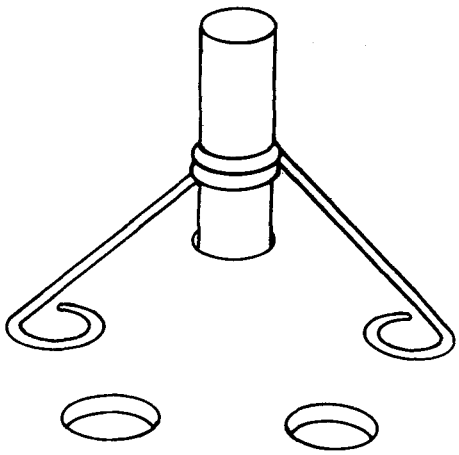

Figure 2. Cannula guide is lowered into the midline trephine hole. Loops formed at ends of anchor wire are inserted into the holes drilled on the frontal crests.

Figure 3. PE 20 tubing is connected to the needle of microliter syringe (A), and is placed over the 30-ga inner cannula (B), exposing 14.5 mm.

prevents the incision from reopening under conditions of social housing. Following closure, an antibacterial dressing (e.g., Wound Powder, Fort Dodge) is applied to the incision.

A piece of 30-ga tubing is inserted into the cannula such that it extends .5 mm below the bottom of the guide barrel. The top of the filler wire is bent prior to its insertion, so that it serves as a stop (Figure 1). A small collar (3 mm in length) of polyethylene tubing (Intramedic 7430, I. D. .045 in. by O.D. .062 in.) can be placed around the top of the cannula to prevent the filler wire from slipping out. A piece of 30-ga tubing is also used as an inner cannula, and is inserted in place of the filler wire so that it extends .5 mm below the end of the cannula guide. In order to prevent an extension greater than .5 mm, a piece of polyethylene tubing (Intramedic PE 20, I.D. .015 mm by O.D. .043 in.) is placed on the inner cannula, exposing 14.5 mm of 30-ga tubing (Figure 3). It may be necessary initially to stretch the PE 20 tubing over low heat and then trim the stretched section, to make it fit firmly over the inner cannula. The PE 20 tubing is in turn connected to the needle of a microliter syringe (Figure 3).

Birds are provided with a 24-h recovery period prior to being returned to social housing. Tissue damage is minimal, limited to the cannula tract, and animals do not display behavioral abnormalities following recovery. The loops on the anchor wire seldom break the dura, but often stretch it slightly ventral from the skull. This method of cannula implantation has been used successfully in our laboratory without a significant loss of animals or time due to the casualties of dislodged implantation assemblies.

REFERENCE NOTE

1. Gagliardi, G. J., & Gallup, G. G., Jr. *Social isolation and tonic immobility.* Paper presented at the meeting of the Eastern Psychological Association, Boston, April 1977.

REFERENCES

Harston, C. T., Sibley, D. H., Gallup, G. G., Jr., & Wallnau, L. B. Effects of intraventricular injections of imipramine and 5-hydroxytryptamine on tonic immobility in chickens. *Bulletin of the Psychonomic Society*, 1976, **8**, 403-405.

Iverson, S. D., & Iverson, L. L. *Behavioral pharmacology.* New York: Oxford University Press, 1975.

Rejecki, D. W., Ivins, B., & Rein, B. Social discrimination and aggressive pecking in domestic chicks. *Journal of Comparative and Physiological Psychology*, 1976, **90**, 442-452.

Wallnau, L. B., & Gallup, G. G., Jr. A serotonergic, midbrain-raphe model of tonic immobility. *Biobehavioral Reviews*, 1977, **1**, 35-43.

(Accepted for publication September 12, 1977.)