

Conference Abstract

P.48 Ultrasound-Based Velocity and Acceleration of the Carotid Atheromatous Plaque in Asymptomatic Patients with Moderate and Severe Stenosis

Kalliopi Dalakleidi^{1,*}, Spyretta Golemati², Aimilia Gastounioti³, Christos Liapis⁴, Konstantina Nikita¹

¹Biomedical Simulations and Imaging Lab., School of Electrical and Computer Engineering, National Technical University of Athens

²Medical School, National and Kapodistrian University of Athens

³Department of Radiology, University of Pennsylvania

⁴Attikon University General Hospital, Medical School, National and Kapodistrian University of Athens

Keywords

Plaque
 motion
 carotid
 ultrasound

ABSTRACT

Purpose: The purpose of this study was to investigate differences in ultrasound-based velocities and accelerations of the carotid atheromatous plaque between asymptomatic patients with moderate and severe stenosis, based on the assumption that plaque motion features are sensitive to cardiovascular health status.

Methods: The dataset used consists of 38 sequences of B-mode images (videos) of carotid atheromatous plaque of asymptomatic patients. Among the examined carotid arteries, 27 had severe stenosis degrees (>70%) and 11 had moderate stenosis degrees (<70%). Plaque motion estimation was based on an adaptive block matching methodology which incorporates Kalman filtering update strategies. Plaque velocity and acceleration were calculated by differentiating displacement and velocity, respectively. The two-tailed *t*-test was used to assess statistically significant differences.

Results: Figure shows examples of plaque velocity and acceleration waveforms. Radial and longitudinal plaque velocities were similar between moderate and severe cases (0.43 ± 0.15 mm/s and 0.73 ± 0.18 mm/s, respectively, vs. 0.37 ± 0.21 mm/s and 0.65 ± 0.20 mm/s, respectively; *p*-values 0.35 and 0.27, respectively). Radial and longitudinal plaque accelerations were significantly higher in moderate compared to severe stenosis cases (7.07 ± 4.64 mm/s² and 10.08 ± 5.22 mm/s², respectively, vs. 3.17 ± 2.25 mm/s² and 5.05 ± 2.96 mm/s², respectively; *p*-values = 0.00 for both cases). In moderate stenoses, longitudinal velocities, but not accelerations, were significantly higher than radial ones, whereas in severe stenoses, longitudinal velocities and accelerations were significantly higher than radial ones.

Conclusion: Ultrasound-based velocities and accelerations can characterise biomechanical phenomena of the carotid plaque. Accelerations can differentiate between moderate and severe plaque.

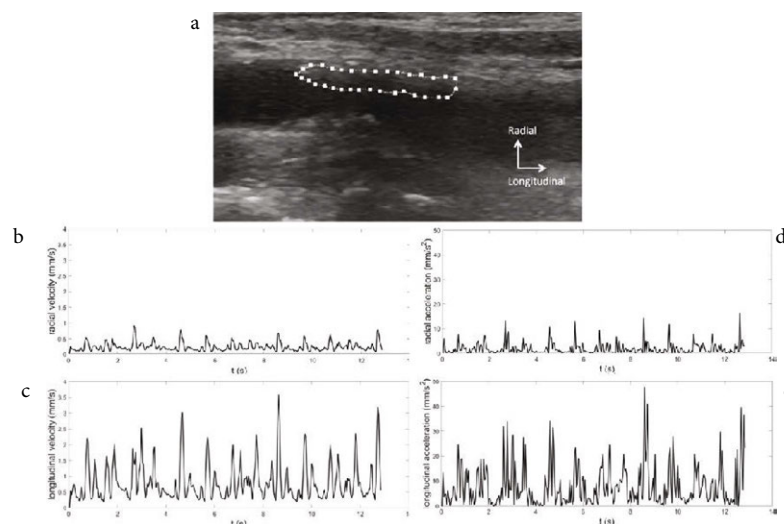


Figure (a) Example of ultrasound image of the carotid artery with the atheromatous plaque outlined in white. (b), (c) waveforms of radial and longitudinal velocities, respectively, of the plaque in (a). (d), (e) waveforms of radial and longitudinal accelerations, respectively, of the plaque in (a).

© 2020 Association for Research into Arterial Structure and Physiology. Publishing services by Atlantis Press International B.V. This is an open access article distributed under the CC BY-NC 4.0 license (<http://creativecommons.org/licenses/by-nc/4.0/>).