

Type I focal cortical dysplasia: surgical outcome is related to histopathology

Laura Tassi¹, Rita Garbelli², Nadia Colombo³,
Manuela Bramerio⁴, Giorgio Lo Russo¹, Francesco Deleo²,
Gloria Milesi², Roberto Spreafico²

¹ C. Munari Epilepsy Surgery Centre

² Division of Epilepsy Clinic and Experimental Neurophysiology, C. Besta Neurological Institute IRCCS Foundation, Milan

³ Department of Neuroradiology, C. Besta Neurological Institute IRCCS Foundation, Milan

⁴ Department of Pathology, Niguarda Hospital, C. Besta Neurological Institute IRCCS Foundation, Milan, Italy

Received March 9, 2010; Accepted June 16, 2010

ABSTRACT – Pre-surgical and post-surgical data were examined and compared from 215 consecutive patients undergoing surgery for intractable epilepsy. Patients were selected on the basis of a proven histopathological diagnosis of type I focal cortical dysplasia (FCD I), alone or associated with other lesions. The patients were divided into five sub-groups: *i*) 66 with isolated FCD I, *ii*) 76 with FCD I and hippocampal sclerosis, *iii*) 49 with FCD I and tumours, *iv*) 16 with FCD I and other malformations of cortical development and *v*) eight with FCD I and anoxic-ischaemic or inflammatory diseases. The duration of epilepsy was greatest in patients with FCD I associated with hippocampal sclerosis, and those with isolated FCD I showed the highest seizure frequency at the time of surgery. Hippocampal sclerosis and tumours were the most frequent pathological lesions associated with FCD I in temporal lobe epilepsy. Febrile seizures significantly correlated with the presence of hippocampal sclerosis and FCD I. Isolated FCD I was observed in 31% of the patients, characterized by frequent seizures, negative magnetic resonance imaging, and frequent frontal or multilobar involvement. In comparison to patients with FCD I associated with hippocampal sclerosis, MCD or tumours, the patients with isolated FCD I had a worse post-surgical outcome (46% in class I). Our findings indicate that there is a high incidence of FCD I associated with other apparently distinct pathologies, particularly those affecting the temporal lobe, and highlight the need for a comprehensive clinicopathological approach for the classification of FCD I.

Key words: epilepsy surgery, neuropathology, cortical dysplasia

Correspondence:

R. Spreafico
Division of Epilepsy,
Clinic and Experimental Neurophysiology,
Istituto Nazionale Neurologico “C. Besta”,
Via Celoria 11,
20133 Milano, Italy
<spreafico@istituto-besta.it>

The distinctive focal structural anomalies of the cortex were first described by Taylor *et al.* (1971) which were referred to as “focal cortical dysplasia” (FCD). However, since then, the term has been extensively used in the literature to refer to a wide spectrum of abnormalities of cortical anatomy. The true prevalence of FCD is unknown, and is probably underestimated in studies based on imaging techniques alone due to the presence of false-negative magnetic resonance imaging (MRI) and the

wide range of techniques used. However, FCD accounts for a high percentage of histologically proven findings, ranging from 20% in adults to 50% in paediatric patients undergoing epilepsy surgery (Bast *et al.*, 2006; Luders and Schuele, 2006).

Although a number of classification methods for these complex structural abnormalities have been proposed (Kuzniecky *et al.*, 1991; Palmini *et al.*, 1994; Barkovich and Kuzniecky, 1996), none is considered satisfactory. Barkovich *et al.* (2005) have recently suggested a new classification of different types of malformations of cortical development which is mainly based on MRI findings and genetic data. This classification includes the various subtypes of FCD in different subgroups based on the assumption that they are due to impairment of ontogenetic processes which take place at different stages of embryonic development.

With the aim of developing a more clinically useful classification of FCD, and in order to assess whether the neuropathologically defined subgroups corresponded to clinically homogeneous groups, Tassi *et al.* (2002) re-examined histological specimens from a series of patients who were surgically treated for intractable epilepsy. The results were correlated with electroclinical findings, MRI data and post-surgical outcome. This classification was further refined by Palmini *et al.* (2004), who proposed two main forms of FCD type I, characterised by laminar disruption alone with no major cytological abnormalities (type IA) and the presence of hypertrophic pyramidal-like neurons outside layer V associated with cortical disorganisation (type IB). A second main group, which included cases similar to those originally recognised by Taylor *et al.* (1971), was also characterized by profound cortical disruption with dysmorphic neurons (type IIA) and balloon cells (type IIB). Type II FCDs are considered to be highly epileptogenic and are the easiest form to detect by means of MRI (Colombo *et al.*, 2003; Krsek *et al.*, 2008).

Although many papers on FCD have been published over the last few years, there is still debate concerning the factors that influence surgical outcome. Some authors have found that a favourable surgical outcome is associated with the presence of severe histopathological features (Tassi *et al.*, 2002; Chung *et al.*, 2005; Kim *et al.*, 2009), whereas others have reported contradictory results (Fauser *et al.*, 2004). Furthermore, there is evidence that patients surgically treated for intractable epilepsy associated with FCD have a worse outcome than those undergoing surgery for other focal lesional epilepsy syndromes (Yun *et al.*, 2006). Improvements in neuropathological diagnostics and the publication of some recent molecular biology studies have clearly shown a good clinical correlation between type II FCD and post-surgical outcome, however, the same cannot be said for type I.

Neuropathological examinations of surgical specimens are essential for classifying the variants of FCD and may help to construct a classification of cortical dysplasias; however, findings need to be correlated with pre-surgical electroclinical data and, above all, post-surgical outcome (Blümcke *et al.*, 2009). The aim of this retrospective study was to investigate correlations between neuropathologically identified type I FCD (isolated or associated with other lesions) and the pre-surgical data and post-surgical outcome of a large cohort of patients surgically treated for intractable epilepsy.

Methods

We retrospectively evaluated 215 of 784 (27%) consecutive patients who underwent surgery for intractable epilepsy between May 1996 and May 2007 at the C. Munari Epilepsy Surgery Centre in Milan, Italy. The patients were selected on the basis of a proven histopathological diagnosis of type I FCD, whether isolated or associated with other lesions, and regardless of site. The lesions were classified and then related to the clinical findings, history of risk factors, MRI data, and post-surgical outcome.

All of the patients underwent an extensive pre-surgical evaluation which included the recording of: a detailed personal and family history, age at seizure onset, type of presentation, and the characteristics and frequency of seizures. The clinical records of each patient were carefully reviewed for these data, and only precise descriptions of pathological events were accepted, particularly in the case of febrile seizures. Information was not recorded when the source of the information or the description of the anamnestic data was considered to be unreliable.

All of the patients also underwent a neurological examination, a complete neuropsychological work-up, MRI, and comprehensive electroencephalographic (EEG) or video-EEG (VEEG) examinations (or both). When it was not possible to identify the epileptogenic zone with sufficient precision using electroclinical data and MRI, pre-surgical invasive stereo-EEG (SEEG) was performed (Cossu *et al.*, 2005).

MRI

Pre-operative MR images of all of the patients were obtained using a 1.5 T machine (Philips ACS-III-NT). The MRI protocol (Colombo *et al.*, 2003) included the following transverse double-echo spin-echo (SE) sequences of the entire brain; T2-weighted (w) coronal turbo spin-echo (TSE) T2-WI; coronal TSE fluid-attenuated inversion-recovery (FLAIR) T2-WI; and coronal inversion recovery (IR) T1-WI. Additional FLAIR T2-WI was obtained in the sagittal plane. In patients with temporal lobe epilepsy, images parallel (transverse) and perpendicular (coronal) to the major hippocampal axis were

acquired. Intravenous contrast was injected when a tumoural lesion was suspected. The MRI data were retrospectively reviewed and an assessment was made of all anatomical abnormalities and focal lesions (e.g. tumours, vascular malformations and malformations of cortical development), gyration anomalies, focal thickenings of the cortex, blurring of the grey-white matter junction, abnormal signal intensity in the cortex and white matter, and atrophic changes. Hippocampal alterations were assessed visually with attention to atrophy, increased signals on T2-WI, decreased signals on T1-WI, and the loss of definition of internal structures.

Stereo-EEG procedure

Ninety patients (42%) underwent surgery after invasive SEEG; however the number of patients undergoing SEEG progressively decreased as less invasive approaches became more refined.

SEEG recordings were considered mandatory in patients when determination of the epileptogenic zone was not considered to be sufficiently reliable by means of video-EEG recording, MRI and based on the clinical aspects of the seizures.

The presurgical invasive recording and final surgical strategy were planned only after informed consent had been obtained from the patient or the parents of under-aged or intellectually impaired subjects.

SEEG was tailored to individual anatomical and electro-clinical characteristics following the procedure described by Talairach and Bancaud (1966), and later refined by Munari *et al.* (1985) and Cossu *et al.* (2005).

Surgery

After obtaining informed consent, surgical resection was performed for strictly therapeutic reasons aimed at removing the cortical areas involved in seizure generation. The objective was to remove both the anatomical lesion (when identified) and the cortical epileptogenic zone identified by the electroclinical and MRI investigations, however, in some patients, an incomplete resection was made in order to avoid damaging nearby critical structures. When MRI was uninformative, the resection was planned on the basis of the electroclinical data. The extent of the resection was planned pre-operatively considering the severity of epilepsy and the risk of post-surgical deficits in each case.

Outcome was determined on the basis of Engel's classification (Engel, 1987), and all of the patients were followed for at least two years. Particular attention was paid to patients in Class Ia and Ic (who were completely seizure-free) with respect to the entire Class I [including class Ib; patients with auras, and class Id; patients with seizures after AED (antiepileptic drug) withdrawal]. AEDs

were withdrawn only after a 12-month seizure-free period for class I patients. The reported follow-up and AED data were collected during visits or by telephone.

Histopathological methods

The surgical specimens were fixed in 10% neutral buffered formalin, embedded in paraffin, and routinely processed. Serial 7 μm sections were stained with haematoxylin and eosin, thionin, Luxol fast blue or Bielschowsky; other sections were immunostained using antibodies against glial fibrillary acid protein (GFAP, Boehringer Mannheim, Germany), neurofilaments (2F11 monoclonal, DAKO, Germany), microtubule associated protein (MAP2, Boehringer Mannheim, Germany), and neuron-specific nuclear protein (NeuN, Chemicon International, Temecula, CA). The slides were independently reviewed by two neuropathologists, one of whom had not been involved in the initial diagnoses and was unaware of the electroclinical data, MRI findings and surgical outcome. Any disagreements were discussed until an agreed diagnosis was reached.

The following criteria were used for making the final diagnosis:

- tumours were histopathologically typed according to the World Health Organisation (WHO) Classification of Tumours (Louis *et al.*, 2007);
- hippocampal sclerosis was diagnosed in the presence of diffuse gliosis associated with pyramidal cell loss in the CA1, CA3 and CA4 (hilus) sectors of Ammon's horn (CA) (for references see Blümcke *et al.*, 2007);
- the diagnosis of FCD was based on the two main morphological types described in the classification by Tassi *et al.* (2002) and refined by Palmini *et al.* (2004): type I and type II (Taylor-type FCD). For this study, we only considered patients with histopathologically proven type I FCD diagnosed on the basis of cortical disruption. The majority of the patients showed laminar (horizontal) alterations particularly affecting cortical layer II or IV; however, columnar (vertical) abnormalities were also observed in some (Blümcke *et al.*, 2009; Tassi *et al.*, 2009). The presence of numerous heterotopic neurons in the white matter was also considered when associated with cortical alterations. The patients with these histopathological characteristics were considered to have type IA FCD (otherwise called architectural dysplasia); the patients also presenting the hypertrophic pyramidal-like neurons described by Tassi *et al.* (2002) were diagnosed as type IB FCD (cytoarchitectural dysplasia).

Statistical analysis

Age at epilepsy onset, seizure frequency and age at the time of surgery were compared according to histopathological subtype using analysis of variance (ANOVA) and Scheffé's *post hoc* analysis when necessary. The χ^2 test was used to compare gender, FS, MRI findings, temporal

lobe resection and surgical outcome between the patients with isolated FCD and those with other additional lesions. The duration of epilepsy in seizure-free (Engel class I) and other patients was analysed using a t test. A multivariate logistic regression model was used to evaluate the associations between temporal lobe resection, histopathological diagnosis of isolated FCD I and class I outcome. P values of < 0.05 were considered significant. All of the analyses were performed using SPSS software (version 17 for Windows).

Results

The general characteristics of the population subgroups are depicted in *figure 1*. According to Palmini's classification (Palmi *et al.*, 2004) 173 of our 215 patients (80%) were classified as type IA, and 42 (20%) as type IB. However, because there was an insufficient number of type IB patients to perform statistical analysis, and the assessment of this subtype is still debated, we evaluated the cohort as a whole without any further subclassification.

The population included 132 males (61%) and 83 females (39%). Their mean age was eight years (SD 8; range 0-53)

at epilepsy onset and 27 years (SD 13; range 2-60) at the time of surgery. A mean duration of epilepsy was 19 years (SD 11; range 1-59); mean seizure frequency at the time of surgery was 47 per month (SD 120; range 1-1,000). MRI was uninformative in 25 patients (12%) (*table 1*). The epileptogenic zone was revealed by electroclinical and imaging data in the temporal lobe in 133 cases (62%), the frontal region in 30 (14%), multilobar including the temporal region in 38 (18%), and multilobar not including the temporal region in 11 (5%) (*table 2*). Follow-up data was available for all of the patients, 148 (69%) were classified as Engel class I, including 123 (57%) in Engel class Ia + c (*tables 3 and 4*).

Type I FCD was "isolated" in 66 (31%) patients who showed no neuropathological signs of other lesions, and was associated with other lesions in 149 (69%) (*table 1*).

Isolated FCD I

The 66 patients with isolated FCD I included 41 (62%) males and 25 (38%) females. Their mean age at epilepsy onset was eight years (SD 10; range 0-53) and 23 years at the time of surgery (SD 12; range 2-57) with a mean duration of epilepsy of 15 years (SD 9; range 1-42). Mean seizure frequency at the time of surgery was

Table 1. General characteristics.

Histology	No. of patients (%)	Males (%)	Females (%)	Age at epilepsy onset (SD)	Duration of epilepsy (SD)	Age at surgery (SD)	Monthly seizure frequency (SD)	Antecedents (%)	FS (%)	Negative MRI (%)	SEEG (%)
FCD isolated	66 (31)	41 (62)	25 (38)	8 (10)	15 (9)	23 (12)	115 (200)	25 (38)	3 (5)	22 (33)	47 (71)
FCD + MCD	16 (7)	11 (69)	5 (31)	10 (7)	18 (11)	28 (11)	21 (19)	6 (38)	1 (6)	0	12 (75)
FCD + tumour	49 (23)	35 (71)	14 (29)	8 (6)	17 (12)	25 (14)	20 (29)	13 (27)	4 (8)	1 (2)	13 (27)
FCD + HS	76 (35)	40 (53)	36 (47)	8 (8)	25 (10)	34 (11)	10 (7)	32 (42)	41 (54)	2 (3)	11 (15)
FCD + other	8 (4)	5 (62)	3 (38)	6 (3)	12 (7)	18 (10)	45 (38)	7 (88)	1 (13)	0	7 (88)
Total	215	132 (61)	83 (39)	8 (8)	19 (11)	27 (13)	47 (120)	83 (39)	50 (23)	25 (12)	90 (42)

Table 2. Site of surgery.

Histology	Temporal (%)	Frontal (%)	Parietal (%)	Occipital (%)	Multilobar except temporal (%)	Multilobar with temporal (%)	Total multilobar (%)
FCD isolated	15 (23)	23 (35)	1 (2)	1 (2)	6 (9)	20 (30)	26 (39)
FCD + MCD	8 (50)	1 (6)	0	0	1 (6)	6 (38)	7 (44)
FCD + tumour	35 (71)	6 (12)	1 (2)	0	3 (6)	4 (8)	7 (14)
FCD + HS	75 (99)	0	0	0	0	1 (1)	1 (1)
FCD + other	0	0	0	0	1 (12)	7 (88)	8 (100)
Total	133 (62)	30 (14)	2 (1)	1 (1)	11 (5)	38 (18)	49 (23)

115 per month (SD 200; range 1-1,000); only three (4.5%) patients reported febrile seizures. MRI was uninformative in 22 (33%) subjects, and SEEG was considered mandatory in 47 (71%) (table 1).

On the basis of the electroclinical and anatomical data, 23 (35%) patients underwent frontal lobe surgery, 15 (23%) temporal lobe surgery and 26 (39%) patients underwent multilobar resection (table 2). Thirty patients (46%) were classified as class I, of whom 23 (35%) were classified as class Ia + c; 19 patients (29%) did not benefit from surgery (table 3). AED therapy was completely discontinued for nine of the class I patients (14%), reduced for two and was continued for all other patients.

FCD I and other lesions

Of the 149 patients with FCD I associated with other types of histopathologically proven lesions, 76 (35%) presented with HS, 49 (23%) tumours, 16 (7%) other types of MCD, and eight (4%) anoxic-ischaemic or post-inflammatory lesions (table 1).

FCD I and HS

The 76 patients in this group included 40 males (53%) and 36 (47%) females. Their mean age at epilepsy onset was eight years (SD 8; range 0-42) and 34 years at the time of surgery (SD 11; range 7-60) with a mean duration of epilepsy of 25 years (SD 10; range 5-59). Mean seizure frequency at the time of surgery was 10 per month (SD 7;

range 1-35), and 41 (53.9%) patients reported FS; the association between a history of FS and a pathological diagnosis of HS in the entire cohort was significant ($p < 0.01$). Only 15% of the patients underwent invasive SEEG (table 1). Based on MRI, HS was visualised in association with suspected FCD in 40 patients and diagnosed alone in 26, FCD was suspected in eight and results were uninformative in two patients. One patient underwent multilobar resection; only the temporal lobe was involved in the other cases (table 2). The vast majority of the patients [62 (82%)] were classified as class I (66% as class Ia + c). AED therapy was terminated for 18 patients and reduced for 25 patients (table 3).

FCD I and tumours

In this group of 49 patients (35 males and 14 females), *glioneuronal tumours* (GNTs) were the most frequent (82%); the diagnoses included 26 *gangliogliomas* (WHO Grade I) (GGs; 53%), 14 *dysembryoplastic neuroepithelial tumours* (WHO Grade I) (DNTs; 28%), two *xanthoastrocytomas* (WHO Grade II), two *pilocytic astrocytomas* (WHO Grade I), two *gangliocytomas* (WHO Grade I), one *meningioma* (WHO Grade I), one *oligoastrocytoma* (WHO Grade II) and one *plexus papilloma* (WHO Grade I).

The patient mean age was eight years (SD 6; range 0-24) at epilepsy onset and 25 years (SD 14; range 4-58) at the time of surgery with a mean duration of epilepsy of 17 years (SD 12; range 1-44). Mean seizure frequency at

Table 3. Surgery outcome according to Engel classification 1987.

Histology	Class Ia + Ic (%)	Class I (%)	Class II (%)	Class III (%)	Class IV (%)	Therapy stopped (%)
FCD isolated	23 (35)	30 (46)	7 (11)	10 (15)	19 (29)	9 (14)
FCD + MCD	10 (63)	14 (88)	0	1 (6)	1 (6)	1 (6)
FCD + tumour	38 (78)	40 (82)	3 (6)	5 (10)	1 (2)	17 (35)
FCD + HS	50 (66)	62 (82)	7 (9)	3 (4)	4 (5)	18 (24)
FCD + other	2 (25)	2 (25)	2 (25)	2 (25)	2 (25)	1 (12)
Total	123 (57)	148 (69)	19 (9)	21 (10)	27 (13)	46 (21)

Table 4. Outcome relative to site of surgery.

Site of surgery	No. of patients (%)	Patients in class I (%)	Patients in class Ia + Ic (%)
Temporal	133 (62)	110 (83)	91 (68)
Frontal	30 (14)	12 (40)	12 (40)
Parietal	2 (1)	1 (50)	0
Occipital.	1 (1)	0	0
Multilobar except temporal	11 (5)	5 (46)	2 (18)
Multilobar including temporal	38 (18)	20 (53)	18 (47)
Total multilobar	49 (23)	25 (50)	20 (41)
Total	215	148 (69)	123 (57)

the time of surgery was 20 per month (SD 29; range 1-150); only four patients (8.2%) reported FS. Thirteen (27%) patients underwent invasive SEEG recording. Based on MRI, 44 patients were shown to have only a tumour, four patients a tumour associated with cortical-subcortical signal alterations, suggesting FCD, and one patient was normal (table 1).

Surgical resection was restricted to the temporal lobe in 35 (71%) patients and the frontal lobe in six; seven patients (14%) underwent multilobar resections (table 2). Forty (82%) patients were classified as class I (78% as class Ia + c) (table 3). AED therapy was terminated for 17 patients and reduced for 10 patients.

FCD I and other MCDs

The 16 patients in this group included five (31%) females and 11 males (69%). The most frequent malformation associated with FCD I was *periventricular nodular heterotopia* (PNH) which was found in 11 subjects; four patients had *hamartomas* and one a *polymicrogyria*.

The patients' mean age was ten years (SD 7; range 0-19) at epilepsy onset and 28 years (SD 11; range 2-43) at the time of surgery with a mean duration of epilepsy of 18 years (SD 11; range 1-42). Mean seizure frequency at the time of surgery was 21 per month (SD 19; range 2-60), and one patient (6%) reported FS. Invasive SEEG was performed in 12 patients (75%) (table 1). MRI was positive for MCD in 16 patients, although FCD was diagnosed in only one. Eight (50%) patients underwent temporal resection, seven (44%) multilobar resection and one frontal lobe resection (table 2). Fourteen (88%) patients were classified as class I, including 10 (63%) as class Ia + c (table 3). AED therapy was terminated for one patient and reduced for 10 patients.

FCD I and anoxic-ischaemic/inflammatory lesions

The eight patients in this group included three females and five males. Their mean age was six years (SD 3; range 2-13) at epilepsy onset and 18 years (SD 10; range 7-36) at the time of surgery with a mean duration of epilepsy of 12 years (SD 7; range 5-23). Mean seizure frequency at the time of surgery was 45 per month (SD 38; range 4-100); one patient reported FS. Invasive SEEG was performed in seven (88%) patients (table 1). MRI revealed the gliotic-inflammatory lesions in all of the patients, without any evidence of FCD (table 2).

All of the patients underwent multilobar resection (table 2). Two (25%) patients were classified as Class Ia + c (table 3). AED therapy was terminated for one patient and reduced for another.

Statistical analysis

Statistical analysis of the subgroups did not reveal any significant difference in mean age at epilepsy onset

($p = 0.80$). All of the subgroups included more males than females. Scheffé's *post hoc* test showed that the duration of epilepsy at the time of surgery was significantly longer in the case of the patients with FCD I associated with HS than in those in all of the other groups ($p < 0.001$). The same test showed that seizures at the time of surgery were significantly more frequent in the patients with isolated FCD I than in those in the other subgroups ($p < 0.001$), as were negative MRI findings.

With the exception of the patients with FCD I and anoxic-ischaemic/inflammatory lesions, the patients with isolated FCD I had the worst outcome (46% classified as class I and 35% as class Ia + c). Isolated FCD I was significantly associated with extra-temporal resection ($p < 0.01$), whereas resections restricted to the temporal lobe were closely associated with a class I outcome (Pearson's χ^2 test: $p < 0.001$). Furthermore, a multivariate logistic regression analysis designed to evaluate the possible associations between a histopathological diagnosis of isolated FCD I, temporal lobe surgery and class I outcome confirmed that a class I outcome is closely associated with surgery restricted to the temporal lobe ($p < 0.001$; OR: 3.69; 95% CI: 1.80-7.50), and negatively associated with isolated FCD I ($p = 0.021$; OR: 0.42; 95% CI: 0.21-0.88). These data suggest that the worse outcome of patients with isolated FCD I is related to both pathology and localisation.

Discussion

The advances made in imaging technologies, particularly new MRI techniques, have meant that structural brain lesions are being increasingly recognised as possible causes of chronic, drug-resistant focal epilepsies, and this has led to a greater use of surgery as an alternative means of treatment. There has also been a parallel improvement in neuropathological studies of surgical specimens, in which the most frequently encountered lesions include hippocampal sclerosis (HS), glioneuronal tumours (GNTs), vascular malformations, glial scars and MCD. However, many studies of surgical series only take predominant or major histopathological lesions into account, even though a specimen may show more than one histopathological alteration (Wolf *et al.*, 1993; Eriksson *et al.*, 2005). The presence of different histopathological lesions in the same specimen has raised doubts concerning the primacy of structural abnormalities in the genesis of seizures. This is particularly true in the case of FCD (especially type I), which is more prevalent in the temporal lobe where other lesions also occur (Tassi *et al.*, 2002; Bautista *et al.*, 2003; Fauser *et al.*, 2004).

One of the main problems in reviewing the published data concerning MCD (and particularly FCD) in patients undergoing epilepsy surgery is the wide range of assumptions and classification systems used in the different

studies. Studies based on imaging analyses use the classification proposed by Barkovich *et al.* (2005), whereas those based on neuropathological evaluations generally use one of two classification systems: the neuropathological grading system proposed by Mischel *et al.* (1995) (Kloss *et al.*, 2002; Bocti *et al.*, 2003; Chung *et al.*, 2005; Lee *et al.*, 2005; Yun *et al.*, 2006) or the classification proposed by Palmini *et al.* (2004), which also considers electroclinical, imaging and post-surgical outcome data (Widdess-Walsh *et al.*, 2005; Hildebrandt *et al.*, 2005; Bast *et al.*, 2006; Fauser *et al.*, 2006; Krsek *et al.*, 2008; Kim *et al.*, 2009). Furthermore, most of the analyses concentrate on different types of cortical dysplasia and exclude any associated brain lesions, although the association between FCD and HS is often considered in studies of patients undergoing temporal lobe surgery.

In this retrospective evaluation of neuropathologically identified FCD I we have verified the incidence and clinical features, irrespective of localisation, and also considered other lesions observed in the same surgical specimens.

Isolated FCD I

Patients with isolated FCD I accounted for almost one-third (31%) of the entire study population. Although their mean age at epilepsy onset was not significantly different from that of the patients in the other groups, they had more frequent seizures at the time of surgery. Furthermore, MRI was completely uninformative in 33% of the cases, and 71% underwent pre-surgical invasive recordings. Routine MRI examinations are unlikely to detect subtle developmental abnormalities, particularly minor malformations of cortical development (Palmini *et al.*, 2004), but even high-resolution MRI may not detect FCD I, particularly when outside the temporal lobe (Colombo *et al.*, 2003, 2009).

The patients with isolated FCD I had a very poor outcome, with only 46% falling into class I (35% in class Ia + c). The distribution of FCD I was quite wide, although there was a prevalence of frontal (35%) and multilobar areas (39%). The poor surgical outcome may reflect incomplete surgical resection even in those undergoing SEEG because lesion demarcation is frequently poor in MRI-negative cases, and the dysplasia detected by MRI tended to be extensive. It can be argued that, regardless of the underlying pathology, temporal lobe surgery has the best outcome because there is more chance that the lesion(s) will be completely removed. The poor outcome observed in patients with isolated FCD I could therefore be related to prevalence outside the temporal lobe. However, multivariate logistic regression analysis showed that FCD I and a lobar location are independently correlated with surgical outcome. Similar findings have been reported by Krsek *et al.* (2009) showing that, in a paediatric population, the majority of patients presented multilobar lesions with only 21% seizure free after surgery.

FCD I associated with other lesions

One hundred and forty-nine of our 215 patients (69%) had FCD I associated with other lesions, of which almost 4/5 were located in the temporal lobe. Four main groups of associated lesions were identified; the vast majority were tumours (23%), HS (35%), other MCDs (7%) and anoxic-ischaemic/inflammatory lesions which were observed in only 4% of the patients, all of whom showed multilobar involvement.

It is well known that, although rare (Blümcke and Wiestler, 2002; Luyken *et al.*, 2003), some tumours (particularly GGs and DNTs) are highly epileptogenic and mainly found in the temporal lobe of children and young adults with pharmacologically intractable focal epilepsy. The presence of dysplastic cortex near the tumour has often been observed and FCD type I has been reported in the large majority of patients (Prayson *et al.*, 1996; Ferrier *et al.*, 2006). In such cases, it is often difficult to differentiate between neoplastic and dysplastic lesions, even in neuropathological specimens. However, it is still debated as to whether the association of FCD with GNTs should be considered as a distinct entity (different from isolated FCD). In agreement with the current literature, we found that the majority of the alterations were in the temporal lobe (71%), although they were also frequently multilobar (14%) or frontal (12%). Perhaps surprisingly, the post-surgical outcome of these patients was very good (82% in class I and 78% in class Ia + c).

Long-term follow-up studies of large patient series have shown that patients with GNTs had favourable outcome as the large majority became seizure free. Complete resection predicts a better post-surgical outcome (Aronica *et al.*, 2001; Luyken *et al.*, 2003). Although no systematic studies have shown that a failure to achieve post-surgical seizure relief is due to unrecognised and unresected adjacent cortical dysplasia, the very high proportion of our patients with tumours (particularly GNTs), who became seizure free, further suggests that a large resection including the surrounding dysplastic area is the most important factor for a good post-surgical outcome and that cortical disorganisation adjacent to the tumour significantly contributes to epileptogenesis.

The largest subgroup in our population consisted of patients with FCD I and HS (76/215; 35%), in whom surgery was restricted to the temporal lobe (only one patient underwent multilobar resection including the temporal lobe). As in the case of our FCD I patients with tumours, surgical outcome was extremely good (82% in class I).

Fauser *et al.* (2004) reported 38 patients with mild MCD or FCD I in a cohort of 67 FCD patients (57%), of whom 91% had temporal lobe lesions; 60% of the patients were in class I and there were no differences between those with temporal and extratemporal FCD. The same group (Fauser *et al.*, 2006) reported a similar incidence of

FCD I in a more recent retrospective study of 120 patients; however, lobar distribution was not evaluated, although 40% of the patients also had HS. An association between FCD and HS has been frequently described in studies of temporal lobe surgery (Levesque *et al.*, 1991; Raymond *et al.*, 1994; Cendes *et al.*, 1995; Prayson *et al.*, 1996; Li *et al.*, 1999), and the best surgical outcome has been obtained when both are removed (Li *et al.*, 1999; Salanova *et al.*, 2004; Chabardès *et al.*, 2005), which suggests that both contribute to seizure genesis. Tassi *et al.* (2009) have recently reported another lesion associated with HS in 71% of patients surgically treated for temporal lobe epilepsy; although tumours were rare (8%) 83% of these patients had FCD I, thus confirming that this type of dysplasia is the most common alteration associated with HS (Eriksson *et al.*, 2005). Interestingly, the outcome of the patients only affected by HS was very good and similar to that found in the present cohort of patients with HS associated with FCD I.

Dual pathology generally refers to the presence of HS with an additional macroscopic extrahippocampal lesion; the published incidence in patients with refractory temporal lobe epilepsy ranges from 5% to 30%, with the commonest extra-hippocampal lesions being cortical developmental abnormalities (Levesque *et al.*, 1991; Cascino *et al.*, 1993; Raymond *et al.*, 1994; Cendes *et al.*, 1995; Li *et al.*, 1999). This wide range is largely due to differences in patient selection and neuropathological procedures which only consider predominant and macroscopic histopathological features.

Thom *et al.* (2009) have recently found that widespread changes involving neocortical structures can be present in patients with temporal lobe epilepsy and hippocampal sclerosis; in particular, 11% of the patients showed a peculiar disorganisation of the supragranular layers previously diagnosed as FCD I (Thom *et al.*, 2000; Garbelli *et al.*, 2006). The authors introduced the term “temporal lobe sclerosis” to describe these patients and suggested that the

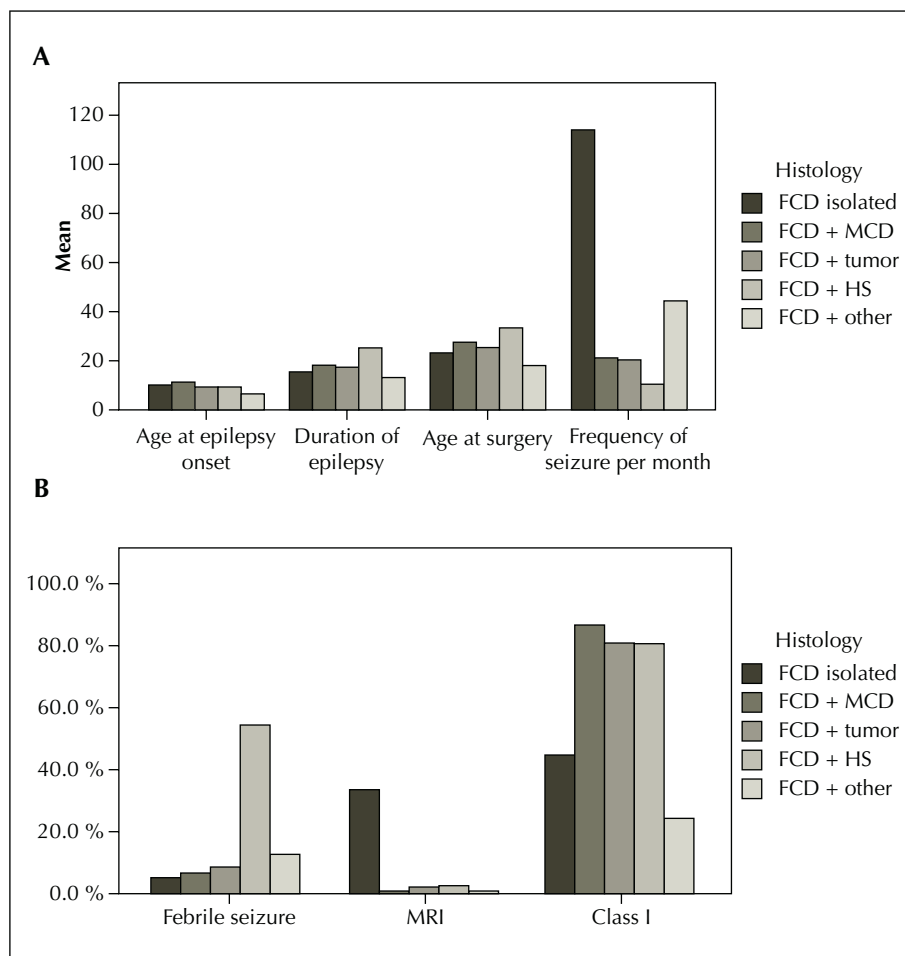


Figure 1. General characteristics of the population subgroups.

A) Mean age at onset of epilepsy, mean age at surgery, mean duration of epilepsy, and mean seizure frequency.

B) Percentage of febrile seizures (FS), MRI-negative cases, and class I surgical outcome.

neocortical disorganisation is probably an acquired, non-developmental process representing part of the spectrum of mesial temporal sclerosis rather than a second or dual pathology. We also detected the same neocortical lesion associated with HS, however, we included these patients in our FCD I cohort because, although we generally agree with the hypothesis of Thom *et al.*, we feel that further studies should confirm that such cases are indeed different from FCD I. Furthermore, the other patients with HS had neuropathological features of FCD I that do not fulfil the criteria for a diagnosis of temporal lobe sclerosis as defined by Thom *et al.* (2009).

The majority of our patients had FCD I associated with tumours or HS, but we also found FCD I associated with other types of MCD (7%) or other acquired lesions due to vascular or inflammatory processes (4%). The most frequent MCD associated with FCD I was nodular heterotopia, as previously reported (Tassi *et al.*, 2005; Meroni *et al.*, 2009). Surgical outcome in this group of patients was also very good (88% in class I, 63% in class Ia + c), once again suggesting that a favourable outcome mainly depends on complete resection of the epileptogenic zone even when the malformation involves more than one lobe. The worst surgical outcome was found in the FCD I patients with anoxic-ischaemic lesions (25% in class I), although it was not possible to perform any statistical evaluation or particular physiopathological speculation due to the small patient number. However, it seems reasonable to assume that a pathological event led to the profound disorganisation of a large portion of the cortical mantle, presumably during pre-natal or early post-natal development. The epileptogenic zone could not be precisely identified in these cases even by means of invasive recordings, and other undetected epileptogenic areas may explain the persistence of seizures after surgery. In the case of these lesions, the compromised cortex (currently defined as FCD I) is more likely to be an acquired alteration, secondary to the development of the principal lesion which some authors have called "progressive cortical dysplasia" (Marin-Padilla *et al.*, 2002).

In conclusion, our findings suggest that isolated FCD I should be evaluated differently from FCD I in the presence of another principal lesion. The epilepsy history and surgical outcome of FCD I patients with tumours, hippocampal sclerosis or other MCDs was similar to those of patients with tumours, HS or MCD without FCD I, whereas patients with isolated FCD I not only had a different epilepsy history but also had a poor surgical outcome. The fact that surgical outcome in patients with FCD I depends on the presence/absence of a second pathology suggests that each component in "combined" cases may contribute to the genesis of seizures. New MRI and electroclinical data, as well as new histopathological and biomolecular markers, are needed to further define this type of dysplasia.

Our data also support the use of a comprehensive clinico-pathological approach to FCD I that takes into account different parameters in order to: *i*) develop a more reliable classification system as a prerequisite for the pre- and post-surgical management of epileptic patients; and *ii*) offer more reliable predictions of post-surgical outcome. □

Financial support.

This study was supported by the Italian Ministry of Health, Fondazione Banca del Monte di Lombardia, Associazione Paolo Zorzi per le Neuroscienze, and EU grant "Functional Genomics and Neurobiology of Epilepsy" (EPICURE, contract No. LSHM-CT-2006-0373315).

Disclosure.

None of the authors has any conflict of interest to disclose.

References

- Aronica E, Leenstra S, van Veelen CW, *et al.* Glioneuronal tumors and medically intractable epilepsy: a clinical study with long-term follow-up of seizure outcome after surgery. *Epilepsy Res* 2001; 43: 179-91.
- Barkovich AJ, Kuzniecky RI. Neuroimaging of focal malformations of cortical development. *J Clin Neurophysiol* 1996; 13: 481-94.
- Barkovich AJ, Kuzniecky RI, Jackson GD, Guerrini R, Dobyns WB. A developmental and genetic classification for malformations of cortical development. *Neurology* 2005; 65: 1873-87.
- Bast T, Ramantani G, Seitz A, Rating D. Focal cortical dysplasia: Prevalence, clinical presentation and epilepsy in children and adults. *Acta Neurol Scand* 2006; 113: 72-81.
- Bautista JF, Foldvary-Schaefer N, Bingaman WE, Lüders HO. Focal cortical dysplasia and intractable epilepsy in adults: clinical, EEG, imaging, and surgical features. *Epilepsy Res* 2003; 55: 131-6.
- Blümcke I, Wiestler OD. Gangliogliomas: an intriguing tumor entity associated with focal epilepsies. *J Neuropathol Exp Neurol* 2002; 61: 575-84.
- Blümcke I, Pauli E, Clusmann H, *et al.* A new clinico-pathological classification system for mesial temporal sclerosis. *Acta Neuropathol* 2007; 113: 235-44.
- Blümcke I, Vinters HV, Armstrong D, Aronica E, Thom M, Spreafico R. Malformations of cortical development and epilepsies: neuropathological findings with emphasis on focal cortical dysplasia. *Epileptic Disord* 2009; 11: 181-93.
- Bocti C, Robitaille Y, Diadori P, *et al.* The pathological basis of temporal lobe epilepsy in childhood. *Neurology* 2003; 60: 191-5.
- Cascino GD, Jack Jr CR, Parisi JE, *et al.* Operative strategy in patients with MRI-identified dual pathology and temporal lobe epilepsy. *Epilepsy Res* 1993; 14: 175-82.
- Cendes F, Cook MJ, Watson C, *et al.* Frequency and characteristics of dual pathology in patients with lesional epilepsy. *Neurology* 1995; 45: 2058-64.

- Chabardès S, Kahane P, Minotti L, et al. The temporopolar cortex plays a pivotal role in temporal lobe seizures. *Brain* 2005; 128: 1818-31.
- Chung CK, Lee SK, Kim KJ. Surgical outcome of epilepsy caused by cortical dysplasia. *Epilepsia* 2005; 46: 25-9.
- Colombo N, Tassi L, Galli C, et al. Focal cortical dysplasias: MR imaging, histopathologic, and clinical correlations in surgically treated patients with epilepsy. *Am J Neuroradiol* 2003; 24: 724-33.
- Colombo N, Salamon N, Raybaud C, Ozkara C, Barkovich AJ. Imaging of malformations of cortical development. *Epileptic Disord* 2009; 11: 194-205.
- Cossu M, Cardinale F, Colombo N, et al. Stereoelectroencephalography in the presurgical evaluation of children with drug-resistant focal epilepsy. *J Neurosurg* 2005; 103: 333-43.
- Engel J. Outcome with respect to epileptic seizures. In: Engel Jr J, ed. *Surgical treatment of the epilepsies*. New York: Raven Press, 1987: 553-71.
- Eriksson SH, Nordborg C, Rydenhag B, Malmgren K. Parenchymal lesions in pharmacoresistant temporal lobe epilepsy: Dual and multiple pathology. *Acta Neurol Scand* 2005; 112: 151-6.
- Fauser S, Schulze-Bonhage A, Honegger J, et al. Focal cortical dysplasias: Surgical outcome in 67 patients in relation to histological subtypes and dual pathology. *Brain* 2004; 127: 2406-18.
- Fauser S, Huppertz HJ, Bast T, et al. Clinical characteristics in focal cortical dysplasia: A retrospective evaluation in a series of 120 patients. *Brain* 2006; 129: 1907-16.
- Ferrier CH, Aronica E, Leijten FS, et al. Electrocorticographic discharge patterns in glioneuronal tumors and focal cortical dysplasia. *Epilepsia* 2006; 47: 1477-86.
- Garbelli R, Meroni A, Magnaghi G, et al. Architectural (Type IA) focal cortical dysplasia and parvalbumin immunostaining in temporal lobe epilepsy. *Epilepsia* 2006; 47: 1074-8.
- Hiltebrandt M, Pieper T, Winkler P, Kolodziejczyk D, Holthausen H, Blümcke I. Neuropathological spectrum of cortical dysplasia in children with severe focal epilepsies. *Acta Neuropathol* 2005; 110: 1-11.
- Kim DW, Lee SK, Chu K, et al. Predictors of surgical outcome and pathologic considerations in focal cortical dysplasia. *Neurology* 2009; 72: 211-6.
- Kloss S, Pieper T, Pannek H, Holthausen H, Tuxhorn I. Epilepsy surgery in children with focal cortical dysplasia (FCD): Results of long-term seizure outcome. *Neuropediatrics* 2002; 33: 21-6.
- Krsek P, Maton B, Korman B, et al. Different features of histopathological subtypes of pediatric focal cortical dysplasia. *Ann Neurol* 2008; 63: 758-69.
- Krsek P, Pieper T, Karlmeier A, et al. Different presurgical characteristics and seizure outcomes in children with focal cortical dysplasia type I or type II. *Epilepsia* 2009; 50: 125-37.
- Kuzniecky R, Garcia JH, Faught E, Morawetz RB. Cortical dysplasia in temporal lobe epilepsy: Magnetic resonance imaging correlations. *Ann Neurol* 1991; 29: 293-8.
- Lee SK, Lee SY, Kim KK, Hong KS, Lee DS, Chung CK. Surgical outcome and prognostic factors of cryptogenic neocortical epilepsy. *Ann Neurol* 2005; 58: 525-32.
- Levesque MF, Nakasato N, Vinters HV, Babb TL. Surgical treatment of limbic epilepsy associated with extrahippocampal lesions: the problem of dual pathology. *J Neurosurg* 1991; 75: 364-70.
- Li LM, Cendes F, Andermann F, et al. Surgical outcome in patients with epilepsy and dual pathology. *Brain* 1999; 122: 799-805.
- Louis DN, Ohgaki H, Wiestler OD, et al. The 2007 WHO classification of tumours of the central nervous system. *Acta Neuropathol* 2007; 114: 97-109.
- Luders H, Schuele SU. Epilepsy surgery in patients with malformations of cortical development. *Curr Opin Neurol* 2006; 19: 169-74.
- Luyken C, Blümcke I, Fimmers R, et al. The spectrum of long-term epilepsy-associated tumors: long-term seizure and tumor outcome and neurosurgical aspects. *Epilepsia* 2003; 44: 822-30.
- Marín-Padilla M, Parisi JE, Armstrong DL, Sargent SK, Kaplan JA. Shaken infant syndrome: developmental neuropathology, progressive cortical dysplasia, and epilepsy. *Acta Neuropathol* 2002; 103: 321-32.
- Meroni A, Galli C, Bramerio M, et al. Nodular heterotopia: a neuropathological study of 24 patients undergoing surgery for drug-resistant epilepsy. *Epilepsia* 2009; 5: 116-24.
- Mischel PS, Nguyen LP, Vinters HV. Cerebral cortical dysplasia associated with pediatric epilepsy. Review of neuropathologic features and proposal for a grading system. *J Neuropathol Exp Neurol* 1995; 54: 137-53.
- Munari C, Soncini M, Brunet P, et al. Electro-clinical semiology of subintractant temporal lobe seizures. *Rev Electroenceph Neurophysiol Clin* 1985; 15: 289-98.
- Palmini A, Gambardella A, Andermann F, et al. Operative strategies for patients with cortical dysplastic lesions and intractable epilepsy. *Epilepsia* 1994; 35: 57-71.
- Palmini A, Najm I, Avanzini G, et al. Terminology and classification of the cortical dysplasias. *Neurology* 2004; 62: 2-8.
- Prayson RA, Reith JD, Najm IM. Mesial temporal sclerosis. A clinicopathologic study of 27 patients, including 5 with coexistent cortical dysplasia. *Arch Pathol Lab Med* 1996; 120: 532-6.
- Raymond AA, Fish DR, Stevens JM, Cook MJ, Sisodiya SM, Shorvon SD. Association of hippocampal sclerosis with cortical dysgenesis in patients with epilepsy. *Neurology* 1994; 44: 1841-5.
- Salanova V, Markand O, Worth R. Temporal lobe epilepsy: Analysis of patients with dual pathology. *Acta Neurol Scand* 2004; 109: 126-31.
- Talairach J, Bancaud J. Lesion, "irritative" zone and epileptogenic focus. *Confin Neurol* 1966; 27: 91-4.
- Tassi L, Colombo N, Garbelli R, et al. Focal cortical dysplasia: Neuropathological subtypes, EEG, neuroimaging and surgical outcome. *Brain* 2002; 125: 1719-32.
- Tassi L, Colombo N, Cossu M, et al. Electroclinical, MRI and neuropathological study of 10 patients with nodular heterotopia, with surgical outcomes. *Brain* 2005; 128: 321-37.
- Tassi L, Meroni A, Deleo F, et al. Temporal lobe epilepsy: neuropathological and clinical correlations in 243 surgically treated patients. *Epileptic Disord* 2009 (epub ahead of print).

Taylor DC, Falconer MA, Bruton CJ, Corsellis JA. Focal dysplasia of the cerebral cortex in epilepsy. *J Neurol Neurosurg Psychiatry* 1971; 34: 369-87.

Thom M, Holton JL, D'Arrigo C, et al. Microdysgenesis with abnormal cortical myelinated fibres in temporal lobe epilepsy: a histopathological study with calbindin D-28-K immunohistochemistry. *Neuropathol Appl Neurobiol* 2000; 26: 251-7.

Thom M, Eriksson S, Martinian L, et al. Temporal lobe sclerosis associated with hippocampal sclerosis in temporal lobe epilepsy: Neuropathological features. *J Neuropathol Exp Neurol* 2009; 68: 928-38.

Widdess-Walsh P, Kellinghaus C, Jeha L, et al. Electro-clinical and imaging characteristics of focal cortical dysplasia: Correlation with pathological subtypes. *Epilepsy Res* 2005; 67: 25-33.

Wolf HK, Campos MG, Zentner J, et al. Surgical pathology of temporal lobe epilepsy. Experience with 216 cases. *J Neuropathol Exp Neurol* 1993; 52: 499-506.

Yun CH, Lee SK, Lee SY, Kim KK, Jeong SW, Chung CK. Prognostic factors in neocortical epilepsy surgery: Multivariate analysis. *Epilepsia* 2006; 47: 574-9.