

S. Morteza SEYED JAFARI^{1,2,3}
 Fatemeh JABBARY LAK⁴
 Amiq GAZDHAR^{2,5}
 Maziar SHAFIGHI²
 Luca BORRADORI¹
 Robert E. HUNGER^{1,2}

¹ Department of Dermatology, Inselspital, Bern University Hospital, Bern, Switzerland

² Department for BioMedical Research, University of Bern, Switzerland

³ Graduate School for Cellular and Biomedical Sciences University of Bern, Switzerland

⁴ Münsingen Hospital, Münsingen, Switzerland

⁵ Department of Pulmonary Medicine, Bern University Hospital, Bern, Switzerland

Reprints: S. M. Seyed Jafari
 <Seyedjafarism@yahoo.com>

Application of electrochemotherapy in the management of primary and metastatic cutaneous malignant tumours: a systematic review and meta-analysis

Electrochemotherapy is becoming a promising technique for the management of malignancies of skin and non-skin origin. The current review aims to clarify current knowledge on administration of electrochemotherapy for the treatment of various skin tumours. A systematic literature search was performed, up to the end of 2016, on studies in which the application of electrochemotherapy for management of primary and metastatic cutaneous malignant tumours was assessed. Having selected appropriate studies, pooled estimates of mean objective (complete) responses, with 95% confidence intervals (CIs), were calculated to assess treatment efficacy. Finally, the main emerging themes from the papers were discussed in more detail. From 465 records identified through database searching, a total of 128 studies were screened, of which 70 were included for review. After a pooled analysis, the estimate for mean objective response following electrochemotherapy was 84.02% (95% CI: 80.08-87.61). Furthermore, the pooled estimate of objective treatment response of evaluated studies was 83.91% (95% CI: 79.15-88.17%) for bleomycin and 80.82% (95% CI: 66.00-92.36%) for cisplatin. Electrochemotherapy is a feasible, inexpensive, fast and easy technique to perform local treatment, regardless of tumour type, with a low level of adverse effects and patient discomfort. This method can be applied alone for patients with primary cutaneous lesions, or local or locoregional metastases, or as an additional treatment modality in patients with distant metastases.

Key words: clinical trials, cutaneous malignant tumour, electrochemotherapy, metastasis

Article accepted on 07/09/2017

Melanoma and non-melanoma skin cancer are now the most common types of cancer in Caucasian populations [1]. Surgery or radiotherapy is the elective treatment for most of the primary skin cancers, which provide high rates of local control and survival [2, 3]. However, despite significant advances in treatment guidelines, recurrence or metastases in the skin are often difficult to manage. As a result, the patients receive multimodal treatment including surgery, radiotherapy, and systemic chemotherapy. The poor response to these treatments could be due to the relative impermeability of the cell membrane to the therapeutic agents [2, 4, 5].

In the 1980s, it was discovered that the delivery of intense electric pulses can transiently and reversibly result in permeabilization of the cell membrane to a large variety of molecules, which are otherwise unable to enter into the cell [2, 6-10]. Therefore, application of a combination of short intense electric pulses and chemotherapy, termed "electrochemotherapy", has been proposed as a new treatment modality for cutaneous involvement of different malignancies [11-16], in which a local increase in plasma membrane permeability, *i.e.* exposure of the tumour nodule to elec-

tric pulses (electroporation), results in increased uptake of chemotherapeutics into the tumour cells [17-19]. Hence, by using this method, the intracellular concentration, and thereby the toxicity, of bleomycin and cisplatin (as the effective drugs for the treatment of different cutaneous tumours [20-22]) can be increased up to 10,000 times and 80 times, respectively [14, 23], which significantly potentiates their antitumour effectiveness, with lower doses required [15, 18, 24-26].

In order to shed more light on the clinical applications of electrochemotherapy in dermatology, the current review aimed to clarify current knowledge on the administration of this method in the management of primary and metastatic skin malignancies.

Material and methods

This review was conducted based on the PRISMA group statement [27]. A systematic literature search was performed in the PubMed Library and Cochrane electronic

databases, up to the end of 2016, taking all electroporation synonyms and skin tumours into account, using the following search terms or respective combinations: electroporation, electrochemotherapy, electropermeabilization, skin cancer, skin metastasis, melanoma, Kaposi's sarcoma, Merkel-cell carcinoma, and basal cell carcinoma.

In some cases, the same article could be found in both databases, however, the evaluation for each database was performed separately and reported in the table of results of the search.

Additionally, no geographical restrictions were imposed in this study. Both qualitative and quantitative studies were chosen. From these manuscripts, those that fulfilled the following inclusion and exclusion criteria were considered in the current review:

- Studies focused on the clinical application of electroporation in the management of primary and metastatic skin tumours.
- Studies restricted to English language and limited to humans. As a result, *in vitro* treatments and veterinary studies were excluded from full-text assessment.
- Scientific letters, review articles, and meta-analysis were not considered for this study.

After evaluation of the selected studies, these were then summarised in a table and subclassified under publication year, authors, patient number, tumour number, type/dose/route of chemotherapy, settings of electroporation, outcome, and side effects. The studies were then ordered chronologically to reveal any changes and particularly advances made over time (*table 1*). Finally, the main emerging themes from the papers were discussed in more detail.

Statistical analysis

Pooled analysis was conducted using MetaXL Version 5.3 (EpiGear International Pty Ltd, Australia). The presence of heterogeneity among these studies was evaluated with Cochran's Q test, and inconsistency was assessed with I² test that describes the percentage of the variability in effect estimates that is due to heterogeneity, where $p < 0.05$ indicates significant heterogeneity. Pooled estimates of mean objective (complete) responses, with 95% confidence intervals (CIs), were calculated to assess the overall efficacy. In order to calculate the pooled estimate of mean objective (complete) response for each tumour or specific administration route, only the relevant papers were considered for the analysis. The random-effects model was defined as the preferred method due to diversity and heterogeneity of the studies, patients, and treated tumours [28].

Results

A total of 465 articles were identified. All abstracts were examined and screened, excluding 308 articles regarding *in vitro* or veterinary treatments, or non-English papers. Full-text assessment of the remaining 128 articles resulted in 70 eligible articles (*figure 1*).

Considering objective responses, significant heterogeneity was detected among all studies ($I^2 = 68%$;

p -heterogeneity < 0.001). After a pooled analysis, the estimate for mean objective response was 84.02% (95% CI: 80.08-87.61%), which suggests efficacy of electrochemotherapy in the management of primary and metastatic cutaneous malignant tumours (*figure 2*).

Choice of chemotherapeutic agent for electroporation

Bleomycin and cisplatin are the most commonly administered drugs for the treatment of skin tumours with electrochemotherapy [29], which can be given systemically or locally [30].

Bleomycin is a water-soluble antibiotic with toxicity to mammalian cells due to the capability to induce DNA breaks [7, 13, 31]. Electropermeabilization of cells allows bleomycin to enter the cytosol and exert its cytotoxic potential. Therefore, bleomycin is an ideal candidate for combining with electric pulses because it is non-permeant, but highly cytotoxic once inside the cell [7, 21, 31-35]. It can therefore be used at lower doses than those needed for classic chemotherapies [7, 13, 31]. In previous studies, electrochemotherapy with bleomycin was found to be effective for primary and metastatic malignant melanoma [2, 5, 17, 20, 30, 36-49], primary and metastatic basal cell carcinoma [2, 21, 38, 44, 50-52], primary and metastatic squamous cell carcinoma [44, 47, 49, 53], Kaposi's sarcoma [41, 43, 49, 54-59], Merkel cell carcinoma [41, 60, 61], cutaneous primary and metastatic lesions of breast cancer [49, 62-68], soft tissue sarcoma [49, 69], cutaneous B-cell lymphoma [70], superficial angiosarcoma [71], metastatic cutaneous nodules and transitional cell carcinoma (bladder cancer) [72], locally advanced and metastatic angiosarcoma [71], and as a palliative therapy for tumour complications [12, 36, 73-75].

Cisplatin is a nuclear DNA-damaging agent with the capability to form DNA crosslinks. Cisplatin transport through the plasma membrane is also limited [76]. Nevertheless, exposure of cutaneous tumours to electric pulses after intravenous or intratumoural non-toxic cisplatin doses potentiates its antitumor effectiveness several-fold [24, 77, 78]. Electrochemotherapy with cisplatin was first introduced by Sersa *et al.* in 1998 [78]. Subsequently, further studies showed its treatment efficacy for malignant melanoma [17, 78, 79], squamous cell carcinoma [78], basal cell carcinoma [78], cutaneous lesions of breast cancer [80], and as a palliative therapy [79]. Efficacy of electrochemotherapy with cisplatin was proven to be dependent on the cisplatin dose, the amplitude of the electric pulses, and the sequence and interval of cisplatin administration [24, 78].

Route of drug administration

According to the findings of the previous trials, either bleomycin or cisplatin can be used as treatment due to their good antitumour effectiveness. Clinical data have proven antitumour effectiveness of bleomycin and cisplatin when given intratumourally, however, intravenous injection is only recommended for bleomycin [24, 37, 77, 78, 81]. The estimates for objective response following electrochemotherapy with intravenous bleomycin, intra-lesional bleomycin, and intra-lesional cisplatin were

Table 1. Summary of the selected studies for the review.

| Study | No. of patients (lesions) | Tumour characteristics | Anaesthesia | Treatment (drug/ dose/ route) | Interval between drug administration and electric pulse | Pulse characteristics (field strength, no. of pulses, duration, frequency) | OR | CR | Comments on outcome | Side effects and drawbacks |
|------------------------------------|---------------------------|--|-------------|---|---|--|----|----|--|--|
| Behradek <i>et al.</i> (1993) [98] | 8 (40) | Permeation nodules of head and neck squamous cell carcinomas | S | Intravenous bleomycin (10 mg/m ²) | 3.5 min | 1300 V/cm, 8 or 4 pulses, 100 μs, 1 Hz | 72 | 57 | - | No major local or general side effects. Local instantaneous contraction of muscles was observed. |
| Rudolf <i>et al.</i> (1995) [30] | 2 (24) | Malignant melanoma nodule | LA | Intravenous bleomycin (10 mg/m ²) | 8 min | 1300 V/cm, 2×4 pulses, 100 μs, 1 Hz | 92 | 92 | - | No major local or general side effects. Muscle contractions were observed after each pulse. Several hours after treatment, erythema and slight oedema was detected at the treated area. These symptoms disappeared within one day. |
| Domenge <i>et al.</i> (1996) [85] | 7 (53) | Multiple and/or large permeation nodules of head and neck squamous cell carcinoma or of salivary, lung cancer, breast adenocarcinoma | S or GA | Intravenous bleomycin (10 or 15 mg/m ²) | 8-28 min | 1000 or 1300 V/cm, 8 or 4 pulses, 100 μs, 1 Hz | 22 | 11 | In almost all the cases, progression of the treated nodules was at least stopped, compared with that of the neighbouring nodules not subjected to electroporation but exposed to the same dose of bleomycin. Clear antitumour effects were obtained, especially in the small nodules. In the largest nodules, extended tumour necrosis was seen. | No local or general side effects, except for one patient, who developed transient heart frequency acceleration and increase in maximal blood during the treatment, which returned to pre-treatment values within a few seconds. |

Table 1. (Continued)

| Study | No. of patients (lesions) | Tumour characteristics | Anaesthesia | Treatment (drug/ dose/ route) | Interval between drug administration and electric pulse | Pulse characteristics (field strength, no. of pulses, duration, frequency) | OR | CR | Comments on outcome | Side effects and drawbacks |
|----------------------------------|---------------------------|---|-------------|---|---|--|----|----|--|--|
| Glass <i>et al.</i> (1996) [38] | 2 (multiple) | Nevoid basal cell carcinoma syndrome | LA | Intravenous bleomycin (10 mg/m ²) | 12-15 min | 1300 V/cm, 8 pulses, 99 μ s, 1 Hz | NM | NM | Partial responses were observed in tumours from both of the patients treated with electrochemotherapy; three partial responses were observed in one patient, and one partial response was observed in the other patient. Complete responses were seen for two lesions. | Only minimal local or systemic side effects were noted in response to the therapy. |
| Glass <i>et al.</i> (1996) [97] | 5 (23) | Cutaneous metastatic melanoma | LA and E | Intratumoural bleomycin, at a dose of 0.5-1.0 mg (based on tumour size) | 10 min | 1300 V/cm, 8 pulses, 99 μ s, 1 Hz | 96 | 78 | - | The treatment was well tolerated, with the exception of the sensation of muscle contraction during the therapy. Also, a slight burning of the skin with the calliper electrodes. |
| Heller <i>et al.</i> (1996) [39] | 6 (18) | Metastatic melanoma, basal cell carcinoma, nevus syndrome, or metastatic breast adenocarcinoma with cutaneous nodules | LA | Intravenous bleomycin (10 mg/m ²) | 5-15 min | 1300 V/cm, 8 pulses, 99 μ s, 1 Hz | 78 | 33 | - | All patients tolerated the treatment well with no residual effects from the electric pulses. |

Table 1. (Continued)

| Study | No. of patients (lesions) | Tumour characteristics | Anaesthesia | Treatment (drug/ dose/ route) | Interval between drug administration and electric pulse | Pulse characteristics (field strength, no. of pulses, duration, frequency) | OR | CR | Comments on outcome | Side effects and drawbacks |
|----------------------------------|---------------------------|---|-------------|--|---|--|-----|------|--|--|
| Glass <i>et al.</i> (1997) [93] | 20 (54) | Primary basal cell carcinoma | LA and E | Intralesional bleomycin, 0.5-1.0 mg (based on tumour size) | 10 min | 1300 V/cm, 8 pulses, 99 μ s, 1 Hz | 100 | 98 | No recurrences were recorded with a mean 18 months of observation. Two weeks after therapy, the histopathological appearance consisted of cutaneous ulceration and scale-crust formation, but no tumour. | At 1 to 2 days after electrochemotherapy, painless erythema and oedema occurred at the treatment site. Ulceration appeared within 2 to 3 days, with a thick, scale-crust appearing afterwards. Complete wound healing by second intention required 4 to 6 weeks. |
| Kubota <i>et al.</i> (1998) [72] | 1 (17) | Metastatic cutaneous nodules, transitional cell carcinoma (bladder cancer) | GA | Intralesional bleomycin (0.5 mg/5 mm of nodule diameter) | 10 min | 1000 V/cm, 8 pulses, 100 μ s, 1 Hz | 100 | 82.3 | All lesions gradually dried, forming yellowish crusts, and 14 completely disappeared. The other 3 lesions partially regressed and showed thin, lustrous skin. | Local exudate and oedema were present for 5 days, and exudate from the lesions in the head remained for 20 days. |
| Heller <i>et al.</i> (1998) [42] | 34 (143) | Basal cell carcinoma, advanced melanoma (metastatic to local or distant soft tissue and skin sites), squamous cell carcinoma, or Kaposi's sarcoma | LA and E | Intralesional bleomycin (0.5-4 mg/cm ³) | 10 min | 1300 V/cm, 8 or 6 pulses, 99 μ s, 1 Hz | 99 | 91 | - | Muscle contraction was seen during administration of each electric pulse, but promptly disappeared after the pulse. |

Table 1. (Continued)

| Study | No. of patients (lesions) | Tumour characteristics | Anaesthesia | Treatment (drug/dose/route) | Interval between drug administration and electric pulse | Pulse characteristics (field strength, no. of pulses, duration, frequency) | OR | CR | Comments on outcome | Side effects and drawbacks |
|---------------------------------|---------------------------|---|-------------|---|--|--|------|------|---|---|
| Sersa <i>et al.</i> (1998) [78] | 4 (30) | Melanoma, squamous cell carcinoma, basal cell carcinoma | NM | Intratumoural cisplatin (0.25-2 mg/cm ³) | 1-2 min | 1300 V/cm, 100 μ s, 1 Hz | 100 | 100 | - | Electrochemotherapy was well tolerated with good cosmetic outcome and only minimal scarring, and a slight depigmentation of the skin. |
| Mir <i>et al.</i> (1998) [21] | 50 (291) | Cutaneous or subcutaneous tumours of basal cell carcinoma, malignant melanoma, adenocarcinoma and head and neck squamous cell carcinoma | LA or GA | Intravenous bleomycin (10 mg/m ² or 15 mg/m ²), or intratumoural bleomycin (0.25-1.0 mg/cm ³ of tissue) | 3 min after intravenous and 10 min after intratumoural injection | 1300 V/cm, 8 or 6 pulses, 100 μ s, 1 Hz | 85.3 | 56.4 | - | Local instantaneous contraction of muscles was observed, which disappeared immediately after the end of each electric pulse. |
| Gehl <i>et al.</i> (2000) [12] | 1 (9) | Ulcerated cutaneous metastases of malignant melanoma (5-20 mm) | LA and E | 0.5 mg of bleomycin | 10 min | 1200 V/cm, 8 pulses, 99 μ s | 100 | 100 | Bleeding immediately stopped on administration of the electric pulses and did not recur. The treated metastases developed crusts and the lesions healed over weeks. | Patient discomfort was brief and modest. |
| Rols <i>et al.</i> (2000) [13] | 4 (55) | Cutaneous metastases of malignant melanoma (2-35 mm) | S or GA | Intravenous bleomycin (10 mg/m ²) | 5-45 min | 1000 and 1300 V/cm, 8 pulses, 100 μ s | 90 | 9 | - | Contractions were seen during application of each pulse. In one patient, slight hyperthermia was noticed, which disappeared after 2 days. The acute reactions were maximal on the fifth day and had completely recovered after 2-3 weeks. |

Table 1. (Continued)

| Study | No. of patients (lesions) | Tumour characteristics | Anaesthesia | Treatment (drug/dose/route) | Interval between drug administration and electric pulse | Pulse characteristics (field strength, no. of pulses, duration, frequency) | OR | CR | Comments on outcome | Side effects and drawbacks |
|---|---------------------------|--|-------------|--|---|--|----|----|---|--|
| Sersa <i>et al.</i> (2000) [17] | 10 (82) | Recurrent melanoma metastases refractory to chemotherapy, Visceral metastases | NM | Intratumoural cisplatin (0.25-2 mg based on tumour size) | 1-2 min | 1300 V/cm, 100 μ s, 1 Hz | 78 | 68 | At 124 weeks of follow-up, a 77% control rate of the tumour nodules treated by electrochemotherapy was observed, compared to 19% for those that were treated with cisplatin only. | Local instantaneous contraction of muscles was observed, which dissipated immediately afterwards. Erythema and oedema were observed in patients treated with electrochemotherapy which remained for 2 weeks. |
| Sersa <i>et al.</i> (2000) [20] | 9 (27) | Cutaneous metastases of malignant melanoma | NM | Intravenous Vinblastine (4 mg/m ²), oral lomustine (80 mg/m ²) on Day 1, intravenous cisplatin (20 mg/m ²) on Days 2 \pm 5, and interferon- α 2b 3 mg/m ² on Days 4-7. | At least 3 h after the beginning of the infusion | 1300 V/cm, 8 pulses, 99 μ s, 1 Hz | 48 | 11 | Four weeks after treatment, objective response was obtained for 48% of tumour nodules, compared with 22% of tumour nodules treated with Vinblastin-based chemioimmunotherapy alone. | Local instantaneous contraction of muscles was observed, which dissipated immediately afterwards. Slight erythema surrounding the nodule and sometimes formation of a superficial scab were detected. |
| Rodriguez-Cuevas <i>et al.</i> (2001) [2] | 15 (38) | Basal cell carcinomas, in-transit metastasis of melanoma, squamous cell carcinomas of the upper aerodigestive tract (metastatic to the skin), and skin metastases from breast cancer | LA | Intralesional bleomycin (0.5-4 mg/cm ³) | 10 min | 1300 V/cm, 8 pulses, 100 μ s, 1 Hz | 98 | 49 | - | No complications were documented related to the treatment, and tolerance was adequate. |

Table 1. (Continued)

| Study | No. of patients (lesions) | Tumour characteristics | Anaesthesia | Treatment (drug/dose/route) | Interval between drug administration and electric pulse | Pulse characteristics (field strength, no. of pulses, duration, frequency) | OR | CR | Comments on outcome | Side effects and drawbacks |
|------------------------------------|---------------------------|--|-------------|--|---|---|-----|------|--|--|
| Sersa <i>et al.</i> (2003) [92] | 14 (211) | Progressive disease of malignant melanoma | NM | Intratumoural cisplatin (1 mg/100cm ³ of tissue) | NM | 1300 V/cm, 8 pulses, 100 μs, 1 Hz | 82 | 70.1 | - | Pain was a limiting factor for most of the patients. |
| Rebersek <i>et al.</i> (2004) [80] | 6 (26) | Cutaneous tumour lesions of breast cancer | LA | Intratumoural cisplatin (1 mg/100 mm ³ of tissue) | 1-2 min | 1300 V/cm, 2×4 pulses, 100 μs, 1 Hz | 100 | 33 | For lesions treated with intratumoural application of cisplatin alone, objective response was obtained for 83% of lesions. | Only minimal local side effects were observed. |
| Snoj <i>et al.</i> (2005) [79] | 1 (1) | Anorectal malignant melanoma | GA | Intralesional cisplatin (6 mg and 4 mg) | 2-5 min | 730 V, 5× (and 3 the second time) 192 pulses, 100 μs, 5000 Hz | 100 | 100 | Fourteen months after the beginning of treatment, the patient was without signs of local recurrence. | NM |
| Kubota <i>et al.</i> (2005) [74] | 1 (multiple) | Perineal malignant melanoma | GA | Intralesional bleomycin (0.1 mg/cm ³ of tissue) | 10 min | 1000 V/cm, 8 pulses, 100 μs, 1 Hz | 100 | 100 | Five months after the second treatment, no recurrence of pigmentation or subcutaneous nodules was detected. | Electrochemotherapy of mucosal malignant melanoma was well tolerated. |
| Byrne <i>et al.</i> (2005) [94] | 19 (36) | Visible and/or palpable cutaneous and/or subcutaneous melanoma deposits (Stage III and Stage IV) | LA and E | Intralesional bleomycin (1 mg/cm ³ of tissue) | 2-20 min | 560-1500 V, 100 μs | 78 | 72 | - | Electroporation caused unpleasant electric shock sensations in the limb due to spasm of underlying muscles or to pain relayed by local nerves. |
| Garbay <i>et al.</i> (2006) [56] | 1 (multiple) | Unresectable Kaposi's sarcoma nodules | GA | Intravenous bleomycin (27 mg) | 8-30 min | 730 V, 31×8 pulses, 100 μs, 5000 Hz (for type III electrode), 960V, 15×8 pulses, 100 μs, 5000 Hz (for type I electrode) | 100 | 100 | Repetitive electrochemotherapy sessions combined with the use of imiquimod application led to an excellent local control with no secondary effect. | NM |

Table 1. (Continued)

| Study | No. of patients (lesions) | Tumour characteristics | Anaesthesia | Treatment (drug/ dose/ route) | Interval between drug administration and electric pulse | Pulse characteristics (field strength, no. of pulses, duration, frequency) | OR | CR | Comments on outcome | Side effects and drawbacks |
|----------------------------------|---------------------------|---|-------------|---|---|--|-----|-----|---|---|
| Gaudy <i>et al.</i> (2006) [95] | 12 (54) | Cutaneous metastases of malignant melanoma (Stage III and Stage IV) | LA and E | Intralesional bleomycin (1 mg/mm ³ of tumour lesion) | 10 min | >600 V/cm, 6 pulses 100 µs, 4 Hz | 46 | 36 | - | Patients reported local pain and muscle spasm with myoclonia after electroporation. |
| Gehl <i>et al.</i> (2006) [36] | 1 (8) | Disseminated malignant melanoma presented with several bleeding, ulcerated metastases on the head and scalp | GA | Intravenous bleomycin (15 mg/m ²) | 8 min | According to the ESOPE protocol. | 100 | 87 | Bleeding metastases ceased to bleed and formed a crust within a few hours after treatment. | NM |
| Whelan <i>et al.</i> (2006) [64] | 1 (1) | Recurrent inflammatory breast cancer, unresponsive to systemic chemotherapy | S | Intravenous (20 mg) and intratumoural bleomycin (5 mg) | 8 min | 1400 V/cm, a consecutive series of pulses, 100 µs | 100 | 100 | Following the third treatment, a dramatic reduction in the tumour mass was accompanied by relief of pain and bleeding, culminating in a complete elimination of tumour on the chest wall. | NM |
| Tjink <i>et al.</i> (2006) [96] | 7 (17) | Squamous cell carcinoma, sarcoma, melanoma, Merkel cell carcinoma | LA or GA | Intratumoural bleomycin (1 mg mg/cm ³ of tissue) | 8-10 min | NM | 100 | 82 | Within a few days after treatment, crusting occurred at the tumour site, with necrosis of the tumour underneath; the crust then disappeared after 10-14 weeks and the tumour was replaced by scar tissue. | Muscle contraction was observed in the treated area. |

Table 1. (Continued)

| Study | No. of patients (lesions) | Tumour characteristics | Anaesthesia | Treatment (drug/dose/route) | Interval between drug administration and electric pulse | Pulse characteristics (field strength, no. of pulses, duration, frequency) | OR | CR | Comments on outcome | Side effects and drawbacks |
|------------------------------------|---------------------------|---|----------------|--|---|---|------|------|---------------------|--|
| Marty <i>et al.</i> (2006) [15] | 41 (171) | Cutaneous and subcutaneous metastases of malignant melanoma tumour nodules, carcinoma and sarcoma | LA or GA | Intravenous bleomycin (15 mg/m ²) or intratumoural bleomycin (0.25-2 mg/cm ² of tissue) or intratumoural cisplatin (0.5-2 mg/cm ² of tissue) | 8-28 min after intravenous, or after intratumoural injection of either bleomycin or cisplatin | 1300 V/cm, 8 pulses, 100µs, 1 or 5000 Hz (for type I electrode), 1000 V/cm, 8 pulses, 100 µs, 1 or 5000 Hz (for type II electrode), 1000 V/cm, 96 pulses, 100µs, 5000 Hz (for type III electrode) | 84.8 | 73.7 | - | Side effects were minor and acceptable. |
| Larkin <i>et al.</i> (2007) [62] | 30 (111) | Squamous cell carcinoma, primary and skin metastatic breast carcinoma, and others | S and LA or GA | Intravenous bleomycin (15 mg/m ²) or intratumoural bleomycin | 8 min after intravenous and immediately after intratumoural injection | 1400 V/cm, 8 pulses, 100 µs, 1 to 5000 Hz | 82 | 60 | - | Only mild pain related to the treatment was reported, which dissipated within 48 hours. |
| Snoj <i>et al.</i> (2007) [89] | 1 (224) | Unresectable cutaneous metastases of malignant melanoma | GA | Intravenous bleomycin (15 mg/m ²) | 8-28 min | 1300V/cm, 8 pulses, 100 µs, 1 or 5000 Hz | 100 | 100 | - | Only muscle contraction was reported. |
| Quaglino <i>et al.</i> (2008) [11] | 14 (233) | Cutaneous metastases of malignant melanoma (Stage III relapsed/refractory patients) | GA | Intravenous bleomycin (15 mg/m ²) | 8-28 min | According to the ESOPE protocol | 93 | 58 | - | Local erythema and slight oedema disappeared within a few days. Moreover, marks from the electrodes and superficial epidermal erosions were noted, followed by scars healing within a month. |

Table 1. (Continued)

| Study | No. of patients (lesions) | Tumour characteristics | Anaesthesia | Treatment (drug/ dose/ route) | Interval between drug administration and electric pulse | Pulse characteristics (field strength, no. of pulses, duration, frequency) | OR | CR | Comments on outcome | Side effects and drawbacks |
|------------------------------------|---------------------------|---|-------------|---|---|---|-----|-----|---|--|
| Fantini <i>et al.</i> (2008) [50] | 1 (multiple) | Metastatic basal cell carcinoma with squamous differentiation | LA | Intratumoural bleomycin (0.25-1 mg/cm ³ of tissue) | 2 min | 730 V/module, 8 pulses, 100 µs, 5000 Hz | 100 | 100 | Clinical healing within 1 to 3 months, which was histologically confirmed by skin biopsy/ | Mild pain due to muscle contraction was reported during the pulse delivery. |
| Curatolo <i>et al.</i> (2008) [57] | 1 (multiple) | Penile Kaposi's sarcoma | LA | Intravenous bleomycin (15 mg/m ²) | 8 min | 680 V/module, runs of 8 pulses, 100 µs, 5000 Hz | 100 | 100 | At 2 months, excellent results with normal scars at sites of treated nodules. | A painless erythema and oedema were observed on the site of treatment and recovered after 1 week. |
| Curatolo <i>et al.</i> (2009) [60] | 1 (multiple) | Extensive Merkel cell carcinoma | S and LA | Intravenous bleomycin (15 mg/m ²) | 8 min | 680 V/module, a series of 8 pulses, 100 µs, 5000 Hz | 100 | 100 | The superficial crust on the treated nodules separated within approximately 5 weeks. Two months after treatment, the lesion further diminished in diameter and flattened. | Erythema and slight oedema were observed at the treatment site and persisted for 2 weeks. The patient had no residual pain or discomfort during and after treatment. |
| Snoj <i>et al.</i> (2009) [73] | 1 (1) | Bleeding melanoma recurrence | NM | Intravenous bleomycin (15 mg/m ²) | NM | Fifteen runs of pulses (by hexagonal needle electrodes in the centre of the lesion), and an additional 10 runs of pulses (via plate on the rim of the tumour) | 100 | 0 | Immediately after therapy, the bleeding stopped and did not recur. The lesion developed a crust and decreased in size within a matter of weeks. After 21 weeks, the lesion was undergoing partial response. | NM |

Table 1. (Continued)

| Study | No. of patients (lesions) | Tumour characteristics | Anaesthesia | Treatment (drug/ dose/ route) | Interval between drug administration and electric pulse | Pulse characteristics (field strength, no. of pulses, duration, frequency) | OR | CR | Comments on outcome | Side effects and drawbacks |
|-------------------------------------|---------------------------|--|-------------|---|---|--|------|------|--|---|
| Campana <i>et al.</i> (2009) [102] | 52 (608) | Melanoma metastases, chest wall recurrence of breast carcinoma, recurrent soft tissue sarcomas, locally advanced recurrent head and neck carcinoma, and locoregional relapsing skin epidermoid carcinoma | S and LA | Intravenous bleomycin (10 mg/m ²), or intratumoural bleomycin (0.25-1 mg/cm ³ of tissue) | 20 min | 8 pulses | 96 | 80 | After a mean follow-up of 9 months, only 2 patients experienced relapse in the treatment field. | Electric currents sometimes caused an unpleasant sensation. |
| Gualdi <i>et al.</i> (2010) [54] | 1 (multiple) | HHV-8-positive skin Kaposi's sarcoma | LA | Intratoural bleomycin (6.5 mg) | 2 min | 730 V/cm, 8 pulses, 100 μ s, 5000 Hz | 100 | 100 | A rapid clinical response was observed, with ulcerative necrosis of the lesions, resulting in clinical healing within about 1 month. Pain rapidly decreased after treatment. Skin biopsies 2 months after treatment showed dermal fibrosis in the absence of abnormal Vascular proliferation and tumour cells. | NM |
| Landström <i>et al.</i> (2010) [99] | 6 (6) | Basal cell carcinoma, squamous cell carcinoma | GA | Intratoural bleomycin (1 mg/mg of tissue) | 10 min | 1100 V/cm, 100 μ s | 66.7 | 66.7 | - | The pain after treatment was moderate and managed with medications. |

Table 1. (Continued)

| Study | No. of patients (lesions) | Tumour characteristics | Anaesthesia | Treatment (drug/ dose/ route) | Interval between drug administration and electric pulse | Pulse characteristics (field strength, no. of pulses, duration, frequency) | OR | CR | Comments on outcome | Side effects and drawbacks |
|--------------------------------------|---------------------------|--|----------------|---|---|--|-----|-----|--|---|
| Kaehler <i>et al.</i> (2010) [23] | 1 (6) | Nodular malignant melanoma skin metastases | GA | Intratumoural bleomycin (range: 1.5-3 mg) | 10 min | 1130 V/cm, runs of 6 pulses, 100 μ s, 4 Hz | 100 | 100 | Two days after treatment, the bleeding of the tumour stopped, and the odour was reduced. Representative punch biopsies of the lesions treated 4 weeks later revealed no melanoma cells. | No adverse events occurred during the intervention. |
| Matthiessen <i>et al.</i> (2011) [4] | 52 (196) | Cutaneous metastases of malignant melanoma, breast cancer, adenocarcinoma, basal cell carcinoma, squamous cell carcinoma | LA and E or GA | Intravenous bleomycin (15 mg/m ²), or intratumoural bleomycin | 8-28 min | 1300 V/cm, 8 pulses, 100 μ s, 1 or 5000 Hz (for type I electrodes); 1000 V/cm, 8 pulses, 100 μ s, 1 or 5000 Hz (for type II electrodes); 1000 V/cm, 8 pulses, 100 μ s, 5000 Hz (for type III electrodes) | 79 | 60 | - | Treatment was well-tolerated by patients and no serious adverse events were reported. |
| Marengo <i>et al.</i> (2011) [100] | 1 (11) | Recurrent squamous cell carcinoma | GA | Intravenous bleomycin (15 mg/m ²) | NM | NM | 100 | 100 | A response was observed 2 weeks after treatment. At Week 4, the infiltration was no longer evident and only residual superficial ulcers were covered by necrotic crusts. | NM |

Table 1. (Continued)

| Study | No. of patients (lesions) | Tumour characteristics | Anaesthesia | Treatment (drug/ dose/ route) | Interval between drug administration and electric pulse | Pulse characteristics (field strength, no. of pulses, duration, frequency) | OR | CR | Comments on outcome | Side effects and drawbacks |
|---------------------------------------|---------------------------|---|-------------|--|---|---|------|------|---|---|
| Kis <i>et al.</i> (2011) [37] | 9 (148) | Cutaneous and subcutaneous metastases of malignant melanoma | GA | Intravenous bleomycin (15 mg/m ²) | 8-28 min | 1000 V/cm, 8 pulses, 100 µs, 1 or 5000 Hz (for type II electrodes); 1000 V/cm, 96 pulses, 100 µs, 5000 Hz (for type III electrodes) | 62 | 23 | - | Marks from needle electrodes were Visible on the skin for approximately 1 month. |
| Skarlatos <i>et al.</i> (2011) [43] | (52/NM) | Progressive and metastatic lesions of melanoma, squamous cell carcinoma, Kaposi's sarcoma, breast, and others | LA or GA | Intravenous bleomycin (15 mg/m ²), or intratumoural bleomycin (0.25-1mg/cm ³ of tissue) | 8 min after intravenous or within 10 min after intratumoural injection | 400 V, 730 V or 960 V depending on the type of electrodes | 95.7 | 63.8 | - | None |
| Matthiessen <i>et al.</i> (2012) [66] | 12 (NM) | Cutaneous recurrences of breast cancer | GA | Intravenous (15 mg/m ²), or intratumoural bleomycin | 8-28 min after intravenous or within 10 min after intratumoural injection | 1000 V/cm, 8 pulses, 100 µs, 1 or 5000 Hz | 17 | 9 | Symptomatic relief included decreasing exudates, odour, and bleeding. | The main side effect was post-treatment pain. |
| Lantini <i>et al.</i> (2012) [59] | 18 (72) | Kaposi's sarcoma | GA | Intravenous bleomycin (15 mg/m ²) | 8 min | According to the ESOPE protocol | 100 | 78 | The treatment was associated with reduction of Viral load to undetectable levels. | NM |
| Benevento <i>et al.</i> (2012) [67] | 12 (142) | Skin or subcutaneous metastases of breast cancer | GA | Intravenous bleomycin (15 mg/m ²) | 8 min | According to the ESOPE protocol | 92 | 75 | - | Adverse events consisted of pain and ulceration in the treated area 1-2 days after treatment. |

Table 1. (Continued)

| Study | No. of patients (lesions) | Tumour characteristics | Anaesthesia | Treatment (drug/ dose/ route) | Interval between drug administration and electric pulse | Pulse characteristics (field strength, no. of pulses, duration, frequency) | OR | CR | Comments on outcome | Side effects and drawbacks |
|------------------------------------|---------------------------|--|-------------|---|---|--|------|------|--|---|
| Curatolo <i>et al.</i> (2012) [55] | 23 (532) | Unresectable Kaposi's sarcoma | GA | Intravenous bleomycin (15 mg/m ²) | 8-28 min | According to the ESOPE protocol | 100 | 65 | - | Cutaneous infection was observed in 2 patients and was treated with oral antibiotics, leading to complete remission within a few days. Two patients complained of local pain during the first few days. |
| Campana <i>et al.</i> (2012) [5] | 85 (894) | Superficial metastases of malignant melanoma | LA or GA | Intravenous bleomycin (15 mg/m ²), or intratumoural bleomycin (1 mg/cm ³ of tissue), or a combination of intravenous and intratumoural bleomycin | 8 min after intravenous and 1 min after intratumoural injection | 1000 V/cm, 8 pulses, 100 µs, 5000 Hz | 94 | 48 | Significant predictive factors for response were tumour size and number of lesions. An increasing number of electrode applications and ECT were predictors of local control. | There were no signs or predictors of toxicity. |
| Campana <i>et al.</i> (2012) [65] | 37(196) | Unresectable chest wall recurrence from breast cancer | GA | Intravenous bleomycin (15 mg/m ²) | 8 min | 910-1000 V/cm, 8 pulses, 100 µs, 5000 Hz | 91.4 | 54.3 | - | Related morbidity was mild, increased after retreatments, and consisted primarily of pain and acute skin ulceration. |
| Kis <i>et al.</i> (2012) [52] | 3 (Multiple) | Gorlin-Goltz syndrome (numerous basal cell carcinomas) | NM | Intravenous bleomycin (15 mg/m ²) | 8-28 min | According to the ESOPE protocol | 99 | 87 | None of the CR lesions relapsed during follow-up (2-20 months). | One day after treatment, erythema and slight oedema around treated lesions, as well as sore muscle due to muscle contractions at the time of pulse delivery, were reported. |
| Seelsi <i>et al.</i> (2013) [61] | 1(1) | Advanced Merkel cell carcinoma | GA | Intravenous bleomycin (15 mg/m ²) | 8-28 min | According to the ESOPE protocol | 100 | NM | - | None |

Table 1. (Continued)

| Study | No. of patients (lesions) | Tumour characteristics | Anaesthesia | Treatment (drug/dose/route) | Interval between drug administration and electric pulse | Pulse characteristics (field strength, no. of pulses, duration, frequency) | OR | CR | Comments on outcome | Side effects and drawbacks |
|------------------------------------|---------------------------|--|-------------|---|---|--|------|------|--|--|
| Caracò <i>et al.</i> (2013) [46] | 60 (NM) | Refractory cutaneous melanoma metastases | LA or GA | Intravenous bleomycin (15 mg/m ²) | 8-28 min | According to the ESOPE protocol | 86.7 | 48.4 | - | Most frequent side effects were pain and myalgia |
| Gatti A <i>et al.</i> (2014) [70] | 3(3) | Cutaneous marginal zone B-cell lymphomas | SA | Intravenous bleomycin (15 mg/m ²) | 8 min | 8 pulses, 100 µs | 100 | 100 | No relapses were observed during 18 months of follow-up. | NM |
| Macri <i>et al.</i> (2014) [55] | 1(1) | Ulcerated squamous cell carcinoma | S and LA | Intravenous bleomycin (15 mg/m ²) | 8 min | 1000 V/cm, a series of 8 pulses, 100 µs, 5000 Hz | 100 | 100 | Two months after treatment, the lesion diminished in diameter and the absence of disease recurrence was confirmed by an incisional biopsy. | None |
| Salwa <i>et al.</i> (2014) [51] | 3(3) | Peri-ocular basal cell carcinoma | S and LA | Intratumoural bleomycin (range: 1.5 to 3 mg) | NM | According to the ESOPE protocol | 100 | 100 | - | NM |
| Di Monta <i>et al.</i> (2014) [58] | 19 (multiple) | Kaposi's sarcoma | LA or GA | Intravenous bleomycin (15 mg/m ²) | 8-28 min | According to the ESOPE protocol | 100 | 100 | - | Pain and erythema of the treated area were reported. The erythema usually disappeared within a few days and a crust over the treated areas was present for 2 weeks |
| Campana <i>et al.</i> (2014) [69] | 34 (210) | Superficial and measurable soft tissue sarcoma tumours | GA | Intravenous bleomycin (15 mg/m ²) | 8 min | According to the ESOPE protocol | 92.2 | 32.3 | Tumour response and control correlated with histological grading. | Skin ulceration and soft tissue necrosis were manageable on an outpatient basis. |
| Ricotti <i>et al.</i> (2014) [40] | 30 (654) | Cutaneous metastases of malignant melanoma | GA | Intravenous bleomycin | 8 min | According to the ESOPE protocol | 100 | 67.3 | 24 months later, the local tumour control rate was 72%. | NM |

Table 1. (Continued)

| Study | No. of patients (lesions) | Tumour characteristics | Anaesthesia | Treatment (drug/ dose/ route) | Interval between drug administration and electric pulse | Pulse characteristics (field strength, no. of pulses, duration, frequency) | OR | CR | Comments on outcome | Side effects and drawbacks |
|---------------------------------------|---------------------------|---|-------------|--|---|--|------|------|---|---|
| Solari <i>et al.</i> (2014) [41] | 39 (39) | Cutaneous or subcutaneous metastases of melanoma, breast cancer, Kaposi's sarcoma, basal cell carcinoma, squamous cell carcinoma, Merkel cell carcinoma, cutaneous angiosarcoma, and gastric adenocarcinoma | GA | Intravenous bleomycin (15 mg/m ²) | 8-30 min | According to the ESOPE protocol | 66.7 | 23 | Response rate significantly correlated with both number and size of metastases, based on univariate analysis. | Reported adverse events (fever and pain in the treated area, 1-2 days after treatment) were easily manageable with acetaminophen. |
| Mir-Bonafé <i>et al.</i> (2015) [108] | 31 (multiple) | Primary melanoma | GA | Intravenous bleomycin (15 mg/m ²) | 8 min | According to the ESOPE protocol | 72 | 23 | - | Immediate local complications (pain, swelling, erythema) were mild and resolved within 48 hours in most cases. |
| Mozzillo <i>et al.</i> (2015) [123] | 15 (multiple) | Cutaneous metastases of malignant melanoma | LA or GA | Ipilimumab followed by intravenous bleomycin (15 mg/m ²) | 8 min | According to the ESOPE protocol | 67 | 27 | - | None |
| Cabula <i>et al.</i> (2015) [68] | 125 (239) | Cutaneous metastases of breast cancer | LA or GA | Intratumoural bleomycin | NM | According to the ESOPE protocol | 90.2 | 58.4 | Small tumour size, absence of visceral metastases, oestrogen receptor positivity, and low Ki-67 index were significantly associated with complete response. | In the first 48 hours, some of the patients reported severe skin pain. Dermatological toxicity included skin ulceration and skin hyperpigmentation. |

Table 1. (Continued)

| Study | No. of patients (lesions) | Tumour characteristics | Anaesthesia | Treatment (drug/ dose/ route) | Interval between drug administration and electric pulse | Pulse characteristics (field strength, no. of pulses, duration, frequency) | OR | CR | Comments on outcome | Side effects and drawbacks |
|-------------------------------------|---------------------------|--|-------------|--|---|---|------|------|--|---|
| Kreuter <i>et al.</i> (2015) [47] | 56 (NM) | Malignant melanoma, Breast cancer, primary squamous cell carcinoma of the skin or cutaneous metastases of other carcinoma types, cutaneous lymphoma or sarcoma | GA | Intravenous bleomycin (15 mg/m ²) | 8 min | According to the ESOPE protocol | 44.6 | 10.7 | - | Only few adverse effects. |
| Quaglino <i>et al.</i> (2015) [101] | 121 (NM) | Metastatic melanoma, squamous cell carcinoma, breast cancer, basal cell carcinoma, Kaposi's sarcoma, sarcoma, Merkel cell carcinoma | LA or GA | Intravenous (15 mg/m ²), or intratumoural bleomycin (1 mg/mm ³ of tissue) | NM | 1300 V/cm, 8 pulses, 100 µs, 1 or 5000 Hz (for type I electrodes); 1000 V/cm, 8 pulses, 100 µs, 1 or 5000 Hz (for type II electrodes); 1000 V/cm, 8 pulses, 100 µs, 5000 Hz (for type III electrodes) | 76 | 46 | - | Pain was reported after the therapy. |
| Lido <i>et al.</i> (2015) [75] | 1(1) | Cutaneous metastasis of unknown primary | GA | Intravenous bleomycin (at a dosage of 26.5 mg) | 8 min | NM | 100 | 100 | Pain and bleeding were significantly reduced. | NM |
| Valpione <i>et al.</i> (2015) [45] | 1(1) | V600E BRAF mutated metastatic melanoma with systemic disease | GA | Intravenous bleomycin (15 mg/m ²) after dabrafenib | NM | NM | 100 | NM | - | No significant cutaneous toxicity. |
| Guida <i>et al.</i> (2016) [71] | 19 (54) | Locally advanced and metastatic angiosarcoma | S or GA | Intravenous bleomycin (15 mg/m ²) | 8 min | 400-960 V, 8 pulses, 100 µs, 5,000 Hz | 63 | 42 | Local symptom improvement included palliation of bleeding and pain relief. | Varying cutaneous toxicity (erythema, tissue oedema, and skin ulceration) was reported. |

Table 1. (Continued)

| Study | No. of patients (lesions) | Tumour characteristics | Anaesthesia | Treatment (drug/ dose/ route) | Interval between drug administration and electric pulse | Pulse characteristics (field strength, no. of pulses, duration, frequency) | OR | CR | Comments on outcome | Side effects and drawbacks |
|------------------------------------|---------------------------|---|-------------|--|--|--|------|------|---|--|
| Hiribmik <i>et al.</i> (2016) [48] | 5 (111) | Advanced melanoma | LA or GA | Intravenous bleomycin (15 mg/m ²), or intratumoural cisplatin after IFN- α adjuvant therapy | NM | According to the ESOPE protocol | 100 | 85 | - | NM |
| Campana <i>et al.</i> (2016) [49] | 376 (1304) | Melanoma, squamous cell carcinoma, Kaposi's sarcoma, breast carcinoma, basal cell carcinoma, soft tissue sarcomas, and others | LA or GA | Intravenous or intratumoural bleomycin or cisplatin | NM | According to the ESOPE protocol | 83.7 | 50.3 | - | None |
| Bertino <i>et al.</i> (2016) [44] | 105 (105) | Basal cell carcinoma, malignant melanoma, squamous cell carcinoma, and others | LA or GA | Intravenous bleomycin, or intratumoural bleomycin | 8 min after intravenous or immediately after intratumoural injection | According to the ESOPE protocol | 82 | 63 | Small, primary, and treatment-naive carcinomas responded significantly better ($p < 0.05$), based on univariate analysis. | Skin ulceration, skin hyperpigmentation, suppuration, headache, nausea, skin odour, dysphagia, and maculopapular rash were reported. |
| Bourke <i>et al.</i> (2016) [63] | 24 (236) | Cutaneous breast cancer lesions refractory to alternative therapy | NM | Intravenous bleomycin (15 mg/m ²) or intratumoural bleomycin | 8 min after intravenous and after intratumoural injection | According to the ESOPE protocol | 79.7 | 64.3 | - | NM |

NM: not mentioned, S: sedation, LA: local anaesthesia, GA: general anaesthesia, SA: spinal anaesthesia, E: epinephrine, OR: objective response, CR: complete response

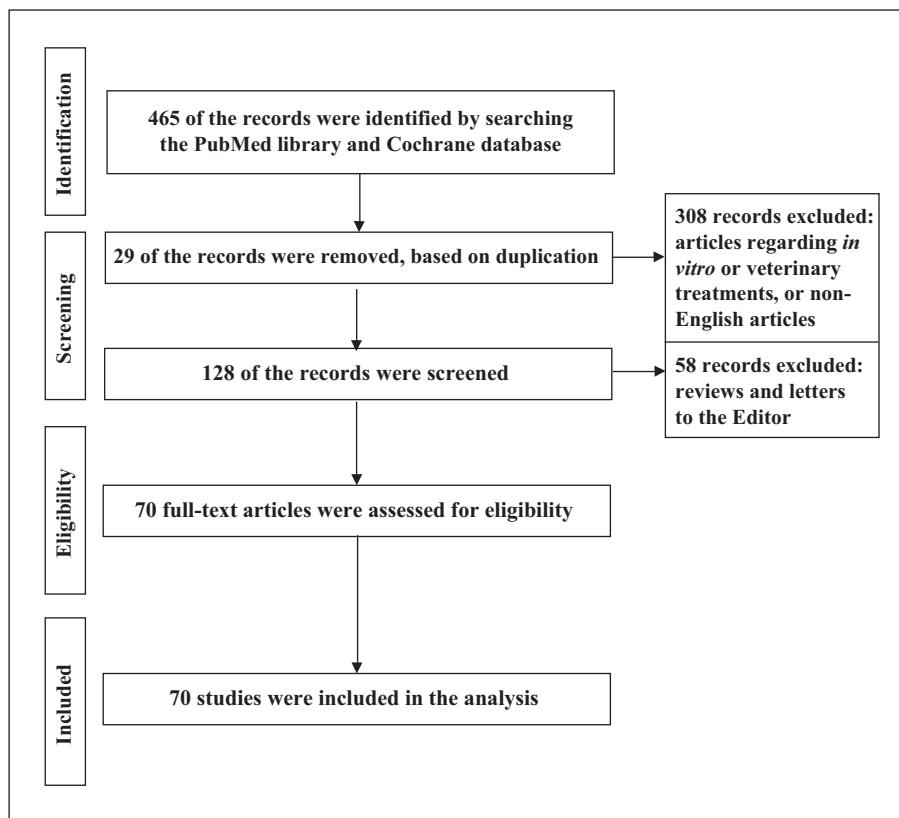


Figure 1. Flow of information through the different phases of the review.

83.46% (95% CI: 73.42-91.57%), 89.61% (95% CI: 83.87-94.24%), and 80.82% (95% CI: 66.00-92.36%), respectively (complete response: 49.53% [95% CI: 36.57-62.52%], 60.32% [95% CI: 51.91-68.43%], and 63.06% [95% CI: 36.32-86.44%], respectively). However, the choice of the drug and its administration route should be made based on tumour size and number of tumour nodules [15]. In general, the intravenous route is recommended in the presence of extensive disease, lymphedema, and any other conditions that could predict an irregular distribution of the drug within the tumour, whereas the intratumoural route is preferable for poorly perfused nodules [82].

Dosage of chemotherapeutic agent

The amount of drug administered into cells is a crucial factor, which is proportional to the drug concentration around the tumour. During growth, vascularization notably decreases with the size of the tumour. In addition, following an increase in pressure, diffusion and convection processes decrease [13].

The required drug dosage is based on tumour size. For direct administration into the tumour, the dose of injected drug is smaller than the normal intravenous dose unless the tumour volume is very large. As a result, if the tumour is very large or a large number of tumours are going to be electroporated, intravenous administration seems to be more convenient than intratumoural injection [14, 83]. In previous studies, intravenous bleomycin was mostly given at a dose of 10 or 15 mg/m² (10-20 mg/m² of body surface), and when administered as an intratumoural injection, the dose was

usually dependent on tumour volume and varied between 0.5 and 4 mg/cm³ (of tumour size) [14]. The dose of cisplatin by intratumoural route was 1 mg/cm³ of tumour size [2, 37, 81].

Timing of drug administration

As tumours are inhomogeneous, in terms of drug distribution and electrical conductivity, the only way to ensure that the drug has reached the target tissue is by performing pulse delivery after injection of the drug [84], when an appropriate drug concentration is available in the interstitial fluid around the tumour cells [85]. With intravenous administration, electric pulse delivery to the treated area needs to be timed to the pharmacokinetic peak of the drug, which in humans is between 8 and 28 minutes after its administration [37, 85]. However, the intratumoural drug administration requires electric pulse delivery between 1 and 10 minutes after the injection [25, 26, 37].

Selection of appropriate electrodes

The distribution of the electric field in the target tissue depends on the geometry and configuration of the electrodes [37]. Therefore, electrodes should be carefully selected according to shape and size of the tumour [37, 86]. The increasing number of electrode applications and electrochemotherapy cycles were shown to be predictors of superficial tumour control. This finding justifies the insertion of multiple electrodes during a single procedure and the application of more electrochemotherapy courses for

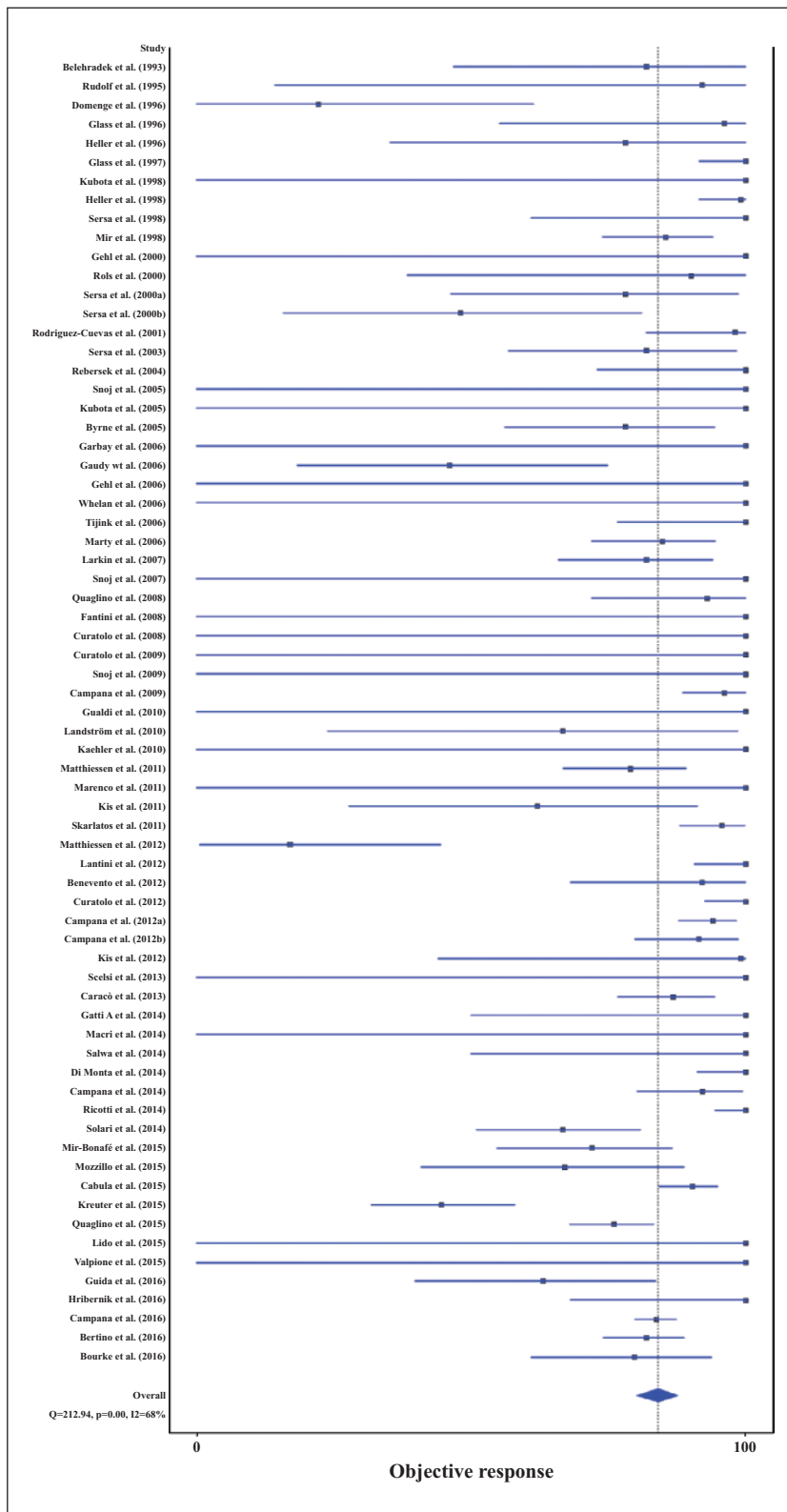


Figure 2. Estimated mean objective response of electrochemotherapy in the management of primary and metastatic cutaneous malignant tumours.

the patients with large and/or diffuse metastases [5]. Electric pulses for electroporation of tissue were delivered by different sets of electrodes, such as plate electrodes (type I

[15, 85], row needle electrodes (type II) [15, 87], hexagonal-centred electrodes (type III) [15, 88], and finger electrodes (type IV) [82]. The plate and row needle electrodes were

limited to treatment of superficial and small tumour nodules (<2 cm diameter), whereas hexagonal-centred electrodes allowed the treatment of bigger (2-3-cm diameter), thicker, and deeper-seated tumour nodules [15, 82, 88]. No difference was observed in objective response rate of the treated tumour nodules regarding the electrodes used [15]. However, the least amount of muscle contraction was detected when hexagonal-centred electrodes (type III) were used and the strongest muscle contractions were reported with plate electrodes (type I) [15].

Characteristics of electric pulses

Depending on the electrodes, four, six, or eight electric pulses were delivered per application. Pulses were delivered by placing appropriate stainless electrodes on the skin adjacent to or around the tumour. Skin contact was ensured using electrocardiography paste and shaving when necessary [22]. For electrochemotherapy of small tumours, one series of electric pulses was recommended. [22]. However, for the treatment of large tumours, sequential electrical treatments were applied at adjacent positions in order to cover the entire tumour volume [22]. The electric pulses delivered in most reported cases were consecutive square waves with duration of 100 μ s, voltage and current amplitudes of up to 3,000 V and 50 A, respectively, and frequency of between 1 to 5,000 Hz [84]. The comparison of electrochemotherapy at 1 and 5,000 Hz demonstrated similar antitumour effectiveness [4, 15, 62, 89-91]. Therefore, 5,000-Hz frequency was selected for patients with multiple nodules, because this exceeds the frequency of tetanic contraction. As a result, delivering the electric pulses at a repetitive frequency of 5,000 Hz not only shortens treatment duration for each nodule to just 1.5 mseconds, but also makes the electrochemotherapy treatment more comfortable, because the multiple delivered pulses are perceived by the patients as a single stimulus, producing an unpleasant sensation only once [4, 15, 62, 89-91].

Clinical responses to electrochemotherapy for malignant cutaneous tumours

The estimate for mean objective treatment response of evaluated studies was 83.91% (95% CI: 79.15-88.17%) for bleomycin and 80.82% (95% CI: 66.00-92.36%) for cisplatin. Efficacy of electrochemotherapy has been reported to be independent of the treated tumour types [14, 15, 42, 49, 82, 92]. Similarly, in the current review, electrochemotherapy was found to be effective for basal cell carcinoma [2, 21, 50, 78, 93], malignant melanoma [2, 5, 12, 13, 17, 21, 23, 36, 40, 73, 74, 79, 92, 94-97], cutaneous lesions of breast cancer [2, 63, 64, 80], squamous cell carcinoma [2, 21, 96, 98-100], Kaposi's sarcoma [55-57], Merkel cell carcinoma [41, 60, 61, 96, 101], and other tumours. The efficacy of this method is presented in more detail in *table 2*.

Correlation between electroporation efficacy and tumour size is one of the controversial aspects. In some studies, no statistical difference was observed among the responses when tumours were grouped according to their size [15, 41, 95]. However, other studies showed that the size of lesion was associated with a different response rate [4, 11, 44, 62]. In fact, authors stated that local response

was inversely correlated with the maximum diameter of the target lesion [102]. However, based on multivariable analysis, a tumour size equal to or less than 3 was associated with better response to treatment [5, 44]. Another prognostic variable for local control was the number of lesions, and 20 or fewer lesions showed better response [5]. The correlation between response and the number of tumour nodules might raise the possibility that some lesions could have been electroporated beyond the recommended bleomycin washout time [5, 81].

Side effects of electrochemotherapy

In the reviewed studies, electroporation delivery was shown to be safe, without any major local or general adverse effects [11, 13, 21, 30, 85, 98, 101]. In particular, no significant modification of haemodynamic or cardiological parameters was noticed even when the treated tumours were located in the chest above the cardiac region. A painless contraction of the underlying muscles was regularly observed at the end of each pulse. However, most of the patients had no residual pain or discomfort from the electrical pulses, either immediately after the treatment or in the following hours or days [11, 13, 21, 30, 85, 98, 101]. Furthermore, after a number of hours following treatment, the only noticeable effects were the occurrence of erythema and slight oedema at the treated area, which soon disappeared. Therefore, all of the observed minor adverse effects seem to be reversible [11, 13, 21, 30, 85, 98].

Discussion

Several reviews have reported on the effectiveness of electrochemotherapy, but no recent comprehensive summary of the effectiveness of electrochemotherapy on skin tumours has been published. In this systematic review, the mean objective response of electrochemotherapy across all eligible studies was estimated at 84.02% (95%CI: 80.08-87.61%).

Systemic chemotherapy has only a palliative role, with response rates below 25% as monotherapy [11, 103]. More aggressive polichemo- or chemoimmunotherapeutic schedules have been recommended to increase response rates, but these are associated with high toxicity and many trials failed to show a significant survival improvement in patients [11, 103]. There are also other issues associated with the management of skin metastases, such as the detrimental impact on quality of life of the patients and the need for significant time-consuming and costly resources, such as nursing support and intensive dressing schedules [11].

In order to cope with these issues, enhanced delivery of chemotherapeutic drugs to tumour cells by electroporation was first introduced by Okino and Mohri [6], and used as a new antitumour treatment strategy by Belehradec *et al.* in 1993 for permeation nodules [98]. Following this study, several clinical studies on electrochemotherapy using bleomycin and cisplatin were initiated to treat cutaneous metastases of different tumours, such as malignant melanoma, basal cell carcinoma, head and neck squamous cell carcinoma, Kaposi's sarcoma, adenocarcinoma of the breast and salivary gland, hypernephroma, and transitional

Table 2. The estimated mean for objective (complete) responses, after pooled analysis.

| Tumour type | Objective response | | | | Complete response | | | |
|--------------------------------|--------------------------|--------|--------------------------------|--------------------|--------------------------|--------|--------------------------------|--------------------|
| | Estimate for OR (95% CI) | Q | I ² (inconsistency) | Significance level | Estimate for CR (95% CI) | Q | I ² (inconsistency) | Significance level |
| Basal cell carcinoma | 95.86% (91.61-98.75%) | 7.11 | 0% | 0.79 | 83.69% (74.35-91.31%) | 15.48 | 29% | 0.16 |
| Squamous cell carcinoma | 78.74%(70.98-85.60%) | 4.36 | 0% | 0.89 | 40.39% (31.81-49.28%) | 8.82 | 0% | 0.45 |
| Malignant melanoma | 80.63%(74.50-86.11%) | 70.42 | 55.00% | < 0.001 | 50.58% (42.71-58.44%) | 79.77 | 61.00% | < 0.001 |
| Breast cancer | 80.18%(66.45-91.14%) | 41.46 | 76% | < 0.001 | 46.39% (32.72-60.32%) | 33.64 | 70% | < 0.001 |
| Kaposi's sarcoma | 95.78% (91.02-98.91%) | 6.51 | 0% | 0.48 | 77.74% (54.64-94.78%) | 28.83 | 76% | < 0.001 |
| All studies | 84.02% (80.08-87.61%) | 212.94 | 68% | <0.001 | 58.58% (52.71-64.34%) | 290.35 | 77% | <0.001 |

OR: objective response; CR: complete response.

cell carcinoma of the bladder [14, 29, 30, 81, 92]. The basic mechanism of electrochemotherapy accounts for the high response rate regardless of histological type. Electroporation is a physical phenomenon that can be applied to all types of living cells [22]. This is due to the fact that, besides membrane permeabilization and magnification of drug cytotoxicity, the application of electric pulses to targeted tissues induces a reversible and transient decrease of tumour blood flow (around 80% reduction) [5, 36, 76, 104, 105]. This transient vasoconstriction at the arteriolar level, called “vascular lock”, leads to drug entrapment in the targeted tissue [5, 36, 76, 104, 106]. As a consequence, the uptake of chemotherapeutic drugs into the tumour vascular endothelial cells leads to unrepairable damage to tumour vessels and to a further decrease in tumour blood flow within hours after electrical treatment [76], which breaks down the nutrient supply and causes death of tumour cells [76]. The synergism of these mechanisms accounts for the notable results for the treatment of all histological types of tumours [5, 14, 15, 42, 92], in which a mean objective treatment response of 83.91% and 80.82% was shown after electrochemotherapy with bleomycin and cisplatin, respectively. Similar to the previous reviews [107], in general, basal cell carcinomas showed highest objective and complete response among all types of tumours. The differences in effectiveness of electrochemotherapy in various clinical studies might be due to heterogeneous treatment conditions (*i.e.* tumour characteristics, patients’ features, drug type, route of drug administration, and electroporation settings) [107].

In order to resolve various controversies regarding the clinical application of this method, a guideline for standard operating procedures for electrochemotherapy was provided in 2006 to unify application strategies in order to conveniently treat patients with cutaneous and subcutaneous nodules by electrochemotherapy [81]. The guideline recommended that all patients should undergo full history-taking, clinical examination, ECG, and the following laboratory tests, before the therapy: full blood count, INR and sodium measurements, potassium, chlorine, phosphate, magnesium, urea, creatinine, bilirubin, AST, ALT, AF, γ -GT, LDH, and creatinine clearance [80, 81].

The adverse effects of electrochemotherapy seem to be mild and transient. In most of the studies, complications such as erythema, oedema, and pain appeared immediately and resolved after a few days [108]. Late side effects and systemic toxicity were also mild due to low chemotherapy drug doses [108].

Post-procedure pain seems to be associated with moderate or severe pain before treatment, size of the largest treated lesion, previous irradiation, and a high level of current [15, 22, 85, 101]. Patients at risk of post-procedure pain could be identified at the pre-treatment visit, and/or at the time of treatment, to provide a pain management strategy for them [101], because the unpleasant sensation can be totally managed by local or general anaesthesia [15, 22, 85]. Whether electrochemotherapy is administered during general anaesthesia or only with local anaesthetics depends on the patient and physician as well as the location, condition, number, and size of the tumours [14, 81]. Additionally, epinephrine is often administered to provide a vasoconstrictive effect, which is beneficial as it would pre-

vent washout of the injected drug prior to electroporation [12, 14, 42, 81, 109].

According to the studies, the main technical pitfalls and difficulties for optimal tumour electroporation are based on the following [81, 102]:

- (1) Electrochemotherapy is contraindicated in patients with known allergy to the drug, interstitial lung fibrosis, cumulative bleomycin dose of $\geq 400,000$ UI/m², and chest wall location of lesions and pacemakers [81, 82].
- (2) Electrochemotherapy of a large tumour might be difficult due to the required repeated time-consuming electrode applications, considering the available window after drug injection [102, 110].
- (3) Electrochemotherapy of large tumour size (>3 cm) might be an issue due to the technical impossibility of reaching the inner portion of the tumour at first application [102].
- (4) Electrochemotherapy of previously irradiated fields could be problematic, due to partial electrode needle penetration and suboptimal electrical current delivery in fibrotic tissue [102, 111].

However, the results of the studies demonstrate that electrochemotherapy is a feasible, inexpensive, and easy-to-operate local treatment with no significant adverse effects or patient discomfort [12, 15, 21, 30]. Electrochemotherapy using low doses of chemotherapeutic agents is very specific to tumour cells and causes no damage to healthy peripheral tissue [112, 113]. This method is not only effective for therapy and local control of primary skin cancers [2, 114], but can also be used in patients with only in-transit metastases or regional diseases, or as a complement to other modalities in patients with distant metastases [95, 114]. The method may also be used as a first-line treatment, for example, for the treatment of non-operable primary [79] or recurrent melanoma [74] in which organs are spared, for alleviation of pain or reduction of tumour bleeding in the palliative setting [12, 112], as well as a neoadjuvant treatment before conventional treatment [15, 79].

From the technological point of view, new pulse generators and different electrode types have been provided for the treatment of deep-seated tumours or those located in more challenging anatomical sites, such as the oral cavity or the anal canal [84, 90]. Furthermore, administration of new drugs, such as calcium or a combination of electrochemotherapy and immunotherapeutic compounds (such as Dabrafenib or Ipilimumab) and biological response modifiers, such as IL-2 [42, 45, 115-123], in order to target distant and non-electroporated lesions, could broaden the therapeutic indications of electrochemotherapy [90, 122]. This might be a strategy to obtain better long-term local and systemic control of skin tumours, which may hopefully lead to an increase in overall survival and improvement of patient’s quality of life, within a multidisciplinary oncological approach [29, 122]. However, further new randomised controlled trials are warranted to compare the efficacy and safety of electroporation-mediated skin cancer therapies with current approved management guidelines. ■

Disclosure. *Financial support: none. Conflict of interest: none.*

References

1. Leiter U, Eigentler T, Garbe C. Epidemiology of skin cancer. *Adv Exp Med Biol* 2014; 810: 120-40.
2. Rodriguez-Cuevas S, Barroso-Bravo S, Almanza-Estrada J, Cristobal-Martinez L, Gonzalez-Rodriguez E. Electrochemotherapy in primary and metastatic skin tumors: phase II trial using intralesional bleomycin. *Arch Med Res* 2001; 32: 273-6.
3. Hunger RE, Angermeier S, Seyed Jafari SM, Ochsenbein A, Shafiqhi M. A retrospective study of 1- versus 2-cm excision margins for cutaneous malignant melanomas thicker than 2 mm. *J Am Acad Dermatol* 2015; 72: 1054-9.
4. Matthiessen LW, Chalmers RL, Sainsbury DC, et al. Management of cutaneous metastases using electrochemotherapy. *Acta Oncol* 2011; 50: 621-9.
5. Campana LG, Valpione S, Mocellin S, et al. Electrochemotherapy for disseminated superficial metastases from malignant melanoma. *Br J Surg* 2012; 99: 821-30.
6. Okino M, Mohri H. Effects of a high-voltage electrical impulse and an anticancer drug on in vivo growing tumors. *Jpn J Cancer Res* 1987; 78: 1319-21.
7. Orłowski S, Belehradec J, Paoletti C, Mir LM. Transient electroporation of cells in culture: increase of the cytotoxicity of anticancer drugs. *Biochem Pharmacol* 1988; 37: 4727-33.
8. Mir LM, Banoun H, Paoletti C. Introduction of definite amounts of nonpermeant molecules into living cells after electroporation: direct access to the cytosol. *Exp Cell Res* 1988; 175: 15-25.
9. Seyed Jafari SM, Shafiqhi M, Beltraminelli H, Geiser T, Hunger RE, Gazdhar A. Improvement of flap necrosis in a rat random skin flap model by in vivo electroporation-mediated HGF gene transfer. *Plast Reconstr Surg* 2017; 139: 1116e-27e.
10. Seyed Jafari SM, Shafiqhi M, Beltraminelli H, et al. Efficacy of in vivo electroporation-mediated IL-10 gene delivery on survival of skin flaps. *J Membr Biol* 2018; 251: 211-219.
11. Quaglino P, Mortera C, Osella-Abate S, et al. Electrochemotherapy with intravenous bleomycin in the local treatment of skin melanoma metastases. *Ann Surg Oncol* 2008; 15: 2215-22.
12. Gehl J, Geertsen PF. Efficient palliation of haemorrhaging malignant melanoma skin metastases by electrochemotherapy. *Melanoma Res* 2000; 10: 585-9.
13. Rols MP, Bachaud JM, Giraud P, Chevreau C, Roche H, Teissie J. Electrochemotherapy of cutaneous metastases in malignant melanoma. *Melanoma Res* 2000; 10: 468-74.
14. Gothelf A, Mir LM, Gehl J. Electrochemotherapy: results of cancer treatment using enhanced delivery of bleomycin by electroporation. *Cancer Treat Rev* 2003; 29: 371-87.
15. Marty M, Sersa G, Garbay JR, et al. Electrochemotherapy—An easy, highly effective and safe treatment of cutaneous and subcutaneous metastases: results of ESOPE (European Standard Operating Procedures of Electrochemotherapy) study. *EJC Suppl* 2006; 4: 3-13.
16. Plaschke CC, Gothelf A, Gehl J, Wessel I. Electrochemotherapy of mucosal head and neck tumors: a systematic review. *Acta Oncol* 2016; 55: 1266-72.
17. Sersa G, Stabuc B, Cemazar M, Miklavcic D, Rudolf Z. Electrochemotherapy with cisplatin: clinical experience in malignant melanoma patients. *Clin Cancer Res* 2000; 6: 863-7.
18. Mir L, Orłowski S, Belehradec J, et al. Biomedical applications of electric pulses with special emphasis on antitumor electrochemotherapy. *Bioelectrochem Bioenerg* 1995; 38: 203-7.
19. Rols M-P, Teissie J. Electroporation of mammalian cells. Quantitative analysis of the phenomenon. *Biophys J* 1990; 58: 1089.
20. Sersa G, Stabuc B, Cemazar M, Miklavcic D, Rudolf Z. Electrochemotherapy with cisplatin: the systemic antitumor effectiveness of cisplatin can be potentiated locally by the application of electric pulses in the treatment of malignant melanoma skin metastases. *Melanoma Res* 2000; 10: 381-5.
21. Mir LM, Glass LF, Sersa G, et al. Effective treatment of cutaneous and subcutaneous malignant tumors by electrochemotherapy. *Br J Cancer* 1998; 77: 2336-42.
22. Heller R, Gilbert R, Jaroszeski MJ. Clinical applications of electrochemotherapy. *Adv Drug Deliv Rev* 1999; 35: 119-29.
23. Kaehler KC, Egberts F, Hauschild A. Electrochemotherapy in symptomatic melanoma skin metastases: intraindividual comparison with conventional surgery. *Dermatol Surg* 2010; 36: 1200-2.
24. Sersa G, Cemazar M, Miklavcic D. Antitumor effectiveness of electrochemotherapy with cis-diamminedichloroplatinum(II) in mice. *Cancer Res* 1995; 55: 3450-5.
25. Heller R, Jaroszeski M, Perrott R, Messina J, Gilbert R. Effective treatment of B16 melanoma by direct delivery of bleomycin using electrochemotherapy. *Melanoma Res* 1997; 7: 10-8.
26. Cemazar M, Milacic R, Miklavcic D, Dolzan V, Sersa G. Intratumoral cisplatin administration in electrochemotherapy: antitumor effectiveness, sequence dependence and platinum content. *Anticancer Drugs* 1998; 9: 525-30.
27. Moher D, Liberati A, Tetzlaff J, Altman DG. Preferred reporting items for systematic reviews and meta-analyses: the PRISMA statement. *Ann Intern Med* 2009; 151: 264-9.
28. DerSimonian R, Laird N. Meta-analysis in clinical trials. *Control Clin Trials* 1986; 7: 177-88.
29. Queirolo P, Marincola F, Spagnolo F. Electrochemotherapy for the management of melanoma skin metastasis: a review of the literature and possible combinations with immunotherapy. *Arch Dermatol Res* 2014; 306: 521-6.
30. Rudolf Z, Stabuc B, Cemazar M, Miklavcic D, Vodovnik L, Sersa G. Electrochemotherapy with bleomycin. The first clinical experience in malignant melanoma patients. *Radial Oncol* 1995; 29: 229-35.
31. Tounekti O, Pron G, Belehradec J Jr., Mir LM. Bleomycin, an apoptosis-mimetic drug that induces two types of cell death depending on the number of molecules internalized. *Cancer Res* 1993; 53: 5462-9.
32. Pron G, Belehradec J, Mir L. Identification of a plasma membrane protein that specifically binds bleomycin. *Biochem Biophys Res Commun* 1993; 194: 333-7.
33. Pron G, Belehradec J, Orłowski S, Mir LM. Involvement of membrane bleomycin-binding sites in bleomycin cytotoxicity. *Biochem Pharmacol* 1994; 48: 301-10.
34. Poddevin B, Orłowski S, Belehradec J, Mir L. Very high cytotoxicity of bleomycin introduced into the cytosol of cells in culture. *Biochem Pharmacol* 1991; 42: S67-75.
35. Belehradec J Jr., Orłowski S, Ramirez LH, Pron G, Poddevin B, Mir LM. Electroporation of cells in tissues assessed by the qualitative and quantitative electroloading of bleomycin. *Biochim Biophys Acta* 1994; 1190: 155-63.
36. Gehl J, Geertsen PF. Palliation of haemorrhaging and ulcerated cutaneous tumors using electrochemotherapy. *EJC Suppl* 2006; 4: 35-7.
37. Kis E, Olah J, Ocsai H, et al. Electrochemotherapy of cutaneous metastases of melanoma—a case series study and systematic review of the evidence. *Dermatol Surg* 2011; 37: 816-24.
38. Glass LF, Fenske NA, Jaroszeski M, et al. Bleomycin-mediated electrochemotherapy of basal cell carcinoma. *J Am Acad Dermatol* 1996; 34: 82-6.
39. Heller R, Jaroszeski MJ, Glass LF, et al. Phase I/II trial for the treatment of cutaneous and subcutaneous tumors using electrochemotherapy. *Cancer* 1996; 77: 964-71.
40. Ricotti F, Giuliodori K, Cataldi I, et al. Electrochemotherapy: an effective local treatment of cutaneous and subcutaneous melanoma metastases. *Dermatol Ther* 2014; 27: 148-52.
41. Solari N, Spagnolo F, Ponte E, et al. Electrochemotherapy for the management of cutaneous and subcutaneous metastasis: a series of 39 patients treated with palliative intent. *J Surg Oncol* 2014; 109: 270-4.
42. Heller R, Jaroszeski MJ, Reintgen DS, et al. Treatment of cutaneous and subcutaneous tumors with electrochemotherapy using intralesional bleomycin. *Cancer* 1998; 83: 148-57.
43. Skarlatos I, Kyrgias G, Mosa E, et al. Electrochemotherapy in cancer patients: first clinical trial in Greece. *In Vivo* 2011; 25: 265-74.
44. Bertino G, Sersa G, De Terlizzi F, et al. European Research on Electrochemotherapy in Head and Neck Cancer (EURECA) project: results of the treatment of skin cancer. *Eur J Cancer* 2016; 63: 41-52.

- 45.** Valpione S, Campana LG, Pigozzo J, Chiarion-Sileni V. Consolidation electrochemotherapy with bleomycin in metastatic melanoma during treatment with dabrafenib. *Radiol Oncol* 2015; 49: 71-4.
- 46.** Caraco C, Mozzillo N, Marone U, et al. Long-lasting response to electrochemotherapy in melanoma patients with cutaneous metastasis. *BMC Cancer* 2013; 13: 564.
- 47.** Kreuter A, van Eijk T, Lehmann P, et al. Electrochemotherapy in advanced skin tumors and cutaneous metastases - a retrospective multicenter analysis. *J Dtsch Dermatol Ges* 2015; 13: 308-15.
- 48.** Hribernik A, Cemazar M, Sersa G, Bosnjak M, Snoj M. Effectiveness of electrochemotherapy after IFN-alpha adjuvant therapy of melanoma patients. *Radiol Oncol* 2016; 50: 21-7.
- 49.** Campana LG, Testori A, Curatolo P, et al. Treatment efficacy with electrochemotherapy: a multi-institutional prospective observational study on 376 patients with superficial tumors. *Eur J Surg Oncol* 2016; 42: 1914-23.
- 50.** Fantini F, Gualdi G, Cimitan A, Giannetti A. Metastatic basal cell carcinoma with squamous differentiation: report of a case with response of cutaneous metastases to electrochemotherapy. *Arch Dermatol* 2008; 144: 1186-8.
- 51.** Salwa SP, Bourke MG, Forde PF, et al. Electrochemotherapy for the treatment of ocular basal cell carcinoma; a novel adjunct in the disease management. *J Plast Reconstr Aesthet Surg* 2014; 67: 403-6.
- 52.** Kis E, Baltas E, Kinyo A, et al. Successful treatment of multiple basaloidomas with bleomycin-based electrochemotherapy: a case series of three patients with Gorlin-Goltz syndrome. *Acta Derm Venereol* 2012; 92: 648-51.
- 53.** Macri GF, Greco A, Gallo A, Fusconi M, Marinelli C, de Vincentiis M. Use of electrochemotherapy in a case of neck skin metastasis of oral squamous cell carcinoma: case report and considerations. *Head Neck* 2014; 36: E86-90.
- 54.** Gualdi G, Monari P, Fantini F, Cesinaro AM, Cimitan A. Electrochemotherapy-induced virus disappearance in HHV-8-positive skin nodules of Kaposi sarcoma: first histological and immunohistochemical demonstration of efficacy. *J Eur Acad Dermatol Venereol* 2010; 24: 239-41.
- 55.** Curatolo P, Quaglino P, Marengo F, et al. Electrochemotherapy in the treatment of Kaposi sarcoma cutaneous lesions: a two-center prospective phase II trial. *Ann Surg Oncol* 2012; 19: 192-8.
- 56.** Garbay J-R, Billard V, Bernat C, Mir LM, Morsli N, Robert C. Successful repetitive treatments by electrochemotherapy of multiple unresectable Kaposi sarcoma nodules. *EJC Suppl* 2006; 4: 29-31.
- 57.** Curatolo P, Mancini M, Ruggiero A, Clerico R, Di Marco P, Calvieri S. Successful treatment of penile Kaposi's sarcoma with electrochemotherapy. *Dermatol Surg* 2008; 34: 839-42, discussion: 42-3.
- 58.** Di Monta G, Caraco C, Benedetto L, et al. Electrochemotherapy as "new standard of care" treatment for cutaneous Kaposi's sarcoma. *Eur J Surg Oncol* 2014; 40: 61-6.
- 59.** Latini A, Bonadies A, Trento E, et al. Effective treatment of Kaposi's sarcoma by electrochemotherapy and intravenous bleomycin administration. *Dermatol Ther* 2012; 25: 214-8.
- 60.** Curatolo P, Mancini M, Clerico R, et al. Remission of extensive Merkel cell carcinoma after electrochemotherapy. *Arch Dermatol* 2009; 145: 494-5.
- 61.** Scelsi D, Mevio N, Bertino G, et al. Electrochemotherapy as a new therapeutic strategy in advanced Merkel cell carcinoma of head and neck region. *Radiol Oncol* 2013; 47: 366-9.
- 62.** Larkin JO, Collins CG, Aarons S, et al. Electrochemotherapy: aspects of preclinical development and early clinical experience. *Ann Surg* 2007; 245: 469-79.
- 63.** Bourke MG, Salwa SP, Sadacharam M, et al. Effective treatment of intractable cutaneous metastases of breast cancer with electrochemotherapy: ten-year audit of single centre experience. *Breast Cancer Res Treat* 2017; 161: 289-97.
- 64.** Whelan MC, Larkin JO, Collins CG, et al. Effective treatment of an extensive recurrent breast cancer which was refractory to multimodal therapy by multiple applications of electrochemotherapy. *EJC Suppl* 2006; 4: 32-4.
- 65.** Campana LG, Valpione S, Falci C, et al. The activity and safety of electrochemotherapy in persistent chest wall recurrence from breast cancer after mastectomy: a phase-II study. *Breast Cancer Res Treat* 2012; 134: 1169-78.
- 66.** Matthiessen LW, Johannesen HH, Hendel HW, Moss T, Kamby C, Gehl J. Electrochemotherapy for large cutaneous recurrence of breast cancer: a phase II clinical trial. *Acta Oncol* 2012; 51: 713-21.
- 67.** Benevento R, Santoriello A, Perna G, Canonico S. Electrochemotherapy of cutaneous metastases from breast cancer in elderly patients: a preliminary report. *BMC Surg* 2012; 12: S6.
- 68.** Cabula C, Campana LG, Grilz G, et al. Electrochemotherapy in the treatment of cutaneous metastases from breast cancer: a multicenter cohort analysis. *Ann Surg Oncol* 2015; 22: S442-50.
- 69.** Campana LG, Bianchi G, Mocellin S, et al. Electrochemotherapy treatment of locally advanced and metastatic soft tissue sarcomas: results of a non-comparative phase II study. *World J Surg* 2014; 38: 813-22.
- 70.** Gatti A, Stinco G, Trevisini S, et al. Electrochemotherapy as a novel treatment for primary cutaneous marginal zone B-cell lymphomas. *Dermatol Ther* 2014; 27: 244-7.
- 71.** Guida M, Campana LG, Curatolo P, et al. Local treatment with electrochemotherapy of superficial angiosarcomas: efficacy and safety results from a multi-institutional retrospective study. *J Surg Oncol* 2016; 114: 246-53.
- 72.** Kubota Y, Mir LM, Nakada T, Sasagawa I, Suzuki H, Aoyama N. Successful treatment of metastatic skin lesions with electrochemotherapy. *J Urol* 1998; 160: 1426.
- 73.** Snoj M, Cemazar M, Srnovrsnik T, Kosir SP, Sersa G. Limb sparing treatment of bleeding melanoma recurrence by electrochemotherapy. *Tumori* 2009; 95: 398-402.
- 74.** Kubota Y, Tomita Y, Tsukigi M, Kurachi H, Motoyama T, Mir LM. A case of perineal malignant melanoma successfully treated with electrochemotherapy. *Melanoma Res* 2005; 15: 133-4.
- 75.** Lido P, Paolino G, Feliziani A, et al. Cutaneous metastasis of unknown primary presenting as massive and invasive abdominal lesion: an elective approach with electrochemotherapy. *An Bras Dermatol* 2015; 90: 879-82.
- 76.** Escoffre JM, Rols MP. Electrochemotherapy: progress and prospects. *Curr Pharm Des* 2012; 18: 3406-15.
- 77.** Cemazar M, Miklavcic D, Vodovnik L, et al. Improved therapeutic effect of electrochemotherapy with cisplatin by intratumoral drug administration and changing of electrode orientation for electroporation on EAT tumor model in mice. *Radiol Oncol* 1995; 29: 121-7.
- 78.** Sersa G, Stabuc B, Cemazar M, Jancar B, Miklavcic D, Rudolf Z. Electrochemotherapy with cisplatin: potentiation of local cisplatin anti-tumour effectiveness by application of electric pulses in cancer patients. *Eur J Cancer* 1998; 34: 1213-8.
- 79.** Snoj M, Rudolf Z, Cemazar M, Jancar B, Sersa G. Successful sphincter-saving treatment of anorectal malignant melanoma with electrochemotherapy, local excision and adjuvant brachytherapy. *Anti-cancer Drugs* 2005; 16: 345-8.
- 80.** Rebersek M, Cufer T, Cemazar M, Kranjc S, Sersa G. Electrochemotherapy with cisplatin of cutaneous tumor lesions in breast cancer. *Anticancer Drugs* 2004; 15: 593-7.
- 81.** Mir LM, Gehl J, Sersa G, et al. Standard operating procedures of the electrochemotherapy: instructions for the use of bleomycin or cisplatin administered either systemically or locally and electric pulses delivered by the Cliniporator TM by means of invasive or non-invasive electrodes. *EJC Suppl* 2006; 4: 14-25.
- 82.** Testori A, Tosti G, Martinoli C, et al. Electrochemotherapy for cutaneous and subcutaneous tumor lesions: a novel therapeutic approach. *Dermatol Ther* 2010; 23: 651-61.
- 83.** Mir LM. Therapeutic perspectives of in vivo cell electroporation. *Bioelectrochemistry* 2001; 53: 1-10.
- 84.** Miklavcic D, Serša G, Brecelj E, et al. Electrochemotherapy: technological advancements for efficient electroporation-based treatment of internal tumors. *Med Biol Eng Comput* 2012; 50: 1213-25.
- 85.** Domenge C, Orlowski S, Luboinski B, et al. Antitumor electrochemotherapy: new advances in the clinical protocol. *Cancer* 1996; 77: 956-63.
- 86.** Miklavcic D, Corovic S, Pucihar G, Pavselj N. Importance of tumour coverage by sufficiently high local electric field for effective electrochemotherapy. *EJC Suppl* 2006; 4: 45-51.

- 87.** Gehl J, Sorensen TH, Nielsen K, *et al.* In vivo electroporation of skeletal muscle: threshold, efficacy and relation to electric field distribution. *Biochim Biophys Acta* 1999; 1428: 233-40.
- 88.** Ramirez LH, Orlowski S, An D, *et al.* Electrochemotherapy on liver tumours in rabbits. *Br J Cancer* 1998; 77: 2104-11.
- 89.** Snoj M, Cemazar M, Kolar BS, Sersa G. Effective treatment of multiple unresectable skin melanoma metastases by electrochemotherapy. *Croat Med* 2007; 48: 391.
- 90.** Campana LG, Testori A, Mozzillo N, Rossi CR. Treatment of metastatic melanoma with electrochemotherapy. *J Surg Oncol* 2014; 109: 301-7.
- 91.** Miklavcic D, Pucihar G, Pavlovic M, *et al.* The effect of high frequency electric pulses on muscle contractions and antitumor efficiency in vivo for a potential use in clinical electrochemotherapy. *Bioelectrochemistry* 2005; 65: 121-8.
- 92.** Sersa G, Cemazar M, Rudolf Z. Electrochemotherapy: advantages and drawbacks in treatment of cancer patients. *Cancer Ther* 2003; 1: 133-42.
- 93.** Glass LF, Jaroszeski M, Gilbert R, Reintgen DS, Heller R. Intraleisional bleomycin-mediated electrochemotherapy in 20 patients with basal cell carcinoma. *J Am Acad Dermatol* 1997; 37: 596-9.
- 94.** Byrne CM, Thompson JF, Johnston H, *et al.* Treatment of metastatic melanoma using electroporation therapy with bleomycin (electrochemotherapy). *Melanoma Res* 2005; 15: 45-51.
- 95.** Gaudy C, Richard MA, Folchetti G, Bonerandi JJ, Grob JJ. Randomized controlled study of electrochemotherapy in the local treatment of skin metastases of melanoma. *J Cutan Med Surg* 2006; 10: 115-21.
- 96.** Tijink BM, De Bree R, Van Dongen GA, Leemans CR. How we do it: chemo-electroporation in the head and neck for otherwise untreatable patients. *Clin Otolaryngol* 2006; 31: 447-51.
- 97.** Glass LF, Pepine ML, Fenske NA, Jaroszeski M, Reintgen DS, Heller R. Bleomycin-mediated electrochemotherapy of metastatic melanoma. *Arch Dermatol* 1996; 132: 1353-7.
- 98.** Belehradec M, Domenge C, Luboinski B, Orlowski S, Belehradec J Jr., Mir LM. Electrochemotherapy, a new antitumor treatment. First clinical phase III trial. *Cancer* 1993; 72: 3694-700.
- 99.** Landstrom FJ, Nilsson CO, Crafoord S, Reizenstein JA, Adamsson GB, Lofgren LA. Electroporation therapy of skin cancer in the head and neck area. *Dermatol Surg* 2010; 36: 1245-50.
- 100.** Marengo F, Nardo T, Savoia P, Bernengo MG. Effectiveness of electrochemotherapy in treatment of a recurrent squamous cell carcinoma of the scalp. *Eur J Dermatol* 2011; 21: 618-9.
- 101.** Quaglino P, Matthiessen LW, Curatolo P, *et al.* Predicting patients at risk for pain associated with electrochemotherapy. *Acta Oncol* 2015; 54: 298-306.
- 102.** Campana LG, Mocellin S, Basso M, *et al.* Bleomycin-based electrochemotherapy: clinical outcome from a single institution's experience with 52 patients. *Ann Surgical Oncol* 2009; 16: 191-9.
- 103.** Garbe C, Eigentler TK. Diagnosis and treatment of cutaneous melanoma: state of the art 2006. *Melanoma Res* 2007; 17: 117-27.
- 104.** Jarm T, Cemazar M, Miklavcic D, Sersa G. Antivascular effects of electrochemotherapy: implications in treatment of bleeding metastases. *Expert Rev Anticancer Ther* 2010; 10: 729-46.
- 105.** Sersa G, Cemazar M, Snoj M. Electrochemotherapy of tumours. *Curr Oncol* 2009; 16: 34-5.
- 106.** Sersa G, Cemazar M, Parkins CS, Chaplin DJ. Tumor blood flow changes induced by application of electric pulses. *Eur J Cancer* 1999; 35: 672-7.
- 107.** Mali B, Jarm T, Snoj M, Sersa G, Miklavcic D. Antitumor effectiveness of electrochemotherapy: a systematic review and meta-analysis. *Eur J Surg Oncol* 2013; 39: 4-16.
- 108.** Mir-Bonafe JM, Vilalta A, Alarcon I, *et al.* Electrochemotherapy in the treatment of melanoma skin metastases: a report on 31 cases. *Actas Dermosifiliogr* 2015; 106: 285-91.
- 109.** Allegretti JP, Panje WR. Electroporation therapy for head and neck cancer including carotid artery involvement. *Laryngoscope* 2001; 111: 52-6.
- 110.** Sersa G. The state-of-the-art of electrochemotherapy before the ESOPE study; advantages and clinical uses. *EJC Suppl* 2006; 4: 52-9.
- 111.** Gilbert RA, Jaroszeski MJ, Heller R. Novel electrode designs for electrochemotherapy. *Biochim Biophys Acta* 1997; 1334: 9-14.
- 112.** Testori A, Faries MB, Thompson JF, *et al.* Local and intraleisional therapy of in-transit melanoma metastases. *J Surg Oncol* 2011; 104: 391-6.
- 113.** Byrne CM, Thompson JF. Role of electrochemotherapy in the treatment of metastatic melanoma and other metastatic and primary skin tumors. *Expert Rev Anticancer Ther* 2006; 6: 671-8.
- 114.** Kunte C, Letule V, Gehl J, *et al.* Electrochemotherapy in the treatment of metastatic malignant melanoma: a prospective cohort study by InspECT. *Br J Dermatol* 2017; 176: 1475-85.
- 115.** Mir LM, Orlowski S, Poddevin B, Belehradec J Jr. Electrochemotherapy tumor treatment is improved by interleukin-2 stimulation of the host's defenses. *Eur Cytokine Netw* 1992; 3: 331-4.
- 116.** Mir LM, Roth C, Orlowski S, *et al.* Potentiation of the antitumoral effect of electrochemotherapy by immunotherapy with allogeneic cells producing interleukin 2. *C R Acad Sci III* 1992; 314: 539-44.
- 117.** Mir LM, Roth C, Orlowski S, *et al.* Systemic antitumor effects of electrochemotherapy combined with histoincompatible cells secreting interleukin-2. *J Immunother Emphasis Tumor Immunol* 1995; 17: 30-8.
- 118.** Spanggaard I, Gehl J. Antiangiogenic metargidin peptide (AMEP) gene therapy in disseminated melanoma. *Methods Mol Biol* 2015; 1317: 359-64.
- 119.** Daud AI, DeConti RC, Andrews S, *et al.* Phase I trial of interleukin-12 plasmid electroporation in patients with metastatic melanoma. *J Clin Oncol* 2008; 26: 5896-903.
- 120.** Mir LM. Electroporation-based gene therapy: recent evolution in the mechanism description and technology developments. *Methods Mol Biol* 2014; 1121: 3-23.
- 121.** Gehl J. Gene electrotransfer in clinical trials. *Methods Mol Biol* 2014; 1121: 241-6.
- 122.** Testori A, Rossi CR, Tosti G. Utility of electrochemotherapy in melanoma treatment. *Curr Opin Oncol* 2012; 24: 155-61.
- 123.** Mozzillo N, Simeone E, Benedetto L, *et al.* Assessing a novel immuno-oncology-based combination therapy: ipilimumab plus electrochemotherapy. *Oncoimmunology* 2015; 4: e1008842.