

Lisa BECKENBACH¹
 Jens M. BARON²
 Hans F. MERK²
 Harald LÖFFLER¹
 Philipp M. AMANN^{1,2}

¹ Department of Dermatology, SLK Hospital Heilbronn, Am Gesundbrunnen 20 -26, 74078 Heilbronn, Germany

² Department of Dermatology and Allergology, RWTH Aachen University Hospital, Pauwelsstrasse 30, 52074 Aachen, Germany

Reprints: P. M. Amann
 <philipp.amann@slk-kliniken.de>

Article accepted on 05/2/2015

Retinoid treatment of skin diseases

Retinoids (vitamin A and its metabolites) are potent natural regulators of cellular activities, including cell growth and differentiation, and they mediate many essential regulatory functions, especially in the skin. Biologically active retinoids exert their effects by binding to nuclear retinoic acid receptors and retinoid-X-receptors. The group of pharmacologically used retinoids include naturally occurring and chemically synthesised vitamin A derivatives. Due to their influence on keratinocyte proliferation, epidermal differentiation and keratinisation, retinoids are commonly used in the field of dermatopharmacology. For safe administration of retinoids, in-depth information about adverse effects and comprehensive information of the patient are important. This article gives an overview on the effects, use, and side-effects of topical and systemic retinoids in dermatology.

Key words: dermatopharmacology, retinoid therapy, retinoids, vitamin A derivatives

Vitamin A (all-*trans* retinol) and its naturally occurring and synthetic derivatives, collectively referred to as retinoids, exert a wide variety of profound effects during embryogenesis, reproduction, regulation of inflammation, cell growth and cell differentiation. Their decisive role as critical gene regulators is primarily mediated by their interaction with the nuclear retinoic acid receptors (RAR) and retinoid-X-receptors (RXR) [1]. Isomers of retinoic acid are thought to be the major biologically active “natural ligand” of these receptors. It has been known for quite some time that retinoids have essential regulatory functions in the skin: they modulate and control the epidermal keratinisation process and proliferation of skin cells [2, 3].

In the early 1960s, retinoids were introduced in dermatotherapy for the treatment of ichthyosis [4], and later for psoriasis and acne [5, 6]. After the development of new, chemically modified “synthetic retinoids” with increased safety, retinoids have been widely used in dermatopharmacology due to their ability to affect epithelial differentiation and the growth of pre-cancerous and cancerous skin lesions.

Retinoids in pharmacology

The group of pharmacologically used retinoids includes natural as well as synthetic derivatives that have vitamin A-like effects [7]. Thousands of retinoid acid analogs have been synthesized. Of these, three generations have been established for systemic and topical treatment of various skin disorders [8]:

- The non-aromatic “naturally occurring” retinoids (1st generation)
- The monoaromatic retinoid derivatives (2nd generation)
- The polyaromatic retinoid derivatives (3rd generation)

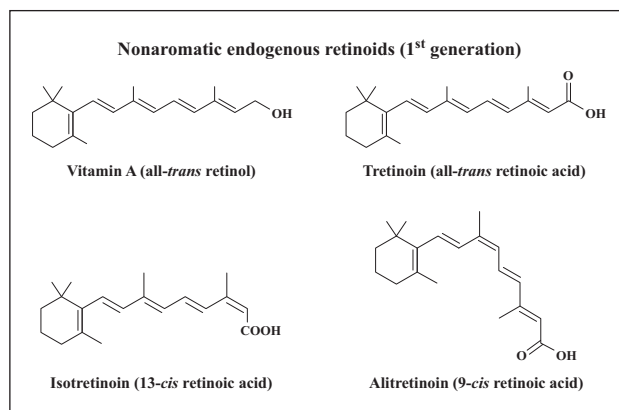


Figure 1. Structure of naturally occurring endogenous retinoids. Vitamin A and endogenous pharmacologically relevant retinoids are displayed and represent retinoids of the first generation.

Endogenous retinoids of the first generation include vitamin A (all-*trans* retinol), tretinoin (all-*trans* retinoic acid), isotretinoin (13-*cis* retinoic acid) and alitretinoin (9-*cis* retinoic acid) (figure 1). Second generation aromatic retinoids include acitretin and etretinate. They are synthesised by changing the cyclic end group. Third generation retinoids, known as arotinoids, have further chemical modifications. This group includes bexarotene and tazarotene. Adapalene is a derivative of naphthoic acid, which has a non-steroidal anti-inflammatory agent (NSAID)-like structure, but retinoid-like features [9] (figure 2).

Physiological and pharmacological effects

The physiological and pharmacological effects of endogenous retinoids are mainly mediated by nuclear RARs and RXRs [1], and are manifested in RAR/RXR-mediated

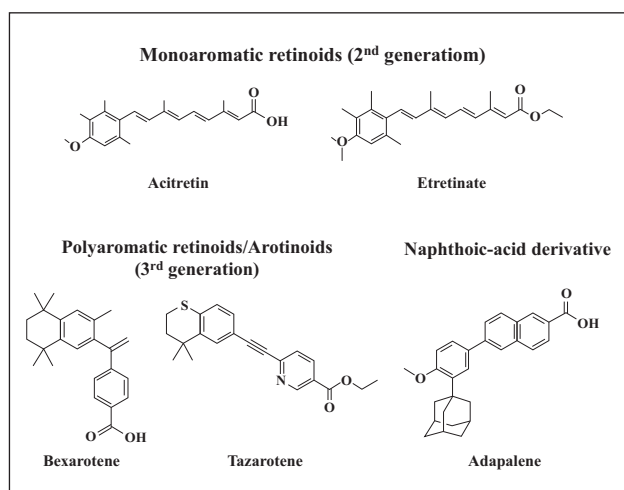


Figure 2. Structure of synthetic retinoids of the second and third generation. These pharmacologically relevant retinoids were chemically modified, resulting in an increased user safety.

transactivation or transrepression (*figure 3*, based on [10]). Transactivation is believed to occur in several steps: (i) ligand binding (e.g. retinoic acid), (ii) dimerisation (e.g. RAR/RXR), (iii) interaction with DNA, (iv) recruitment of coactivators, and (v) RNA elongation [11]. All RAR and RXR protein isotypes ($-\alpha$, $-\beta$ and $-\gamma$) were found immunohistochemically in normal human skin. RAR- γ and RXR- α represent the majority of the cutaneous retinoid receptors [10]. Interestingly, pharmacologically used retinoids show different receptor binding characteristics (*tables 1-2*).

Retinoids modulate various physiological processes, like cellular proliferation and differentiation or the regulation of inflammation in the skin. By affecting epidermal cellular division and differentiation, retinoids also have numerous major effects on embryogenesis and adult formation of the layered epidermal structure. Furthermore, retinoids inhibit growth-stimulating signals and induce a multitude of downstream signalling pathways, which regulate apoptosis, growth arrest and cell differentiation in pre-cancerous and cancerous lesions [12]. Due to these anti-cancer effects, retinoids are pharmacologically used as chemoprotective, as well as therapeutic, agents in dermatology. In addition, retinoids are effective in the therapy of inflammatory skin diseases, hyperproliferative skin diseases and many more skin diseases. Topical retinoids regulate disturbed keratinisation in pilosebaceous glands, reduce inflammatory reactions and increase the penetration of other topical agents [9].

Furthermore, there is evidence that vitamin A plays a role in protecting against free radicals induced by inflammatory processes and therefore its administration may also accelerate the healing process in the skin [13, 14]. Hence, vitamin A and its derivatives also find applications for improving wound healing and preventing skin aging [15].

Different retinoic acid isomers and derivatives have various impacts on gene regulation [16]. Thus, retinoids show a varying spectrum of effects and side effects, which is an important characteristic. For example, isotretinoin is very effective for severe, therapy-refractory forms of acne, as compared to etretinate. In contrast, etretinate or acitretin are preferred for the treatment of psoriasis and other disorders of keratinisation. For that reason, the effects and side effects of each retinoid have to be evaluated individually.

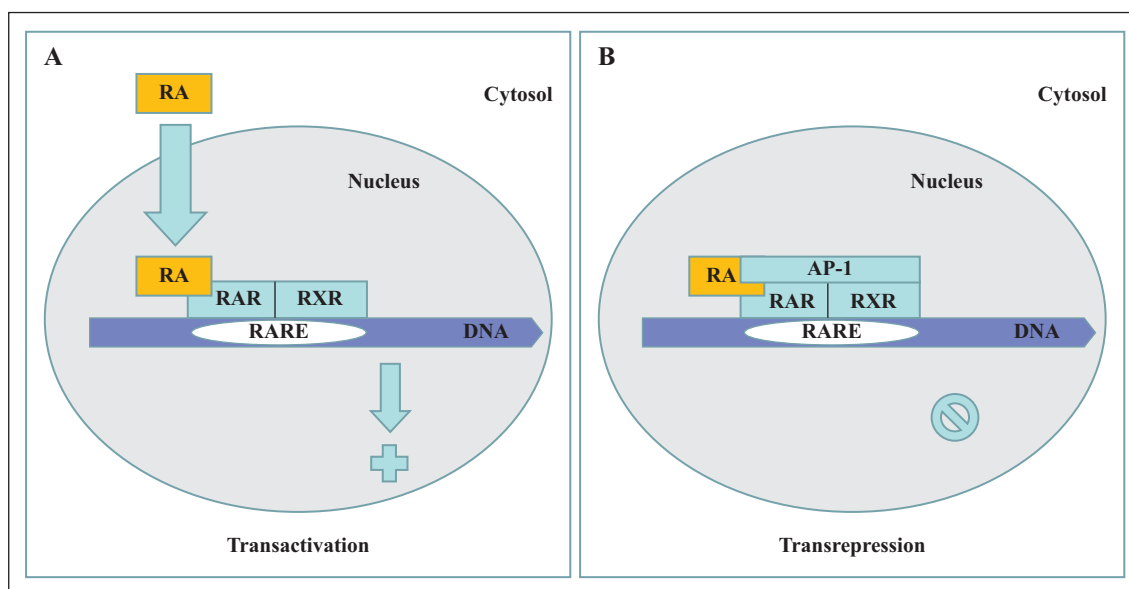


Figure 3. Retinoid receptor-dependent gene regulation. **A)** The intranuclear binding of all-*trans* retinoic acid (RA) to RAR results in the formation of an activated heterodimer complex (shown here as RAR/RXR). By binding to the promoter area of the so called retinoid acid response element (RARE), the activated complex stimulates gene transcription of the target gene (**A**, transactivation). **B)** Although there are further proteins involved, the interaction between the retinoid receptors and the transrepressor AP-1 is illustrated as direct for simplification. The newly formed protein complex inhibits transcription of the target gene. (**B**, transrepression).

Table 1. Systemic retinoid therapy.

Vitamin A derivative	Receptor target	Indication
Isotretinoin (13- <i>cis</i> retinoic acid)	RAR agonist	Severe acne Rosacea (e.g. phymatous, granuloma, fulminant, steroid-induced; Morbihan disease) Pityriasis rubra pilaris
Alitretinoin (9- <i>cis</i> retinoic acid)	RAR agonist and RXR agonist	Severe chronic hand-eczema (therapy-refractory under potent topical steroids) Pityriasis rubra pilaris Darier's disease
Acitretin (9-(4-Methoxy-2,3,6-trimethylphenyl)-3,7-dimethylnona-2,4,6,8-tetraenol acid)	RAR agonist	Severe therapy-resistant keratinization disorders Psoriasis (e.g. pustular, palmoplantar, erythrodermic) Hyperkeratosis palmoplantaris Pityriasis rubra pilaris Darier's disease Ichthyosis Lichen ruber Chemoprevention of NMSC
Bexarotene (4-[1-(3,5,5,8,8-Pentamethyltetralin-2-yl)ethenyl]-benzoic acid)	RXR agonist	Cutaneous T-Cell Lymphoma CD30 ⁺ -lymphoproliferative diseases with multifocal lesions

Table 2. Topical retinoid therapy.

Vitamin A derivative	Receptor target	Indication
Tretinoin (all- <i>trans</i> retinoic acid)	RAR agonist	Acne (inflammatory and non-inflammatory) Photoaging Postinflammatory hyperpigmentation Melasma
Isotretinoin (13- <i>cis</i> retinoic acid)	RAR agonist	Acne (inflammatory and non-inflammatory)
Adapalene (6-[3-(1-Adamantyl)-4-methoxyphenyl]-naphthalin-2-carbon acid)	RAR agonist	Acne (inflammatory and non-inflammatory)
Tazarotene (6-[(3,4-Dihydro-4,4-dimethyl-2H-1-benzothiopyran-6-yl)ethynyl]-3-pyridinecarboxylic acid ethyl ester)	RAR agonist	Psoriasis vulgaris
Alitretinoin (9- <i>cis</i> retinoic acid)	RAR agonist and RXR agonist	Kaposi's sarcoma
Bexarotene (4-[1-(3,5,5,8,8-Pentamethyltetralin-2-yl)ethenyl]-benzoic acid)	RXR agonist	Cutaneous T-cell lymphoma (stage IA-IB)

Non-aromatic retinoids (1st generation)

Isotretinoin

Systemic use

Isotretinoin plays an important role for the treatment of acne, since it shows an excellent efficacy against severe acne. A single therapeutic course of isotretinoin can permanently improve acne. This drug decreases sebum production in sebaceous gland cells, normalises follicular keratinisation and reduces the microbiological colonisation of the commensal bacterium *Propionibacterium acnes* and the associated inflammation [9].

An interesting potential anti-inflammatory mechanism of retinoids was described by Modlin *et al.* for tretinoin [17] and by Despenza *et al.* for isotretinoin [18]. The latter described that isotretinoin normalises an exaggerated immune response to *Propionibacterium acnes*. This response, mediated by toll-like-receptor 2 (TLR2), is increased in acne patients due to high expression of TLR2.

Isotretinoin reduces TLR2 expression in antigen-presenting cells and also decreases the inflammatory reaction after contact with the bacteria for up to six months after the end of therapy [18].

In the treatment of rosacea, isotretinoin led to a significant reduction of erythema, papules, and pustules, as well as decreased hypertrophy of connective tissue and sebaceous glands in several studies [19, 20]. Off-label use of low dose isotretinoin (0.15–0.3 mg/kg bw daily) showed high efficacy and was well tolerated. Isotretinoin is specifically indicated for certain rosacea subtypes such as phymatous, granulomatous, steroid-induced rosacea or rosacea fulminans, as well as in Morbihan disease [21, 22].

Topical use of isotretinoin and other topical retinoids (tretinoin, adapalene) in acne therapy

Topical retinoids have been successfully used in the treatment of acne for over 50 years. Tretinoin and isotretinoin are used as first-line compounds and for the long term treatment of inflammatory and non-inflammatory acne [8]. In addi-

tion, tretinoin is available for the treatment of photoaging [9] and to accelerate the skin healing process, for example after aesthetic interventions [15]. Tretinoin has been shown to significantly brighten up senile lentiginos and improve the clinical appearance of the skin [23]. Furthermore, there is evidence that tretinoin shows efficacy in the treatment of numerous pigmentary abnormalities such as postinflammatory hyperpigmentation or melasma [24, 25]. In contrast to the classical retinoids, adapalene is a derivative of naphthoic acid with retinoid-like features. By combining a retinoid with an NSAID-like structure, an increased anti-inflammatory effect was expected. Adapalene has comedolytic, antiproliferative, and anti-inflammatory characteristics [26]. Numerous clinical trials have compared adapalene 0.1% gel with tretinoin and isotretinoin 0.05% gel in the management of acne vulgaris and concluded that adapalene exhibits comparable efficacy with lower potential for irritation and faster onset of effects [27, 28]. Another benefit of adapalene in comparison to tretinoin and isotretinoin is its higher photostability and more stable chemical structure.

Topical retinoid therapy is recommended for the treatment of comedonal acne and moderate acne papulopustulosa, as well as of moderately severe and severe acne, combined with benzoyl peroxide, azelaic acid, topical or systemic antibiotics and hormonal systemic antiandrogens for women. Because of the comedolytic and anticomedone effect of adapalene and its confirmed anti-inflammatory effects and good tolerability, the recent European guideline for acne vulgaris treatment recommends selecting adapalene over the classical retinoids tretinoin and isotretinoin [29].

In addition, adapalene 0.1% gel is used in the treatment of patients with papulopustular rosacea and has revealed significantly higher effects concerning the reduction of inflammatory lesions than metronidazol 0.75% gel in a small study. However, there was no difference in the scores of erythema and telangiectasia [30].

Alitretinoin

Systemic use

After characterisation of the RXR receptor in pharmacologic design studies, alitretinoin proved to be the ideal ligand for this nuclear receptor [31]. It is both an RAR and RXR agonist. The BACH study, which represents the largest, double-blinded, randomised, placebo-controlled multicenter trial (RCT) for chronic hand-eczema, including over 1000 patients, showed that orally administered alitretinoin is effective for severe, therapy refractory hand-eczema [32]. Responses, defined as clear or almost clear hands, were achieved in nearly every second participant under daily treatment with 30 mg alitretinoin for 12–24 weeks. In 2008, this led to drug approval for this indication. Recently, we and others showed that alitretinoin is effective against pityriasis rubra pilaris [33, 34]. Further pilot studies, retrospective analysis or case reports showed a positive response to alitretinoin in Darier's disease [35, 36], palmoplantar pustular psoriasis [37], lichen planus [38–40], alopecia areata [41], or cutaneous t-cell lymphoma [42, 43]. Variable effects of alitretinoin were observed in congenital ichthyosis [44].

Topical use

Alitretinoin 0.1% gel is indicated for the treatment of cutaneous lesions in Kaposi's sarcoma. In an RCT, nearly half of the patients showed a positive response to topical application of alitretinoin [45].

In addition, topical alitretinoin was studied for the treatment of photodamaged skin. A small pilot study showed improvement of benign and precancerous lesions, such as seborrheic keratoses or actinic keratoses [46]. However, larger blinded controlled trials are needed to draw further conclusions regarding a therapeutic benefit.

Monoaromatic retinoids (2nd generation)

Acitretin

Second generation retinoids have been used for the treatment of psoriasis since the 1970s. During the 1980s, etretinate was only rarely used due to the associated side effects and the adverse pharmacokinetics (long half-life, high lipophilicity and, therefore, long teratogenic potential even after the end of therapy). Acitretin is the most important metabolite of etretinate and has even better pharmacokinetic characteristics at a comparable efficacy profile. For this reason, only acitretin is available as a systemic retinoid in most European countries and has been so since 1988. Acitretin shows strong effects in pustular psoriasis and erythrodermic psoriasis. Additionally, in an open study, low-dose acitretin was applied (0.2–0.3 mg/kg bw daily) to patients with isolated nail-psoriasis for six months, and it showed good results, with a response rate of over 50% [47]. However, compared to other conventional systemic treatments, acitretin is not suggested as a first choice for monotherapy in psoriasis vulgaris [48].

Acitretin provides a therapeutic option for lichen ruber planus, Darier's disease, pityriasis rubra pilaris, and ichthyosis [49].

Polyaromatic retinoids (3rd generation)

Bexarotene

Systemic use

Bexarotene is the first retinoid that binds selectively to RXR receptors and, therefore, it is sometimes referred to as 'rexinoid'. Oral bexarotene is most often used as either monotherapy or adjunctive therapy in the treatment of cutaneous T-cell lymphoma (CTCL) [50]. It is effectively used in the treatment of mycosis fungoides and Sézary syndrome in combination with PUVA or extracorporeal photopheresis [51].

Oral bexarotene is also recommended as a second-line therapy for CD30-positive lymphoproliferative diseases with multifocal lesions [51]. Due to the frequent side-effects, such as thyroid gland dysfunction and adipose tissue metabolism disorders, the early use of preventive therapy with thyroid-hormones and hypolipidemic drugs and routine blood tests are recommended [52].

Topical use

In clinical trials, bexarotene gel was effective for the topical treatment of cutaneous lesions in patients with early stage CTCL who had refractory or persistent disease following other therapies or who could not tolerate other therapies. It was approved by the US Food and Drug Administration in 2000 as a skin-directed therapy in the treatment of stage IA–IB CTCL [50]. In phase I, II, and III clinical trials of CTCL stage IA–IIA, the overall response rate of bexarotene 1% gel ranged from 44 to 63% [53, 54]. In open-label studies, topical bexarotene application also showed useful therapeutic activity in chronic severe hand-eczema [55] and mild-to-moderate plaque psoriasis [56]. In combination with narrowband UVB phototherapy, bexarotene gel was significantly more effective for the treatment of moderate-to-severe psoriasis vulgaris than narrowband UVB phototherapy alone [57]. A clinical benefit was also observed for alopecia areata in a phase I/II trial [58].

Tazarotene

Tazarotene is the first topical retinoid developed for the treatment of psoriasis. As a prodrug, tazarotene is metabolised in the skin to its active form (tazarotenic acid). In the topical treatment of psoriasis vulgaris, good results have been achieved with tazarotene 0.1% gel in mono- or combination therapy [8].

A meta-analysis by Mason *et al.* [59] revealed that tazarotene as monotherapy has a comparable efficacy to the vitamin-D-analog calcipotriol. Due to skin irritations, tazarotene is often combined with topical corticosteroids. In addition, tazarotene has been shown to improve onycholysis with or without occlusive treatment for 12–24 weeks [60–62].

Chemoprevention of malignant skin lesions

In the 1980s, it was found that retinoids are effective against precancerous skin lesions, such as actinic keratoses [63]. A few years later, a chemopreventive effect of systemic retinoids on the risk of skin cancer was observed in patients with xeroderma pigmentosum (isotretinoin) [64] and in kidney transplant patients (etretinate) [65].

Although systemic retinoids are widely used in organ transplant patients, only a few RCTs that systematically investigated retinoids in prophylaxis of non-melanocytic cutaneous neoplasia (NMSC) have been performed.

Topical retinoids in chemoprevention

Current data on the chemopreventive effect of topical retinoids are not conclusive [66, 67]. Recently, a wide-ranged RCT was published, including over 1100 non-immunosuppressed participants with several basal cell carcinomas or squamous cell carcinomas in their personal history as risk factors [68]. Topical tretinoin was proven to be ineffective in reducing the appearance of new NMSC or pre-stages.

Systemic retinoids in chemoprevention

There are several publications describing investigations of retinoids (mostly acitretin) as preventive agents for skin

cancer in immunosuppressed organ transplant recipients. Three RCTs were summarized in a systematic review by Chen *et al.*, who described a moderate reduction of NMSC [69]. The prophylactic treatment with retinoids seemed to be most effective in the prevention of squamous cell carcinomas [70]. In immunocompetent high risk patients with multiple NMSC in their personal history, there was no statistically significant benefit observed. Furthermore, a reduction of NMSC incidence during a two year treatment with acitretin was observed but this reduction was not significant, maybe due to low statistical power [71]. There was a high incidence of adverse effects, which appeared dose-related and after long-term treatment, and led to numerous withdrawals [69, 72, 73]. Appropriate selection of patients (e.g. immunosuppressed patients with numerous squamous cell carcinomas) may improve the risk-benefit ratio [49]. It is important to mention that the preventive effect of retinoids persists only during the treatment interval. After completion, recurrence of NMSC was observed [72]. Due to the rebound effect, retinoids should be seen as long term components in the management of skin cancer in organ transplanted patients [49]. Therefore, therapy with systemic retinoids requires both careful monitoring and interdisciplinary treatment management between the attending dermatologists and transplant specialists. Valid randomized studies are desirable and necessary for the development of guidelines for dosage and adverse event management.

Side effect profile

The acute toxicity of retinoids is comparable to vitamin A intoxication. The adverse effects of therapeutically used systemic retinoids are similar. Vitamin A derivatives play a crucial role in embryonic development, as demonstrated by the teratogenic effect of either an excess or a deficiency of vitamin A. Systemic retinoids are highly teratogenic especially early in pregnancy. Fetal deformities by retinoid administration include central nervous system malformations, craniofacial dysmorphisms, heart defects and defects of the thymic or parathyroid gland [74]. Teaching effective contraception to women of child-bearing age, even after the end of therapy, is very important, as are periodical pregnancy tests and prohibition for blood donation.

There is evidence that retinoids, such as bexarotene and acitretin, decrease the efficacy of oral contraceptives, especially progesterone-only compounds like the mini-pill, by inducing CYP450 (e.g. CYP3A4). Therefore, additional contraception using barrier-methods should be used. Retinoid levels can be elevated for months to years depending on the compound used, due to the bioavailability and storage in adipose tissue as fat-soluble derivatives of vitamin A. The highly lipophilic etretinate has a very long half-life and may be detected in the body two years after the end of therapy [8]. This is also relevant for acitretin. In particular, there is evidence that acitretin is metabolised to etretinate by the consumption of alcohol during acitretin treatment [75]. For this reason, women with childbearing potential should avoid the consumption of alcohol until two months after the end of therapy. Effective contraception and blood donation prohibition are recommended during

the two years after the end of acitretin treatment. During systemic use of alitretinoin, isotretinoin and bexarotene, contraception should be continued for at least one month after the end of therapy.

Percutaneous absorption of topically applied retinoids is minimal [76]. Nevertheless, there are single case histories reporting characteristic retinoid teratogenic damage, which have been shown in animal experiments. Therefore, it is essential to avoid the use of retinoids in pregnant women or women trying to conceive [77]. Other major side-effects from the systemic use of retinoids are mucocutaneous xerosis, conjunctivitis, loss of hair and alteration of laboratory values, such as an elevation of transaminases and triglyceride levels. Hence, periodic monitoring of laboratory values is necessary during systemic retinoid treatment. Elevated triglycerides constitute a contraindication. In addition, headache can appear and cause symptoms of pseudotumor cerebri. Simultaneous application of tetracyclines should be avoided since both drugs show synergistic effects in the development of pseudotumor cerebri. Other undesirable effects are myalgia and arthralgia. Additionally, an association between long-term retinoid treatment and the appearance of disorders in bone metabolism and development of extraskelatal ossifications, like tendon calcification, spinal hyperostosis, and osteoporosis, has been reported [78]. These side effects should be considered, especially in high-performance athletes. Due to retinoid-induced increased light sensitivity, the patient should be informed about the importance of UV-protection.

There are different opinions about the possible relationship between retinoids (especially isotretinoin in the treatment of acne) and the incidence of depression and suicidality. In contrast to several case reports and uncontrolled clinical studies, epidemiologic investigations could not prove a correlation. The fact that acne itself represents a risk for depression should also be considered [9].

Although the spectrum of side effects of the different pharmacological retinoids is similar, the incidence of appearance in the group of retinoids differs, which is probably caused by different binding affinity to the RAR and RXR receptor subtypes. For example, bexarotene, a selective RXR agonist, often causes hypothyroidism by reversible RXR-dependent suppression of TSH gene expression [79]. In contrast, this occurs less during treatment with alitretinoin, which represents both a RAR and RXR agonist. The occurrence of this side-effect is even more unlikely during therapy with a simple RAR agonist.

All topically applied retinoids may induce erythema, exfoliation, and burning. These effects subside gradually and can be decreased by using greasy ointments. Light sensitivity and sunburn may be the result of epidermal rarefaction [9]. In conclusion, retinoids are among the most efficacious drugs used in the treatment of dermatological disorders and have a wide range of biological effects. Thorough knowledge about the side effects and comprehensive information for patients are essential for the safe use of retinoids. ■

Disclosure. Acknowledgements: With kind permission of Springer Science+Business Media. Financial support: none. Conflict of interest: none.

References

1. Amann PM, Eichmuller SB, Schmidt J, Bazhin AV. Regulation of gene expression by retinoids. *Curr Med Chem* 2011; 18: 1405-12.
2. Baron JM, Skazik C, Merk HF. [Retinoids and their metabolism: new therapeutic approaches?]. *Hautarzt* 2008; 59: 745-6.
3. Baron JM, Merk HF, Bickers DR. Recent studies on the pharmacokinetics and metabolism of retinoids in the skin. In: Vahlquist A, Duvic M, editors. *Retinoids and carotenoids in Dermatology*. London: Taylor & Francis, 2007, p. 67-75.
4. Stuetgen G. [On the local therapy of keratosis with vitamin A acid]. *Dermatologica* 1962; 124: 65-80.
5. Kligman AM, Fulton JE Jr., Plewig G. Topical vitamin A acid in acne vulgaris. *Arch Dermatol* 1969; 99: 469-76.
6. Orfanos CE, Mahrle G, Goerz G, et al. Laboratory investigations in patients with generalized psoriasis under oral retinoid treatment. A multicenter study of computerized data. *Dermatologica* 1979; 159: 62-70.
7. Amann PM, Merk HF, Baron JM. [Retinoids in dermatopharmacology]. *Hautarzt* 2014; 65: 98-105.
8. Baron JM. Retinoid Pharmacology. In: Krieg T, Bickers DR, Miyachi Y, editors. *Therapy of Skin Diseases*. Berlin Heidelberg: Springer-Verlag, 2010, p. 77-85.
9. Fox LP, Merk HF, Bickers DR. Dermatopharmakologie. In: Brunton LL, Lazo JS, Parker KL, editors. *Goodman & Gilman's - Pharmakologische Grundlagen der Arzneimitteltherapie*. Berlin: ABW Wissenschaftsverlag GmbH, 2006, p. 1-73.
10. Fisher GJ, Voorhees JJ. Molecular mechanisms of retinoid actions in skin. *FASEB J* 1996; 10: 1002-13.
11. Dilworth FJ, Chambon P. Nuclear receptors coordinate the activities of chromatin remodeling complexes and coactivators to facilitate initiation of transcription. *Oncogene* 2001; 20: 3047-54.
12. Mongan NP, Gudas LJ. Diverse actions of retinoid receptors in cancer prevention and treatment. *Differentiation* 2007; 75: 853-70.
13. MacKay D, Miller AL. Nutritional support for wound healing. *Altern Med Rev* 2003; 8: 359-77.
14. Ndiaye MA, Nihal M, Wood GS, Ahmad N. Skin, reactive oxygen species, and circadian clocks. *Antioxid Redox Signal* 2014; 20: 2982-96.
15. Hubbard BA, Unger JG, Rohrich RJ. Reversal of skin aging with topical retinoids. *Plast Reconstr Surg* 2014; 133: 481e-90e.
16. Baron JM, Heise R, Blaner WS, et al. Retinoic acid and its 4-oxo metabolites are functionally active in human skin cells in vitro. *J Invest Dermatol* 2005; 125: 143-53.
17. Liu PT, Krutzik SR, Kim J, Modlin RL. Cutting edge: all-trans retinoic acid down-regulates TLR2 expression and function. *J Immunol* 2005; 174: 2467-70.
18. Dispenza MC, Wolpert EB, Gilliland KL, et al. Systemic isotretinoin therapy normalizes exaggerated TLR-2-mediated innate immune responses in acne patients. *J Invest Dermatol* 2012; 132: 2198-205.
19. Erdogan FG, Yurtsever P, Aksoy D, Eskioglu F. Efficacy of low-dose isotretinoin in patients with treatment-resistant rosacea. *Arch Dermatol* 1998; 134: 884-5.
20. Gollnick H, Blume-Peytavi U, Szabo EL, et al. Systemic isotretinoin in the treatment of rosacea - doxycycline- and placebo-controlled, randomized clinical study. *J Dtsch Dermatol Ges* 2010; 8: 505-15.
21. Schaller M, Belge K. [Systemic therapy of rosacea]. *Hautarzt* 2013; 64: 500-5.
22. Reinholz M, Tietze JK, Kilian K, et al. Rosacea - s1 guideline. *J Dtsch Dermatol Ges* 2013; 11: 768-80.
23. Rafal ES, Griffiths CE, Ditre CM, et al. Topical tretinoin (retinoic acid) treatment for liver spots associated with photodamage. *N Engl J Med* 1992; 326: 368-74.
24. Bulengo-Ransby SM, Griffiths CE, Kimbrough-Green CK, et al. Topical tretinoin (retinoic acid) therapy for hyperpigmented lesions caused by inflammation of the skin in black patients. *N Engl J Med* 1993; 328: 1438-43.

- 25.** Kang HY, Valerio L, Bahadoran P, Ortonne JP. The role of topical retinoids in the treatment of pigmentary disorders: an evidence-based review. *Am J Clin Dermatol* 2009; 10: 251-60.
- 26.** Bikowski JB. Mechanisms of the comedolytic and anti-inflammatory properties of topical retinoids. *J Drugs Dermatol* 2005; 4: 41-7.
- 27.** Ioannides D, Rigopoulos D, Katsambas A. Topical adapalene gel 0.1% vs. isotretinoin gel 0.05% in the treatment of acne vulgaris: a randomized open-label clinical trial. *Br J Dermatol* 2002; 147: 523-7.
- 28.** Cunliffe WJ, Poncet M, Loesche C, Verschoore M. A comparison of the efficacy and tolerability of adapalene 0.1% gel versus tretinoin 0.025% gel in patients with acne vulgaris: a meta-analysis of five randomized trials. *Br J Dermatol* 1998; 139(Suppl 52): 48-56.
- 29.** Nast A, Dreno B, Bettoli V, et al. European evidence-based (S3) guidelines for the treatment of acne. *J Eur Acad Dermatol Venereol* 2012; 26(Suppl 1): 1-29.
- 30.** Altinyazar HC, Koca R, Tekin NS, Esturk E. Adapalene vs. metronidazole gel for the treatment of rosacea. *Int J Dermatol* 2005; 44: 252-5.
- 31.** Heyman RA, Mangelsdorf DJ, Dyck JA, et al. 9-cis retinoic acid is a high affinity ligand for the retinoid X receptor. *Cell* 1992; 68: 397-406.
- 32.** Ruzicka T, Lynde CW, Jemec GB, et al. Efficacy and safety of oral alitretinoin (9-cis retinoic acid) in patients with severe chronic hand eczema refractory to topical corticosteroids: results of a randomized, double-blind, placebo-controlled, multicentre trial. *Br J Dermatol* 2008; 158: 808-17.
- 33.** Pampin A, Gomez-de la Fuente E, Caro Gutierrez MD, Lopez-Estebarez JL. Successful treatment of atypical adult pityriasis rubra pilaris with oral alitretinoin. *J Am Acad Dermatol* 2013; 69: e105-6.
- 34.** Amann P M, Susic M, Gluder F, Berger H, Krapf W, Loffler H. Alitretinoin (9-cis retinoic acid) is Effective Against Pityriasis Rubra Pilaris: A Retrospective Clinical Study. *Acta Derm Venereol* 2014 Jul 4. doi: 10.2340/00015555-1928. [Epub ahead of print].
- 35.** Barnstedt SE. [Successful treatment of Darier disease with oral alitretinoin]. *Hautarzt* 2012; 63: 139-41.
- 36.** Letule V, Herzinger T, Ruzicka T, Molin S. Treatment of Darier disease with oral alitretinoin. *Clin Exp Dermatol* 2013; 38: 523-5.
- 37.** Irla N, Navarini AA, Yawalkar N. Alitretinoin abrogates innate inflammation in palmoplantar pustular psoriasis. *Br J Dermatol* 2012; 167: 1170-4.
- 38.** Molin S, Ruzicka T. Oral alitretinoin in lichen planus: two case reports. *Acta Derm Venereol* 2010; 90: 523-4.
- 39.** Brehmer F, Haenssle HA, Schon MP, Emmert S. Response of recalcitrant lichen planus to alitretinoin in 3 patients. *J Am Acad Dermatol* 2011; 65: e58-60.
- 40.** Alsenaid A, Eder I, Ruzicka T, Braun-Falco M, Wolf R. Successful treatment of nail lichen planus with alitretinoin: report of 2 cases and review of the literature. *Dermatology* 2014; 229: 293-6.
- 41.** Kolesnik M, Gollnick H, Bonnekoh B. Complete remission of alopecia areata under treatment of chronic hand eczema with alitretinoin. *Eur J Dermatol* 2013; 23: 110-1.
- 42.** Molin S, Ruzicka T. Possible benefit of oral alitretinoin in T-lymphoproliferative diseases: a report of two patients with palmoplantar hyperkeratotic-rhagadiform skin changes and mycosis fungoides or Sezary syndrome. *Br J Dermatol* 2009; 161: 1420-2.
- 43.** Kapsler C, Herzinger T, Ruzicka T, Flaig M, Molin S. Treatment of cutaneous T-cell lymphoma with oral alitretinoin. *J Eur Acad Dermatol Venereol* 2014.
- 44.** Ganemo A, Sommerlund M, Vahlquist A. Oral alitretinoin in congenital ichthyosis: a pilot study shows variable effects and a risk of central hypothyroidism. *Acta Derm Venereol* 2012; 92: 256-7.
- 45.** Walmsley S, Northfelt DW, Melosky B, Conant M, Friedman-Kien AE, Wagner B. Treatment of AIDS-related cutaneous Kaposi's sarcoma with topical alitretinoin (9-cis-retinoic acid) gel. Panretin Gel North American Study Group. *J Acquir Immune Defic Syndr* 1999; 22: 235-46.
- 46.** Baumann L, Vujevich J, Halem M, et al. Open-label pilot study of alitretinoin gel 0.1% in the treatment of photoaging. *Cutis* 2005; 76: 69-73.
- 47.** Tosti A, Ricotti C, Romanelli P, Cameli N, Piraccini BM. Evaluation of the efficacy of acitretin therapy for nail psoriasis. *Arch Dermatol* 2009; 145: 269-71.
- 48.** Pathirana D, Ormerod AD, Saiag P, et al. European S3-guidelines on the systemic treatment of psoriasis vulgaris. *J Eur Acad Dermatol Venereol* 2009; 23(Suppl 2): 1-70.
- 49.** Ormerod AD, Campalani E, Goodfield MJ. British Association of Dermatologists guidelines on the efficacy and use of acitretin in dermatology. *Br J Dermatol* 2010; 162: 952-63.
- 50.** Schadt CR. Topical and oral bexarotene. *Dermatol Ther* 2013; 26: 400-3.
- 51.** Stadler R, Assaf C, Klemke CD, et al. Brief S2k guidelines-Cutaneous lymphomas. *J Dtsch Dermatol Ges* 2013; 11(Suppl 3), 19-28, 0-30.
- 52.** Scarisbrick JJ, Morris S, Azurdia R, et al. U.K. consensus statement on safe clinical prescribing of bexarotene for patients with cutaneous T-cell lymphoma. *Br J Dermatol* 2013; 168: 192-200.
- 53.** Breneman D, Duvic M, Kuzel T, Yocum R, Truglia J, Stevens VJ. Phase 1 and 2 trial of bexarotene gel for skin-directed treatment of patients with cutaneous T-cell lymphoma. *Arch Dermatol* 2002; 138: 325-32.
- 54.** Heald P, Mehlmauer M, Martin AG, Crowley CA, Yocum RC, Reich SD. Topical bexarotene therapy for patients with refractory or persistent early-stage cutaneous T-cell lymphoma: results of the phase III clinical trial. *J Am Acad Dermatol* 2003; 49: 801-15.
- 55.** Hanifin JM, Stevens V, Sheth P, Breneman D. Novel treatment of chronic severe hand dermatitis with bexarotene gel. *Br J Dermatol* 2004; 150: 545-53.
- 56.** Breneman D, Sheth P, Berger V, Naini V, Stevens V. Phase II clinical trial of bexarotene gel 1% in psoriasis. *J Drugs Dermatol* 2007; 6: 501-6.
- 57.** Magliocco MA, Pandya K, Dombrovskiy V, Christiansen L, Wong Y, Gottlieb AB. A randomized, double-blind, vehicle-controlled, bilateral comparison trial of bexarotene gel 1% versus vehicle gel in combination with narrowband UVB phototherapy for moderate to severe psoriasis vulgaris. *J Am Acad Dermatol* 2006; 54: 115-8.
- 58.** Talpur R, Vu J, Bassett R, Stevens V, Duvic M. Phase I/II randomized bilateral half-head comparison of topical bexarotene 1% gel for alopecia areata. *J Am Acad Dermatol* 2009; 61: 592 e1-9.
- 59.** Mason J, Mason AR, Cork MJ. Topical preparations for the treatment of psoriasis: a systematic review. *Br J Dermatol* 2002; 146: 351-64.
- 60.** Scher RK, Stiller M, Zhu YI. Tazarotene 0.1% gel in the treatment of fingernail psoriasis: a double-blind, randomized, vehicle-controlled study. *Cutis* 2001; 68: 355-8.
- 61.** Bianchi L, Soda R, Diluvio L, Chimenti S. Tazarotene 0.1% gel for psoriasis of the fingernails and toenails: an open, prospective study. *Br J Dermatol* 2003; 149: 207-9.
- 62.** Rigopoulos D, Gregoriou S, Katsambas A. Treatment of psoriatic nails with tazarotene cream 0.1% vs. clobetasol propionate 0.05% cream: a double-blind study. *Acta Derm Venereol* 2007; 87: 167-8.
- 63.** Moriarty M, Dunn J, Darragh A, Lambe R, Brick I. Etretinate in treatment of actinic keratosis. A double-blind crossover study. *Lancet* 1982; 1: 364-5.
- 64.** Kraemer KH, DiGiovanna JJ, Moshell AN, Tarone RE, Peck GL. Prevention of skin cancer in xeroderma pigmentosum with the use of oral isotretinoin. *N Engl J Med* 1988; 318: 1633-7.
- 65.** Shuttleworth D, Marks R, Griffin PJ, Salaman JR. Treatment of cutaneous neoplasia with etretinate in renal transplant recipients. *Q J Med* 1988; 68: 717-25.
- 66.** Euvrard S, Verschoore M, Touraine JL, et al. Topical retinoids for warts and keratoses in transplant recipients. *Lancet* 1992; 340: 48-9.
- 67.** Wu PA, Stern RS. Topical tretinoin, another failure in the pursuit of practical chemoprevention for non-melanoma skin cancer. *J Invest Dermatol* 2012; 132: 1532-5.
- 68.** Weinstock MA, Bingham SF, DiGiovanna JJ, et al. Tretinoin and the prevention of keratinocyte carcinoma (Basal and squamous cell carcinoma of the skin): a veterans affairs randomized chemoprevention trial. *J Invest Dermatol* 2012; 132: 1583-90.
- 69.** Chen K, Craig JC, Shumack S. Oral retinoids for the prevention of skin cancers in solid organ transplant recipients: a systematic review of randomized controlled trials. *Br J Dermatol* 2005; 152: 518-23.
- 70.** Lens M, Medenica L. Systemic retinoids in chemoprevention of non-melanoma skin cancer. *Expert Opin Pharmacother* 2008; 9: 1363-74.

- 71.** Kadakia KC, Barton DL, Loprinzi CL, *et al.* Randomized controlled trial of acitretin versus placebo in patients at high-risk for basal cell or squamous cell carcinoma of the skin (North Central Cancer Treatment Group Study 969251). *Cancer* 2012; 118: 2128-37.
- 72.** Bavinck JN, Tieben LM, Van der Woude FJ, *et al.* Prevention of skin cancer and reduction of keratotic skin lesions during acitretin therapy in renal transplant recipients: a double-blind, placebo-controlled study. *J Clin Oncol* 1995; 13: 1933-8.
- 73.** George R, Weightman W, Russ GR, Bannister KM, Mathew TH. Acitretin for chemoprevention of non-melanoma skin cancers in renal transplant recipients. *Australas J Dermatol* 2002; 43: 269-73.
- 74.** Lammer EJ, Chen DT, Hoar RM, *et al.* Retinoic acid embryopathy. *N Engl J Med* 1985; 313: 837-41.
- 75.** Larsen FG, Jakobsen P, Knudsen J, Weismann K, Kragballe K, Nielsen-Kudsk F. Conversion of acitretin to etretinate in psoriatic patients is influenced by ethanol. *J Invest Dermatol* 1993; 100: 623-7.
- 76.** Nohynek GJ, Meuling WJ, Vaes WH, *et al.* Repeated topical treatment, in contrast to single oral doses, with Vitamin A-containing preparations does not affect plasma concentrations of retinol, retinyl esters or retinoic acids in female subjects of child-bearing age. *Toxicol Lett* 2006; 163: 65-76.
- 77.** Loureiro KD, Kao KK, Jones KL, *et al.* Minor malformations characteristic of the retinoic acid embryopathy and other birth outcomes in children of women exposed to topical tretinoin during early pregnancy. *Am J Med Genet A* 2005; 136: 117-21.
- 78.** DiGiovanna JJ. Retinoid chemoprevention in the high-risk patient. *J Am Acad Dermatol* 1998; 39: S82-5.
- 79.** Sherman SI. Etiology, diagnosis, and treatment recommendations for central hypothyroidism associated with bexarotene therapy for cutaneous T-cell lymphoma. *Clin Lymphoma* 2003; 3: 249-52.