

# Neonatal suppression-burst without epileptic seizures: expanding the electroclinical phenotype of STXBP1-related, early-onset encephalopathy

Massimo Mastrangelo<sup>1</sup>, Angela Peron<sup>2</sup>, Luigina Spaccini<sup>2</sup>, Francesca Novara<sup>3</sup>, Barbara Scelsa<sup>1</sup>, Paola Introvini<sup>4</sup>, Federico Raviglione<sup>1</sup>, Stefano Faiola<sup>5</sup>, Orsetta Zuffardi<sup>3,6</sup>

<sup>1</sup> Pediatric Neurology Unit, V Buzzi Children's Hospital, ICP, Milan

<sup>2</sup> Clinical Genetics Service, V Buzzi Children's Hospital, ICP, Milan

<sup>3</sup> Department of Molecular Medicine, University of Pavia, Pavia

<sup>4</sup> Division of Neonatology, V Buzzi Children's Hospital, ICP, Milan

<sup>5</sup> Fetal Therapy Unit, Department of Obstetrics, V Buzzi Children's Hospital, ICP, Milan, Italy

<sup>6</sup> Foundation IRCCS Casimiro Mondino, Pavia, Italy

Received July 6, 2012; Accepted January 9, 2013

**ABSTRACT** – Early-onset epileptic encephalopathies (EOEEs) are characterised by epileptic seizures beginning in the first months of life, abnormal background EEG activity, and are associated with severe developmental delay and poor prognosis. Mutations and deletions in the *STXBP1* gene are associated with Ohtahara syndrome, also known as “early infantile epileptic encephalopathy”. We report an infant affected by EOEE with a 9q34.11 deletion that encompassed the genes *STXBP1* and *SPTAN1*. The infant presented with neonatal encephalopathy without epileptic seizures and an EEG pattern varying from highly discontinuous to suppression-burst. This was followed by West syndrome at 2 months with atypical hypsarrhythmia and spasms, easily controlled by therapy. Our findings suggest that molecular analysis of *STXBP1* should be considered for newborns affected by neonatal encephalopathy associated with a peculiar EEG pattern, even in the absence of neonatal epileptic seizures.

**Key words:** neonatal encephalopathy, *STXBP1*, *SPTAN1*, neonatal seizures, EEG pattern, hypsarrhythmia

Early-onset epileptic encephalopathy (EOEE) is a clinical condition characterised by epileptic seizures beginning in the first months of life, abnormal background EEG pattern, and is associated with severe developmental delay and poor prog-

nosis (Milh *et al.*, 2011). Besides many other, mostly acquired symptomatic, conditions, EOEE is comprised of two distinct epileptic syndromes: early myoclonic encephalopathy (EME) and early infantile epileptic encephalopathy (EIEE),

**Correspondence:**

Massimo Mastrangelo  
Neurologia Pediatrica  
Ospedale V Buzzi, AOICP  
Via Castelvetro 24  
20154 Milan, Italy  
<m.mastrangelo@icp.mi.it>

also known as Ohtahara syndrome (Aicardi and Ohtahara, 2002). A suppression-burst (SB) EEG pattern is a distinctive feature in both conditions and most EOEEs, and 75% of cases are reported to evolve into West syndrome (WS) (Deprez et al., 2009; Saitsu et al., 2008).

*STXBP1* is a gene encoding a component of the machinery involved in the fusion of secretory vesicles to the presynaptic membrane for the release of neurotransmitters. Mutations in this gene have been reported in patients with EIEE, but are also present in 10% of patients with EOEE who are not considered to have Ohtahara syndrome or WS, and rarely typical WS (Deprez et al, 2010). The clinical spectrum associated with *STXBP1* mutations has recently been expanded to include both types of epileptic manifestations and severe intellectual disability (ID) without epilepsy (Hamdan et al, 2011). Besides intragenic mutations, microdeletions involving the gene and the surrounding regions have also been reported (Saitsu et al., 2008; Deprez et al, 2010; Milh et al, 2011; Saitsu et al, 2012). Here, we report the electroclinical features of an infant with EOEE, with a 2.4 Mb deletion encompassing the *STXBP1* gene. The infant presented, in the neonatal period, with a distinct, highly discontinuous EEG pattern resembling SB, without epileptic seizures. A comparison between the infant's phenotype and that of other reported patients bearing an overlapping deletion is provided.

## Case study

Our female patient was the third child of unrelated healthy parents, with two older healthy sisters. Family history was unremarkable. The pregnancy was characterised by the presence of a small stomach and polyhydramnios at the 32nd gestational week (GW); prenatal karyotype analysis based on amniotic fluid revealed 46, XX. Oesophageal atresia was suspected, but not confirmed later. She was born at 38 GWs with normal delivery; Apgar score: 8-10, birth weight: 25th percentile, length at birth: 50th percentile, and head circumference (OFC): 10th percentile. At birth, she presented with hypotonia and poor spontaneous motricity; severe swallowing dysfunction and drooling resulted in gavage feeding.

Video-EEG recordings at 5 and 12 days of age showed a highly discontinuous pattern, characterised by SB with some variability between wakefulness and sleep (figure 1A, 1B). However, epileptic seizures were neither observed nor recorded in the neonatal period. These electroclinical findings were compatible with a condition of neonatal encephalopathy without epilepsy. At 2 months of age, WS with spasms, hypsarrhythmia, and further psychomotor regression started;

an isolated hypermotor seizure (figure 2A) preceded the onset of both isolated (figure 2B) and clustered spasms.

A rapid titration with vigabatrin (up to 80 mg/kg per day) led to both clinical and electrographic seizure control in less than 10 days. The EEG background activity improved and the hypsarrhythmia disappeared; however, bilateral abnormalities with isolated multifocal spikes and spike-and-slow-wave complexes persisted, in association with bilateral, high-voltage, theta and delta activity. Physiological sleep events were absent. During wakefulness, isolated non-epileptic jerks were present. The encephalopathic condition persisted. Vigabatrin was discontinued after eight months and seizures never recurred.

At 10 months of age, weight and height were in the tenth percentile and OFC below the third percentile. The patient presented with slightly narrow and up-slanting palpebral fissures, a wide mouth with down-turned corners, and hypoplasia of the depressor angularis oris muscle; she continuously brought her right hand to her mouth.

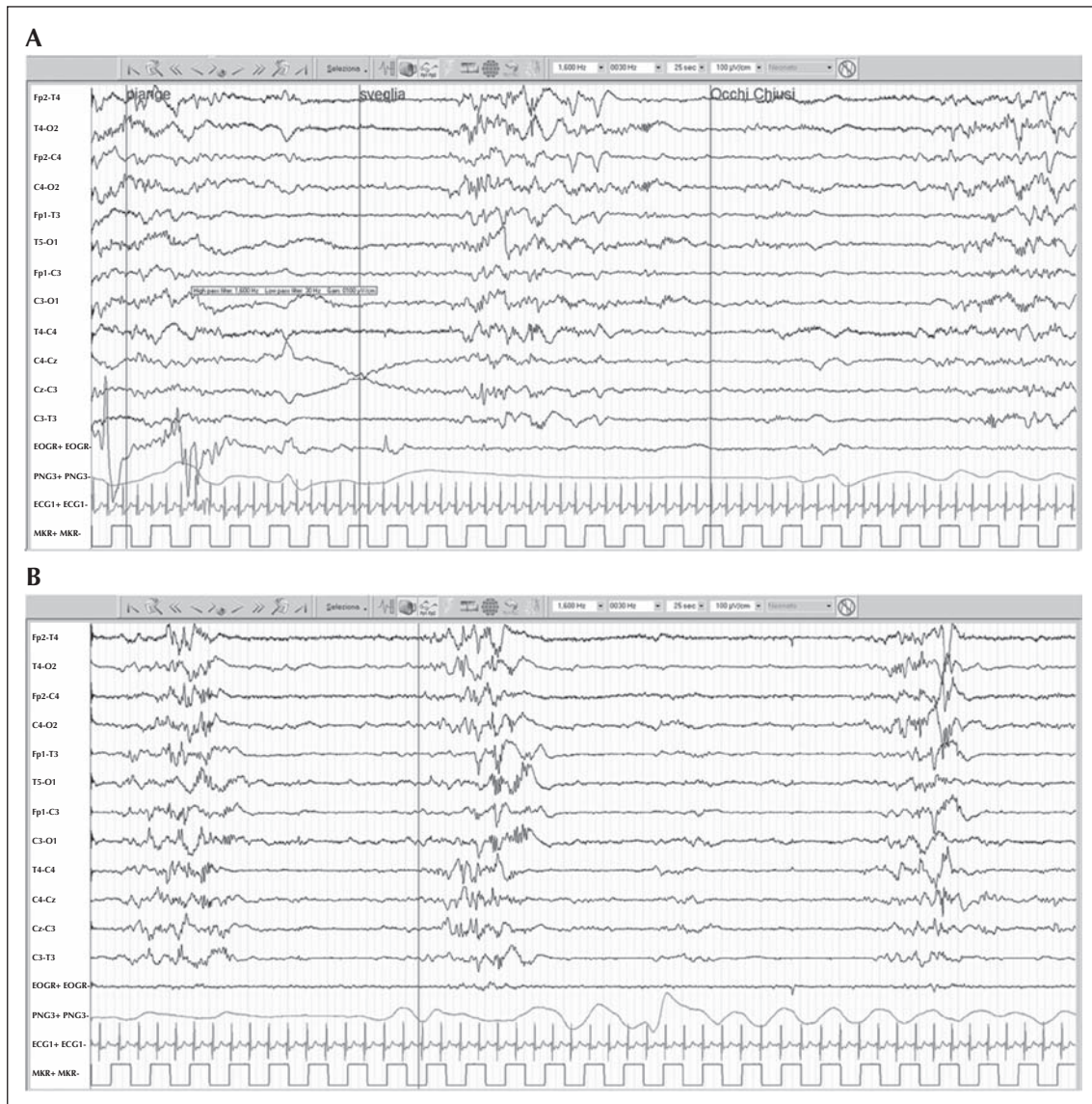
At the last examination (24 months of age), she was seizure-free although the non-epileptic jerky movements persisted; video-EEG showed a non-specific slowing-down of background activity with multifocal slow and fast activity. Head control and sitting position were acquired, language was absent, and severe intellectual impairment was evident. Hypertonia of the upper limbs with axial hypotonia and rotatory nystagmus was observed. The OFC was below the third percentile. The swallowing dysfunction improved and she was able to eat solid food. An ophthalmologic evaluation showed hypermetropia, astigmatism, strabismus, and initial cataracts. Brain MRI at 9 days and at 2 months of age showed a thin corpus callosum (figure 3).

## Laboratory analysis

Metabolic and genetic analyses were normal. An array-CGH performed at 10 months of age demonstrated a 9q34.11 deletion of 2.4 Mb (arr 9q34.11 [130,292,884 × 2,130,301,290-132,733,488 × 1,132,741,532 × 2] hg19) encompassing the *STXBP1* and *SPTAN1* genes. The genomic imbalance occurred *de novo*, as demonstrated by the Q-PCR performed on the proband and her parents, and originated from paternal meiosis, as evidenced by microsatellite analysis (D9S752 and D9S1795).

## Discussion

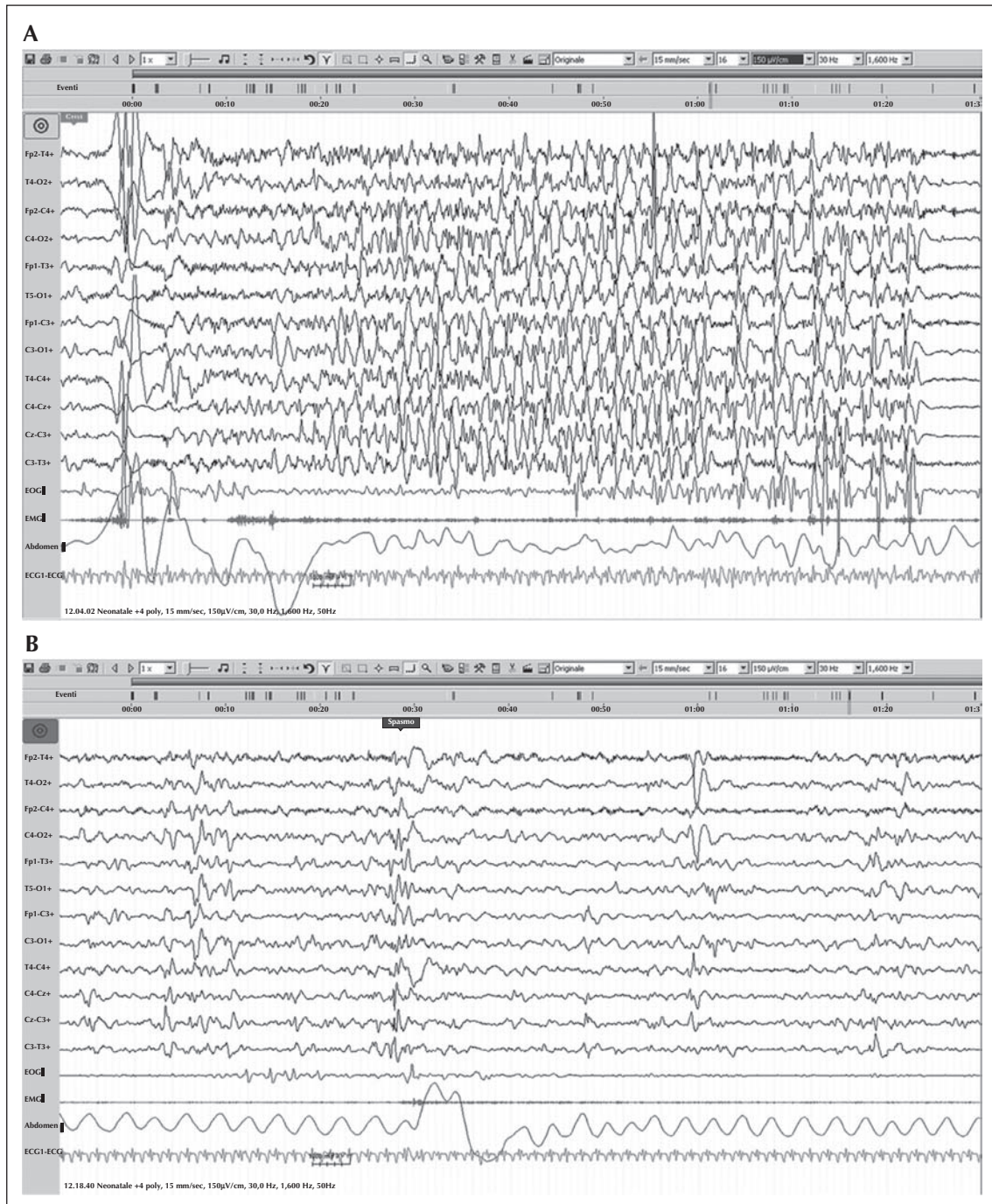
Early-onset epileptic seizures and an abnormal EEG background associated with moderate-to-profound



**Figure 1.** Neonatal and post-neonatal EEG. At 5 days: (A) highly discontinuous pattern during wakefulness; (B) moderately asynchronous SB-EEG pattern during sleep.

mental retardation are the electroclinical hallmarks of EOEEs. When persisting for more than two weeks in abnormal neonates without severe brain insults, the SB-EEG pattern is the specific EEG feature of EME and EIEE (Pavone *et al.*, 2012). The SB-EEG pattern should be differentiated from hypsarrhythmia (which is generally associated with WS and starts after the neonatal period) in which the chaotic electrical activity in wakefulness evolves with periodicity and becomes remarkable in sleep (Ohtahara *et al.*, 1976). However, the evolution from a highly discontinuous EEG pattern to SB and to hypsarrhythmia may be considered as a continuum (Milh *et al.*, 2011).

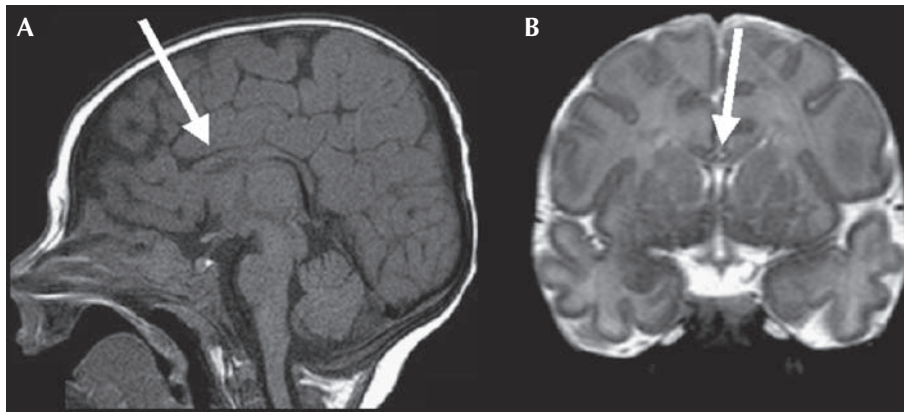
In patients without metabolic and structural brain anomalies, mutations in different genes are reported to be the cause of EOEEs (Giordano *et al.*, 2010; Saitu *et al.*, 2010a; Mignot *et al.*, 2011). So far, 35 patients with *STXBP1* mutations or deletions have been described, as well as four with mutations or deletions in *SPTAN1*. Among these patients, three cases presented with a deletion of different sizes encompassing both genes (Saitu *et al.*, 2008; Mignot *et al.*, 2011; Saitu *et al.*, 2012), overlapping the deletion identified in our patient (figure 4). The electroclinical features of these patients are listed in table 1. Concerning the other clinical features, all the patients with microdeletions involving




**Figure 2.** Neonatal and post-neonatal EEG. At 2 months: (A) hypermotor seizure characterised by eyes opening, stiffening, and slight clonic jerks of the bilateral upper limbs; (B) isolated subtle spasm 14 minutes later.

the entire *STXBP1* gene presented with profound psychomotor delay, ID, and microcephaly. Microcephaly is present in all patients with 9q deletion in this region, but not in those with *STXBP1* mutations or intragenic deletions, suggesting that microcephaly is not related to complete loss of *STXBP1*, but rather to another gene present in the deleted region. Further studies are

needed to better delineate the candidate genes which may influence this feature. Furthermore, a thin corpus callosum was present in all of the cited patients for whom brain MRI was available. In contrast with the case described by Saitsu *et al.* (2008), myelination in our patient appeared to be normal. It was not possible to identify a characteristic facial gestalt.



**Figure 3.** (A) Sagittal T1-weighted and (B) coronal T2-weighted MR images from a two-month postnatal study showing global thinning of the corpus callosum (arrows), more evident in the anterior part. No focal parenchymal lesions were detectable. Myelination was normal for age.



**Figure 4.** Representation of 9q33.3q34.1 genomic region. (A) All 9q33.3q34.1 deletions published so far, including that of our patient. (B) *STXBP1* intragenic deletions. The deletions corresponding to each case are represented by a coloured box.

Concerning the EEG pattern, with the exception of the patients with genomic deletions described in *table 1*, a peculiar SB-EEG pattern was also identified in patients with *STXBP1* mutations or intragenic deletions (Milh *et al.*, 2011; Saitsu *et al.*, 2012). Truncat-

ing mutations and intragenic *STXBP1* deletions have also been identified in six patients with EOE (Deprez *et al.*, 2010) with an SB-EEG pattern around the time of recording (all EEGs were re-examined at a later date).

**Table 1.** Genetic and electroclinical findings of cases with deletions encompassing both *STXBP1* and *SPTAN1*.

Cases	Saitou <i>et al.</i> , 2008 Patient 1*	Mignot <i>et al.</i> , 2011 Patient 3	Saitou <i>et al.</i> , 2012 Patient 2231	Present case
Deletion	9q33.3q34.11	9q33.3q34.11	9q33.3q34.1	9q34.11
Size (Mb)	2.0	3.14-3.30	2.85	2.4
Origin	<i>De novo</i>	<i>De novo</i>	<i>De novo</i>	<i>De novo</i>
Prenatal findings	NR	Normal	NR	Small stomach and polyhydramnios (32nd GW)
Epilepsy (age at onset)	Tonic seizures (45 days) Spasms (2 months) Generalised clonic seizures (29 months)	Spasms (6 months)	Spasms (1 month)	Spasms (2 months) preceded by a single hypermotor seizure
EEG	SB Hypsarrhythmia (3 months) Diffuse slow spike-and-wave discharges (29 months)	Disorganised background activity, multifocal spikes and burst of spikes and spike-waves (6 months) Slow wave in the frontal or occipital lobes (after 10 months) Infraclinical epileptic discharges (8 years)	SB (1 month)	Severely discontinuous pattern with SB (5 and 12 days) with no seizures Hypsarrhythmia (2 months) Non-specific slowing-down of background activity with multifocal slow and fast activity (24 months)
Non-epileptic movement disorders	Limb tremor	Limb dyskinesia Head and limb tremor	NR	Jerky movements
Brain MRI	Thin corpus callosum Cortical atrophy Diffuse hypomyelination at 12 months with catch-up completion by 4 years	Global atrophy	Thin corpus callosum Relatively small cerebellum	Thin corpus callosum
Time at last evaluation	29 months	10 years	19 months	24 months
ID	Profound	Severe	Profound	Severe
Additional clinical findings	Microcephaly Hypotonic quadriplegia Poor weight gain	Microcephaly Absent/hypoplastic nails Frequent stereotypies	Microcephaly Spastic quadriplegia Ventricular septal defect	Microcephaly Hypertonia of the upper limbs with axial hypotonia Rotatory nystagmus Hypermetropia, astigmatism, strabismus and initial cataract She continuously brought her right hand to her mouth
Dysmorphism	NR	NR	Cleft lip and palate Overlapping fingers Small penis	Slightly narrow and up-slanted palpebral fissures Wide mouth with down-turned corners and hypoplasia of the depressor angularis oris muscle

GW: gestational week; SB: suppression-burst; ID: intellectual disability; NR: not reported.

\*the same patient is reported by Tohyama *et al.* (2008; Patient 2) and Saitou *et al.* (2010b; Patient 1).

The evidence that a transient EEG pattern, that varies from highly discontinuous to SB and evolves into hypsarrhythmia, is associated with disruption of *STXBP1* is also supported by the description of the previously cited case of Saitsu *et al.* (2012), in which the SB pattern lasted for only one month, and by the case (Patient 3) of Milh *et al.* (2011).

The EEG recordings of our patient in the neonatal period showed a highly discontinuous pattern, characterised by SB with some variability between wakefulness and sleep; however, epileptic seizures were neither observed nor recorded in the first month of life. At 2 months, when the cluster of spasms appeared, the transition of the SB-EEG pattern to hypsarrhythmia was noted. However, this is not surprising if we consider that at this age spasms with psychomotor regression and hypsarrhythmia are the specific features of WS (Fusco and Vigeveno, 1993). To our knowledge, this is the first description of a patient with a deletion of *STXBP1* and *SPTAN1* in which serial EEG recordings are reported over time. In particular, in the neonatal period, an initial SB-EEG pattern was found in the absence of neonatal seizures. In fact, for the patients reported by Saitsu *et al.* (2008; Patient 1) and Saitsu *et al.* (2012; Patient 2231), an SB pattern was evident upon appearance of tonic seizures and spasms, respectively, and a diagnosis of EIEE was made. Since no previous recordings were available, it is possible that these patients also had a highly, neonatal, discontinuous/SB pattern even before the beginning of the seizures. Further studies with neonatal EEG monitoring are needed to investigate the occurrence of this new finding. Finally, an early diagnosis is essential to avoid unnecessary genetic, metabolic, and neuroradiological analyses. This would provide a basis to establish appropriate follow-up with periodical video-EEG recordings in order to detect seizure onset and thus initiate effective antiepileptic treatment.

This case contributes to an expanding phenotype associated with *STXBP1* alterations and offers some insight into the aetiological diagnosis of EOEEs. We conclude that copy number analysis covering all *STXBP1* exons is recommended, not only for patients with EIEE, but also for those with EOEE with the peculiar EEG pattern that varies from a highly discontinuous to a more or less persistent SB, even in the absence of neonatal seizures. □

#### Acknowledgements and disclosures.

We would like to thank the patient and her family for participating in this study, all the physicians that collaborated in the clinical follow-up of the patient, and Dr Andrea Righini who kindly provided brain MRI images.

None of the authors has any conflict of interest to disclose.

## References

- Aicardi J, Ohtahara S. Severe neonatal epilepsies with suppression-burst pattern. In: Roger J, Bureau M, Dravet C, Genton P, Tassinari C, Wolf P. *Epileptic syndromes in infancy, childhood and adolescence*. 3rd ed. Montrouge (France) : John Libbey Eurotext, 2002: 33-44.
- Deprez L, Jansen A, De Jonghe P. Genetics of epilepsy syndromes starting in the first year of life. *Neurology* 2009;72:273-81.
- Deprez L, Weckhuysen S, Holmgren P, *et al.* Clinical spectrum of early-onset epileptic encephalopathies associated with *STXBP1* mutations. *Neurology* 2010;75:1159-65.
- Fusco L, Vigeveno F. Ictal clinical electroencephalographic findings of spasms in West syndrome. *Epilepsia* 1993;34:671-8.
- Giordano L, Sartori S, Russo S, *et al.* Familial Ohtahara syndrome due to a novel *ARX* gene mutation. *Am J Med Genet A* 2010;152A:3133-7.
- Hamdan FF, Gauthier J, Dobrzyńska S, *et al.* Intellectual disability without epilepsy associated with *STXBP1* disruption. *Eur J Hum Genet* 2011;19:607-9.
- Mignot C, Moutard ML, Trouillard O, *et al.* *STXBP1*-related encephalopathy presenting as infantile spasms and generalized tremor in three patients. *Epilepsia* 2011;52:1820-7.
- Milh M, Villeneuve N, Chouchane M, *et al.* Epileptic and nonepileptic features in patients with early onset epileptic encephalopathy and *STXBP1* mutations. *Epilepsia* 2011;52:1828-34.
- Ohtahara S, Ishida T, Oka E, *et al.* On the specific age dependent epileptic syndrome: the early infantile epileptic encephalopathy with suppression-burst. *No to Hattatsu* 1976;8:270-9.
- Pavone P, Spalice A, Polizzi A, Parisi P, Ruggieri M. Ohtahara syndrome with emphasis on recent genetic discovery. *Brain and Dev* 2012;4:459-68.
- Saitsu H, Kato M, Mizuguchi T, *et al.* *De novo* mutations in the gene encoding *STXBP1* (*MUNC18-1*) cause early infantile epileptic encephalopathy. *Nat Genet* 2008;40:782-8.
- Saitsu H, Kato M, Okada I, *et al.* *STXBP1* mutations in early infantile epileptic encephalopathy with suppression-burst pattern. *Epilepsia* 2010a;51:2397-405.
- Saitsu H, Tohyama J, Kumada T, *et al.* Dominant-negative mutations in alpha-II spectrin cause West syndrome with severe cerebral hypomyelination, spastic quadriplegia, and developmental delay. *Am J Hum Genet* 2010b;86:881-91.
- Saitsu H, Kato M, Shimono M, *et al.* Association of genomic deletions in the *STXBP1* gene with Ohtahara syndrome. *Clin Genet* 2012;81:399-402.
- Tohyama J, Akasaka N, Osaka H, *et al.* Early onset West syndrome with cerebral hypomyelination and reduced cerebral white matter. *Brain Dev* 2008;30:349-55.