



Correspondence:

Initial chest CT findings in COVID-19: correlation with clinical features^{*#}

Zhu-jing SHEN¹, Nan LU¹, Lu-lu GAO², Jian LV³,
 Hua-fu LUO⁴, Ji-feng JIANG⁵, Chao XU⁶, Shi-ya LI⁷,
 Ju-jiang MAO⁸, Kai LI⁹, Xiao-pei XU¹, Bin LIN^{†‡1}

¹Department of Radiology, the Second Affiliated Hospital, Zhejiang University School of Medicine, Hangzhou 310009, China

²Department of Radiology, Zhejiang Hospital, Hangzhou 310013, China

³Department of Radiology, Nanxishan Hospital of Guangxi Zhuang Autonomous Region, Guilin 541002, China

⁴Department of Radiology, Guang'an People Hospital, Guang'an 638000, China

⁵Department of Radiology, Zhuzhou Central Hospital, Zhuzhou 412007, China

⁶Department of Radiology, Affiliated Hospital of Yan'an University, Yan'an 716000, China

⁷Department of Radiology, Traditional Chinese Hospital of Ma'an Shan, Ma'an Shan 243000, China

⁸Department of Radiology, the Affiliated Hospital of Guizhou Medical University, Guiyang 550004, China

⁹Department of Radiology, Neihuang People's Hospital, Anyang 456300, China

[†]E-mail: zjdxlinbin@zju.edu.cn

<https://doi.org/10.1631/jzus.B2000133>

Published online May 20, 2020

In December 2019, coronavirus disease 2019 (COVID-19), a new de novo infectious disease, was first identified in Wuhan, China and quickly spread across China and around the world. The etiology was a novel betacoronavirus, the severe acute respiratory syndrome coronavirus 2 (SARS-CoV-2) (Lu et al., 2020). On Mar. 11, 2020, World Health Organization

(WHO) characterized COVID-19 as a global pandemic. As of Mar. 22, 2020, over 292 000 confirmed COVID-19 cases have been reported globally. To date, COVID-19, with its high infectivity, has killed more people than severe acute respiratory syndrome (SARS) and Middle East respiratory syndrome (MERS) combined (Wu and McGoogan, 2020).

Researchers are continuing to rigorously document and analyze clinical and radiological findings from laboratory-confirmed COVID-19 patients so that the clinical, laboratorial, and radiological changes in these patients can be better understood (Chen et al., 2020; Chung et al., 2020; Guan et al., 2020; Huang et al., 2020; Pan YY et al., 2020; Shi et al., 2020; Song et al., 2020; Wang et al., 2020). Records showed that common symptoms include fever and respiratory symptoms including dry cough and sore throat. Laboratory test results showed that lymphopenia is present in most cases and that lung abnormalities usually present as viral pneumonia, similar to other kinds of viral pneumonia (Yin and Wunderink, 2018).

Computed tomography (CT) scans, as a sensitive modality that detects changes in the lungs, are playing an important role in the evaluation and management of COVID-19 patients. Progressive airspace opacities and multifocal patchy subpleural ground-glass opacifications (GGOs) have been recorded as among the most common initial CT appearances of COVID-19 (Bernheim et al., 2020; Shi et al., 2020; Zu et al., 2020). However, the relationship between CT imaging features and clinical features remains unclear. In this study, we analyze initial chest CT images of patients with COVID-19 to determine the natural history of lung abnormalities and the relation of these characteristics with clinical features. These findings may help researchers and practitioners to more fully understand the clinical course and lung changes prompted by COVID-19 infection and possibly lead to improved methods in public health surveillance and evaluation.

[‡] Corresponding author

* Project supported by the Zhejiang University Special Scientific Research Fund for COVID-19 Prevention and Control (No. 2020XGZX036), China

Electronic supplementary materials: The online version of this article (<https://doi.org/10.1631/jzus.B2000133>) contains supplementary materials, which are available to authorized users

ORCID: Bin LIN, <https://orcid.org/0000-0002-3647-2144>

© Zhejiang University and Springer-Verlag GmbH Germany, part of Springer Nature 2020

Data for this study were taken from records of 36 patients with confirmed COVID-19 who were admitted to hospital from Jan. 16 to Feb. 6, 2020. Demographic and clinical data were obtained from all patients, including severity and time course of symptoms, laboratory results, and patient histories, including exposure. Data for this analysis for each patient included the duration from the onset of symptoms to the initial CT scan, fever measurements (including highest temperature and the duration from fever onset to CT scan), and white blood cell counts. Other blood parameters were not included due to limited data availability.

All CT images were reviewed by two experienced radiologists who used scoring method described by Chung et al. (2020) to evaluate the extent of involvement for each of the five lung lobes. Score 0, signified normality; Score 1, 1%–25% of the total lobe area; Score 2, 26%–50% of the total lobe area; Score 3, 51%–75% of the total lobe area; Score 4, 76%–100% of the total lobe area. The overall lung “CT score” was obtained by summing the five lung lobe scores (range, 0–20).

As indicated in Table 1, patients in this study had a median age of 46 years (interquartile range (IQR), 34–55 years). The median interval between onset and initial CT scanning was 4 d with IQR of 2–7 d. Among them, 33 (91.7%) patients presented with fever, and 30 of them (83.3%) experienced fever as the initial symptom. Thirty-one (86.1%) patients had low or middle fever (lower than 39 °C). As three patients did not have fever, the median interval between fever onset and CT scanning was 3 d with IQR of 1–7 d. On admission, 10 patients (27.8%) had leucopenia (white blood cell count $<4 \times 10^9 \text{ L}^{-1}$), 20 (55.6%) had lymphopenia (lymphocyte percentage $<20\%$), and 24 (66.7%) had neutrophilia (neutrophil percentage $>70\%$).

Fig. 1 presents the results of correlations between CT score and clinical data. CT scores were positively correlated with age ($r=0.333$, $P=0.048$) and with the duration from onset to CT scanning ($r=0.666$, $P<0.001$). CT scores correlated well with the duration from fever onset to CT scanning ($r=0.698$, $P<0.001$), and a marginally significant correlation was observed between CT scores and the highest temperature ($r=0.290$, $P=0.086$). Additionally, CT scores were negatively correlated with the lymphocyte count ($r=-0.495$, $P=0.002$), but positively correlated with the neutrophil

Table 1 Clinical features of 36 patients with COVID-19 on admission

Clinical feature	Value*
Sex	
Men	14 (38.9)
Women	22 (61.1)
Age (year)	46 (34–55)
Exposure history	
Recent travel to Wuhan	24 (66.7)
Exposure to infected patient	7 (19.4)
Unknown exposure	5 (13.9)
Fever	33 (91.7)
Highest temperature (°C)	38.3 (37.7–38.9)
<37.3	3 (8.3)
37.3–38.0	14 (38.9)
38.1–39.0	17 (47.2)
>39.0	2 (5.6)
Other symptoms	
Cough	24 (66.7)
Sputum production	8 (22.2)
Sore throat	11 (30.6)
Chills/rigor	9 (25.0)
Rhinorrhoea	4 (11.1)
Shortness of breath	6 (16.7)
Headache/dizziness	6 (16.7)
Muscle pain/fatigue	15 (41.7)
Diarrhea	1 (2.8)
Duration from onset to CT scanning (d)	4 (2–7)
Duration from fever onset to CT scanning (d)	3 (1–7)
WBC count ($\times 10^9 \text{ L}^{-1}$)	5.3 (3.7–7.0)
<4	10 (27.8)
4–10	25 (69.4)
>10	1 (2.8)
Neutrophil count ($\times 10^9 \text{ L}^{-1}$)	3.7 (2.7–5.4)
<50%	3 (8.3)
50%–70%	9 (25.0)
>70%	24 (66.7)
Lymphocyte count ($\times 10^9 \text{ L}^{-1}$)	1.0 (0.6–1.2)
<20%	20 (55.6)
20%–40%	11 (30.6)
>40%	5 (13.9)

* Values are expressed as number (percentage) or median (interquartile range, IQR). CT, computed tomography; WBC, white blood cell

count ($r=0.385$, $P=0.021$). The imaging features of lung lesions from early to late stage are showed in the supplementary materials (Document S1).

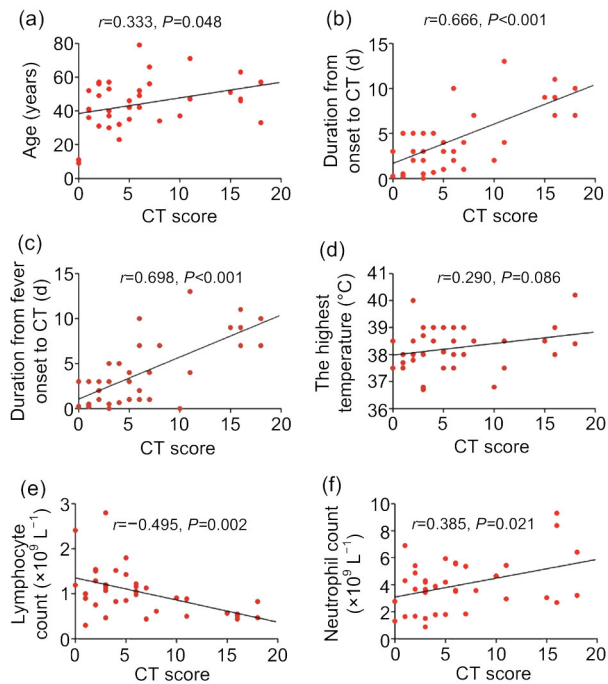


Fig. 1 Correlations between CT scores and clinical data Age (a), duration of symptoms (b), duration of fever (c), the highest temperature (d), lymphocyte count (e), and neutrophil count (f). CT, computed tomography

In this study, we investigated the initial CT features in COVID-19 patients and correlated results with their clinical features. Viral pneumonia developed in 94.4% of infected patients, presenting with GGO or/and consolidation with a focal or diffuse distribution, findings similar to those previously described (Chung et al., 2020; Pan YY et al., 2020; Shi et al., 2020; Song et al., 2020). In addition, the lung involvement was positively correlated with the duration of symptoms in all patients. These lung abnormalities were observed in the initial patient CT images and none necessitated any interventions. Our findings indicate that in the natural progress of SARS-CoV-2 infection, lung lesions become more severe with longer duration of symptoms, results consistent to those of infections just as SARS (Ooi et al., 2003). Recent studies have also shown that lung involvement increases rapidly after the onset of symptoms (Bernheim et al., 2020; Pan F et al., 2020).

More than 90% patients with COVID-19 developed fever during the disease course, with 90.9% of these patients exhibiting fever as their first symptom. Similar results were reported in recent studies

(Huang et al., 2020; Wang et al., 2020), as well as in other viral pneumonia caused by coronavirus, such as SARS and MERS (Yin and Wunderink, 2018). Wu et al. (2020) have also documented that the extent of lung lesions has been positively correlated with the duration and degree of fever.

To date, there is limited evidence about the pathophysiology about the COVID-19. It was reported that SARS-CoV-2 infection induced increased concentrations of proinflammatory cytokines (interleukin-1 β (IL-1 β), IL-4, IL-10, interferon- γ (IFN- γ), IFN- γ -inducible protein-10 (IP10), and monocyte chemoattractant protein-1 (MCP1)) (Huang et al., 2020) and decreased lymphocytes in patients with COVID-19 (Chen et al., 2020; Wang et al., 2020). Overactivation of T cells observed in at least one pathological study (Xu et al., 2020) suggests that virus particles spread through the respiratory mucosa and infected other cells induced a cytokine storm in the body. This response is thought to have generated a follow on series of immune responses (mainly cellular immune) and caused changes in peripheral white blood cells and immune cells (especially T lymphocytes), in turn resulting in diffuse alveolar damage. Data from both this and one previous study (Wu et al., 2020) indicate that there are correlations between degree of lung lesions and observed white blood cell count. The negative correlation between lung involvement and lymphocyte count in peripheral blood ($r=-0.260$, $P<0.05$) (Wu et al., 2020) provided more information that lymphopenia might be the hallmark of the exacerbations of COVID-19. Further studies are necessary to characterize the pathology and pathogenesis in COVID-19, which will help to improve our understanding of the disease.

Notably, there were some outlier results in this study in two teenager patients. Both patients did have fever, went to hospital on the first day and third day of onset symptom, respectively, but were admitted with normal CT. Three other patients were admitted with mild lung abnormalities, mild symptoms, and no fever. These suggested that early presentation to the healthcare center for testing helped to diagnose the disease in mild stage and allowed for better prognosis.

This study has several limitations. First, the sample size of our study was small, and most patients presented with mild illness. Therefore, the findings may not be extended in patients with a severe disease.

Second, CT images of one patient were acquired with 5-mm slice thickness, which might influence the precision of lesion evaluation. Third, due to limited data availability, it is impossible to assess the relationship between CT features and other clinical data, and continued observations of the disease course are needed.

Our results of lung abnormalities in the natural history of 36 COVID-19 patients with mild symptoms showed that there was a correlation of disease severity in chest CT findings with the duration of symptoms, especially fever, and that lymphopenia might be a marker of exacerbations of COVID-19.

Contributors

Zhu-jing SHEN designed the study and wrote the first draft of the manuscript. Nan LU and Lu-lu GAO analyzed the data and wrote the protocol. Jian LV, Hua-fu LUO, Ji-feng JIANG, Chao XU, Shi-ya LI, Ju-jiang MAO, and Kai LI collected the clinical and CT data. Xiao-pei XU and Bin LIN assisted with study design and interpretation of findings. All authors have read and approved the final manuscript and, therefore, have full access to all the data in the study and take responsibility for the integrity and security of the data.

Compliance with ethics guidelines

Zhu-jing SHEN, Nan LU, Lu-lu GAO, Jian LV, Hua-fu LUO, Ji-feng JIANG, Chao XU, Shi-ya LI, Ju-jiang MAO, Kai LI, Xiao-pei XU, and Bin LIN declare that they have no conflict of interest.

All procedures followed were in accordance with the ethical standards of the responsible committee on human experimentation (institutional and national) and with the Helsinki Declaration of 1975, as revised in 2008 (5). Local institutional review boards approved the protocol. Due to the urgency of distributing these findings, the institutional review board of the Second Affiliated Hospital, Zhejiang University School of Medicine (Hangzhou, China) waived the necessity to get consent for the collection, analysis, and publication of these patients' data.

References

- Bernheim A, Mei XY, Huang MQ, et al., 2020. Chest CT findings in coronavirus disease-19 (COVID-19): relationship to duration of infection. *Radiology*, online. <https://doi.org/10.1148/radiol.2020200463>
- Chen NS, Zhou M, Dong X, et al., 2020. Epidemiological and clinical characteristics of 99 cases of 2019 novel coronavirus pneumonia in Wuhan, China: a descriptive study. *Lancet*, 395(10223):507-513. [https://doi.org/10.1016/S0140-6736\(20\)30211-7](https://doi.org/10.1016/S0140-6736(20)30211-7)
- Chung M, Bernheim A, Mei XY, et al., 2020. CT imaging features of 2019 novel coronavirus (2019-nCoV). *Radiology*, 295(1):200230. <https://doi.org/10.1148/radiol.2020200230>
- Guan WJ, Ni ZY, Hu Y, et al., 2020. Clinical characteristics of coronavirus disease 2019 in China. *N Engl J Med*, 382(18):1708-1720. <https://doi.org/10.1056/NEJMoa2002032>
- Huang CL, Wang YM, Li XW, et al., 2020. Clinical features of patients infected with 2019 novel coronavirus in Wuhan, China. *Lancet*, 395(10223):497-506. [https://doi.org/10.1016/S0140-6736\(20\)30183-5](https://doi.org/10.1016/S0140-6736(20)30183-5)
- Lu RJ, Zhao X, Li J, et al., 2020. Genomic characterisation and epidemiology of 2019 novel coronavirus: implications for virus origins and receptor binding. *Lancet*, 395(10224):565-574. [https://doi.org/10.1016/S0140-6736\(20\)30251-8](https://doi.org/10.1016/S0140-6736(20)30251-8)
- Ooi CGC, Khong PL, Lam B, et al., 2003. Severe acute respiratory syndrome: relationship between radiologic and clinical parameters. *Radiology*, 229(2):492-499. <https://doi.org/10.1148/radiol.2292030736>
- Pan F, Ye TH, Sun P, et al., 2020. Time course of lung changes on chest CT during recovery from 2019 novel coronavirus (COVID-19) pneumonia. *Radiology*, online. <https://doi.org/10.1148/radiol.2020200370>
- Pan YY, Guan HX, Zhou SC, et al., 2020. Initial CT findings and temporal changes in patients with the novel coronavirus pneumonia (2019-nCoV): a study of 63 patients in Wuhan, China. *Eur Radiol*, Online. <https://doi.org/10.1007/s00330-020-06731-x>
- Shi HS, Han XY, Jiang NC, et al., 2020. Radiological findings from 81 patients with COVID-19 pneumonia in Wuhan, China: a descriptive study. *Lancet*, 20(4):425-434. [https://doi.org/10.1016/S1473-3099\(20\)30086-4](https://doi.org/10.1016/S1473-3099(20)30086-4)
- Song FX, Shi NN, Shan F, et al., 2020. Emerging 2019 novel coronavirus (2019-nCoV) pneumonia. *Radiology*, 295(1):200274. <https://doi.org/10.1148/radiol.2020200274>
- Wang DW, Hu B, Hu C, et al., 2020. Clinical characteristics of 138 hospitalized patients with 2019 novel coronavirus-infected pneumonia in Wuhan, China. *JAMA*, 323(11):1061-1069. <https://doi.org/10.1001/jama.2020.1585>
- Wu J, Wu XJ, Zeng WB, et al., 2020. Chest CT findings in patients with coronavirus disease 2019 and its relationship with clinical features. *Invest Radiol*, 55(5):257-261. <https://doi.org/10.1097/rli.0000000000000670>
- Wu ZY, McGoogan JM, 2020. Characteristics of and important lessons from the coronavirus disease 2019 (COVID-19) outbreak in China: summary of a report of 72 314 cases from the Chinese center for disease control and prevention. *JAMA*, 323(13):1239-1242. <https://doi.org/10.1001/jama.2020.2648>
- Xu Z, Shi L, Wang YJ, et al., 2020. Pathological findings of COVID-19 associated with acute respiratory distress syndrome. *Lancet Respir Med*, 8(4):420-422. [https://doi.org/10.1016/S2213-2600\(20\)30076-X](https://doi.org/10.1016/S2213-2600(20)30076-X)
- Yin YD, Wunderink RG, 2018. MERS, SARS and other coronaviruses as causes of pneumonia. *Respirology*, 23(2):

130-137.

<https://doi.org/10.1111/resp.13196>

Zu ZY, Jiang MD, Xu PP, et al., 2020. Coronavirus disease 2019 (COVID-19): a perspective from China. *Radiology*, online.

<https://doi.org/10.1148/radiol.2020200490>

List of electronic supplementary materials

Document S1 Supplementary materials

中文概要

题目: 2019 冠状病毒病首次胸部 CT 影像表现及其与临床表现的相关性研究

目的: 分析 2019 冠状病毒病 (COVID-19) 患者首次胸

部 CT 影像表现及其与临床表现 (包括发热症状、实验室检查) 的相关性。

创新点: 初步探索 COVID-19 肺部病灶与临床数据的相关性, 对评估 COVID-19 患者提供一定的依据。

方法: 纳入 2020 年 1 月 16 日至 2020 年 2 月 6 日入院的 36 例 COVID-19 患者, 回顾性分析首次胸部 CT 的影像学表现, 包括影像特征、分布模式、累及范围等, 并进一步分析其与临床特征 (包括发病时间、发热症状、白细胞计数等) 的相关性。

结论: 结果发现, 在自然病程中, COVID-19 肺部病变与发病时间显著相关, 特别是发热症状。COVID-19 病变范围与淋巴细胞计数呈负相关, 淋巴细胞减少可能是 COVID-19 进展的标志之一。

关键词: 2019 冠状病毒病 (COVID-19); 胸部 CT; 发热; 淋巴细胞减少