

CASE REPORT

Acute myocarditis secondary to cardiac tuberculosis: a case report

Alice Cowley MBChB¹, Laura Dobson MBChB¹, John Kurian MBBS² and Christopher Saunderson MBChB¹

¹Department of Cardiology, Leeds General Infirmary, Leeds, UK

²Department of Cardiology, Bradford Royal Infirmary, Bradford, UK

Correspondence should be addressed to C Saunderson

Email
chrissaunderson@doctors.org.uk

Summary

Isolated myocardial involvement in tuberculosis is exceedingly rare but there are reports it can present with sudden cardiac death, atrioventricular block, ventricular arrhythmias or congestive cardiac failure. We report the case of a 33-year-old male, of South Asian descent, who presented with chest pain, shortness of breath and an abnormal ECG. The patient had no significant past medical history and coronary angiogram showed no evidence of coronary artery disease. Of note, the patient had recently been discharged from a local district hospital with an episode of myocarditis. The patient was found to be severely hypoxic with evidence of severe biventricular failure on echocardiography. Computed tomography of the chest demonstrated hilar lymphadenopathy, and the differential diagnosis was thought to be tuberculosis or sarcoidosis. A TB Quantiferon gold test performed at the district hospital was positive; however, fine needle aspiration was negative for acid-fast bacilli. Despite aggressive diuresis, the patient became increasingly hypoxic and suffered a cardiac arrest. Post-mortem confirmed a diagnosis of myocardial tuberculosis – a rare case of acute decompensated heart failure.

Key Words

- ▶ fulminant myocarditis
- ▶ left ventricular dysfunction
- ▶ right ventricular dysfunction
- ▶ mycobacterium tuberculosis

Learning points:

- Tuberculosis myocarditis is a rare diagnosis but should be considered in at risk individuals presenting with acute fulminant myocarditis.
- Cardiac failure can occur even in the absence of disseminated tubercular disease.
- TB myocarditis is not just a disease of the immunocompromised.
- Definitive diagnosis of cardiac tuberculosis during life requires a myocardial biopsy.
- Echocardiography is a vital tool for the assessment of cardiac function, filling pressures and fluid status in the critically unwell patient.

Background

Tuberculosis (TB) rarely involves the heart but when it does most usually manifests as isolated pericarditis leading to a pericardial effusion or myopericarditis. Isolated TB myocarditis is extremely rare but can present

(like any other cause of myocarditis) with sudden cardiac death, tachy- and brady- arrhythmias or congestive cardiac failure (1). TB, due to its insidious onset and long latent phase, is difficult to diagnose in most organs of the

body and the heart is no different. TB myocarditis can mimic other cardiac infiltrative diseases and is usually diagnosed late and only following biopsy of either cardiac or surrounding lymphatic tissue.

Case presentation

A UK born 33-year-old male of Pakistani descent presented to the regional primary percutaneous intervention centre complaining of chest pain and shortness of breath. Further questioning revealed symptoms of anorexia, non-productive cough and night sweats. The patient denied arthralgia, skin rashes or eye symptoms. The patient had no personal or contact TB history or social history of note. The patient's last foreign travel was five years ago. Past medical history was remarkable for a recent admission to a local hospital for an episode of presumed acute myocarditis of uncertain aetiology. Investigations during this episode included a positive TB Quantiferon gold test, negative human deficiency virus (HIV) and normal serum angiotensin-converting enzyme (ACE) levels. Computerised tomography (CT) imaging of the chest demonstrated asymmetrical hilar lymphadenopathy with subsequent endobronchial aspiration demonstrating non-caseating granulomatous inflammation that was negative for acid-fast bacilli.

On presentation, the patient had a marked hypoxia (arterial oxygen saturations of 88% on high flow oxygen) and tachypnoea with a respiratory rate of 32 bpm. Examination was only remarkable for fine crepitations at the right lung base. Specifically there was no clubbing, lymphadenopathy or peripheral oedema.

Investigation

ECG showed sinus rhythm with p pulmonale, right bundle branch block with prolonged QRS duration (186 ms) (Fig. 1). Subsequent angiogram showed normal coronary arteries. Arterial blood gas analysis showed type 1 respiratory failure with a pH of 7.48, partial pressure oxygen of 5.97 kPa, carbon dioxide of 3.3 kPa with a lactate of 1.9 despite high flow oxygen administration by reservoir facemask. Laboratory test showed a troponin I of 7118 ng/L (normal <50 ng/L) and elevated C-reactive protein of 53 mg/L (normal <10 mg/L). An autoimmune screen was negative. Chest radiograph showed cardiomegaly with clear lung fields (Fig. 2). Urgent bedside transthoracic echocardiography demonstrated severe biventricular impairment and transmitral Doppler was suggestive of elevated left atrial pressure (Fig. 3 and Video 1). A CT pulmonary angiogram demonstrated right paratracheal, mediastinal and hilar lymphadenopathy

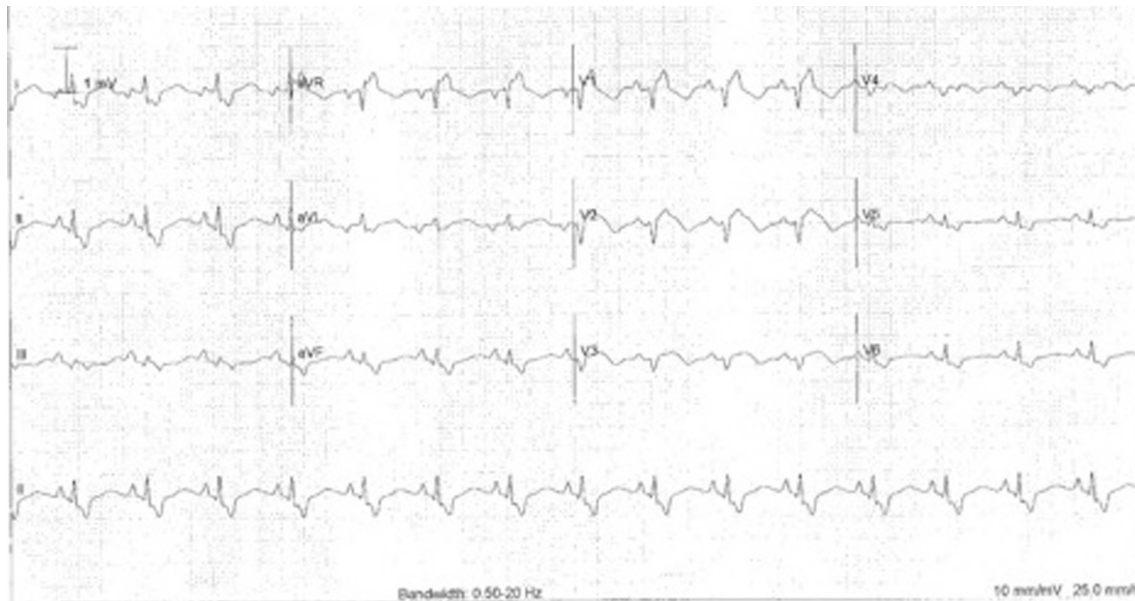


Figure 1
An ECG showing p pulmonale, right bundle branch block with a QRS duration of 186 ms.

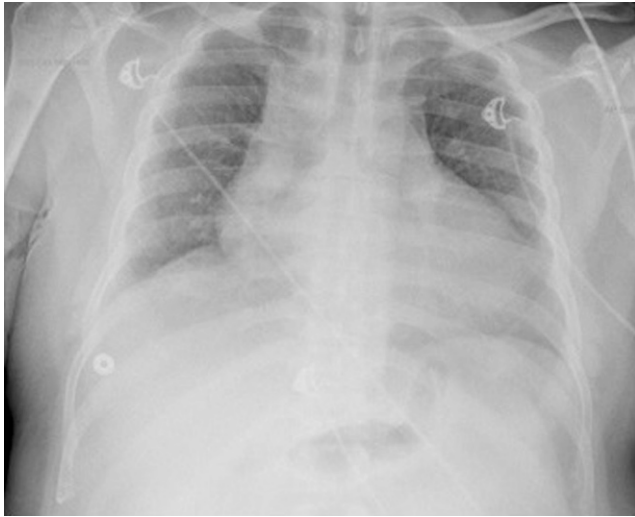


Figure 2
Anterior-posterior chest radiograph with increased cardiothoracic ratio indicating cardiomegaly.

with septal thickening and diffuse non-specific ground-glass opacification but no evidence of pulmonary embolism (Fig. 4). Cardiac magnetic resonance imaging could not be performed due to claustrophobia.

Treatment and outcome

The patient received aggressive diuresis with intravenous furosemide and was commenced on positive pressure non-invasive ventilation. The patient slowly improved over the following few days and heart failure therapy including angiotensin-converting enzyme inhibitors, beta blockers and an aldosterone antagonist were initiated. The patient received intravenous antibiotics to cover any potential infection. The cause of the acute myocarditis was still

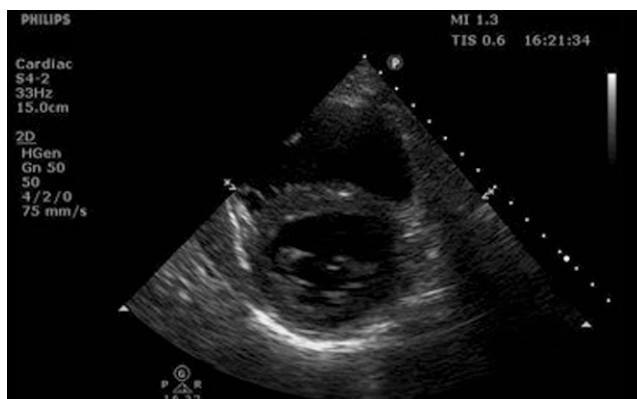

Figure 3
Parasternal short axis view on ECHO displaying severe biventricular failure, the right ventricle was almost akinetic.

Video 1

Two chamber parasternal short axis view on ECHO displaying severe biventricular failure, the right ventricle was almost akinetic. View Video 1 at <http://movie-usa.glencoesoftware.com/video/10.1530/ERP-17-0024/video-1>.

undetermined; although it was clear that the aetiology was secondary to granulomatous disease. The differential although uncertain was between TB and acute sarcoidosis, and given the vastly differing treatment strategies, the decision by the multi-disciplinary team was to delay definitive treatment until further information could be obtained from an endobronchial ultrasound-guided biopsy and further high-resolution CT chest imaging. Echocardiography was repeated during the admission to evaluate fluid balance.

Unfortunately the patient deteriorated with increasing oxygen requirements requiring intubation and ventilation. Given the uncertainty about diagnosis, high-dose steroids and anti-tuberculosis medication were initiated concurrently. Bedside echocardiography was repeated at this stage to re-evaluate ventricular function and to optimise fluid balance. Despite these measures, the patient continued to deteriorate, had a cardiac arrest and was unable to be resuscitated.

At post-mortem, there was almost complete replacement of the right ventricular myocardium with scar tissue and patchy fibrosis of the left ventricle. Other positive findings included hilar lymphadenopathy as seen on the CT thorax. Ziehl-Neelsen stain for mycobacterium of the lymph nodes was positive and there was evidence of giant cells invading cardiac myocytes (Fig. 5). Biopsy of the lung tissue showed mycobacterium tuberculosis after four-week incubation.

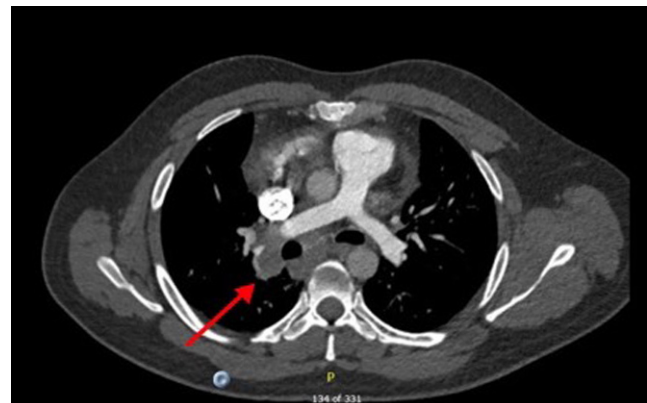


Figure 4
Computed tomography scan showed significant mediastinal, paratracheal and hilar lymphadenopathy (arrow).

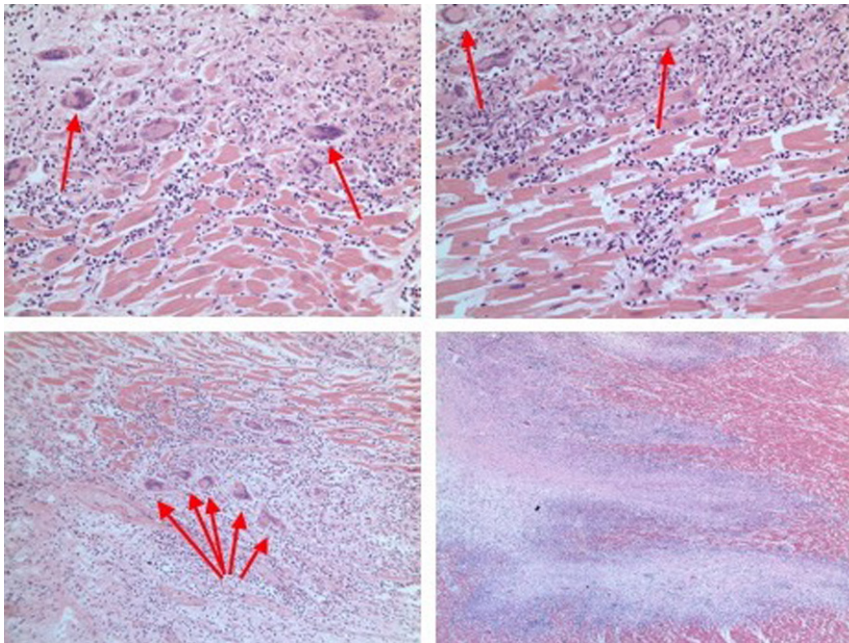


Figure 5
Histopathology slides showing inflammation and giant cells (arrows) invading cardiac myocytes.

Discussion

Despite medical advances, mycobacterium tuberculosis remains a deadly disease with the ability to invade almost every organ of the body. Difficulty in diagnosis is a hallmark feature of the disease and as a result diagnosis is often late or, as in this case, occurs post-mortem. Cardiac involvement with TB infection occurs in approximately 1% of affected individuals and most commonly affects the pericardium (2). Myocardial involvement is very rare and estimated to be responsible for <0.1% of TB-related deaths and usually present with acute fulminant myocarditis, sudden cardiac death or brady or tachy arrhythmias (1, 3).

Infiltration of the myocardium by TB can occur by haematogenous seeding from a remote focus, direct spread from the pericardium or, as seems likely in this case, via lymphatic spread from mediastinal lymph nodes (4). A predilection for the right-sided mediastinal lymph nodes has been described in TB thus allowing direct spread to the myocardium with the right side of the heart being most commonly affected in this situation, as seen in the post-mortem of this patient (5, 6). Three different types of myocardial involvement in TB have been described pathologically: diffuse infiltrative, caseating nodular and miliary. The imaging and post-mortem findings in this case suggest direct lymphatic spread causing a diffuse infiltrative process within the myocardium. Interestingly previous investigation of mediastinal lymph nodes was

negative for acid-fast bacilli, although this can be seen in TB and does not rule out the infection (7).

TB myocarditis is often diagnosed at post-mortem, reinforcing the difficult nature of the diagnosis. Biopsy of the myocardium can be a useful diagnostic tool in cases of congestive cardiac failure with unknown aetiology, but only carries a weak recommendation (Class IIa Level C) for use in European guidelines (8, 9). Treatment with anti-tubercular drugs has been shown to lead to better clinical outcomes in TB myocarditis (5). Therefore, greater awareness and more prompt diagnosis, including endomyocardial biopsy, could improve outcomes for this rare sequelae of TB.

Declaration of interest

There is no conflict of interest that could be perceived as prejudicing the impartiality of this case report.

Funding

This work did not receive any specific grant from any funding agency in the public, commercial or not-for-profit sector.

Patient consent

The patient is deceased, but written informed consent for publication of this case report has been granted by the patient's next of kin.

Author contribution statement

Alice Cowley and Christopher Saunderson wrote the initial manuscript draft. Laura Dobson recorded echocardiographic images and together with John Kurian reviewed and revised the manuscript. Alice Cowley and Christopher Saunderson revised the final version of the manuscript.

References

- 1 Khurana R, Shalhoub J, Verma A, Assomull R, Prasad SK, Kooner JS & Sethi A 2008 Tubercular myocarditis presenting with ventricular tachycardia. *Nature Clinical Practice Cardiovascular Medicine* **5** 169–174. (doi:10.1038/ncpcardio1111)
- 2 Fowler NO 1991 Tuberculous pericarditis. *JAMA* **266** 99–103. (doi:10.1001/jama.1991.03470010103039)
- 3 Rose AG 1987 Cardiac tuberculosis. A study of 19 patients. *Archives of Pathology and Laboratory Medicine* **111** 422–426.
- 4 Maeder M, Ammann P, Rickli H & Schoch OD 2003 Fever and night sweats in a 22-year-old man with a mediastinal mass involving the heart. *Chest* **124** 2006–2009.
- 5 Michira BN, Alkizim FO & Matheka DM 2015 Patterns and clinical manifestations of tuberculous myocarditis: a systematic review of cases. *Pan African Medical Journal* **21** 118. (doi:10.11604/pamj.2015.21.118.4282)
- 6 Wallis PJ, Branfoot AC & Emerson PA 1984 Sudden death due to myocardial tuberculosis. *Thorax* **39** 155–156. (doi:10.1136/thx.39.2.155)
- 7 Bennedsen J, Thomsen VO, Pfyffer GE, Funke G, Feldmann K, Beneke A, Jenkins PA, Hegginsbothom M, Fahr A, Hengstler M, *et al.* 1996 Utility of PCR in diagnosing pulmonary tuberculosis. *Journal of Clinical Microbiology* **34** 1407–1411.
- 8 Parrillo JE, Aretz HT, Palacios I, Fallon JT & Block PC 1984 The results of transvenous endomyocardial biopsy can frequently be used to diagnose myocardial diseases in patients with idiopathic heart failure. endomyocardial biopsies in 100 consecutive patients revealed a substantial incidence of myocarditis. *Circulation* **69** 93–101. (doi:10.1161/01.CIR.69.1.93)
- 9 Ponikowski P, Voors AA, Anker SD, Bueno H, Cleland JG, Coats AJ, Falk V, González-Juanatey JR, Harjola VP, Jankowska EA, *et al.* 2016 ESC guidelines for the diagnosis and treatment of acute and chronic heart failure: the task force for the diagnosis and treatment of acute and chronic heart failure of the European Society of Cardiology (ESC). developed with the special contribution of the heart failure association (HFA) of the ESC. *European Journal of Heart Failure* **18** 891–975. (doi:10.1002/ejhf.592)

Received in final form 10 August 2017

Accepted 16 August 2017

Accepted preprint published online 16 August 2017