

CASE REPORT

Large, mobile, transmitral metastatic osteosarcoma presenting as cardiac arrest

Clare M Jackson MB ChB¹, Helen E Ellis MB ChB², Mark C Dodd MB ChB³ and Laurence O'Toole FRCP¹

Departments of ¹Cardiology, and ²Critical Care, Northern General Hospital, Herries Road, Sheffield S5 7AU, UK

³Department of Critical Care, Chesterfield and North Derbyshire Royal Hospital, Top Road, Calow, Chesterfield S44 5BL, UK

Correspondence should be addressed to C M Jackson

Email
claremjackson@yahoo.com

Summary

The present case is an unusual one of a 21-year-old female with a primary osteosarcoma and left lung metastasis presenting following a witnessed pulseless electrical activity cardiac arrest. The electrocardiogram was unremarkable. A computed tomography pulmonary angiogram (CTPA) demonstrated a tumour within the left inferior pulmonary veins. Transthoracic echocardiography (TTE) revealed a severely hypokinetic left ventricle and a multi-lobulated, mobile mass arising from one of the left pulmonary veins which prolapsed to varying degrees on a beat-to-beat basis back and forth through the mitral valve into the left ventricle (during ventricular diastole) and retracted back into the left atrium (during ventricular systole). The present case demonstrates the importance of performing TTE in an emergency presentation, its influence on diagnosis and, in the present case, its usefulness in aiding the decision to withdraw life-sustaining treatments. It also highlights the importance of considering urgent intervention for a tumour seen to prolapse through the mitral valve because of the real risk of acute obstruction.

Learning points:

- The present case emphasises the importance of thorough clinical assessment in triggering TTE assessment in a critical care setting.
- TTE is a portable, radiation-free imaging modality that can aid rapid diagnosis in a deteriorating patient and guide an informed management plan.
- Many district general hospitals in the UK lack cardiology support and access to echocardiography 'out-of-hours'. TTE, in the hands of an experienced operator, is an invaluable tool in the emergency assessment and management of critically unwell patients and should be available 24 h a day, 7 days a week.
- Echocardiographers and physicians seeing similar dynamic tumour pathology with variable transmission through the mitral valve should bear in mind acute obstruction as a potential consequence and thus consider urgent intervention.

Background

The present case is an unusual and interesting example of a sudden, unheralded pulseless electrical activity (PEA) cardiac arrest in a young female with a known osteosarcoma and pulmonary metastasis which was subsequently found to have metastasised to the heart. The case

illustrates the utilisation of transthoracic echocardiography (TTE) in an emergency presentation, its influence on diagnosis and the management of the patient and how it aided explanation of the cause of the cardiac arrest. It also highlights the importance of considering urgent intervention in the context of dynamic tumour pathology.

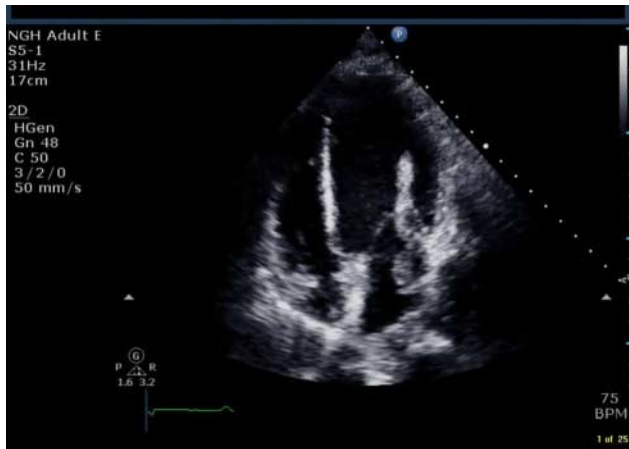

Figure 1
Apical four chamber view. 2D image of the tumour extending from the left atrium into the left ventricle during ventricular diastole.

Case presentation

A 21-year-old female was brought to the emergency department following a witnessed out-of-hospital cardiac arrest. The presenting cardiac rhythm was PEA with a return of spontaneous circulation following paramedic cardiopulmonary resuscitation. She had been intubated and ventilated at the time of the cardiac arrest and was subsequently admitted to the Intensive Care Unit for therapeutic hypothermia and organ support.

Her medical notes revealed a history of primary osteosarcoma of the femur, which had been surgically resected 2 years previously. Adjunctive chemotherapy preceded a period of remission before bilateral pulmonary metastatic deposits were identified. These were surgically resected, but at follow-up, a recurrent and rapidly progressive metastasis at the left lung base was diagnosed.

Investigation

At the time of the acute presentation, the electrocardiogram was unremarkable. Serum troponin was only mildly elevated, in keeping with the cardiac arrest and brief period of cardiopulmonary resuscitation. A computed tomography pulmonary angiogram (CTPA) revealed a tumour within the left inferior pulmonary veins. A CT thorax performed 6 weeks earlier had shown the metastatic lung lesion invading the left pulmonary vein and involving the posterior branches of the left main stem bronchus, but there was no evidence of intra-cardiac spread at that time.

A previously undocumented grade 3, pan-systolic murmur was found upon examination. This, together with an unexplained increase in vasopressor requirement, led to an urgent comprehensive TTE being performed by a Cardiology SpR trainee (who was not BSE accredited at the time) in the Intensive Care Unit. The TTE demonstrated severe global hypokinesia of the left ventricle, normal wall thickness and internal dimensions. The left atrium contained a multi-lobulated, mobile mass arising from one of the left pulmonary veins. This mass prolapsed to differing degrees on a beat-to-beat basis through the mitral valve into the left ventricle during ventricular diastole and appeared to retract fully into the left atrium during ventricular systole (Figs 1, 2 and 3). M-mode across the mitral valve in the parasternal long axis view indicated variable mechanical contact between the valve and the lesion as it retracted into the left atrium at the end of ventricular diastole (Fig. 4). The closure of the mitral valve was incomplete because of the restricted excursion of the mitral valve leaflets (in keeping with the observed left ventricular systolic dysfunction), which caused mitral regurgitation (MR) with a single severe, regurgitant jet. This jet was seen as central because it regurgitated through the mitral valve but then had the appearance of being posteriorly directed because of the flow being deviated around the tumour within the left atrium (Fig. 5) (effective orifice area 1.48 cm²; proximal isovelocity surface area (PISA) radius 1.4 cm; aliasing velocity 60 cm/s; peak MR velocity 4.99 m/s; MR velocity time integral (VTI) 134 cm). The remainder of the chambers were normal in size, and there was no other significant valvular lesion. The findings

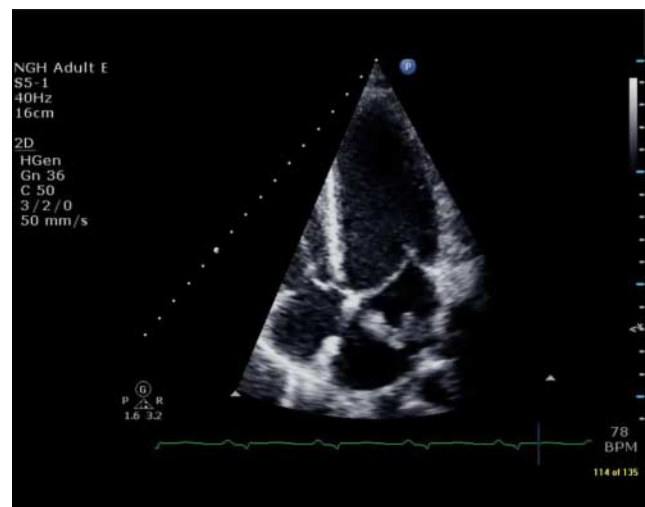


Figure 2
Apical four chamber view. The tumour is fully retracted into the left atrium.

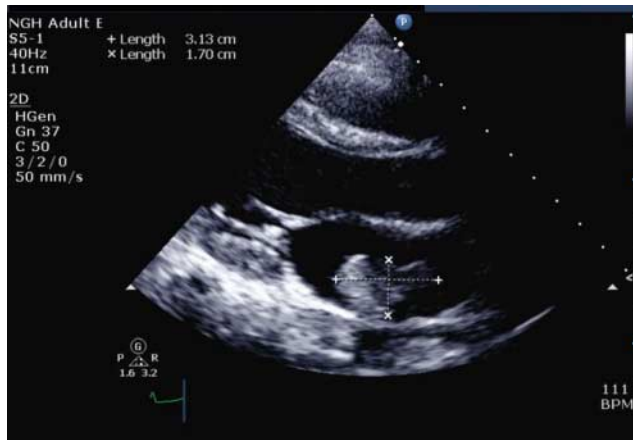

Figure 3
Parasternal long axis view. The tumour can be seen within the left atrium.

were felt to be consistent with acute MR secondary to the severe left ventricular impairment and disruption of the mitral valve integrity by the tumour. The left ventricular systolic dysfunction was thought to most probably be a result of acute stunning secondary to the cardiac arrest.

Treatment and outcome

Increasing inotrope and vasopressor requirements, the CT and TTE findings and a terminal diagnosis led to discussions with the patient's family, and a decision was made to withdraw life-sustaining treatment. The patient was transferred to a palliative care setting and died a short time later.

Discussion

The present unusual case demonstrates the unexpected finding of a dynamic intravascular tumour traversing the mitral valve, severe left ventricular impairment and severe MR. The value of cardiac ultrasound during cardiac arrest and in patients admitted to intensive care has increasingly been recognised (1, 2). The case clearly demonstrates the advantage of TTE in this setting, because it can provide rapid diagnosis in a deteriorating patient with increasing inotrope and vasopressor requirements and can guide an informed management plan – in the present case, to withdraw life-sustaining treatment.

Tumours involving the heart are relatively rare. Metastases are more common than primary cancers and are thought to occur in up to 15% of all sarcomas (3). They are often asymptomatic, even with extensive cardiac involvement, but they can lead to sudden cardiac death.

Transvenous spread to the left heart cavity via the pulmonary veins is uncommon (4), but there have been case reports describing this phenomenon (5).

The use of TTE in the present case helped in determining the probable mechanism of cardiac arrest and explaining the lack of a satisfactory response to increasing vasopressor doses.

Although TTE did not demonstrate significant inflow obstruction to the left ventricle by the tumour, the beat-to-beat variability in the degree to which the tumour appeared to 'unfold' and project through the mitral valve into the left ventricle supports the hypothesis of sudden, temporary complete occlusion of the mitral valve (and thus left ventricular inflow) as a plausible causative mechanism for the PEA cardiac arrest. It is most likely that the lobulated lesion caught on the mitral valve apparatus during ventricular diastole, which temporarily prevented its retraction at the end of the ventricular filling phase back into the left atrium. This scenario would have caused a loss of ventricular filling for a few cardiac cycles, which would have resulted in the emptying of the left ventricular cavity and subsequent cardiac arrest. This explanation is given credence by the presenting rhythm of PEA and the rapid restoration of circulation following cardiopulmonary resuscitation. Cardiac arrest resulting from a ball-valve effect of a tumour or thrombus in the right side of the heart has been described previously (6).

We believe that the severe left ventricular systolic impairment was most probably secondary to myocardial stunning as a result of the cardiac arrest, and the MR occurred as a result of the systolic impairment. This hypothesis is further supported by the fact that

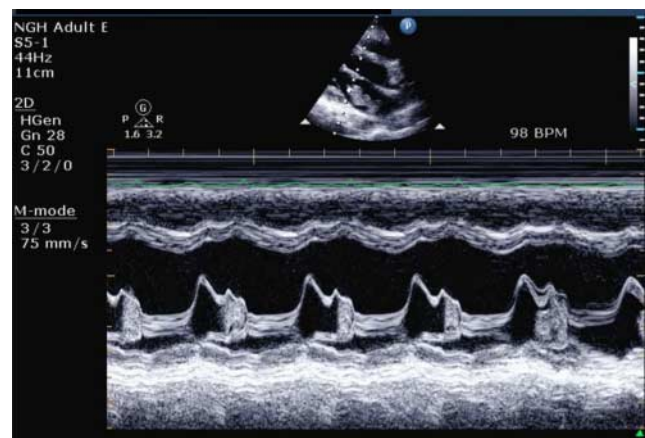


Figure 4
Parasternal long axis view. M-mode across the mitral valve indicates variable mechanical contact between the valve and the tumour.

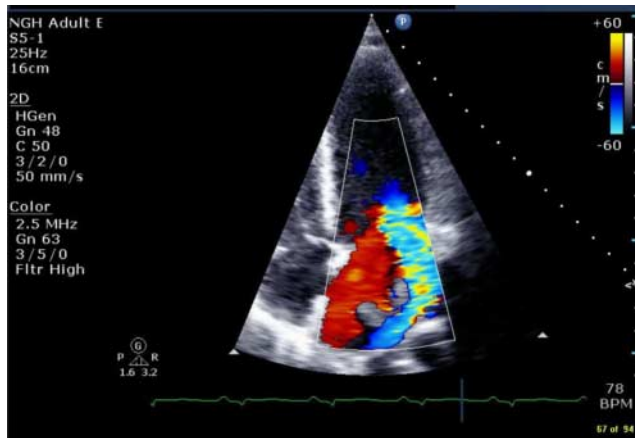


Figure 5
Apical four chamber view. Colour Doppler showing a single severe mitral regurgitant jet.

a post-chemotherapy echocardiogram performed 12 months earlier had revealed entirely normal left ventricular systolic function and only trivial MR. The absence of preceding symptoms and signs of chronic MR seen with TTE (no dilatation of the left atrium, no dilatation or hypertrophy of the left ventricle and no pulmonary hypertension) are also supportive of a more acute process having led to the observed findings.

Other possible mechanisms or contributing factors for the cardiac arrest and left ventricular dysfunction have been considered (cardiac arrhythmia secondary to cardiac metastasis, embolisation of the tumour into a coronary artery and cardiotoxicity of doxorubicin chemotherapy), but none was considered to be able to comprehensively explain the absence of symptoms before the cardiac arrest or the presenting clinical and TTE findings.

In summary, the present case demonstrates the usefulness of TTE in an acutely unwell individual and its influence on diagnosis and management of the patient. It also highlights the importance of considering urgent intervention when dynamic tumour pathology with variable transmission through the mitral valve is observed because of its potential to lead to acute obstruction and cardiac arrest.

Declaration of interest

The authors declare that there is no conflict of interest that could be perceived as prejudicing the impartiality of the research reported.

Funding

This research did not receive any specific grant from any funding agency in the public, commercial or not-for-profit sector.

Patient consent

The patient is deceased, but consent for publication of this case report has been granted by the parents.

Author contribution statement

C M Jackson, H E Ellis, M C Dodd and Laurence O'Toole collaborated in interpreting the investigation and wrote, reviewed and submitted the manuscript.

Acknowledgements

Julian Gunn was the physician in charge of the patient's care during her hospital admission and gives permission for publication of this case report.

References

- Orme RM, Oram MP & McKinstry CE 2009 Impact of echocardiography on patient management in the intensive care unit: an audit of district general hospital practice. *British Journal of Anaesthesia* **102** 340–344. (doi:10.1093/bja/aen378)
- Stanko LK, Jacobsohn E, Tam JW, De Wet CJ & Avidan M 2005 Transthoracic echocardiography: impact on diagnosis and management in tertiary care intensive care units. *Anaesthesia and Intensive Care* **33** 492–496.
- Roberts WC 1997 Primary and secondary neoplasms of the heart. *American Journal of Cardiology* **80** 671–682. (doi:10.1016/S0002-9149(97)00587-0)
- Reynen K, Köckeritz U & Strasser RH 2004 Metastases to the heart. *Annals of Oncology* **15** 375–381. (doi:10.1093/annonc/mdh086)
- Suriani R, Konstadt S, Camunas J & Goldman M 1993 Transesophageal echocardiographic detection of left atrial involvement of a lung tumor. *Journal of Cardiothoracic and Vascular Anesthesia* **7** 73–75. (doi:10.1016/1053-0770(93)90123-3)
- Culpepper AL & von Hamm E 1934 Primary carcinoma of the liver with extensive metastasis to the right heart, and tumor-thrombosis of the inferior vena cava. *American Journal of Cancer* **21** 355–362. (doi:10.1158/ajc.1934.355)

Received in final form 7 April 2015

Accepted 13 April 2015