

CASE REPORT

An unusual myocardial infarction

Sara Di Michele MD¹, Francesca Mirabelli MD¹, Domenico Galzerano MD² and Sunil Mankad MD³

¹Department of Heart and Great Vessels 'A. Reale', La Sapienza University, Rome, Italy

²Division of Cardiology, San Gennaro Hospital, Naples, Italy

³Mayo Clinic, Department of Cardiovascular Disease, Rochester, Minnesota, USA

Correspondence should be addressed to D Galzerano
Email
domicogalzerano@libero.it

Summary

We present a 74-year-old male with a chondrosarcoma, who presented with chest pain. The history, electrocardiogram (ECG), and biomarkers established the diagnosis of myocardial infarction (MI); angiography did not show coronary atherosclerosis and, both initial transthoracic echocardiogram and chest computed tomography (CT), did not demonstrate any cardiac abnormalities. A second echocardiogram following a routine ECG showed presence of a mass involving the right ventricle and the cardiac apex that was confirmed by chest CT scan. We underline the importance of considering cardiac tumors in the clinical arena of MI management.

Learning points:

- Cardiac tumors cause ECG changes similar to ischemic heart diseases.
- Keep in mind cardiac tumors when performing transthoracic echocardiogram (TTE) in the setting of suspected MI.
- TTE is the technique of choice in detecting cardiac tumors.

Background

Primary cardiac tumors are observed in 0.0017–0.03% of unselected patients at autopsy (1, 2). Of these tumors, 10–25% are malignant. Secondary cardiac tumors are 20–40 times more common than primary ones. Although 10–25% of patients with terminal cancer display cardiac metastases, clinical evidence is scarce and pre-mortem diagnosis is unpredictable. Chondrosarcoma (CHS) is a primary malignant bone tumor that rarely metastasizes to the heart (3, 4, 5, 6, 7). It is a rare oncologic tumor most commonly found in the lower extremities – limb girdles, distal extremities, and trunk. It has already been reported that cardiac tumors may present with electrocardiogram (ECG) changes, mimicking myocardial infarction (MI).

Case presentation

A 74-year-old male was admitted in the emergency room for chest and epigastric pain radiating to the left arm

and lasting for 3 h. He had a known diagnosis of CHS of the right arm with metastasis to the lungs. Following amputation of the right arm, the patient was treated with cytostatic drugs for palliative purposes. He suffered from chronic obstructive pulmonary disease.

Investigation

ECG demonstrated ST elevation in the precordial leads (V1 trough V5) and right bundle branch block (Fig. 1A); cardiac enzymes were abnormal with a mild increase in troponin T levels, 0.07 µg/dl (normal range <0.03); moreover, the patient displayed mild anemia (hemoglobin 10 mg/dl, hematocrit 27%, red blood cell count $3.0 \times 10^6/\text{mm}^3$, and total iron 17 mg/dl) and a leukocytosis ($16.4 \times 10^3/\text{mm}^3$). An ST elevation MI (STEMI) was diagnosed and the patient was admitted to a tertiary care hospital for a primary angioplasty. The angiography showed a 50% stenosis of the left anterior descending coronary artery, while the right coronary and the

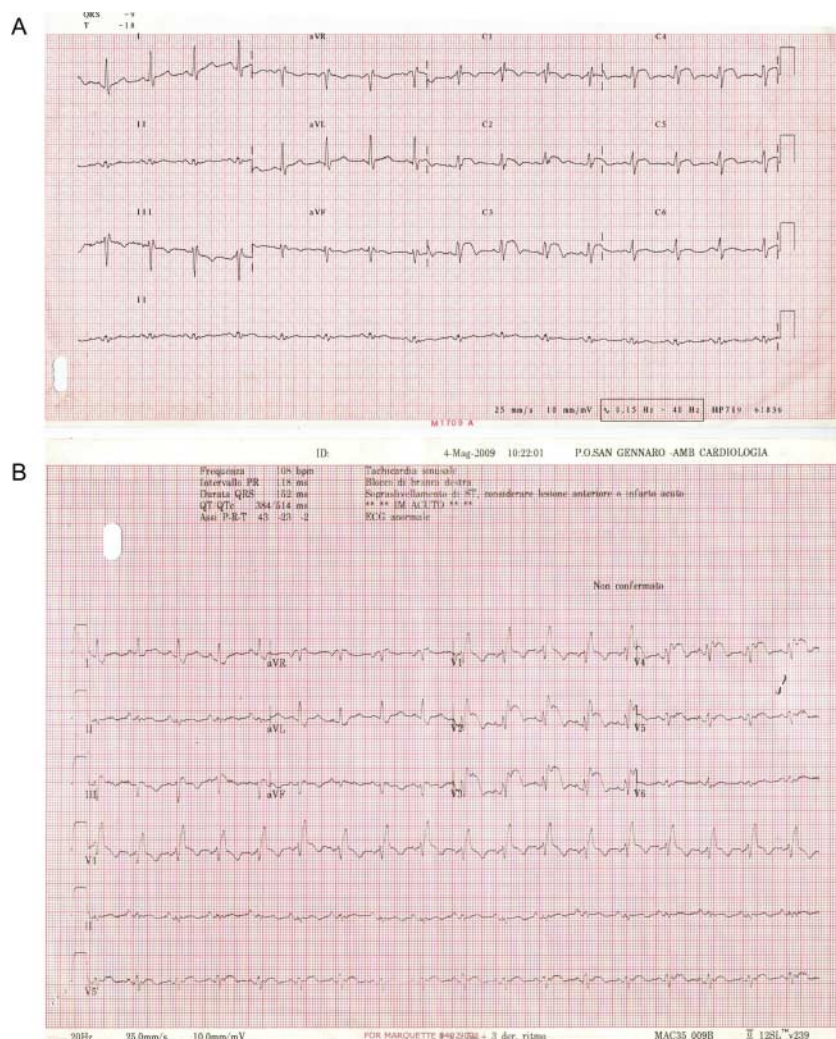


Figure 1
Electrocardiography. (A) ST elevation in precordial leads from V1 to V5 and the right bundle branch block. (B) Increase in elevation in precordial leads.

circumflex arteries only displayed mild atherosclerosis. The patient was discharged the following day with a diagnosis of acute coronary syndrome and with the suggestion of performing an echocardiogram (TTE). He underwent TTE that showed normal left ventricular size and function with mild left ventricular diastolic dysfunction, mild sclerosis of aortic and mitral valve leaflets, mild left atrium dilation, and normal right ventricle. ECG showed persistent ST elevation in precordial leads. A chest computed tomography (CT) scan was then performed, which showed multiple metastases of the lung. No mention of heart architecture and function was reported.

Treatment and outcome

One month later, during a routine oncologic checkup, an ECG was performed, which showed a further increase in ST

elevation in the precordial leads (Fig. 1B). The patient was then referred for another TTE that displayed the following findings: dilation of the right ventricle with a large, nonhomogeneous, echo-dense mass infiltrating the diaphragmatic wall and occupying most of the apical right ventricular cavity (Fig. 2). Its shape was multilobulated with well-defined margins. The mass extended from the base to the right ventricular apex. The contraction of the apical segment of the interventricular septum was reduced, presumably due to tumor infiltration. The whole myocardial apex showed an increase in echogenicity. There was mild tricuspid regurgitation with mild pulmonary hypertension. The TTE also showed normal left ventricular size and global function with mild diastolic dysfunction, mild sclerosis of aortic and mitral valve leaflets, mild left atrium dilation, and mild mitral regurgitation.

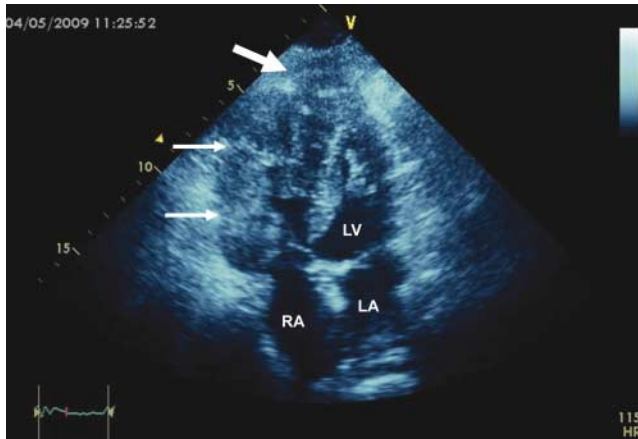


Figure 2
Transthoracic echocardiography: apical four-chamber view; presence of a large, nonhomogeneous mass infiltrating the diaphragmatic wall occupying the most of the apical right ventricular cavity can be observed. Its shape was multilobulated and its margins were defined. The entire whole myocardial apex showed an increase in echogenicity. Thin arrows: the right apical ventricle cavity is almost completely obliterated; mass involving right ventricular wall; thick arrow: mass involving the cardiac apex. ra, right atrium; la, left atrium; lv, left ventricle; details in the text.

On the basis of this apparently novel finding, we then re-reviewed the previous chest CT scan, which in fact revealed a hypodense, irregular, large nonhomogeneous right ventricular mass (Fig. 3) that appeared to infiltrate not only the right ventricular wall but also the apex and the interventricular septum.

Discussion

Primary cardiac tumors are observed in 0.0017–0.03% of unselected patients at autopsy (1, 2). Of these tumors, 10–25% are malignant. Secondary cardiac tumors are 20–40 times more common than the primary ones. Although 10–25% of patients with terminal cancer display cardiac metastases, clinical evidence is scarce and pre-mortem diagnosis is unpredictable. CHS is a primary malignant bone tumor that rarely metastasizes to the heart (3, 4, 5, 6, 7). It is a rare oncologic tumor most commonly found in the lower extremities – limb girdles, distal extremities, and trunk. To our knowledge, only 21 cases of cardiac metastasis have been described in the literature. A lesion in the right atrium is the most frequent finding, and just a single case of CHS metastatic to the right ventricle has been reported. The major risk with these tumors is their risk of embolic potential: pulmonary embolism for metastases of the right side and systemic embolism for metastases of the left side of the heart. The technique of choice in detecting cardiac masses is TTE examination (8). TTE is the initial technique

and most often can establish the diagnosis as well as specify the location and extent of the tumor.

In difficult cases and to better assess the morphological pattern, a transesophageal echocardiography (TEE) may be required. Most physicians consider TEE as the method of choice for optimal visualization of heart morphology (8). TEE was not performed in our patient due to adequate acoustic windows and because of the poor condition of the patient. Cardiac magnetic resonance imaging (MRI) has, in recent years, emerged as an excellent tool in diagnosing space-occupying lesions within or in the proximity of the heart and has the advantage over CT of not including ionizing radiation or nephrotoxic contrast media (9). In this case, we did not perform MRI as a chest CT with contrast media had been performed already. A CT scan provides excellent resolution for defining these lesions and allows for a superior understanding of the geometric and spatial relationship with nearby anatomic structures.

It has already been reported that cardiac tumors may present with ECG changes, mimicking MI. Suggested mechanisms for these pseudo-infarction ECG patterns are continuous myocardial injury preventing formation of new cardiac cell membrane, stretched adjacent muscle fibers, inflammatory reaction, change in the transmembrane $\text{Na}^+ - \text{K}^+$ gradient, and transfer of K^+ from damaged tissue to the adjacent myocardium producing electropotential

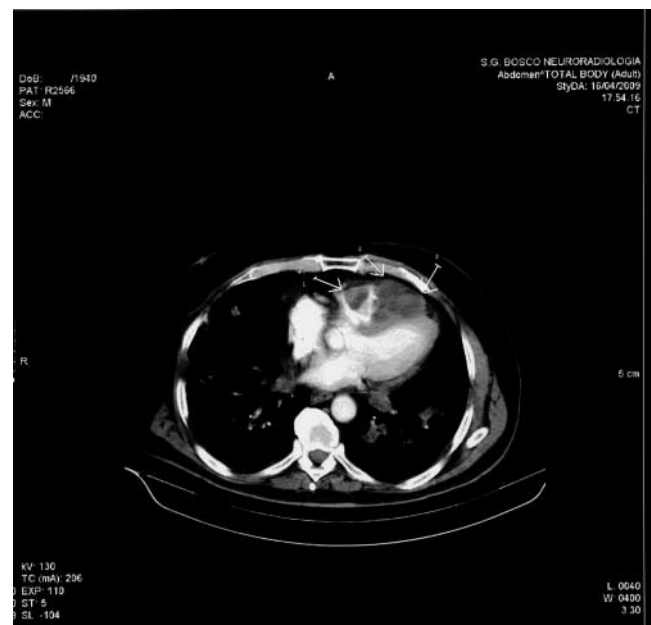


Figure 3
Chest computed tomography scan: hypodense, irregular, large nonhomogeneous right ventricular mass, which appeared to infiltrate not only the right ventricular wall (thin arrows) but also the apex (thick arrow) and the interventricular septum.

differences (10). In this case, the ECG changes may have been related to an involvement of apex and interventricular septum; although the tumor mainly infiltrated the right ventricle, the apex and the interventricular septum were also involved and probably induced the observed ECG changes. In turn, such an ECG pattern was associated with chest pain and a mild increase in cardiac biomarkers, mimicking an acute coronary syndrome, and TTE should be able to solve the diagnostic dilemma, but in this case, it was not detected by the first TTE; a retrospective review of the initial TTE did demonstrate an infiltrative mass involving the right ventricle and highlights the importance of careful evaluation of the right ventricle.

There was a mild increase in troponin T levels, but, as has been reported previously, an increase in this biomarker may stem from many causes.

While the initial CT scan report that did not mention the underlying cardiac abnormality did not change the clinical course of the disease, it does illustrate that experience in interpreting cardiac abnormalities on CT imaging is important. Owing to this guarded prognosis, we did not advise surgery and the patient was placed on cytostatic therapy for palliative purposes. The prognosis is poor, although surgery has been shown to increase the survival of patients with isolated cardiac metastases in other settings.

In conclusion, our case underlines the importance of a comprehensive examination of the heart by TTE, especially in oncologic patients with unusual ECG changes. Even though it is well known that cardiac tumors may present ECG changes mimicking MI, it has been considered that this is the first report demonstrating a metastatic CHS presenting as a mimicker of MI. Angiography and ventriculography were not able to detect the tumor. Further ST elevation led to serial echocardiography that established the diagnosis and review of the previous CT scan that was performed for oncological purposes, which further clarified the extent. We underline the importance of performing TTE in the clinical setting of MI management, when the etiology may be in question or when cardiac tumors are suspected.

Declaration of interest

The authors declare that there is no conflict of interest that could be perceived as prejudicing the impartiality of the work reported.

Funding

This research did not receive any specific grant from any funding agency in the public, commercial or not-for-profit sector.

Patient consent

The patient is deceased.

Author contribution statement

S Di Michele, F Mirabelli, D Galzerano, and S Mankad collaborated in interpreting the investigation, and wrote, reviewed, and submitted the manuscript. D Galzerano visited the patient, and was the physician responsible for the patient.

References

- Centofanti P, Di Rosa E, Deorsola L, Dato GM, Patanè F, La Torre M, Barbato L, Verzini A, Fortunato G & di Summa M 1999 Primary cardiac tumors: early and late results of surgical treatment in 91 patients. *Annals of Thoracic Surgery* **68** 1236–1241. (doi:10.1016/S0003-4975(99)00700-6)
- Neragi-Miandoab S, Kim J & Vlahakes GJ 2007 Malignant tumours of the heart: a review of tumour type, diagnosis and therapy. *Clinical Oncology* **19** 748–756. (doi:10.1016/j.clon.2007.06.009)
- Harting MT, Messner GN, Gregoric ID & Frazier OH 2004 Sarcoma metastatic to the right ventricle. Surgical intervention followed by prolonged survival. *Texas Heart Institute Journal* **31** 93–95.
- Cordioli E, Pizzi C & Bugiardini R 1999 Left ventricular metastasis from uterine leiomyosarcoma. *Cardiologia* **44** 1001–1003.
- Geyer HL & Karlin N 2010 Extraskelatal myxoid chondrosarcoma of the heart and review of current literature. *Current Oncology* **17** 58–62.
- Banfic L, Jelic I, Jelasic D & CuZic S 2001 Heart metastasis of extraskelatal myxoid chondrosarcoma. *Croatian Medical Journal* **42** 199–202.
- Leung CY, Cummings RG, Reimer KA & Lowe JE 1988 Chondrosarcoma metastatic to the heart. *Annals of Thoracic Surgery* **45** 291–295. (doi:10.1016/S0003-4975(10)62465-4)
- Peters PJ & Reinhardt S 2006 The echocardiographic evaluation of intracardiac masses: a review. *Journal of the American Society of Echocardiography* **19** 230–240. (doi:10.1016/j.echo.2005.10.015)
- Restrepo CS, Largoza A, Lemos DF, Diethelm L, Koshy P, Castillo P, Gomez R, Moncada R & Pandit M 2005 CT and MR imaging findings of malignant cardiac tumors. *Current Problems in Diagnostic Radiology* **34** 1–11. (doi:10.1067/j.cpradiol.2004.10.003)
- Nakamura A, Suchi T & Mizuno Y 1975 The effect of malignant neoplasms on the heart. A study on the electrocardiographic abnormalities and the anatomical findings in cases with and without cardiac involvement. *Japanese Circulation Journal* **39** 531–542. (doi:10.1253/cj.39.531)

Received in final form 30 August 2014

Accepted 13 October 2014