



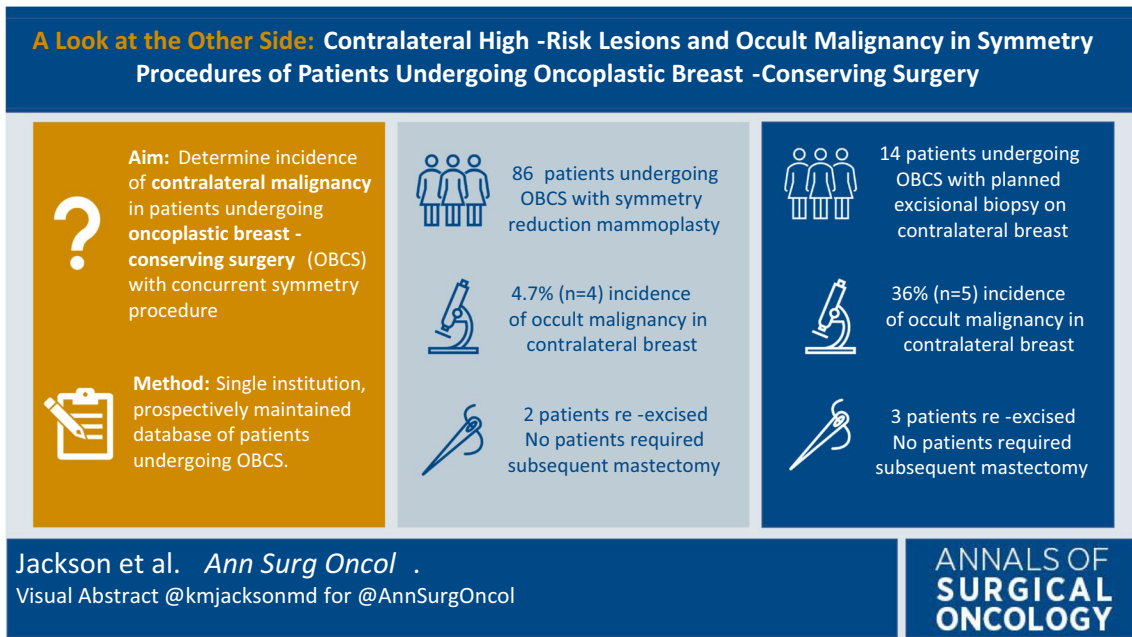
ASO Visual Abstract: A Look at the Other Side—High-Risk Lesions and Occult Contralateral Malignancy in Symmetry Procedures of Patients Undergoing Oncoplastic Breast-Conserving Surgery

Katherine M. Jackson, MD¹ , Janelle-Cheri Millen, MB, BS¹, Javier I. J. Orozco, MD¹, Stacey L. Stern, MS², Crystal E. Fancher, MD¹, and Janie G. Grumley, MD¹

¹Department of Surgical Oncology, Providence Saint John's Cancer Institute, Santa Monica, CA; ²Department of Statistics, Providence Saint John's Cancer Institute, Santa Monica, CA

In our study (<https://doi.org/10.1245/s10434-023-13894-6>), the frequency of incidental, contralateral malignancy in patients with unilateral cancer undergoing oncoplastic, breast-conserving surgery with a symmetry

procedure approached 5%. With routine orientation of all specimens, margins and tumor location can be accurately assessed, and mastectomy may be avoided.



DISCLOSURE The authors have no conflicts of interest or disclosures.

Publisher's Note Springer Nature remains neutral with regard to jurisdictional claims in published maps and institutional affiliations.