

RESEARCH

Open Access



Sonographic findings of thoracic empyema: outcome perspectives

Ahmad Mohamed Said¹, Saad R. Samra¹, Karim M. Al Fakhary² and Ashraf E. Sileem^{1*} 

Abstract

Background: Despite advances in antimicrobial therapy and a range of drainage techniques for the infected pleural area, thoracic empyema continues to be a serious reason behind morbidity and mortality. Although chest ultrasonography has been found to be an efficient diagnostic tool for pleural effusion features, it is rarely utilized to predict the outcomes of pleural illnesses.

Aim of the work: To determine the impact of sonographic patterns in predicting the outcomes of thoracic empyema patients.

Patients and methods: In this retrospective study, patients were divided into four groups based on their sonographic patterns: (I) complex non-septated effusions (plankton sign), (II) complex fixed septated effusions, (III) complex mobile septated effusions, and (IV) homogeneously echogenic effusions (hematocrit sign). These sonographic patterns were compared to the patients' co-morbidities, length of stay in the hospital, chest tube drainage, and medicinal or surgical therapy effectiveness.

Results: In comparison with other sonographic pattern groups, patients in group I (70.6%) and group IV (45.5%) had effective thoracic tube drainage with a very high statistically significant difference (P value < 0.001). For patients in group II (75%) (P value < 0.001), open thoracotomy was a very highly significant effective therapy (P value 0.001).

Conclusion: The sonographic pattern of thoracic empyema is a useful tool for guiding treatment decisions in these patients.

Keywords: Chest ultrasonography, Thoracic empyema, Tube drainage, Medical thoracoscopy, Video-assisted thoracic surgery

Introduction

Pleural empyema is a condition in which pus accumulates in the pleural space and is associated with a 2–30% morbidity and death rate [1]. Patients are commonly seen by a doctor when their purulent process has progressed to the fibrinopurulent or chronic stage, which is still controversial. These people are typically subjected to various treatments and protracted hospitalization before their empyema is effectively managed [2]. Empyema can be treated by using chest tube drainage, medical

thoracoscopy, video-assisted thoracic surgery (VATS), or thoracotomy with or without pleural fibrinolysis. Despite the fact that early intervention is universally recommended, there is still debate on the best management approach for multiloculated empyema, as well as when and how to intervene. Pleural shadowing determined by chest radiography or contrast-enhanced thoracic CT can be, in addition, described with pleural ultrasonography. Solid portions and septae can be separated from liquid loculations [3].

Even for assessing the diagnostic puncture of minor pleural effusions, chest ultrasonography is a safe, convenient, and fine approach. Transudative and exudative effusions can be amazing by using sonographic patterns

*Correspondence: sileem.ashraf@yahoo.com

¹ Chest Department, Faculty of Medicine, Zagazig University, Zagazig, Egypt
Full list of author information is available at the end of the article

of pleural effusions: a transudate is normally anechoic, whereas exudates can be anechoic, complicated (either complex septated constant or cell septae or complicated non-septated), or echogenic sample [4].

Pleural ultrasonography simply exceeds CT when it comes to figuring out an empyema. Based on the ultrasound pattern, a therapeutic method using pleural ultrasonography would possibly be devised. Ultrasonography would consequently be capable to stratify therapeutic modalities at the time of admission to the hospital, rather than numerous days later after a failed first-line treatment with chest tube drainage [5].

Thus, we analyzed the one-of-a-kind sonographic patterns of patients with thoracic empyema to examine its position in predicting thoracic empyema patients' outcomes.

Patients and methods

This retrospective cohort study included 72 thoracic empyema patients (42 adult males and 30 females with a mean age of 43.1 ± 13.3), who had been previously admitted to the Chest Department, Zagazig University Hospitals, within the period between April 2018 and October 2019. The study was once approved by the institutional review board of the hospital (ZU-IRB #9235-2-1-2018).

Inclusion criteria

Patients enrolled in this study had thoracic empyema retrospectively which was described as frank pus on thoracentesis with or without positive smear and bacteriologic culture findings, or pH < 7.2 with signs of infection [6]. The patients' data were estimated and reviewed carefully from their previous hospital medical records.

Exclusion criteria

Patients were excluded if thoracic empyema was caused by any invasive procedure, such as trauma or surgery. Moreover, the patients who had unfulfilled medical records were excluded.

On the first day of hospitalization, full medical history with laboratory investigations and plain chest radiographs were recorded from the files, and most of the patients additionally underwent contrast-enhanced thoracic computed tomography (CT). Transthoracic ultrasonography with sonar-guided thoracentesis was executed for all patients retrospectively, after having their consent, through Sonoscape SSI 4000 color Doppler ultrasound machine with (3.5 to 5.0 MHz) curvilinear or phased array probe in supine or sitting position, with the transducer scanning through the intercostal space. The aspirated fluid samples were collected below aseptic conditions and dispatched for biochemical examination and

were cultured for each aerobic and anaerobic microorganisms [7].

We evaluated the echogenicity of the empyema from the recorded sonographic guided thoracentesis pattern.

The classification of sonographic patterns

The recorded findings of chest ultrasonography patterns for all 72 enrolled patients were classified into four groups (Fig. 1) as follows: group I (17 patients)—complex non-septated and exceedingly hyperechoic pattern, with hyperechoic swirling debris deposited inside the effusion and agitated by using cardiac or respiratory movement in a pleural effusion (plankton sign); group II (14 patients)—complex fixed septated effusion, the place the fibrous bands were fixed inside the effusion; group III (19 patients)—complex mobile septated effusion, where the septa were mobile with undulating moves inside the anechoic pleural space; and group IV (22 patients)—homogeneously echogenic pattern, with echogenic spot density in the pleural fluid. This exceedingly cellular fluid obviously created a layering effect by means of gravity (hematocrit sign) (Fig. 2) [4, 8].

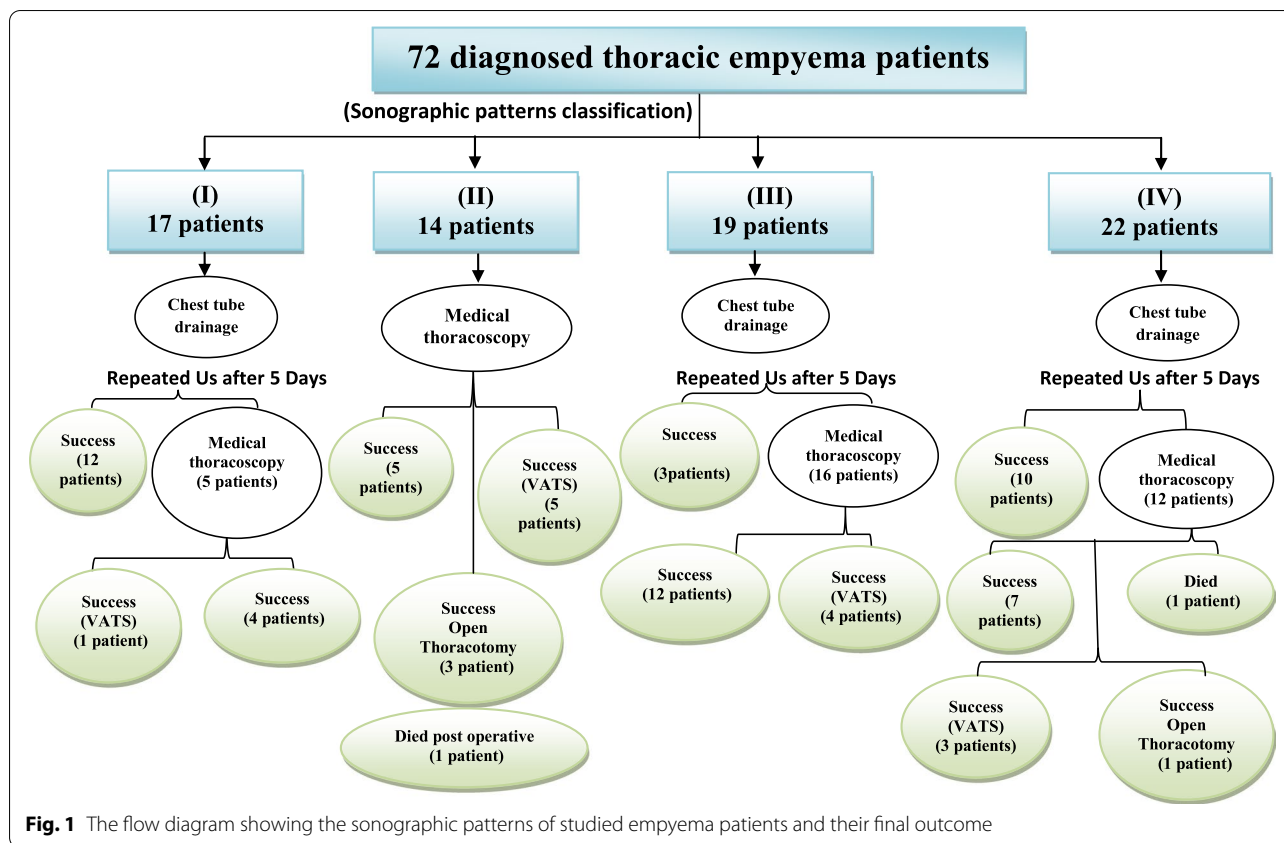
A third-generation cephalosporin plus metronidazole or beta-lactam/beta-lactamase inhibitor combinations antibiotics were prescribed from the start for all patients in this study. Antimicrobial therapy for hospital-acquired empyema should be the focal point for covering methicillin-resistant *Staphylococcus aureus* and *Pseudomonas*. Vancomycin, metronidazole, and antipseudomonal cephalosporin were real-looking alternatives. Intravenous antibiotic therapy was frequently suitable at first; however, when objective clinical (e.g., temperature) and biochemical (e.g., C-reactive protein) improvement was established, the administration route was changed to oral. Antibiotic therapy had to be continued for 2 to 6 weeks, depending on the severity of the infection and the clinical response to the remedy [9].

Tube thoracotomy

Our patients with empyema underwent standard tube thoracotomy, unless there were fixed septated effusions with the aid of chest ultrasonography (group II) in only fourteen patients who withstood medical thoracoscopy with fibrinolytic therapy directly.

Reevaluation was done for our patients on the fifth day by chest radiography and ultrasonography.

Tube thoracotomy was viewed as a successful method when a chest radiograph indicated improved lung expansion and the tube had to be removed when there was no drain or modifications of the fluid into serious effusion. When there is radiological proof of loculated effusion with poor drainage, medical thoracoscopy is done.



Medical thoracoscopy

Thoracoscopy is used to be carried out in our endoscopic unit with the services of ultrasonography. With the empyema facet up and the arm over the head, the patient is positioned in a lateral or dead lateral decubitus position. Throughout the procedure, the patient's vitals and oxygen saturation were continuously monitored. Thoracoscopy was performed in the lateral decubitus position with 1% lidocaine local anesthesia and analogue sedation with midazolam and pethidine or morphine. Under ultrasonographic guidance, a 1.5-cm incision was made, and a 10-mm trocar was introduced into the proper intercostal space. A 0° optical telescope was inserted and connected to a videotape camera and monitor. The pleura was examined carefully using a thoracoscope (KarlStorz, Germany) and supplementary CO₂ insufflations if needed. All pleural fluid was suctioned out, and the pleural cavity was closely examined. Fibrinous septae were dissected and removed with straight Maryland forceps. The pleural cavity was irrigated with saline, and the fluid and fibrinopurulent material were aspirated and removed from the cavity. A drain (30 to 32 F) was introduced at the end of the procedure and connected to underwater seal suction with a negative pressure suction of 20 cm H₂O. When there was no more drainage and the

chest X-ray improved, the tube was withdrawn. After the procedure, all patients were given IV antibiotics for at least one week [10].

Treatment success was defined as survival without the need for further surgical interventions.

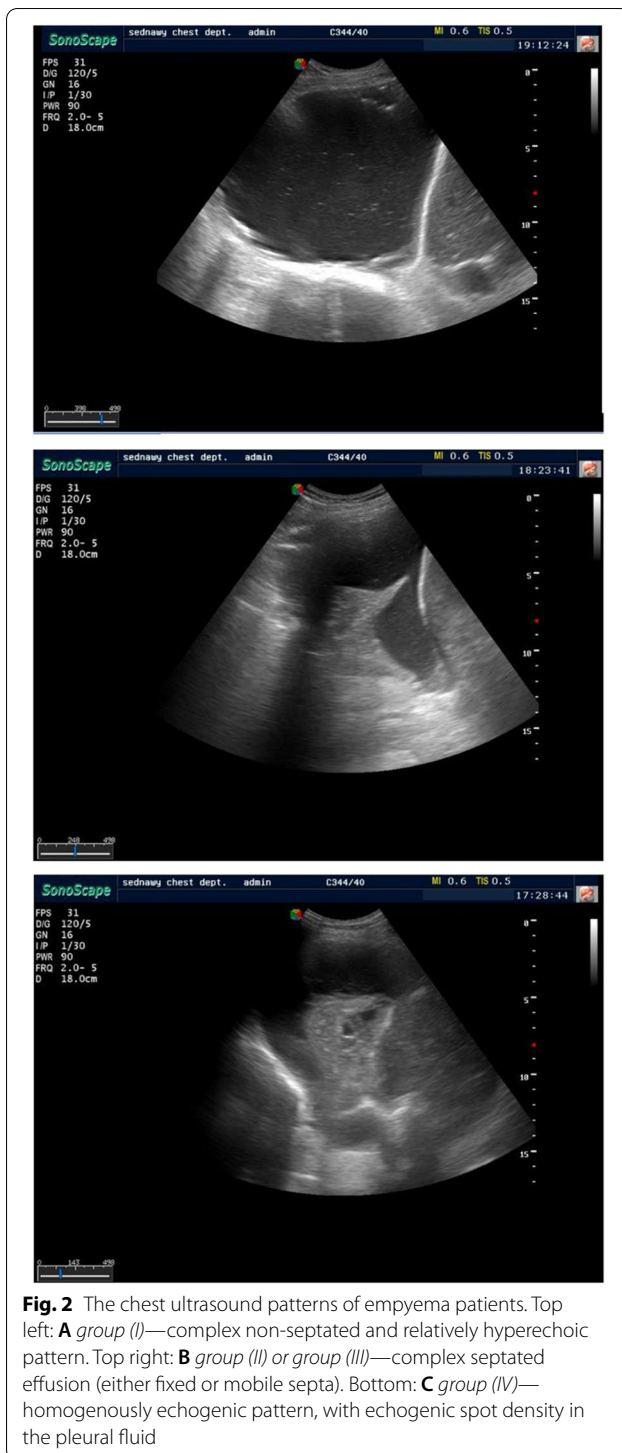Chemical fibrinolysis after medical thoracoscopy

After 24 h of medical thoracoscopy, 250,000 IU of streptokinase was diluted in 100 cc saline and 20 cc lidocaine 1% and injected through the chest tube once daily then the tube was clamped for 6 h. The process was repeated for 3 consecutive days [11].

Surgical procedures (VATS or open thoracotomy)

The thickened pleural peel was found in 13 patients by medical thoracoscopy, so video-assisted thoracoscopic surgical operation (VATS) was carried out on them (Fig. 1).

VATS was performed with a patient in lateral decubitus position under general anesthesia and single lung ventilation. Three incisions were made in a triangular configuration for the camera and instruments. A lysis of all adhesions creating the pleural area into one cavity was done. Decortication of the lung and a generous wash of the pleural cavity with saline were carried out, and then



two pleural drains related to an underwater seal were once inserted after confirmation of lung expansion [12].

Five patients were presented with multiple loculations and extreme adhesions in the pleural cavity through medical thoracoscopy, so these patients underwent open

thoracotomy for further decortication and drainage while attaining full lung expansion.

Outcomes

The perioperative mortality was defined as patients who died due to causes related to the empyema or the operative complications, while profitable strategies were defined as the improvement of empyema with no need for additional intervention [2].

The principal outcomes that we examined in our findings have succeeded or failed procedures and/or in-hospital mortality of cases. Regarding the recorded chest sonographic findings, duration of chest tube insertion with or barring intra-pleural fibrinolytic therapy and surgical interventions were encountered and analysed. In addition, the length of stay in the hospital was once reviewed as a secondary outcome.

Statistical analysis

The data were collected and analyzed using the commercial Statistical Package for Social Sciences, version 25. Tables were used for existing data such as frequencies, proportions, mean, and standard deviation (SD). Independent samples of Student's *t*-test and one-way analysis of variance were used, as appropriate, for quantitative data. The chi-square test and Fisher's exact test were used to analyze the categorical variables. All outcomes were assessed to be statistically significant when a value of $P \leq 0.05$.

Results

Table 1 summarizes the demographic characteristics of the four sonographic groups that enrolled in this study with no significant statistical difference between them. The majority of studied patients were males (58.3%) and the most frequent underlying comorbidity was hypertension (25%) followed by diabetes mellitus (23.6%).

In 58 of 72 patients (80.6%), positive bacteriological results were detected. The most frequent isolated pathogenic bacteria were gram-negative germs (34.7%) followed by mixed organisms (22.2%) as shown in Table 2.

The mean hospital stay (16.6 ± 6.9) and the mean period of chest tube drainage (9.2 ± 5.4) of the patients with complex non-septated sample (group I) were shorter than those with different sonographic sample groups with high statistical differences between them (Table 3).

Patients with complex non-septated pattern (group I) (70.6%) followed by those with homogeneously echogenic pattern (group IV) (45.5%) underwent successful thoracic tube drainage in relation to other sonographic

Table 1 The demographic characteristics of patients with different sonographic groups

	Group I (17)	Group II (14)	Group III (19)	Group IV (22)	Total (72)	P value
Age						
Mean \pm SD	41.3 \pm 15.9	47.9 \pm 11.7	42.6 \pm 13.3	41.8 \pm 12.2	43.1 \pm 13.3	0.5
Sex, No. (%)						
Male	10 (58.8%)	9 (64.3%)	11 (57.9%)	12 (54.5%)	42 (58.3%)	0.95
Female	7 (41.2%)	5 (35.7%)	8 (42.1%)	10 (45.5%)	30 (41.7%)	
Comorbidities						
No	8 (47.1%)	3 (21.4%)	11 (57.9%)	12 (54.5%)	34 (47.2%)	0.17
DM	4 (23.5%)	5 (35.7%)	3 (15.8%)	5 (22.7%)	17 (23.6%)	0.62
HPN	4 (23.5%)	5 (35.7%)	4 (21.1%)	5 (22.7%)	18 (25.0%)	0.78
IHD	1 (5.9%)	2 (14.3%)	0 (0.0%)	1 (4.5%)	4 (5.6%)	0.36
COPD	2 (11.8%)	2 (14.3%)	0 (0.0%)	1 (4.5%)	4 (5.6%)	0.34
Malignancy	1 (5.9%)	0 (0.0%)	0 (0.0%)	1 (4.5%)	2 (2.8%)	0.61
Liver disease	0 (0.0%)	1 (7.1%)	3 (15.8%)	1 (4.5%)	4 (2.8%)	0.29
Renal disease	0 (0.0%)	1 (7.1%)	1 (5.3%)	2 (4.5%)	4 (2.8%)	0.66

patterns with very high statistically significant difference (P value $<$ 0.001), while surgical thoracotomy was more frequently used in complex fixed septated effusion patients (group II) (21.4%) than it was used with other sonographic pattern groups with statistically significant difference (P value $<$ 0.05) as shown in Table 3. There were 2 patients died in this study, one of them in group II (7.1%) due to postoperative persistent hemorrhage and the other one in group IV (4.2%) by septic shock (Table 3).

Table 4 clarified that the tube drainage was hugely a successful management in group I patients (44.4%) in relation to the other therapeutic modalities of thoracic empyema (P value = 0.006), while the open thoracotomy proved its effectiveness in patients with complex fixed septated effusion pattern (group II) (75%) (P value $<$ 0.001). Medical thoracoscopy with fibrinolytic therapy was a remarkably effective therapeutic modality in patients with complex mobile septated effusion pattern (group III) (46.2%).

Table 2 Bacteriological results of pleural effusions in different sonographic groups

Type of germs	Group I (17), no. (%)	Group II (14), no. (%)	Group III (19), no. (%)	Group IV (22), no. (%)	Total (72), no. (%)
Gram-positive	2 (11.8%)	2 (14.3%)	0 (0.0%)	3 (13.6%)	7 (9.7%)
Gram-negative	5 (29.4%)	6 (42.9%)	8 (42.1%)	6 (37.3%)	25 (34.7%)
Mixed germs	4 (23.5%)	2 (14.3%)	5 (26.3%)	5 (22.7%)	16 (22.2%)
Anaerobic germs	2 (11.8%)	0 (0.0%)	4 (21.1%)	4 (18.2%)	10 (13.9%)
No germs identified	4 (23.5%)	4 (28.6%)	2 (10.5%)	4 (18.2%)	14 (19.4%)

Table 3 Clinical course, treatment, and outcomes for thoracic empyema in different sonographic groups

	Group I (17)	Group II (14)	Group III (19)	Group IV (22)	Total (72)	P value
Hospital stay (days), mean \pm SD	16.6 \pm 6.9	25.4 \pm 7.2	23.6 \pm 4.9	21.7 \pm 6.5	21.7 \pm 7.0	0.002*
Duration of chest tube drainage (days), mean \pm SD	9.2 \pm 5.4	15.4 \pm 4.8	13.6 \pm 3.4	11.8 \pm 5.9	12.4 \pm 5.3	0.012*
Tube drainage, no. (%)	12 (70.6%)	0 (0%)	3 (15.8%)	10 (45.5%)	25 (34.7%)	$<$ 0.001*
Medical thoracoscopy, no. (%)	4 (23.5%)	5 (35.7%)	12 (63.2%)	7 (31.8%)	28 (38.3%)	0.7
VATS, no. (%)	1 (5.9%)	5 (35.7%)	4 (21.1%)	3 (13.6%)	13 (18.1%)	0.2
Surgical thoracotomy, no. (%)	0 (0%)	3 (21.4%)	0 (0%)	1 (4.5%)	4 (5.6%)	0.03*
Mortality, no. (%)	0 (0%)	1 (7.1%)	0 (0%)	1 (4.5%)	2 (2.8%)	0.5

* means significant

Discussion

Thoracic empyema is a long-standing condition that remains a large clinical issue. Despite advances in antimicrobial remedies and a variety of drainage methods for the contaminated pleural area, thoracic empyema continues to be a cause of morbidity and mortality [13].

Although chest ultrasonography has been found to be a high-quality diagnostic device for pleural effusion features, it is hardly ever utilized to predict the results of pleural illnesses [14]. Increased septations as measured with the aid of thoracic US may be predictive of medical outcomes, according to only two researches [3, 5].

In the current study, the demographic characteristics of the 4 sonographic groups that enrolled in this study were clarified with no significant statistical distinction between them, and the majority of studied patients were males as shown in Table 1. This is in agreement with both studies that classified their patients in accordance with sonographic patterns in merely two groups (septated and non-septated) with no significant statistical distinction between them involving the demographic traits and the majority of patients were adult males [3, 5].

In thoracic empyema, antibiotic therapy is commenced empirically, apart from the fact that the choice of antibiotics primarily has to be based on culture. In the current study, the initial empirical antibiotics were in concordance with the subsequent bacteriological results as shown in Table 2.

The majority of patients with thoracic empyema, whether or not suspected or proven, were treated with broad-spectrum antibiotics. Antibiotics needed to be adjusted to target infections depending on epidemiology, antibiotic resistance patterns, the supply of infection, and whether or not the patients were from the community or a healthcare facility. The most usually reported organism was *Staphylococcus aureus*. The most usually reported isolates from tropical and temperate locations were respectively pneumococci and viridians streptococci. The microbiological pattern differed substantially between community and hospital-acquired infections, with hospital-acquired illness reporting more gram-negative and drug-resistant isolates [15].

In this study, in 14 of 72 sufferers (19.4%), sterile cultures were detected (Table 2). These outcomes are in agreement with Pilav et al. [16] that 24% (24/100) of cases had poor results. The use of antibiotics prior to admission to the chest department or the technical mistakes in the collection and storage of sample material can be the purpose of bad microbiologic results.

The current study, in concordance with much other research [17–19], highlighted that aerobic gram and micro-organisms emerged as the most frequent pathogens in empyema (34.7%) as shown in (Table 2).

The hazard of empyema was accelerated via a variety of a number of concomitant illnesses that change systemic or local pulmonary host defenses, such as cancer and chronic obstructive pulmonary disease [20]. Gram-negative bacterial infection of the pleural space was linked to a higher incidence of underlying illness in the current study.

Brutsche et al. [21] enrolled 216 patients of empyema between 2000 and 2003; most of them were successfully treated by simple drainage (75%). In case of multiloculated disease, either medical thoracoscopy (15%) or surgical VATS/thoracotomy with pleurectomy (11%) was performed. While in the current study, successful treatment was provided by tube drainage (34.7%), medical thoracoscopy (38.3%), VATS (18.1%), and open thoracotomy (5.6%) as shown in (Table 3). The difference in successful treatment modalities can be diagnosed by early detection and intervention of empyema in Brutsche et al. [21] study, as they were concerned with hospitalized pneumonia patients.

Two deaths were recorded (2.8%) in this study, one of them in group II due to postoperative chronic hemorrhage and the other one in group IV by way of septic shock with no significant distinction between the other studied groups, while Chen et al. [3] reported 22 deaths (13.5%) out of 163 patients (11% in septated and 16% in non-septated groups); however, no patient who underwent surgical intervention died. Vaziri and Abed [2] announced that there was no intra-operative death and 12 of 112 patients (10.7%) died in the hospital which included one patient who had undergone thoracotomy. Surgical complications included significant air leak in

Table 4 Successful outcome of thoracic empyema in relation to different sonographic patterns

	Success tube drainage (no. = 25)	Success medical thoracoscopy (no. = 28)	Success VATs (no. = 13)	Success open thoracotomy (no. = 4)	P value
Group I, no. (%)	12 (44.4%)	4 (15.4%)	1 (7.7%)	0 (0%)	0.006*
Group II, no. (%)	0 (0%)	5 (19.2%)	5 (38.5%)	3 (75%)	< 0.001*
Group III, no. (%)	3 (11.1%)	12 (46.2%)	4 (30.8%)	0 (0%)	0.04*
Group IV, no. (%)	10 (37%)	7 (26.9%)	3 (23.1%)	1 (25%)	0.6

* means significant

two patients, persistent hemorrhage (> 400 ml/day over 3 days) in one patient in the VATS group and wound infection required local debridement and drainage in one patient.

This study is considered the first one to classify thoracic empyema into 4 groups in accordance with its sonographic appearance. Implementations of this classification in the management of thoracic empyema add on value to the most useful interventions in those patients; tube drainage, clinical thoracoscopy with fibrinolytic therapy and open thoracotomy, which correlate significantly with a successful outcome in different groups (*P* value 0.006, 0.04, and < 0.001, respectively) as shown in (Table 4). Chen et al. [3] sonographically classified the empyema into septated and non-septated groups. Their study reported that the non-septated group showed significantly shorter hospital stay and mean duration of chest tube drainage in agreement with the current result (*P* value 0.002 and 0.012, respectively), taking into consideration the non-septated group presented as groups I and IV (Table 3). Overall patients in groups I and IV were 39, 33 patients (84.6%) of them successfully managed without surgical interventions [tube drainage (*P* value < 0.001) and medical thoracoscopy] and 6 patients (15.4%) needed further surgical procedures. The study of Ravaglia et al. [22] reported non-surgical successful management (medical thoracoscopy) of thoracic empyema in organized and free-flowing empyema (76.5%) and successful surgical management in 23.5%. The surgical interventions in these groups (I and IV) might be attributed to the presence of fibrous thickening of the pleura (pleural peel).

In complex fixed septated effusion patients (group II) and complex mobile septated effusion pattern (group III), which was previously classified as septated effusion, tube drainage was never initiated as a therapeutic option in group II while medical thoracoscopy with fibrinolytic therapy was the first therapeutic choice. In group III, chest tube drainage was used as a therapeutic option than medical thoracoscopy with fibrinolytic therapy. Overall patients in groups II and III were 33, 8 patients (24.2%) of them successfully managed without surgical interventions. This highlights the benefit of further division of septated empyema into fixed and mobile.

It was noted that the very small sample size of four groups may limit the findings, potentially lowering the data's reliability.

In conclusion, transthoracic ultrasonography is a safe, feasible bedside tool. The early interpretation and differentiation of the pattern of thoracic empyema can independently guide the therapeutic options.

Acknowledgements

Not applicable.

Authors' contributions

SA, SS, and SA all share in the conception, design of the work, acquisition, analysis, and interpretation of the data. AK shares in performing the surgical interventional sector of all patients. All authors read and approved the final manuscript.

Funding

No financial support or sponsorship.

Availability of data and materials

The databases used and analyzed during the current study are available from the corresponding author on reasonable request.

Declarations

Ethics approval and consent to participate

The study was approved by the ethical institutional review board of the hospital, Zagazig University Faculty of Medicine (ZU-IRB #9235-2-1-2018). A written informed consent was obtained from all participants. The reference number is not available.

Consent for publication

Not applicable.

Competing interests

The authors declare that they have no competing interests.

Author details

¹Chest Department, Faculty of Medicine, Zagazig University, Zagazig, Egypt.

²Cardiothoracic Surgery Department, Zagazig University, Zagazig, Egypt.

Received: 2 March 2022 Accepted: 2 June 2022

Published online: 18 June 2022

References

- Ferguson AD, Prescott RJ, Selkon JB, Watson D, Swinburn CR (1996) The clinical course and management of thoracic empyema. *QJM* 89:285–289
- Vaziri M, Abed O (2012) Management of thoracic empyema: review of 112 cases. *ActaMedicologica* 50(3):203–207
- Chen KY, Liaw YS, Wang HC, Luh KT, Yang PC (2000) Sonographic septation: a useful prognostic indicator of acute thoracic empyema. *J Ultrasound Med* 19:837–843
- Tu CY, Hsu WH, Hsia TC, Chen HJ, Tsai KD, Hung CW, Shih CM (2004) Pleural effusions in febrile medical ICU patients: chest ultrasound study. *Chest* 126:1274–1280
- Chen CH, Chen W, Chen HJ, Yu YH, Lin YC, Tu CY et al (2009) Transthoracic ultrasonography in predicting the outcome of small-bore catheter drainage in empyemas or complicated parapneumonic effusions. *UltrasoundMed Biol* 35:1468–1474
- Davies CW, Gleeson FV, Davies RJ (2003) BTS guidelines for the management of pleural infection. *Thorax* 58(Suppl 2):ii18–ii28
- Miller JM, Holmes HT (1995) Specimen collection, transport, and storage. In: Murray PR, Baron EJ, Pfaller MA et al (eds) *Manual of clinical microbiology*, 6th edn. American Society for Microbiology, Washington, DC, p 299
- Mayo PH, Doelken P (2006) Pleural ultrasonography. *Clin Chest Med* 27(2006):215–227
- Higuchi M, Suzuki H (2020) Current status and prospect of medical and surgical management for thoracic empyema. *CurrChallThoracSurg* 2:39
- Sumalani KK, Rizvi NA, Asghar A (2018) Role of medical thoracoscopy in the management of multiloculated empyema. *BMC Pulm Med* 18(1):179. <https://doi.org/10.1186/s12890-018-0745-y> PMID: 30486876; PMCID: PMC6264615
- Abu-Daff S, Maziak DE, Alshehab D et al (2013) Intrapleural fibrinolytic therapy (IPFT) in loculated pleural effusions--analysis of predictors for failure of therapy and bleeding: a cohort study. *BMJ Open* 3(2):e001887. Published 2013 Jan 31. <https://doi.org/10.1136/bmjopen-2012-001887>

12. Hansen HJ, Petersen RH (2012) Video-assisted thoracoscopic lobectomy using a standardized three-port anterior approach - the Copenhagen experience. *Ann Cardiothorac Surg* 1(1):70–76
13. Maskell NA, Batt S, Hedley EL, Davies CW, Gillespie SH, Davies RJ (2006) The bacteriology of pleural infection by genetic and standard methods and its mortality significance. *Am J Respir Crit Care Med* 174:817–823
14. Shen KR, Bribriescio A, Crabtree T, Denlinger EJ, Eiken P, Jones DR, Keshavjee S, Maldonado F, Paul S, Kozower B (2017) The American Association for Thoracic Surgery consensus guidelines for the management of empyema. *J Thorac Cardiovasc Surg* 153:e129–e146
15. Hassan M, Cargill T, Harris E et al (2019) The microbiology of pleural infection in adults: a systematic review. *Eur Respir J* 54:1900542
16. Pilav I, Guska S, Musanovic S, Kadic K, Grbic K (2011) Pathogens of pleural empyema inpatients treated on the clinic for thoracic surgery of UKCS. *HealthMED*. 3(5):1344–1348
17. Mohanty S, Kapil A, Das BK (2007) Bacteriology of parapneumonic pleural effusions in an Indian hospital. *Trop Doct* 37(4):228–229
18. Gagreja D, Goel N, Aggarwal R, Chaudhary U (2011) Changing trend of antimicrobial resistance among gram-negative bacilli isolated from lower respiratory tract of ICU patients: a 5-year study, Indian. *J Crit Care Med* 15(3):164–167
19. Sonali J, Banavaliker JN (2013) Empyema thoracis: bacteriological analysis of pleural fluid from the largest chest hospital in Delhi. *IOSR J Dent Med Sci* 3(6):46–51
20. Porcel J, Vázquez P, Vives M, Nogués A, Falguera M, Manonelles A (2002) Pleural space infections: microbiologic and fluid characteristics in 84 patients. *Internet J Pulm Med* 3(1):1–5
21. Brutsche MH, Tassi GF, Gyorik S, Gokcimen M, Renard C, Marchetti G P, Tschopp JM (2005) Treatment of sonographically stratified multiloculated thoracic empyema by medical thoracoscopy. *CHEST* 128:3303–3309
22. Ravaglia C, Gurioli C, Tomassetti S, Casoni GL, Romagnoli M, Gurioli C, Agnoletti V, Poletti V (2012) Is medical thoracoscopy efficient in the management of multiloculated and organized thoracic empyema? *Respiration* 84:219–224

Publisher's Note

Springer Nature remains neutral with regard to jurisdictional claims in published maps and institutional affiliations.

Submit your manuscript to a SpringerOpen[®] journal and benefit from:

- Convenient online submission
- Rigorous peer review
- Open access: articles freely available online
- High visibility within the field
- Retaining the copyright to your article

Submit your next manuscript at ► [springeropen.com](https://www.springeropen.com)
