

ORIGINAL ARTICLE

Open Access



Modified perichondrial-periosteal flaps to camouflage nasal dorsum in rhinoplasty

Ahmed Gamal Khafagy^{1,2*} , Hesham Abdelaty El-Sersy¹ and Ahmed Mahmoud Maarouf¹

Abstract

Background: The smooth and straight nasal dorsum is a goal after nasal hump reduction as dorsal irregularities are unexpected and inevitable complications. The aim of this study is to evaluate modified perichondrial-periosteal flaps functionally and aesthetically to camouflage nasal dorsal irregularities. A total of 115 patients with nasal humps were enrolled in the study. The perichondrium over the upper lateral cartilages is divided in the midline and dissected forming two laterally based flaps while the periosteum over the nasal bones is dissected superiorly. After completion of all rhinoplasty steps, the flaps were repositioned and sutured as a separate layer. Follow-up for 2 years with an assessment of irregularities of the nasal dorsum, collapse of the upper lateral cartilage, and nasal breathing.

Results: Aesthetically, no nasal dorsal irregularities were noticed. Also, no patients complained of nasal obstruction.

Conclusion: The modified perichondrial-periosteal flap is a successful technique, functionally and aesthetically. It avoids the appearance of dorsal irregularities.

Keywords: Perichondrial periosteal flaps, Upper lateral cartilage, Nasal hump, Rhinoplasty, Camouflage nasal dorsum

Background

Since the complete development of open rhinoplasty by Padovan in 1966 [1], irregularities of the nasal dorsum especially at the transitional keystone area remain inevitable and unexpected even with the best hands [2]. Numerous techniques were devised and developed over decades to achieve smooth, straight, and naturally appeared dorsum of the nose with patent nasal airway [3].

Functionally and aesthetically, it is known that the keystone area is the most complex and difficult step in rhinoplasty, and it is crucial to preserve the attachment of the upper lateral cartilages (ULCs) to the overlying nasal bones at the end of the procedure [4].

At the keystone area, where the majority of deformities appear after rhinoplasty, the perichondrium and the periosteum covering the ULC and nasal bones, respectively, are worthy and valuable structures in nourishment

and covering the nasal dorsum and disguise minor irregularities that should appear [5, 6].

This study describes the dissection and elevation of triple flaps consisting of the perichondrium over the upper lateral cartilages and the periosteum over the nasal bones in 115 patients with a dorsal hump.

Methods

Study sample

A prospective study including 115 patients who underwent primary open rhinoplasty for nasal hump removal under general anaesthesia. The following patients were excluded from the study: age below 18 years, previous septoplasty or rhinoplasty, patients with a small hump of less than 3-mm reduction, and contact sport professional players such as boxers.

Follow-up of all patients for 2 years postoperatively with the assessment of the following: irregularities of the nasal dorsum, collapse of ULC, and nasal breathing.

* Correspondence: ahmedgamal_2489@yahoo.com

¹Otorhinolaryngology Department, Ain Shams University, Cairo, Egypt

²Magrabi Center, P.O. box: 23293 Doha, Qatar

Surgical technique (triple separated flaps technique)

All surgeries were performed by the senior first author. Loupe magnification was used in all patients from skin to skin. An inverted V shape incision was created in the columella and elongated into an infracartilagenous incision. Then, the middle vault and nasal dorsum are exposed by dissecting into the superficial musculoaponeurotic system preserving the perichondrium over ULCs and periosteum over the nasal bones (supraperichondrial and supraperiosteal dissection).

Then, meticulous dissection and elevation of the 3 flaps are as follows:

- a- Two laterally based perichondrial flaps on each side (inferiorly): A midline incision of the perichondrium covering the ULCs using a blade 15 was done from the caudal end of nasal bones to anterior septal angle (Fig. 1 A). Using a freer elevator, the firmly attached perichondrium over the right ULC was dissected (Fig. 1 B) and elevated laterally for 1 cm width forming the first flap (Fig. 1 C). The same was repeated with the perichondrium over the left ULC forming the second flap. Now, two inferior perichondrial flaps, each is laterally based, were created (Fig. 1 D).
- b- One superiorly based periosteal flap (superiorly) (Fig. 1 E): A transverse incision was made in the periosteum at the caudal edge of the nasal bones. The subperiosteal tunnel was done using Joseph elevator, the and periosteum was dissected carefully transversely from side to side with a slight upward

direction till the nasofrontal angle. Now, one superior periosteal flap (superiorly based) was created.

Excision and reduction of bony and cartilaginous hump were performed, and the remaining surgical steps such as osteotomies, spreader flaps, and grafts were fixed and completed. Then, the two perichondrial flaps were repositioned and sutured in the midline using 3 or 4 interrupted simple absorbable sutures (Fig. 1 F), while the periosteum was repositioned in its place without suturing it to perichondrium.

Profuse cleansing and washing of the nasal dorsum before and after stitching the perichondrium were done to clear small residues and tiny fragments of the bones and cartilages to avoid future irregularities.

Results

A total number of 115 patients were operated on with an average operating time of 160 min. There were 61 females and 54 males with ages ranging from 18 to 49 years. Throughout 2 years follow-up, we did not notice dorsal irregularities in all patients by inspection and palpation (Fig. 2). The nasal dorsum was smooth without deviations.

As regards nasal breathing, no patients complained of nasal obstruction.

Discussion

Hump reduction is a widely carried out procedure that can result in functional and aesthetic complications if

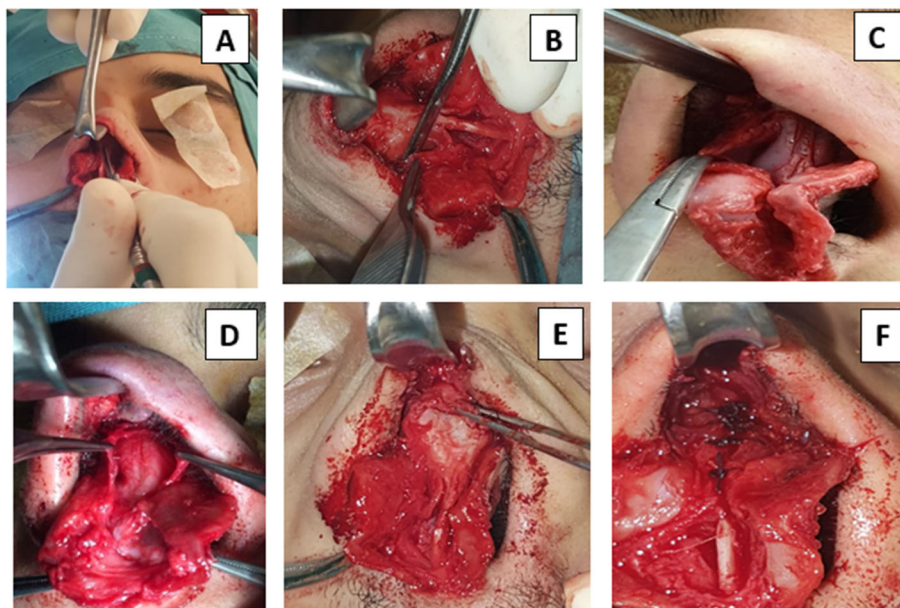


Fig. 1 Steps of modified perichondrio-periosteal flap. **A** Midline incision of the perichondrium. **B** Dissection of the perichondrium. **C** Right laterally based perichondrial flap. **D** Right and left elevated perichondrial flap. **E** Caudal edge of the periosteal flap. **F** Closure of the perichondrium by simple stitches

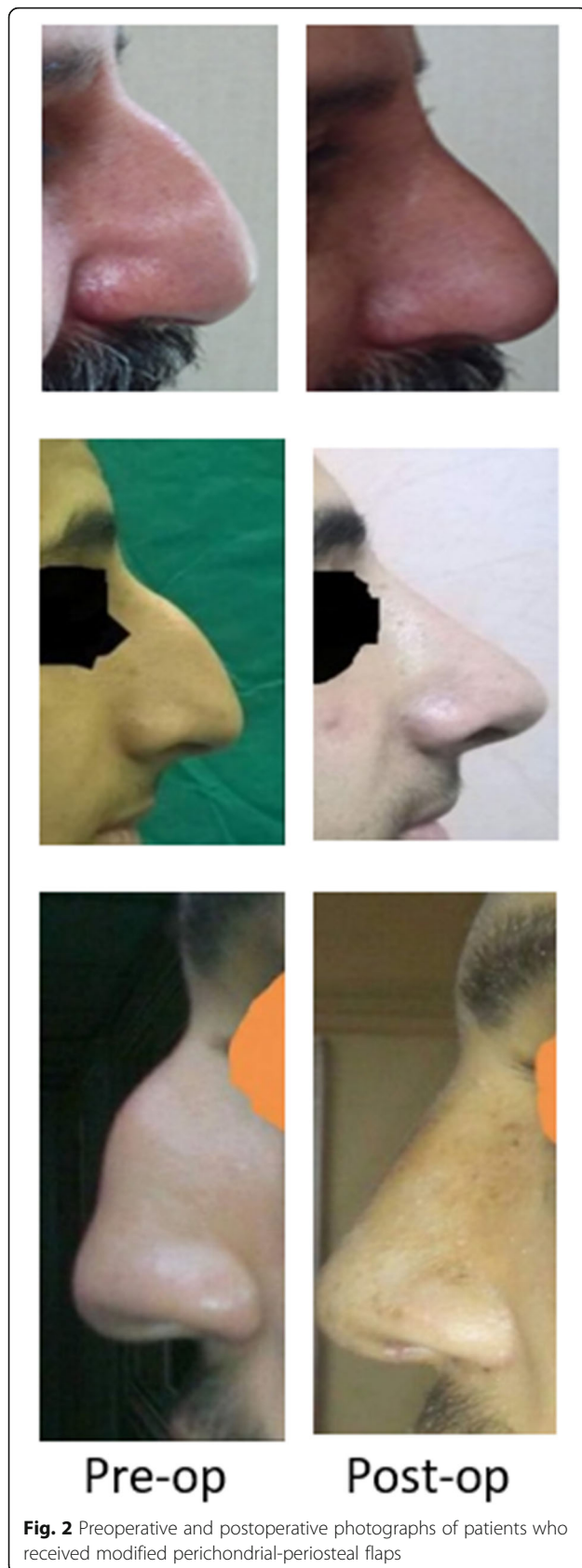


Fig. 2 Preoperative and postoperative photographs of patients who received modified perichondrial-periosteal flaps

performed inadequately [7]. Despite the surgeon’s experience and meticulous dissection during hump reduction, dorsal irregularities remain inevitable and unexpected complications after subsiding of postoperative nasal dorsal edema [2].

Dorsal irregularities are more apparent in patients with thin skin, and it is one of the reasons for revision rhinoplasty due to dissatisfaction especially in patients aiming for smooth and straight dorsum [8]. Consequently, various strategic camouflages were developed and applied by surgeons to prevent the appearance of these irregularities and avoid revision surgery. Some authors use onlay grafts, e.g., temporalis fascia, perichondrium, and Gore-Tex [9]. Complications such as visibility of edge, displacement, infection, and extrusion were documented with onlay graft [10]. Others used ULC flaps to avoid these irregularities to prevent keystone notching of the nasal dorsum after surgery [11, 12].

Also, the perichondrium over the ULC and the periosteum over the nasal bones (perichondrio-periosteal flap) could be used as a separate layer to cover and camouflage the nasal dorsum. It can be combined with other techniques as it can cover the onlay graft [6].

The perichondrio-periosteal flap can be dissected and elevated as a continuous laterally based flap as described by Jugo in 1986 [3] and Ahmet et al. in 2005 [5], while Cerkes [6] described two separated laterally based perichondrio-periosteal flap on each side following a midline incision of both structures. All three authors conclude that it gives excellent covering of the dorsum of the nose, stabilizes the osteotomies, and improves the outcome of rhinoplasty.

In the current study, a modification is applied on the perichondrio-periosteal flap to be 3 separated flaps, two laterally based perichondrial flap, and one superiorly periosteal flap. It is difficult to preserve the perichondrio-periosteal flap as one continuous flap without tears especially at the transition area of both structures. In our study, we do not incise the periosteum in the midline as Cerkes did in his study [6] because the periosteum is not a reparable tissue and it is quite difficult to suture it [5]. Furthermore, it falls away and rolls up as fragments if incised and can cause future irregularities [12].

Meticulous dissection of these flaps is crucial as the perichondrium and periosteum are firmly adherent to the underlying ULC and nasal bones, respectively. For this reason, loupe magnification was recommended during dissection, elevation, and even in all rhinoplasty steps.

In 1994, Crysdale and Walker showed that open septorhinoplasty can be appropriate in children older than 6 years old with nasal block due to severe deviation to avoid respiratory and dentition problems that can affect the child [13]. Many surgeons now perform open septoplasty and open septorhinoplasty procedures in children

who present with severe nasal septal deviation [14, 15]. So, we recommend modified perichondrial-periosteal flaps to be included in future studies as an essential step in septorhinoplasty in children.

Despite modified perichondrial-periosteal flaps elongate the timing of the procedure (average operating time is 160 min), it is worthy as the power of the flap is based on the histological network of the arterioles and capillaries that avoid weakening of the cartilage and provide nourishment to the nasal dorsum [5].

Conclusion

The modified perichondrial-periosteal flap (three flaps technique) is an excellent and successful technique, functionally and aesthetically, to camouflage the nasal dorsum. It provides stability of the upper lateral cartilage with normal nasal breathing and avoids the appearance of unexpected dorsal irregularities.

Abbreviation

ULC: Upper lateral cartilage

Acknowledgements

Institution where the work was done: Magrabi ENT Hospital, Doha, Qatar.

Authors' contributions

All authors have read and approved the final manuscript. AGK contributed to the following: idea, protocol, patient selection, surgery, follow-up, and writing of the manuscript. HAE and AMM contributed to the surgery, follow-up, and writing of the manuscript.

Funding

This research did not receive any specific grant from funding agencies in the public, commercial, or not-for-profit sectors.

Availability of data and materials

The datasets used and/or analyzed during the current study are available from the corresponding author on reasonable request.

Declarations

Ethics approval and consent to participate

Ethics Committee of Magrabi Hospital, Doha, Qatar. The reference number is ENT-8-2016Q.

Informed written consent from all patients to participate in the study.

Consent for publication

Written informed consent for the publication of the images are obtained from the participants.

Competing interests

Dr. Hesham El-Sersy is a co-author of this study and an editorial board member of the journal. He declares a competing interest for this submission. He has not handled this manuscript. The rest of the authors declare that they have no competing interests.

Received: 8 May 2021 Accepted: 27 May 2021

Published online: 06 July 2021

References

1. Padovan I (1966) External approach in rhinoplasty (decortication). *Symp Otorhinolaryngol* 3-4:354–360
2. Bocchieri A (2004) Subtotal reconstruction of the nasal septum using a conchal reshaped graft. *Ann Plast Surg* 53(2):118–125

3. Jugo SB (1986) The Periosteoperichondrial Flap in External Rhinoplasty. *Arch Otolaryngol Head Neck Surg* 112:776–779
4. Chin KY, Uppal R (2014) Improved access in endonasal rhinoplasty: the cross cartilaginous approach. *J Plast Reconstr Aesthet Surg* 67(6):781–788
5. Ahmet K, Adnan K, Nihal I (2005) A Perichondrial Flap for Functional Purposes in Rhinoplasty. *Aesth. Plast. Surg* 29:256–260
6. Cerkas N (2013) Concurrent elevation of the upper lateral cartilage perichondrium and nasal bone periosteum for management of dorsum: the perichondro-periosteal flap. *Aesthet Surg J* 33(6):899–914
7. Pearson DC, Adamson PA (2004) The ideal nasal profile: rhinoplasty patients vs the general public. *Arch Facial Plast Surg* 6(4):257–262
8. Dayan SH, Greene RM (2006) Achieving a natural nasal dorsum in rhinoplasty. *Ear Nose Throat J* 85(1):22–23
9. Bocchieri A, Macro C (2006) Septal considerations in revision rhinoplasty. *Facial Plast Surg Clin North Am* 14:357–371
10. Oneal RM, Berkowitz RL (1998) Upper lateral cartilage spreader flaps in rhinoplasty. *Aesthet Surg J* 18(5):370–371
11. Maryam S, Maryam J, Peter AA. Newly Designed Upper Lateral Cartilage Flap for Preventing Depression of the Keystone Area .in Large-Nose Septorhinoplasty. *JAMA Facial Plast Surg* doi:<https://doi.org/10.1001/jamafacial.2015.0904>. Published online September 24, 2015.
12. Broadbent TR, Woolf RM (1984) Anatomy of a rhinoplasty: Saw technique. *Ann Plast Surg* 13:67–89
13. Crysdale WS, Walker PJ (1994) External septorhinoplasty in children: patient selection and surgical technique. *J Otolaryngol* 23:28–31
14. Akkina SR, Parikh SR (2018) Pediatric septoplasty. *Oper Tech Otolaryngol Head Neck Surg* 29(2):66–69
15. Sabry O, Dewidar H, Abdel-Aziz M, Elemam A, Nassar A (2021) Efficiency of modified Goldman's technique in open pediatric septoplasty. *Egypt J Otolaryngol* 37:16

Publisher's Note

Springer Nature remains neutral with regard to jurisdictional claims in published maps and institutional affiliations.

Submit your manuscript to a SpringerOpen[®] journal and benefit from:

- Convenient online submission
- Rigorous peer review
- Open access: articles freely available online
- High visibility within the field
- Retaining the copyright to your article

Submit your next manuscript at ► [springeropen.com](https://www.springeropen.com)