

CASE REPORT

Open Access



Digital gangrene as an unusual paraneoplastic manifestation of Hodgkin's lymphoma—a rare case report

Swaroop Deme^{*} , Bhaskar Kakarla, Venkateswar Rao P, Raju YSN and Nageswara Rao M.

Abstract

Background: Hodgkin's lymphoma presenting with digital ischemia and gangrene is a rare manifestation. Paraneoplastic manifestations are rare in Hodgkin's lymphoma but can occur in the form of paraneoplastic cerebellar degeneration (PCD) and dermatomyositis/polymyositis. This case report adds an exceptional presentation of Hodgkin's lymphoma as digital ischemia and gangrene.

Case presentation: We report a case of a 60-year-old male patient who presented with fever, cough, shortness of breath, the pain in the right middle finger. On examination bluish-black discoloration of the right middle finger, left middle finger, ring finger, and generalized lymphadenopathy was noted. On further evaluation, he was found to have anemia, eosinophilia, and severe thrombocytopenia with a normal coagulation profile and negative rheumatological workup. Arterial Doppler of both upper limbs showed the normal study. He was diagnosed to have Hodgkin's lymphoma on the lymph node and bone marrow biopsy. He was started on chemotherapy with partial improvement in symptoms and was lost to follow-up after 2 cycles.

Conclusions: Digital ischemia can be a rare paraneoplastic manifestation of Hodgkin's lymphoma.

Keywords: Digital ischemia, Paraneoplastic manifestation, Hodgkin's lymphoma, Case report

Background

Digital ischemia with gangrene of one or several fingertips as a paraneoplastic manifestation is common with adenocarcinoma and is rare with other malignancies. In the absence of evidence of rheumatological, cardiovascular, occupational, arteriosclerotic, and autoimmune diseases, an acute occurrence of digital ischemia and gangrene should suggest a possibility of paraneoplastic syndrome and the need for a thorough search of malignancy [1]. In Hodgkin's lymphoma common paraneoplastic manifestations include neurological like sensory neuropathies, paraneoplastic cerebellar degeneration (PCD), and Lambert-Eaton myasthenic syndrome. Presentation with digital ischemia and gangrene of Hodgkin's

lymphoma is a rare occurrence [2]. We present a case of a 60-year-old patient with digital ischemia and gangrene in association with stage 4 Hodgkin's lymphoma of mixed cellularity subtype involving lung and bone marrow.

Case presentation

A 60-year-old male presented with blackish discoloration of fingertips of both upper limbs of one year, fever, cough, and breathlessness of 2 months duration. The patient had a history of spontaneous amputation of digital phalanx of the left ring finger and surgical amputation of distal phalanx of the right middle finger 6 months before presentation. The patient was a known smoker for the past 30 years. There were no other comorbidities and no relevant family and genetic information. There was no history of trauma, cold exposure, and usage of sympathomimetic drugs. Physical examination showed normal

*Correspondence: swaroopreddymd@gmail.com
Nizams Institute of Medical Sciences, Panjagutta, Hyderabad, Telangana
500082, India

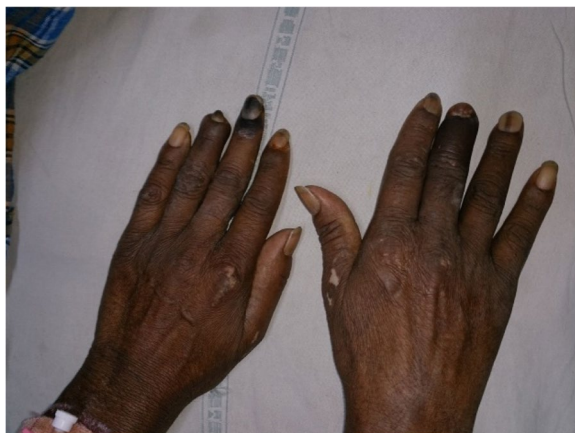

Fig. 1 Showing left middle finger gangrene and index finger .

peripheral pulses, blackish discoloration of fingertips of right and left middle fingers, and left ring finger (Fig. 1). He had multiple nontender, rubbery consistent lymph nodal swellings in bilateral cervical, axillary, and inguinal regions with the largest inguinal lymph node measuring 3 × 3 cm. Differential diagnosis of digital gangrene considered was Buerger's disease as the patient being a smoker, vasculitides, connective tissue disorders with vasculitis, antiphospholipid antibody syndrome, and malignancy with paraneoplastic manifestation/hypercoagulable state.

Investigations revealed thrombocytopenia (platelet count 10,000 cells/cu mm) with other hematologic parameters being normal. Antinuclear antibody, Anti Scl 70, antineutrophil cytoplasmic antibody (c-ANCA/p-ANCA) and antiphospholipid antibodies, cold agglutinins, homocysteine levels, Protein C&S, and antithrombin III were normal. Chest radiograph showed bilateral pleural effusions. Arterial Doppler of both upper limbs didn't show any thrombus. Photoplethysmography of other digits was normal and there was no signal from gangrenous digits. As there was no other organ involvement suggestive of vasculitides, a biopsy could not be performed. CECT chest, abdomen showed fibrocalcific changes in both lung parenchyma with underlying collapse/consolidation with loculated effusions. Pleural fluid analysis revealed transudative effusions. There was also mediastinal, axillary, abdominal, and retroperitoneal lymphadenopathy. Lymph nodes and bone marrow biopsy were suggestive of Hodgkin's lymphoma of mixed cellularity variant having classical Reed Sternberg cells with immunohistochemistry showing cluster of differentiation 3 (CD 3), CD 20, CD 15, and CD 30 positivity (Fig. 2a–d). Finally, a diagnosis of Hodgkin's lymphoma-mixed cellularity type, stage IV with paraneoplastic digital ischemia/

gangrene was done. He was treated with Doxorubicin (25 mg/m² I.V), Bleomycin (10 mg/m² I.V), Vinblastine (6 mg/m² I.V), and Dacarbazine (375 mg/m² I.V), days 1 and 15. The patient improved symptomatically and effusions decreased after chemotherapy. The patient was lost to follow-up after 2 cycles of chemotherapy.

Discussion

Paraneoplastic syndromes are rare disorders caused by secretory peptides, hormones, or alterations in the immune response of the tumor. These mechanisms explain the distant nonmetastatic effects of the tumor with variable systemic manifestations and syndromes. Persistent digital ischemia is one of the rare cutaneous paraneoplastic manifestations. In 1865, Trousseau first described the vascular paraneoplastic syndrome of migratory thrombosis as an unusual manifestation of visceral malignancy.

Paraneoplastic syndromes themselves can be the presenting feature of malignancy. In 1% of patients, skin manifestations can be the first diagnostic sign [2]. In a study by Ewa Poszepczynska-Guigné et al., cancer detection coincided, preceded, or followed with the acral vascular syndrome in 47%, 44%, and 9% respectively. The cutaneous manifestations have preceded malignancy ranging from 1 month to 11 years [3]. In our case, acral vascular manifestations have preceded malignancy by 1 year.

Gastrointestinal malignancies were the commonest tumors to present with ischemia of digits followed by lung, hematologic, and gynecological malignancies [4]. Gangrene was the commonest manifestation of acral vascular syndrome followed by acrocyanosis and Raynaud's phenomenon. Fingers were affected in 94% of patients. Adenocarcinomas were the predominantly associated malignancies (41%), and metastases were observed in 41% [3]. In our case, no definite signs of thrombosis or alteration of the coagulative system were identified. We could exclude autoimmune arteritis by the absence of antinuclear antibodies and antiphospholipid antibodies. In the same way, we could exclude a thrombosis of the upper limb by a negative arterial Doppler ultrasonography. Normal coagulative indices like antithrombin III, protein S, and protein C gave us the possibility to exclude an inherited or acquired hypercoagulable state.

The cause of digital ischemia is not clear in the majority of cases. The proposed mechanisms of such clinical manifestations are various: vasospasm due to sympathetic hyperactivity, arteritis induced by tumor antigen-antibody complexes deposition or as a consequence of immune dysregulation, blood hyperviscosity, hypercoagulability, or peripheral thrombosis [5]. Cryoglobulinemia or cold

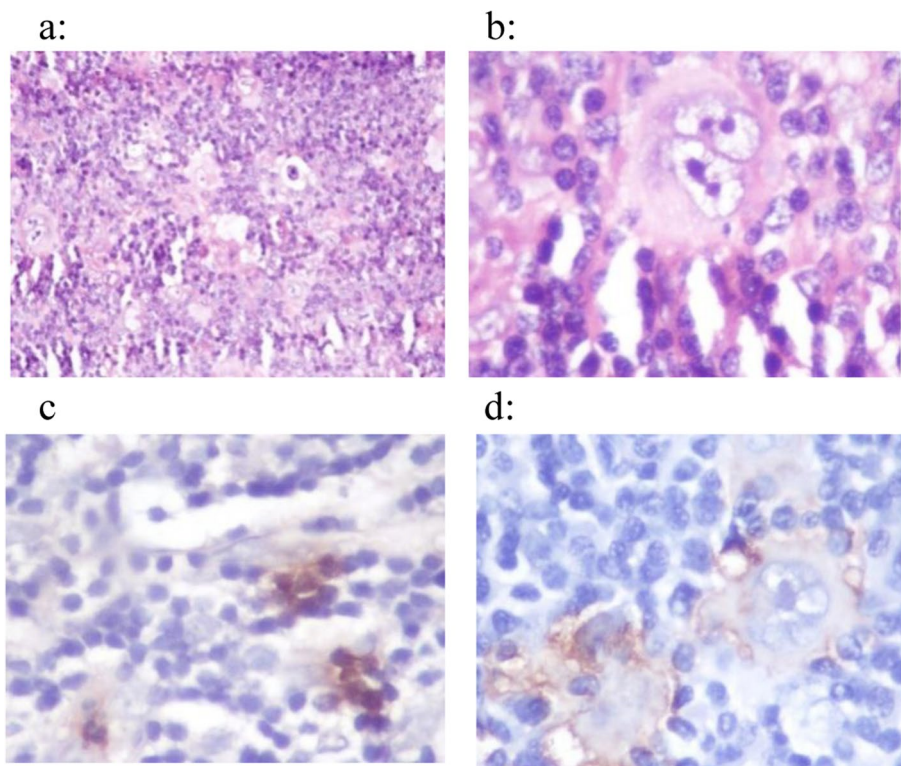


Fig. 2 Legend: Lymph node biopsy histopathology showing **a** polymorphous population with neutrophils, eosinophils, lymphocytes, and RS cells; **b** RS cell; **c** CD 15 positivity; **d** CD 30 positivity

agglutinin disease are commonly associated with lymphoma-associated acrosyndromes but in our case cold agglutinins were negative [6]. Hyperstimulation of the sympathetic nervous system as a result of compression of cervical plexus by the tumor or the metastasized lymph nodes could cause acral vasoconstriction [7]. In our case, peripheral vasospasm due to increased sympathetic activity could be the potential cause of digital ischemia.

Hodgkin's disease is a tumor characterized by neoplastic cells of B cell origin. The mixed cellular variety is the second most common type (15 to 30%) and is seen mostly in older adults. Hodgkin's disease can occasionally present with unusual manifestations. These include severe and unexplained itching, cutaneous disorders such as erythema nodosum and ichthyosiform atrophy, paraneoplastic cerebellar degeneration, and other distant effects on the central nervous system, nephrotic syndrome, immune hemolytic anemia and thrombocytopenia, hypercalcemia, and pain in lymph nodes on alcohol ingestion [5, 8].

The strength of this case report is the biopsy-proven diagnosis of lymphoma and exclusion of all other possible causes of digital gangrene by a necessary workup. The

limitation was we could not follow the patient to assess the prognosis in this particular scenario.

Conclusions

Hodgkin's lymphoma presenting with digital gangrene is a very rare entity. Very few cases have been reported where digital gangrene occurs as a paraneoplastic manifestation of Hodgkin's lymphoma. A thorough search should be made for occult malignancy especially in an elderly person presenting with digital ischemia like in our case. A neoplastic origin of the digital vascular syndrome should be considered in elderly patients, especially men, in the absence of any other identifiable etiology.

Abbreviations

PCD: Paraneoplastic cerebellar degeneration; CECT: Contrast-enhanced computerized tomography; CD: Cluster of differentiation; ANCA: Antineutrophil cytoplasmic antibody; I.V: Intravenous; CNS: Central nervous system.

Acknowledgements

Our pathologist Dr. Megha Uppin (Associate professor, Department of Pathology, NIMS) for helping us out in the diagnosis of our patient.

Authors' contributions

DS, KB, PVR, YSNR, and MNR were responsible for the concept, design, definition of intellectual content, literature search, data acquisition, manuscript editing, and review. All authors have read and approved the final manuscript.

Funding

Nil

Availability of data and materials

Not applicable

Declarations**Ethics approval and consent to participate**

Not applicable

Consent for publication

A written informed consent was taken from the patient.

Competing interests

Nil

Received: 30 July 2021 Accepted: 11 October 2021

Published online: 28 October 2021

References

- Mahley V, Neureiter D, Kircher T, Schuler G, Fartasch M (1999) Digital ischemia as paraneoplastic marker of metastatic endometrial carcinoma. *Hautarzt* 50(10):748–752
- Halpern SM, Todd P, Kirby JD (1994) Hodgkin's disease presenting with digital ischaemia. *Clin Exp Dermatol* 19(4):330–331
- Ewa Poszepczynska-Guigne MD, Viguier M, Chosidow O et al (2002) Paraneoplastic acral vascular syndrome: Epidemiologic features, clinical manifestations, and disease sequelae. *J Am Acad Dermatol* 47(1):47–52
- Raimondo L, Cella CA, Moretto R, Matano E, Carlomagno C (2011) Digital ischemia in patients with solid tumors: a case report and review of the literature. *J Cancer Ther* 2:281–284
- Briani C, Vitalani R et al (2011) Spectrum of paraneoplastic disease associated with lymphoma. *Neurology* 76(8):705–710
- Woei-A-Jin FJ, Tamsma JT, Khoe LV, den Hartog WC, Gerritsen JJ, Brand A (2014) Lymphoma-associated paraneoplastic digital ischemia. *Ann Hematol* 93(2):355–357
- Hawley PR, Johnston AW (1967) Rankin JT association between digital ischemia and malignant disease. *Br Med J* 3:208–212
- Dan L (2012) *Longo Malignancies of Lymphoid Cells*, Harrison's Principles of Internal Medicine, volume 1, 18th edition, pp 933–934

Publisher's Note

Springer Nature remains neutral with regard to jurisdictional claims in published maps and institutional affiliations.

Submit your manuscript to a SpringerOpen[®] journal and benefit from:

- ▶ Convenient online submission
- ▶ Rigorous peer review
- ▶ Open access: articles freely available online
- ▶ High visibility within the field
- ▶ Retaining the copyright to your article

Submit your next manuscript at ▶ [springeropen.com](https://www.springeropen.com)
