

ORIGINAL RESEARCH

Open Access



Non-hypertrophic gastric outlet obstruction in the paediatric population: a case series with focus on management

Naser El-Mefleh^{1,2*}  and Muhammad Eyad Ba'Ath³

Abstract

Background Non-hypertrophic gastric outlet obstruction (GOO) in children is rare and usually presents beyond infancy. Aetiology is variable, and management is not well established due to its rarity.

Methods We aimed to conduct a descriptive study of these cases within our geographic area. It is a retrospective chart review of all children with non-hypertrophic gastric outlet obstruction presenting to three hospitals in north-west Syria during the period 2019–2023. Demographics, presentation, and management data were extracted.

Results Twelve cases were identified, eight males, with age range 1–12 years and follow-up range 3–42 months. Eight patients had a history drinking battery acid and one with ingestion of high-dose ibuprofen. The other three had no clear aetiology. Five patients improved by endoscopic balloon dilatations (EBD), and seven needed surgeries. All those who had successful EBD were treated within 3 weeks of ingestion.

Conclusion Non-hypertrophic GOO in children is rare and mostly related to caustic material ingestion. Treatment by endoscopic balloon dilatation is likely to be successful if done within 3 weeks from caustic ingestion. After that period, often surgery is needed.

Keywords Gastric obstruction, Pyloric stenosis, Balloon dilation, Battery acid: NSAID, Ibuprofen

Background

Idiopathic hypertrophic pyloric stenosis (IHPS) is the most common cause of gastric outlet obstruction (GOO) in young infants, with more than 90% of cases presenting between 3 and 10 weeks after birth [1, 2]. Non-hypertrophic GOO (NHGOO) is much rarer and typically present later. The aetiology is poorly understood, and sometimes no clear cause can be identified [1, 3, 4]. Anecdotally, we witnessed an increase in these cases in our region over the last few years. We report

our experience in 12 cases with late onset NHGOO. We discuss symptoms, causes and the best management in affected children.

Methods

It is a retrospective case series of all children with GOO with causes other than congenital or IHPS that presented to three hospitals (Bab Al-Hawa Hospital, DEVA Hospital and Muhammad Wassim Maaz Hospital) in the northwest of Syria between December 2019 and August 2023. Cases were identified from a personally maintained list of one of the paediatric surgeons covering the hospitals. Medical records of children admitted for GOO were reviewed and relevant information extracted. Cases where the child was born with congenital pyloric stenosis or atresia, or where the diagnosis was IHPS, were

*Correspondence:

Naser El-Mefleh
dr.naser1989@hotmail.com

¹ Department of Pediatric Surgery, Bab Alhawa Relief Hospital, Edleb, Syria

² Department of Pediatric Surgery, DEVA Hospital and Muhammad

Wassim Maaz Hospital, Aleppo, Syria

³ American Hospital Dubai, Dubai, United Arab Emirates

excluded. The study complied with the ethical guidance of healthcare institutions involved.

Results

Twelve patients (eight boys and four girls) were enrolled. Age ranged from 1 to 12 years (mean age was 3.44 years). All presented with characteristic recurrent nonbilious vomiting. Other common complaints were postprandial vomiting, weight loss, dehydration, electrolyte imbalances and metabolic alkalosis. The follow-up period ranged from 3 to 42 months (mean 21.0, SD 10.28). Eight patients had a history of drinking caustic substance, which is battery acid: H₂SO₄ (sulphuric acid). In three cases, there was no clear history of a cause, and in one patient, there was a history of ingesting a single high dose of ibuprofen (2000 mg, and child

weight was 11 kg, approximately 180 mg per kg), with negative history for other gastrointestinal problems or chronic drugs usage. The early and late appearance of the pylorus following sulphuric acid ingestion (SAI) is shown in Fig. 1.

Seven patients presented late to surgery and had complete obstruction with severe scarring in the pylorus (they were referred for surgery because of failing attempts of EBD). The other five patients improved with EBD and did not require surgical intervention. All cases that had successful EBD were dilated within 3 weeks from the time of the injury. Three patients needed two dilatations, and two patients required only one dilatation. Technique of EBD is shown in Fig. 2: CRE balloon with diameter range from 8 to 12 mm was used according to child age, and the dilatation was done using direct endoscopic visualisation.

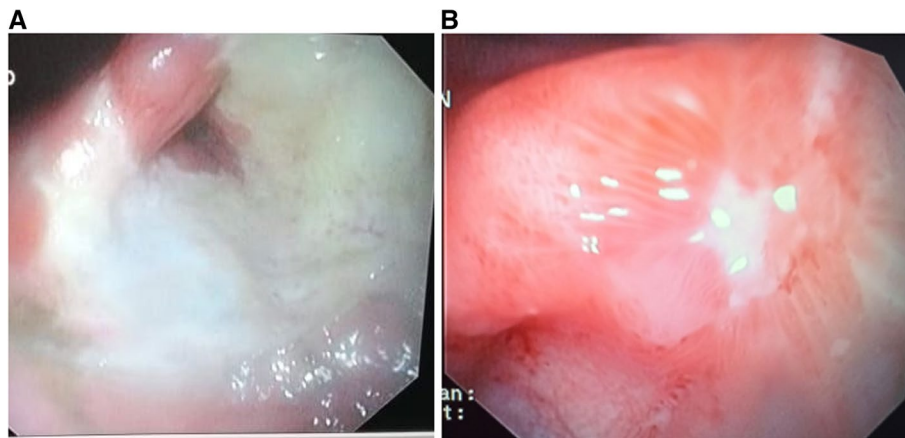


Fig. 1 Early vs late endoscopic appearance of SAI. **A** Early endoscopic appearance of SAI: a case where endoscopy was performed within 24 h of SAI. The pyloric region was affected by the ingested acid, which seems to have had the longest mucosal contact due to stasis at the level of the pylorus. This case responded well to EBD. **B** Late endoscopic appearance of SAI: endoscopic appearance of SAI more than 3 weeks after ingestion. Extensive scarring and complete closure of the pylorus are noted. Case did not respond to EBD and needed surgery

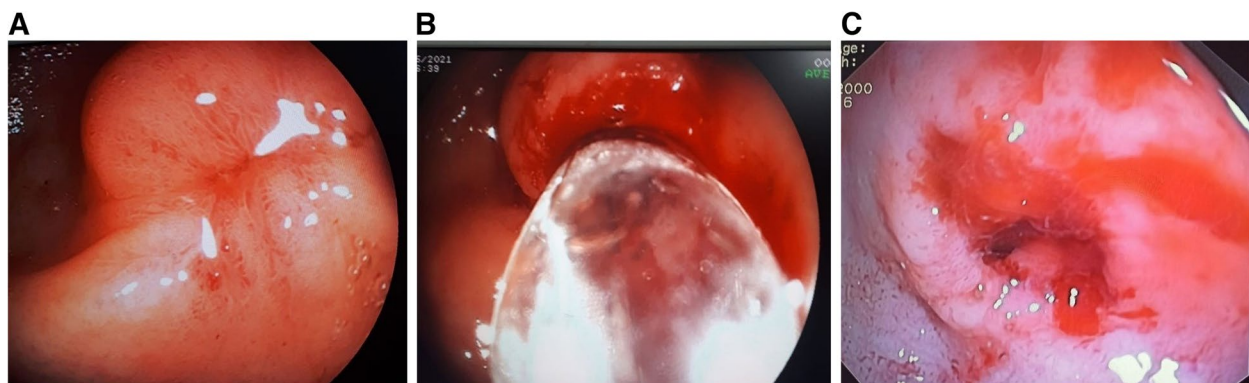


Fig. 2 Endoscopic pyloric balloon dilatation. **A** Appearance before dilatation. Two weeks from injury. Note incomplete closure of pylorus. **B** Balloon deployed inside stenotic pylorus. **C** View following dilatation. Case did not need surgery

Surgical procedures included gastrojejunostomy GJS ($n = 2$), Heineke–Mikulicz pyloroplasty (HMP) ($n = 2$) and gastroduodenostomy GDS ($n = 3$). Severe anastomotic stricture (after GDS) requiring a second operation (GJS) developed in one patient after 1 month. Another patient had adhesions-related intestinal obstruction 1 month later, which resolved with nonoperative treatment. All patients are currently symptoms-free and gaining weight adequately. None of the patients developed bile reflux gastritis, dumping syndrome, failing to thrive or anaemia. The average number of days as inpatient after surgery ranged 6 to 9 days (average: 7.12 days).

Surgical technique

All patients were operated under general anaesthesia with endotracheal intubation after correcting electrolyte and acid-alkaline imbalance. The surgical incision was either on the midline or transverse right upper quadrant; after entering the abdomen, the pylorus was identified and palpated to assess the degree of fibrosis and scarring in it, and typically, it was rigid and contracted. Prior to opening the stomach, the diagnosis was further confirmed by the inability to pass a nasogastric tube through the pylorus with manual manipulation. Following this, the definitive management was undertaken in the form of HMP, GDS or GJS. A single-layer anastomosis was performed with interrupted 4/0 coated VICRYL[®], and a trans-anastomotic tube was left in place for early enteral feeding. The anastomosis was tested for patency and leakage, and the abdomen was closed in layers with no drain left.

Discussion

Patients with gastric outlet obstruction caused by caustic ingestion usually require surgical intervention [5]. However, in our study, 41% of cases did not need surgery, possibly due to early diagnosis and management within 3 weeks from ingestion and before the occurrence of scarring in the pylorus. In contrast to post-caustic oesophageal injury, limited series reporting the sequel of acid ingestion on the stomach have been published [6–10]. Although rare, a high index of suspicion must be maintained for acquired NHGOO, in the differential diagnosis of children with nonbilious vomiting and failure to thrive especially with metabolic alkalosis [3, 4]. Following diagnostic workup, appropriate management should be initiated [1]. Gastric outlet obstruction should be treated with EBD [1, 11, 12] of the pylorus or with surgery. The success of EBD is related to the timing after injury. All successful EBD in our series were done within 3 weeks from the injury. This might be related to the fact these cases were less affected to start with or due to the fibrosis not yet being severe enough to preclude successful

EBD. The later explanation makes EBD intervention time sensitive. Whenever possible, EBD should be attempted within 3 weeks from injury to maximise the chances of successful nonoperative treatment. In our case series, the earliest EBD was attempted 9 days after injury.

Surgery remains the mainstay of management for GOO in late-presenting cases (usually after 3 weeks) or when nonoperative treatment fails. Surgical procedures used are multiple and include GJS, HMP and GDS [1, 3, 5, 13, 14]. The choice of surgical technique depends on the findings at laparotomy [5, 6], such as the extent of fibrosis in the pylorus or past surgeries in the same anatomical region, in addition to the surgeon's preference and experience (in our case series, four surgeons were involved). When choosing surgical technique, the surgeon should consider the possibility of formation of adhesions and the need for reoperation and the possible complications of each procedure. We usually recommend attempting preservation of normal anatomical passage of enteric contents (HMP) over bypass procedures (GDS or GJS), which other authors agree with [5, 7, 8]. If the fibrosis at the level of the pylorus is limited to the mucosa, then pyloroplasty can be considered; otherwise, some form of bypass surgery is required [5].

A case of complete obstruction of the gastric outlet due to an unusual and previously undescribed cause is documented in our series: a high dose of NSAID (ibuprofen). The child presented within less than 24 h of taking the drug with a history of severe hematemesis and was admitted to the intensive care unit and required blood transfusion. The child was discharged 9 days after admission in a reasonable condition but presented 4 days later with progressive, postprandial non-bilious vomiting. The child had supportive treatment for 12 days. An early upper gastroduodenal endoscopy was not performed due to parental refusal. The patient was subsequently transferred to the surgical department and eventually had upper gastroduodenal endoscopy 25 days following ingestion. By that time, the child was severely malnourished, and the pylorus showed signs of ulceration and scarring leading to GOO. The pylorus would not even admit a wire to permit dilatation, and the child ended up having surgery.

Accidental caustic material ingestion by children still occurs in some developing countries [15]. Acquired GOO is a significant complication of caustic acid ingestion [16]. Most cases leading to pyloric stenosis in our study are related to SAI. The chemical is a colourless fluid, like water, and is used in the manufacturing of some large batteries. The incidence of SAI seems to have increased in northwest of Syria due to the widespread use of batteries in houses where main electrical supply is patchy and often non-existent. The fluid is commonly stored

in inappropriate containers (sometimes water cans) and kept within households so it can be used to top-up battery fluid. This made it within the reach of young children, which led to the increase in ingestion cases [17].

No cases in our series had significant oesophageal injury, despite the severity of pyloric lesions. This suggests that the caustic effect on the pylorus is related to the stagnation that occurs at the level of the antrum, while the oesophagus is spared due to the rapid transit through it. It is generally thought that “acid licks the oesophagus and bites the pyloric antrum” [18]. These patients might benefit from delayed emptying of the stomach with an NGT, which is not generally recommended with other caustic material ingestions. This, however, needs clinical confirmation with prospective trials.

Two cases in our series were treated as peptic ulcers following an initial endoscopy, with an initial decision to repeat the endoscopy after few weeks. This might have resulted in missing the opportunity to treat pyloric strictures endoscopically. One case had delayed treatment due to parental refusal. Quite few cases reached us severely malnourished and/or dehydrated. There is clearly a room for improving awareness of this condition in the community and within medical practitioners. This will hopefully lead to improvement in storage conditions and earlier establishment of diagnosis and initiation of appropriate treatment.

Conclusion

Acquired GOO in children due to causes other than IHPS is rare. A significant number of cases seems to be related to caustic material ingestions, particularly SAI. Rarely, it can be caused by ibuprofen. Treatment usually consists of EBD, and when it fails, surgical management is indicated. EBD is unlikely to be successful when done after 3 weeks of injury.

Abbreviations

IHPS	Idiopathic hypertrophic pyloric stenosis
GOO	Gastric outlet obstruction
NHGOO	Non-hypertrophic GOO
SAI	Sulphuric acid ingestion
EBD	Endoscopic balloon dilatations
HMP	Heineke–Mikulicz pyloroplasty
GDS	Gastroduodenostomy
GJS	Gastrojejunostomy

Acknowledgements

Not applicable

Authors' contributions

The contribution of both authors was large and close—the first author (N) collected data and performed most of the endoscopic and surgical procedures and follow-up of cases, and the second author (M) had the greatest effort in reviewing and checking the data linguistically and scientifically and coordinating them in the best way to be well understood.

Funding

No funding

Availability of data and materials

All data generated or analysed during this study are included in this published article.

Declarations

Ethics approval and consent to participate

The study was approved by local ethics committee of hospitals where study was done. Devahospital.sy@gmail.com. IRB number: IRB43-1321.

Consent for publication

Not applicable

Competing interests

The authors declare that they have no competing interests.

Received: 27 January 2023 Accepted: 5 October 2023

Published online: 11 December 2023

References

- Chao HC. Update on endoscopic management of gastric outlet obstruction in children. *World J Gastrointest Endosc.* 2016;8(18):635–45.
- Lone YA, Hushain D, Chana RS, Khan RA, Sachdeva S, Mushtaq E. Primary acquired gastric outlet obstruction in children: a retrospective single center study. *J Pediatr Surg.* 2019;54(11):2285–90.
- Ozokutan BH, Ceylan H, Ertaşkin I, Yapici S. Pediatric gastric outlet obstruction following corrosive ingestion. *Pediatr Surg Int.* 2010;26(6):615–8.
- Otjen JP, Iyer RS, Phillips GS, Parisi MT. Usual and unusual causes of pediatric gastric outlet obstruction. *Pediatr Radiol.* 2012;42(6):728–37.
- Elhalaby EA, Halawa NAEA, Elhalaby IE, Shawky D, Hassan H, Almetaher HA. The safety and efficacy of the trans-umbilical approach for pyloroplasty in the management of post-acid corrosive gastric outlet obstruction in children. *Ann Pediatr Surg.* 2021;17(1):16.
- Tekant G, Eroğlu E, Erdoğan E, Yeşiladağ E, Emir H, Büyükcünal C, et al. Corrosive injury-induced gastric outlet obstruction: a changing spectrum of agents and treatment. *J Pediatr Surg.* 2001;36(7):1004–7.
- Ciftci AO, Senocak ME, Büyükcünal N, Hiçsönmez A. Gastric outlet obstruction due to corrosive ingestion: incidence and outcome. *Pediatr Surg Int.* 1999;15(2):88–91.
- Ozcan C, Ergün O, Sen T, Mutaf O. Gastric outlet obstruction secondary to acid ingestion in children. *J Pediatr Surg.* 2004;39(11):1651–3.
- Gillis DA, Higgins G, Kennedy R. Gastric damage from ingested acid in children. *J Pediatr Surg.* 1985;20(5):494–6.
- Hall RJ, Lilly JR. Treatment of acid burns of the stomach in children by pedicle pyloroplasty. *Surg Gynecol Obstet.* 1988;167(2):152–4.
- Andrade M, Sawamura R, Cupo P, Del Ciampo IR, Fernandes MI. Endoscopic treatment of gastric outlet obstruction secondary to accidental acid ingestion in a child. *J Pediatr Gastroenterol Nutr.* 2016;62(1):90–2.
- Chan KL, Saing H. Balloon catheter dilatation of peptic pyloric stenosis in children. *J Pediatr Gastroenterol Nutr.* 1994;18(4):465–8.
- El-Asmar KM, Allam AM. Surgical management of corrosive-induced gastric injury in children: 10years' experience. *J Pediatr Surg.* 2018;53(4):744–7.
- Zeng JX, Zhu DL, Xia HM, Liang QF. Surgical management of pyloric stenosis induced by gastrointestinal chemical burn in children. *Zhonghua Wei Chang Wai Ke Za Zhi.* 2013;16(5):467–70.
- Lakshmi CP, Vijayahari R, Kate V, Ananthakrishnan N. A hospital-based epidemiological study of corrosive alimentary injuries with particular reference to the Indian experience. *Natl Med J India.* 2013;26(1):31–6.

16. Contini S, Scarpignato C. Caustic injury of the upper gastrointestinal tract: a comprehensive review. *World J Gastroenterol.* 2013;19(25):3918–30.
17. Urganci N, Usta M, Kalyoncu D, Demirel E. Corrosive substance ingestion in children. *Indian J Pediatr.* 2014;81(7):675–9.
18. Marks INBS, Werbeloff L. The natural history of corrosive gastritis: report of five cases. *Am J Dig Dis.* 1963;8:509–24.

Publisher's Note

Springer Nature remains neutral with regard to jurisdictional claims in published maps and institutional affiliations.

Submit your manuscript to a SpringerOpen[®] journal and benefit from:

- ▶ Convenient online submission
- ▶ Rigorous peer review
- ▶ Open access: articles freely available online
- ▶ High visibility within the field
- ▶ Retaining the copyright to your article

Submit your next manuscript at ▶ [springeropen.com](https://www.springeropen.com)
