


CASE REPORTS

Open Access



Long proximal pouch oesophageal atresia with tracheo-oesophageal fistula, a diagnostic dilemma: case report

Sello Machaea , Vuyo Nogela and Milind Chitnis

Abstract

Background: Oesophageal atresia is a congenital abnormality commonly encountered in neonates. Classification proposed by Gross is the most frequently used. It divides the oesophageal anomalies into five types. Type C—proximal oesophageal atresia and distal tracheo-oesophageal fistula—is the most common. Dafoe and Ross described a rare subtype with a long proximal pouch. Only 11 cases of a long proximal pouch have been reported in the English literature so far. We describe a neonate with long proximal pouch oesophageal atresia with distal tracheo-oesophageal fistula emphasizing the difficulty in arriving at the diagnosis.

Case presentation: A 1-week-old neonate presented with feed intolerance and failure to advance orogastric tube into the stomach. Water soluble upper gastrointestinal tract contrast revealed a blind ending proximal oesophagus at the level of the diaphragm. Gastric volvulus was considered as a diagnosis. Patient underwent a laparotomy where a normal stomach was found. Bubbles were seen coming from the fashioned gastrostomy with each inspiration. This prompted us to consider the possibility of a missed oesophageal atresia with distal tracheo-oesophageal fistula. Diagnosis was confirmed on bronchoscopy and right thoracotomy. The tracheo-oesophageal fistula was ligated and a cervical oesophagostomy and Stamm gastrostomy were performed due to irreparable tear in the long upper pouch.

Conclusion: This rare subtype of long upper pouch oesophageal atresia poses a diagnostic dilemma that can result in delay in the diagnosis and management. This diagnosis should be suspected if the tip of the orogastric/feeding tube is seen to be far below the level of the carina.

Keywords: Oesophageal atresia, Tracheo-oesophageal fistula, Long proximal pouch, Diagnostic dilemma

Background

Oesophageal atresia is a rare condition with a frequency of 1.27–4.55 per 10,000 live births with a slight male preponderance of 1.26:1 [1]. Development of the oesophagus seems to be more complex than just the cranio-caudal separation of the foregut into respiratory and oesophageal components. Probably, the middle oesophagus not only separates from the respiratory tract but also fuses with the proximal oesophagus to complete formation of the oesophageal tube. What triggers the length of the

upper pouch to vary from a short high pouch in the neck to a long pouch is unknown. Gross described five types of oesophageal atresia with type C—proximal oesophageal atresia and distal tracheo-oesophageal fistula—accounting for about 85% of the anomalies [2].

Postnatal diagnosis is confirmed by the passage of a stiff 10Fr catheter through the nose or mouth. An X-ray is then obtained with downward pressure on the tube. With oesophageal atresia, the tip of the tube is found to be curled in the blind upper pouch. Usually the upper pouch ends around the level of carina which corresponds to the second to fourth thoracic vertebral level. If the tip of the catheter passes below the level of the carina, the diagnosis of oesophageal atresia is usually questioned.

*Correspondence: machaea_s@yahoo.com
Walter Sisulu University, Mthatha, South Africa

A rare subtype of type C oesophageal atresia was first reported in 1960 [3]. In this variant, the level of the blind upper oesophageal pouch is lower than usual and leads to a diagnostic dilemma. Case reports about this rare entity have described the level of the upper pouch to end around the 6th to the 9th thoracic vertebra. This may give an impression that the tube is in the stomach and may further delay the diagnosis. Our aim is to report a newborn with the long upper pouch oesophageal atresia to emphasize the diagnostic dilemma and the rare complication of a long tear in the long upper pouch.

Case presentation

A 7-day-old newborn baby girl was referred to our centre from a base hospital 100km away. She was born by caesarean section for foetal distress (birth weight 2.23 kg) and was admitted for respiratory distress. Intravenous antibiotics and feed were started on day 2 of life. She did not tolerate feeds, developed worsening respiratory distress and needed respiratory support. A diagnosis of oesophageal atresia was suspected due to the feed intolerance and inability to pass an orogastric tube into the stomach.

Child arrived at our centre well hydrated, intubated and ventilated with markedly decreased air entry on the right side. Her oxygen saturation was 83% on FiO₂ of 90%. There were neither dysmorphic features nor cardiac murmurs on examination. Chest X-ray showed a ‘white out’ of the right lung with air in the gastrointestinal tract. The aspiration of the orogastric tube did not result in any gastric contents. A Replogle tube inserted and left on continuous low pressure suction (Fig. 1). Her cardiac echo was normal.

Upper gastrointestinal water soluble contrast was performed with a Replogle tube in situ (Fig. 2). It revealed a blind ending oesophagus below the diaphragm, at the level of the 11th thoracic vertebra. With the presumed diagnosis of gastric volvulus, laparotomy was planned on the eighth day of life. On laparotomy, stomach was found to be normal and in the correct position and orientation. This ruled out gastric volvulus. A gastrostomy was performed and an attempt to pass a feeding tube, in a retrograde manner, from the stomach into the distal oesophagus, failed. Bubbles could be seen coming out from the fashioned gastrostomy with each inspiration. This led us to consider the possibility of an oesophageal atresia with distal tracheo-oesophageal fistula.

Bronchoscopy demonstrated copious secretions in the airway and a tracheo-oesophageal fistula at the level of carina. Right posterolateral, muscle sparing thoracotomy through 5th intercostal space, was performed. Long proximal oesophageal pouch, with a large oesophageal tear/perforation (from thoracic inlet to distal stump), was

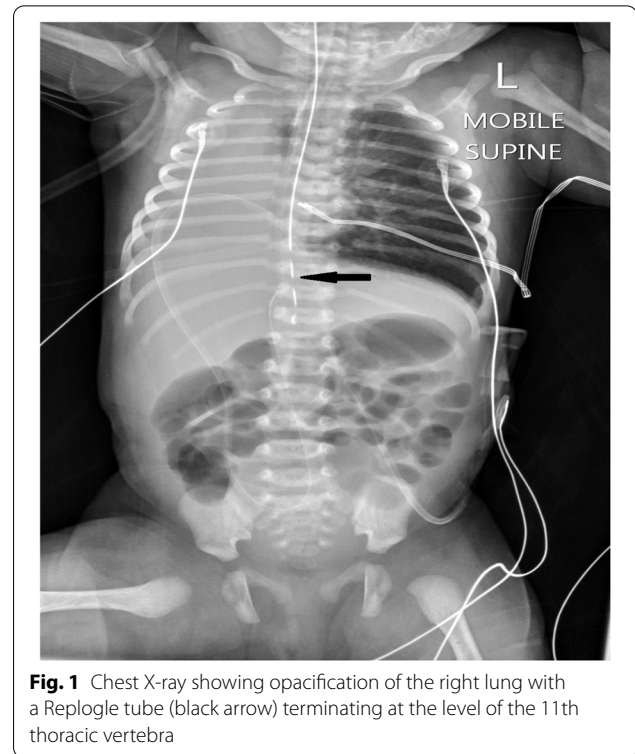
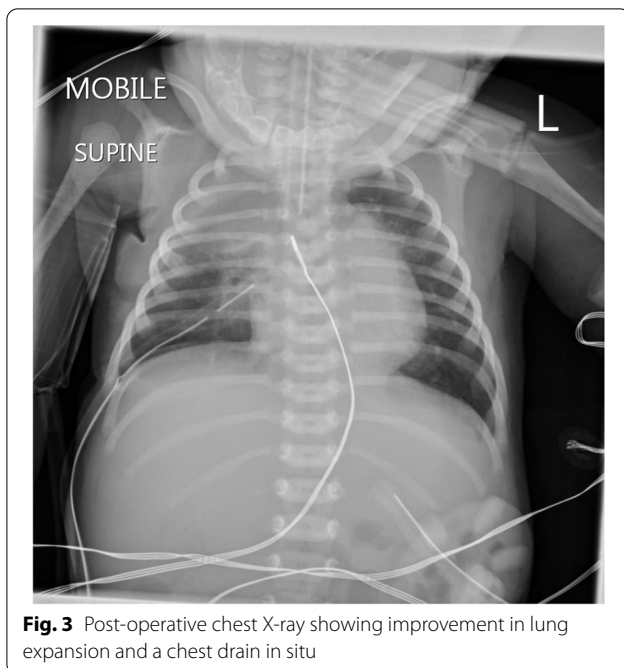


Fig. 1 Chest X-ray showing opacification of the right lung with a Replogle tube (black arrow) terminating at the level of the 11th thoracic vertebra

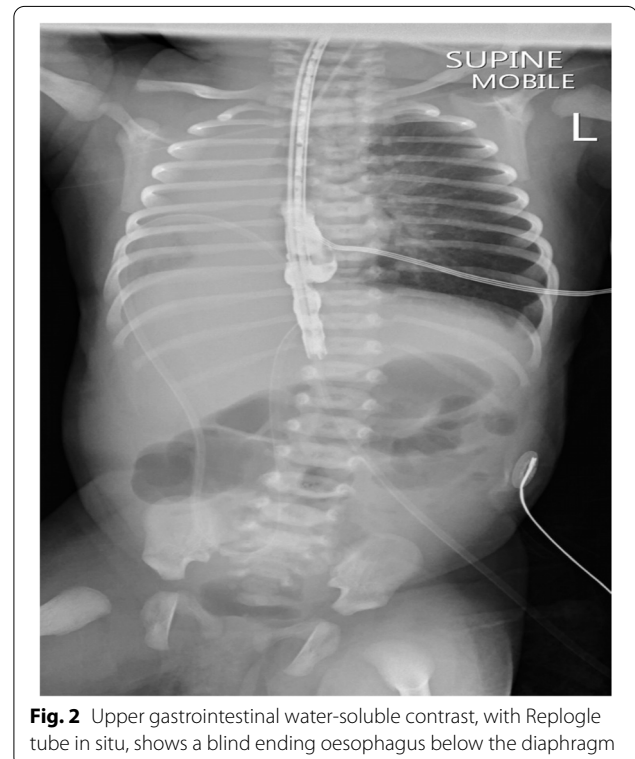

Fig. 2 Upper gastrointestinal water-soluble contrast, with Replogle tube in situ, shows a blind ending oesophagus below the diaphragm



found. Left cervical oesophagostomy and Stamm gastrostomy were fashioned as the oesophagus was deemed irreparable (Fig. 3). Child recovered from pneumonia and was discharged on D33 of life and is awaiting oesophageal replacement.

Discussion

Oesophageal atresia is a rare condition and the rarer variants present a bigger challenge in making the correct diagnosis. The delay in the diagnosis results in malnutrition due to delayed feeding and lower respiratory tract infections due to aspiration [4]. To our knowledge, only 11 cases have been reported in the English literature so far (Table 1).

Majority of the cases have been reported from the low- to medium-income countries—mainly India. There is a slight male preponderance. With oesophageal atresia, the blind ending proximal pouch normally terminates between the second and the fourth thoracic vertebral level. In most patients with this pathology reported so far, the proximal pouch terminated at the eighth thoracic vertebral level. To our knowledge, our patient had the longest reported proximal pouch, terminating at the 11th thoracic vertebra, making the diagnosis of oesophageal atresia based on imaging, highly unlikely. The majority of patients reported so far had a primary anastomosis of the proximal and distal oesophageal pouch and recovered well. Two patients had demised due to sepsis [7] and lower respiratory tract infection preoperatively [10]. Our patient

Table 1 Case report summary

| Author | Country | Sex | Outcome |
|-------------|----------|-----|----------|
| Dafoe [3] | Canada | F | Survived |
| Roe [5] | USA | F | Survived |
| Rathod [6] | Indian | F | Survived |
| Rathod [7] | Indian | ? | Demised |
| Kondo [8] | Japan | M | Survived |
| Yoshu [9] | India | M | Survived |
| Gupta [10] | India | M | Survived |
| Gupta [10] | India | M | Demised |
| Gupta [10] | India | M | Survived |
| Negash [11] | Ethiopia | F | Survived |
| Hasan [12] | India | M | Survived |

sustained an irreparable long oesophageal tear/perforation due to vigorous manipulation of the Replegle tube, a similarly uncommon occurrence in oesophageal atresia.

Whether the incidence of this rare type of oesophageal atresia is increasing, it is still to be identified. Careful assessment and preoperative imaging are essential for a successful outcome and in avoiding complications such as oesophageal injury and death [13].

Conclusion

A high index of suspicion is required to suspect and diagnose this rare anomaly as this variant has atypical findings on radiological assessment and poses a serious diagnostic dilemma. Delay in the correct diagnosis can result in morbidity and/or mortality. If diagnosed early, most of the long proximal pouch oesophageal atresia cases can have a good outcome.

Acknowledgements

Not applicable.

Authors' contributions

SM and VN collected the data and drafted the manuscript. MC supervised the authors and advised in preparation of the manuscript. All authors read and approved the final manuscript.

Authors' information

SM, Paediatric Surgery Consultant, Frere Hospital, East London and Senior Lecturer Walter Sisulu University, South Africa.
 VN, Paediatric Surgery Registrar, Frere Hospital, East London affiliated to the Walter Sisulu University, South Africa.
 MC, Associate Professor and Head of Department Paediatric Surgery, Frere Hospital, East London affiliated to the Walter Sisulu University, South Africa.

Funding

No funding required.

Availability of data and materials

The datasets used and/or analysed during the current study are available from the corresponding author on request.

Declarations

Ethics approval and consent to participate

Exemption from ethical approval was obtained from the Frere Hospital ethics committee with written informed consent obtained from the mother to participate in the case report.

Consent for publication

Written informed consent for data utilization and publication was also obtained from the mother. A copy of the written consent is available for review by the Editor-in-Chief of this journal on request.

Competing interests

The authors declare that they have no competing interests.

Received: 12 May 2021 Accepted: 13 November 2021

Published online: 03 March 2022

References

1. Wang B, Tashiro J, Allan B, Sola J, Parikh P, Hogan R. A nationwide analysis of clinical outcomes among newborns with esophageal atresia and tracheoesophageal fistula in the United States. *J Surg Res*. 2014;190(2):604–12.
2. Pinheiro P, Silva A, Pereira R. Current knowledge on esophageal atresia. *World J Gastroenterol*. 2012;18:3662–72.
3. Dafoe C, Ross C. Tracheo-esophageal fistula and esophageal atresia. *Diseases of the Chest*. 1960;37:42–51.
4. Gupta R, Barolia D, Dogra N, Singh A, Tanger R. A G. survival in esophageal atresia diagnosed on the 19th day of life: lessons learned. *Saudi Journal of Health Science*. 2018;7(3):186–8.
5. Roe B, Nobis P. Congenital tracheo-esophageal fistula: an unusual case. *American journal of disease of children*. 1963;106:489–91.
6. Rathod K, Verma S, Kanojia R, Samujh R, Rao K. Esophageal atresia with distal fistula and long overlapping upper esophageal pouch. *J Pediatr Surg*. 2011;46:2041–2.
7. Rathod K, Khanna S, Kanojia R, Rao K. A novel variant of esophageal atresia with tracheo-esophageal fistula with crossed-over proximal esophageal pouch: a diagnostic dilemma. *Dis Esophagus*. 2012;5:393–4.
8. Kondo T, Honda S, Minato M, Fujisawa S, Miyag iH, Cho K. A preoperative diagnostic challenge of a long overlapping upper pouch with distal tracheoesophageal fistula. *Journal of Neonatal Biology*. 2015; 4(4).
9. Yoshu E, Mahajan J, Dash V. Long upper pouch in esophageal atresia: a rare variant. *Journal of Neonatal Surgery*. 2016; 5(1).
10. Gupta R, Sharma P, Goyal R. Kluth type IIIb esophageal atresia: diagnostic dilemma and pitfalls of using infant feeding tube. *Journal of Indian Association of Pediatric Surgeons*. 2018;23(2):96–9.
11. Negash S, Girma H, Woldeselassie G. Esophageal atresia type C with overlapping long upper pouch: a rare variant. *Journal of Surgery Case Reports*. 2020;72:251–4.
12. Hasan Z, Choubey D, Thakur V, Kumar V, Yadav R, Rahul S. Long upper pouch overlapping with lower pouch associated esophageal atresia and trachea-esophageal fistula. *Journal of Indira Gandhi Institute of Medical Sciences*. 2020;6(1):96–7.
13. Parelkar S, Mundada D, Joshi P, Sanghvi B, Kapadnis S, Oak S. Iatrogenic perforation of upper pouch in pure esophageal atresia: a rare complication and review of literature. *European journal of Pediatric Surgery Reports*. 2013 March; 1.

Publisher's Note

Springer Nature remains neutral with regard to jurisdictional claims in published maps and institutional affiliations.

Submit your manuscript to a SpringerOpen[®] journal and benefit from:

- Convenient online submission
- Rigorous peer review
- Open access: articles freely available online
- High visibility within the field
- Retaining the copyright to your article

Submit your next manuscript at ► [springeropen.com](https://www.springeropen.com)