

RESEARCH

Open Access



Role of hepatobiliary scintigraphy with different semi-quantitative parameters along with histopathological scoring in differentiating biliary atresia from neonatal hepatitis

Nsreen R. A. Mohamadien¹, Rania Makboul², Shereen M. Galal³ and Nadia M. Mostafa^{1*}

Abstract

Background: Biliary atresia (BA) and neonatal hepatitis (NH) are the two major causes of neonatal cholestasis (NC). However, both conditions had entirely different therapeutic schedule and prognosis. Considering BA as a surgical emergency, it is pretty important to accurately differentiate the two entities. The aim of the study is to evaluate the diagnostic utility of hepatobiliary scintigraphy (HBS) using a semi-quantitative technique as well as 15-point histopathological scoring system in differentiating BA from NH.

Results: The sensitivity, specificity, and overall accuracy of HBS in the diagnosis of BA was 90.5%, 80%, and 83.6%, respectively. The median values of kidney-liver ratio (KLR), intestinal-liver ratio (ILR), and background-liver ratio (BLR) were significantly higher in patients with BA, while that of the liver-kidney ratio (LKR) was significantly lower in cases with BA. Moreover, KLR had the largest area under curve (AUC); advocates it to be the best of the semi-quantitative parameters that can predicts BA. Histopathological scoring using a cutoff point ≥ 7 was helpful in discriminating BA from NH with 85.7% sensitivity, 95% specificity and 91.8% accuracy.

Conclusions: HBS is a non-invasive diagnostic tool frequently used in diagnosis of BA, yet it has a relatively low specificity. To overcome this challenge, we kindly recommend the use of semi-quantitative parameters that could possibly improve the accuracy of HBS for diagnosing BA. Additionally, the use of 15-point scoring for liver biopsy was useful.

Keywords: Biliary atresia, Radionuclide imaging, Cholestasis, Liver biopsy

Background

Neonatal cholestatic jaundice (conjugated hyperbilirubinemia) occurs when conjugated bilirubin is higher than 1 mg/dl, if the total serum bilirubin is ≤ 5 mg/dl, or $> 20\%$ of total serum bilirubin when it is > 5 mg/dl [1]. Cholestasis is defined as reduced bile formation or flow through the intra- or extrahepatic biliary tree resulting

in accumulation of biliary substances within the liver. The incidence of neonatal cholestasis (NC) is approximately 1 in 2500 live births according to the recent guidelines for the evaluation of cholestatic jaundice in infants [2].

NC is always pathologic and signifies hepatobiliary disorder. Differential diagnoses of neonatal cholestatic jaundice include hepatocellular causes [neonatal hepatitis (NH), metabolic diseases (galactosemia, tyrosinemia, alpha one antitrypsin deficiency, parenteral nutrition-related cholestasis, and storage disorders)], ductal

* Correspondence: nadia.khalifa@med.aun.edu.eg; drnadia1980@gmail.com

¹Department of Clinical Oncology and Nuclear Medicine, Faculty of Medicine, Assiut University, Assiut, Egypt
Full list of author information is available at the end of the article



© The Author(s). 2021, corrected publication 2021. **Open Access** This article is licensed under a Creative Commons Attribution 4.0 International License, which permits use, sharing, adaptation, distribution and reproduction in any medium or format, as long as you give appropriate credit to the original author(s) and the source, provide a link to the Creative Commons licence, and indicate if changes were made. The images or other third party material in this article are included in the article's Creative Commons licence, unless indicated otherwise in a credit line to the material. If material is not included in the article's Creative Commons licence and your intended use is not permitted by statutory regulation or exceeds the permitted use, you will need to obtain permission directly from the copyright holder. To view a copy of this licence, visit <http://creativecommons.org/licenses/by/4.0/>.

paucity, and idiopathic and obstructive causes [biliary atresia (BA) and choledochal cyst] [3]. BA and NH are the two most common causes of neonatal cholestatic jaundice, yet they have similar clinical manifestations. The early correct discrimination of both conditions is mandatory for the outcome of BA and may avoid unnecessary surgery in cases with NH [4]. Hepatobiliary scintigraphy (HBS) using ^{99m}Tc -iminodiacetic acid (IDA) derivatives is a widely used functional imaging modality for differentiating BA from NH. The first and the frequently used radiopharmaceutical was ^{99m}Tc -dimethyl IDA, which was referred to as hepatic IDA (HIDA). The radiotracer excreted by the liver in a similar manner to that of bilirubin into the bile ducts. So, HIDA scan relied on the principle that the presence of tracer in the bowel confirm patency of biliary channels and excludes BA [5–7].

A normal HBS shows rapid clearance of the radiotracer from the blood pool. Prompt and uniform hepatic uptake is reached within 5 min, functional visualization of the gall bladder is seen as early as 10 min and bowel activity by 30–40 min [6].

The aim of the study was to assess the diagnostic accuracy of the semi-quantitative technique of HBS as a non-invasive diagnostic tool as well as the 15-point histopathological scoring in differentiating BA from NH in correlation with histopathological diagnosis.

Methods

Study population

This retrospective study was approved by the Institutional Committee of Medical Ethics with a waiver of consent. Between January 2018 and December 2019, a total of 73 infants (mean age 79.62 ± 32.8 days, range 30–180 days) with cholestatic jaundice were referred to nuclear medicine unit in our institution for HIDA scintigraphy. Patients did not have liver biopsy or lost their histopathological data, as well as those with final diagnosis related to causes other than NH and BA were excluded leaving a valid cohort of sixty-one infants (37 boys and 24 girls) who were enrolled in this study. Cholestasis is considered if the serum direct bilirubin level was more than 1.0 mg/dL or > 17 mmol/L [2].

Detailed clinical history was obtained from mothers of all participants. All patients were subjected to complete physical examination and laboratory investigations including serum level of bilirubin (total and fractionated), complete blood count (CBC), prothrombin (PT) time, partial thromboplastin time (PTT), international randomization ratio (INR), and urine analysis. Percutaneous liver biopsy was performed for histopathological

diagnosis after assurance of normal coagulation profile in addition to HIDA scan for all patients.

Patient preparation and HBS protocol

Pretreatment with phenobarbital (dose: 5 mg/kg/day for 5 days) to activate hepatic enzymes and increase bile flow in an attempt to reduce the risk of a false-positive results and maximize the specificity of the test in detection of BA. Patients were kept in fasting state for 2–4 h before the study (allowing only clear fluids if clinically indicated). After intravenous administration of ^{99m}Tc -HIDA (200 uci/kg) into a peripheral vein, dynamic images were acquired in a rate of one frame every second for a total 60 frames, then one frame every minute for a total of 15 frames. Serial static images were acquired at 30 min, 1, 2, 4, 6, and 24 h after radiotracer injection, using a dual head SPECT/CT gamma camera (Symbia T, Siemens Healthcare, Erlangen, Germany) fitted with a low energy all-purpose parallel hole (LEAP) collimators, using 15% energy window set at 140 KeV and matrix size of 128×128 . The infants were imaged in a supine position, arms to the side and the imaging field included the heart, liver, intestine, and urinary bladder. All precautions were taken to avoid patient movement. The images were blindly reviewed by two experienced (15 and 11 years of experience) nuclear medicine physicians (the first reader conducted the visual analysis while the second reader performed the semiquantitative analysis).

Qualitative analysis

Patients without functional visualization of the gall bladder and/or bowel up 24 h were recorded as positive for BA. In contrast, those with functionally visualized gallbladder and/or bowel (regardless of the timing or degree of excretion) [5, 6, 8] were recorded as negative for BA. In addition, the time of blood pool clearance was estimated for all cases.

Quantitative analysis

Quantitative data readings were done by drawing a region of interest (ROI) on 30-min image frame over the liver and a mirror image ROI over the left kidney, para-umbilical region (intestinal uptake), and right thigh (background). The mean count in each ROI was obtained for estimation of liver-kidney ratio (LKR), kidney-liver ratio (KLR), intestinal-liver ratio (ILR), and background-liver ratio (BLR).

Reference standard

We relayed on the results of the histopathological examination as the reference standard as all of the included patients underwent liver biopsy.

Histopathological examination

The paraffin-embedded block was sectioned and stained with Hematoxylin and Eosin stain. The biopsy materials were screened for adequacy in size and the number of portal tracts. Bile ductular proliferation, bile plugs in bile ductules, and porto-portal bridging are the standard histological features indicative of BA. The histological features indicative of NH includes lymphocytic and neutrophilic infiltration, lobular and portal inflammation and necrosis (lobular disarray), hepatocellular swelling, and giant cell transformation (Fig. 1).

Histological scoring system

The 15-point scoring system based on histology of liver biopsy, consisting of seven histological criteria to differentiate BA from NH was used. Each histological feature was scored and the sum of the scores was calculated. The score ranges from 0 to 15 points. Features against BA were negatively scored. A higher score was indicative of BA, while a lower score was less favorable for BA. A cut-off value score of ≥ 7 had the best diagnostic utility to differentiate BA from other causes of intrahepatic cholestasis [9].

Bile ductular proliferation was considered to be present if the average number of ductules was more than five in the portal tract. The degree of bile ductular proliferation was scored as no proliferation—average number of bile ductules per portal tract < 5 ; mild—average number of bile ductules per portal tract between 5 and 9; moderate—

average number of bile ductules per portal tract ≥ 10 ; and marked proliferation—attenuated, elongated, or angulated bile ductules in addition to proliferation (average number of bile ductules per portal tract ≥ 10).

Blinded histological interpretation

The interpretation of the histology slides was done blindly without knowledge of the clinical data or the final clinical diagnosis. A blinded histological diagnosis was made for each histological specimen and was labeled as BA or NH.

Statistical analysis

Data analysis was performed using SPSS version 21.0 (IBM Corp, Armonk, NY, USA). Based on histopathological examination, sensitivity, specificity, positive and negative predictive values, and diagnostic accuracy of ^{99m}Tc -HIDA scan were computed for BA versus NH and were compared with those of other imaging and laboratory investigations. Descriptive statistics of quantitative variables as mean \pm SD, median (IQR) and range, as well as description of qualitative variables as number and percentage were used. The non-parametric Mann-Whitney test was used to compare medians between the two groups while independent sample *T* test was used to compare mean between groups in normally distributed data. Chi-square test was used to compare qualitative variables. Area under the curve from ROC curve analysis

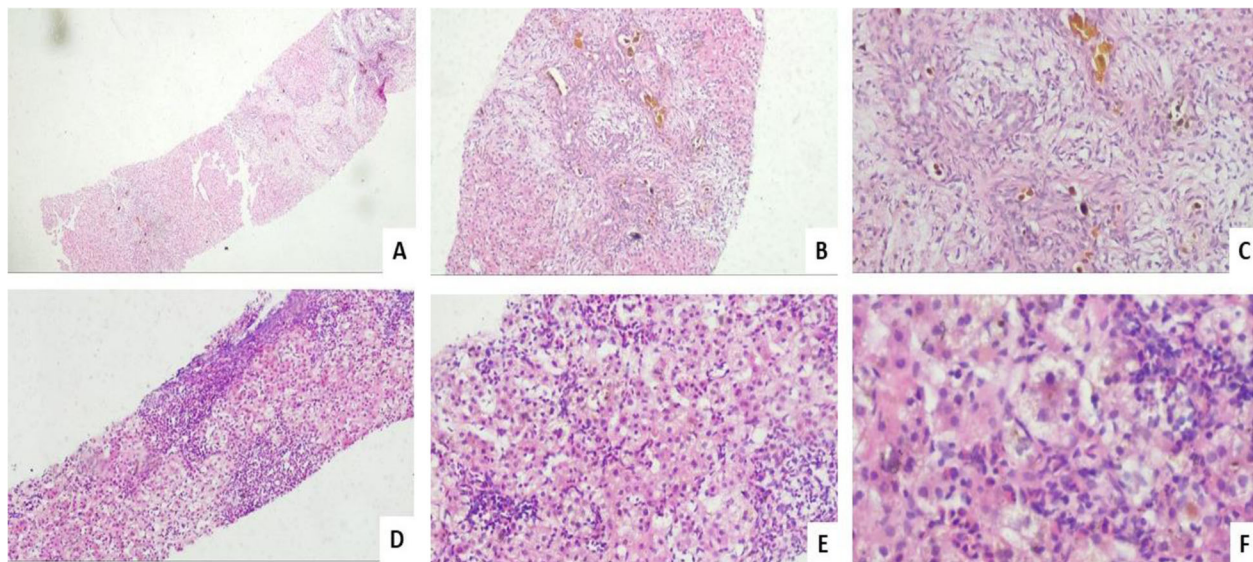


Fig. 1 **a** Liver core stained by H&E of a case of BA showing periportal fibrosis ($\times 40$). **b, c** Higher power view of previous case showing bile ductular proliferation, bile plugs, portal fibrosis and neutrophilic infiltration ($\times 200$, $\times 400$ respectively). **d** Liver core stained by H&E of case of NH showing periportal and lobular inflammation ($\times 100$). **e** Higher power of previous case showing lobular inflammation and lobular disarray ($\times 200$). **f** High power of a case of NH showed cholestasis, lobular inflammation and giant cell formation ($\times 400$)

was used to evaluate the different ratios. Significant relationship was considered when P value was < 0.05

Results

Sixty-one infants with cholestatic jaundice were enrolled in this retrospective study in the period between January 2018 and December 2019, including 37 boys and 24 girls. The mean age at presentation was 79.62 days \pm 32.8 SD (range 30–180 days). The main clinical presentation in all infants was jaundice, other associated symptoms were acholic stool, dark urine, and fever in 18, 18, and 6 cases respectively. Mean serum direct bilirubin was 9.62 (SD \pm 23.71). Serological screening for TORCH syndrome was negative in 51 cases and positive in 10 cases. According to histopathological examination of liver biopsies, the final diagnosis of BA was established in 21 (34.4%) infants while the other 40 (65.6%) cases where diagnosed as NH. The clinical and laboratory characteristics of the cases are illustrated in Table 1.

The mean total scoring was significantly higher for BA compared to NH group (9.1 vs. 3.8, $P < 0.01$). The histopathological scoring of both conditions was summarized in Table 2. Where portal duct proliferation, bile plug in portal tract, and porto-portal bridging were significantly more frequent in cases with BA ($P < 0.001$). Lymphocytic infiltrate in portal region, multinucleated hepatocyte, neutrophils in the infiltrate, and hepatocellular swelling were more frequent in cases with NH ($P = 0.048, 0.167, 0.297, \text{ and } 0.176$ respectively). Regarding the pathological diagnosis using 15-point scoring system, 41 cases were diagnosed as NH and 20 as BA. True positive and true negative findings were identified in 18/20 and 38/41 cases respectively, giving 85.7% sensitivity, 95% specificity, 92.7% NPV, 90% PPV, and 91.8% accuracy (Chi-square 70.7, $P < 0.01$).

Receiver operating characteristic [ROC] curve analyses showed a significant validity of histopathological scoring for diagnosis of BA (AUC: 0.949; SE: 0.028; 95% CI: 0.893–1.000, $P < 0.001$) (Fig. 2).

The final results of HIDA scintigraphy revealed BA in 27 infants and NH in the remaining 34 infants. Relying on histopathological examination, 19/27 and 32/34 cases were proved to be true positive (Figs. 3 and 4) and true negative (Fig. 5) respectively, giving 90.5% sensitivity, 80% specificity, 70.4% PPV, 94.1% NPV, and 83.6% accuracy (Chi-square 27.7, $P < 0.001$). The time of blood pool clearance was significantly higher in cases with BA ($P = 0.034$). Using the semi-quantitative analysis of the HIDA scintigraphy, the median values of KLR, ILR, and BLR were significantly higher in cases with BA (P value = 0.008, 0.011, 0.016 respectively) while that of the LKR was significantly lower in cases with BA ($P = 0.006$) (Table 3). Parameters which showed significant association with the diagnosis of BA were

subjected to further analysis with ROC to determine which of them is the best to predict the diagnosis of BA. We found that KLR, ILR, BLR, and time of blood pool clearance were fairly predictive of BA with KLR had the largest AUC of 0.707 (95% CI: 0.573–0.840, $P = 0.008$), indicating that KLR was the best of the semi quantitative parameters in predicting BA (Fig. 6) (Table 4).

Table 1 Clinical and laboratory characteristics

| Parameter | Pathologic diagnosis | | P value |
|-------------------|-------------------------|-------------------------|---------|
| | BA (21) Number and % | NH (40) Number and % | |
| Age: | | | 0.152** |
| • Mean (SD) | 70 \pm 30.5 | 84.7 \pm 33.3 | |
| • Median(IQR) | 60 (45) | 90 (52.5) | |
| Total bilirubin | | | 0.802** |
| • Mean (SD) | 13 \pm 14.9 | 10 \pm 6.5 | |
| • Median (IQR) | 8.05 (7) | 8.65 (11) | |
| Direct bilirubin | | | 0.641** |
| • Mean (SD) | 15 \pm 38.5 | 6 \pm 4.2 | |
| • Median (IQR) | 6.5 (5) | 5 (7) | |
| Sex | | | 0.684* |
| • Male | 12(57.1%) | 25 (62.5%) | |
| • Female | 9 (42.9%) | 15 (37.5%) | |
| Stool color | | | 0.635* |
| • Pigmented | 14 (66.7%) | 29 (72.5%) | |
| • Acholic | 7 (33.3%) | 11 (27.5%) | |
| Dark urine | | | 0.907* |
| • Present | 6 (28.6%) | 12 (30%) | |
| • Absent | 15 (71.4%) | 28 (70%) | |
| Liver size | | | 0.545* |
| • Normal | 11 (52.4%) | 20 (50%) | |
| • Absent | 8 (38.1%) | 12 (30%) | |
| • Not assessed | 2 (9.5%) | 8 (20%) | |
| ICU admission: | | | 0.662* |
| • Yes | 8 (38.1%) | 13 (32.5%) | |
| • No | 13 (61.9%) | 27 (67.5%) | |
| Blood transfusion | | | 0.576* |
| • Yes | 3 (15%) | 8 (21%) | |
| • No | 17 (85%) | 30 (79%) | |
| Fever | | | 0.335* |
| • Present | 1 (4.8%) | 5 (12.5%) | |
| • Absent | 20 (95.2%) | 35 (87.5%) | |
| TORCH | | | 0.455* |
| • Positive | 5 (23.8%) | 5 (12.5%) | |
| • Negative | 16 (76.2%) | 35 (87.5%) | |

Statistical relationships were evaluated by Chi-square test*, Mann-Whitney test**. SD standard deviation

Discussion

Through the many causes of persistent cholestatic jaundice in infancy, BA and NH account for 70–80% of cases [9]. Yet, both conditions had completely different therapeutic schedule and prognosis [10]. BA is a surgical emergency, Kasai portoenterostomy surgical treatment ideally performed in the first 60 days of life. If the surgery is not performed within 90 days, it will progress into liver cirrhosis and hepatic failure which is difficult to recover a normal condition [11]. On the other hand, conservative treatment is very effective in the management of almost all cases of NH [12]. So, it is pretty important to accurately differentiate BA from medical causes, mainly NH.

However, no preoperative diagnostic algorithm has proven 100% diagnostic accuracy for BA [3].

Consistent with many previous studies [9, 11–15], the current study demonstrated that NC is more frequent in male patients (37 males vs. 24 females). Based on histopathological examination of liver biopsy, 21 cases (12 males and 9 females, 34.4%) were diagnosed as BA while the remaining 40 cases (25 males and 15 females, 65.6%) were diagnosed as NH. In keeping with other studies [12, 16, 17], we found that BA tend to present at a relatively younger age compared to NH (mean age at the time of HBS was 70 ± 30.5 days for BA vs. 84.7 ± 33.3 days for NH). On the other contrary, Zhou et al. found

Table 2 Histopathological scoring

| Scoring parameter | Pathologic diagnosis | | P value |
|---|-------------------------|-------------------------|----------|
| | BA (21) Number and % | NH (40) Number and % | |
| Portal duct proliferation: | | | < 0.001* |
| • None (0) | 1 (4.8%) | 33 (82.5%) | |
| • Mild (1) | 2 (9.5%) | 4 (10%) | |
| • Moderate (2) | 9 (42.9%) | 3 (7.3%) | |
| • Marked (3) | 9 (42.9%) | 0 (0.0%) | |
| Bile plug in portal ductules | | | < 0.001* |
| • Absent (0) | 5 (23.8%) | 34 (85%) | |
| • Present (2) | 16 (76.2%) | 6 (15%) | |
| Porto-portal bridging: | | | < 0.001* |
| • None (0) | 3 (14.3%) | 34 (85%) | |
| • < 50% of portal tracts (1) | 9 (42.9%) | 5 (12.5%) | |
| • > 50% of portal tracts (2) | 9 (42.9%) | 1 (2.5%) | |
| Lymphocytic infiltrate in portal region | | | 0.048* |
| • None (2) | 0 (0%) | 0 (0%) | |
| • Mild (1) | 14 (66.7%) | 16 (40%) | |
| • Moderate/Sever (0) | 7 (33.3%) | 24 (60%) | |
| Multinucleated hepatocyte | | | 0.167* |
| • None (2) | 9 (42.9%) | 8 (20%) | |
| • Only around central vein (1) | 8 (38.1%) | 21 (52.5%) | |
| • Diffuse (0) | 4 (19%) | 11 (27.5%) | |
| Neutrophils in the infiltrate: | | | 0.297* |
| • Absent or mild (1) | 21 (100%) | 38 (95%) | |
| • Moderate or marked (0) | 0 (0.0 %) | 2 (5%) | |
| Hepatocellular swelling | | | 0.176* |
| • None (2) | 6 (28.6%) | 4 (10%) | |
| • Mild/focal (1) | 11 (52.4%) | 26 (65%) | |
| • Periportal / diffuse (0) | 4 (19%) | 10 (25%) | |
| Total score | | | < 0.01** |
| Mean \pm SD | 9.1 \pm 2.5 | 3.8 \pm 1.6 | |

Statistical relationships were evaluated by Chi-square test* and independent sample t-test**

that both BA and NH groups had approximately the same age at the time of HBS [11]. We did not find a significant relationship between BA and acholic stool (reported in only 33.3% of BA cases, $P = 0.635$). This comes in contrast to Abou-Taleb et al. and Dehghani et al. who observed a significant correlation (acholic stool was found in 100% ($P = 0.0001$) and 95% ($P = 0.003$) of BA cases), respectively [12, 17]. However, similar to both of them, our study did not reveal a significant association between BA and the level of serum direct bilirubin. In agreement with relevant reports, we found that HBS had an overall accuracy of 83.6% in diagnosing BA [12, 18]. Several studies reported variable degrees of sensitivity (84.6–100%) and specificity (61.1–88.6%) for the HBS in diagnosing BA [19–23]. In a large meta-analysis discussing the accuracy of ^{99m}Tc -IDA HBS in differentiating BA from NH, Kianifar et al. have reported a pooled sensitivity of 98.7% and a pooled specificity of 70.4%; the reported high sensitivity was due to the extremely rare false negative results recorded [24]. In the current study, HBS had a sensitivity of 90.5% and a specificity of 80% in diagnosing BA. We observed bowel activity in two cases ultimately diagnosed as BA (false negative for BA), at 30-min image in one case and 2-h image in the other (Fig. 7). Given the progressive obliterative nature of BA, it is not surprising for HBS to show tracer excretion owing to the scan timing in respect to the degree of occlusion of extra-hepatic bile ducts. Muthukanagarajan et al. recorded that only 20% of BA showed complete fibroinflammatory obliteration [25].

This is matched with a recent case series study that reported biliary excretion in 6 infants finally diagnosed as BA. Despite the presence of tracer excretion, yet it was abnormal in all of the included infants (either delayed (6- and 24-h image) or subtle detected activity). Thus, they hypothesized that excluding BA relying on detection of any radioactivity in the intestine without consideration of the degree or timing of excretion is an erroneous conclusion that could result in delayed diagnosis and treatment of BA with subsequent inevitable negative impact on the outcome [26]. Kim et al., in a case report, found bowel activity at 4-h image during HBS for an infant with NC, finally diagnosed to have BA. It was attributed to the presence of a remnant slit-like patent lumen in the pathological specimen that allowed bile/tracer transit into the duodenum in this patient [27].

On the other hand, we encountered 8 cases with false positive results for BA in our study (did not demonstrate tracer excretion up to 24-h imaging despite final diagnosis of NH, Fig. 8). In part, this could be attributed to severe NH which was evident in 6 cases resulting in poor hepatocellular extraction, no tracer excretion, and consequently non-visualization of bowel. Low birth weight, prematurity, and total parenteral nutrition also decrease the capacity to excrete the radiotracer into the intestine, any of them could be another contributing factor [15]. However, due to the retrospective nature of our study, these clinical data were not amenable for us.

In the other part, co-existing mechanical obstruction of non-BA origin might be suggested in the remaining

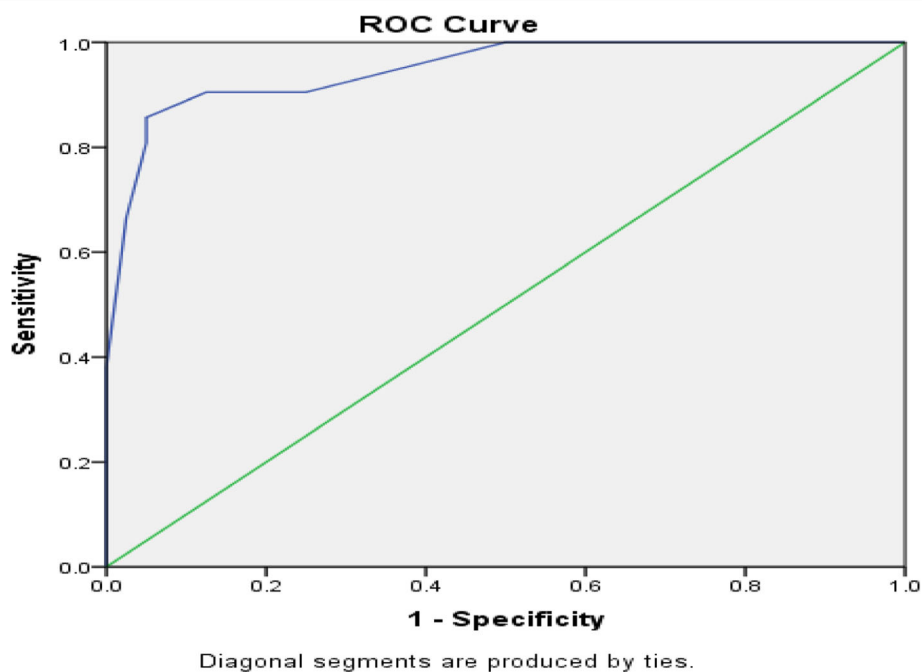


Fig. 2 Association between histopathological scoring and diagnosis of BA

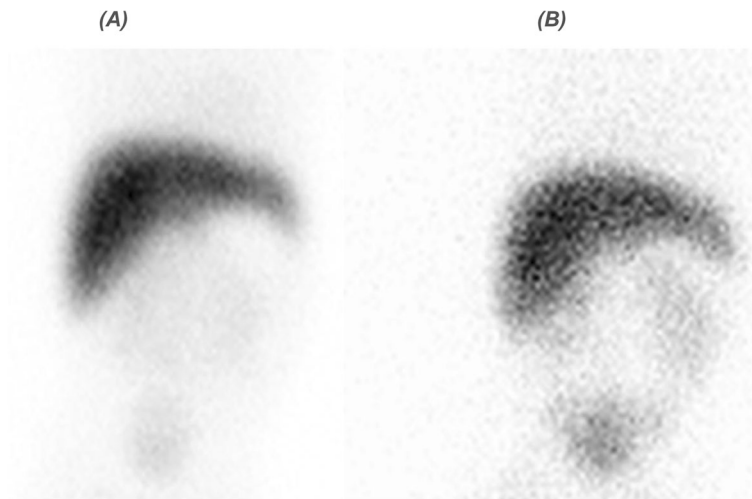


Fig. 3 HIDA scan of a 59-day-old infant with cholestatic jaundice: no bowel activity could be seen at 2-h image (a) up to 24-h imaging (b) following radiotracer injection; it was interpreted as positive for BA as well as the final diagnosis (true positive for BA). Histopathological score was 13

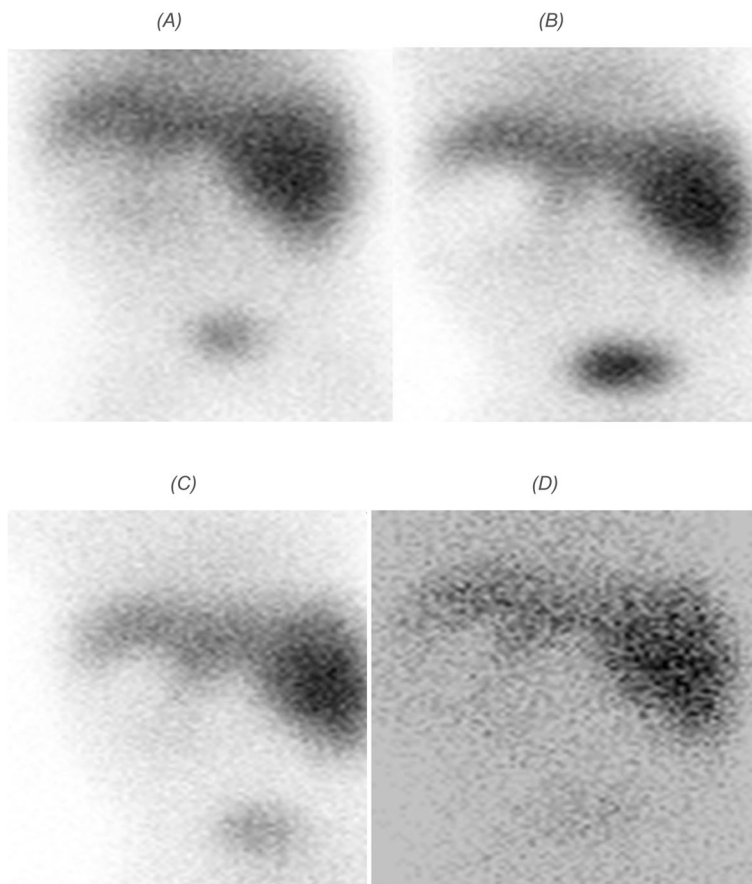


Fig. 4 HIDA scan of a 55-day-old infant with cholestatic jaundice: interestingly, this case incidentally discovered to have situs inversus during the examination. No bowel activity could be seen at 15-min (a), 1-h (b), 6-h (c), and 24-h imaging (d) following radiotracer injection with evident renal clearance into urinary bladder, it was interpreted positive for BA as well as the final diagnosis (true positive for BA). Histopathological score was 10

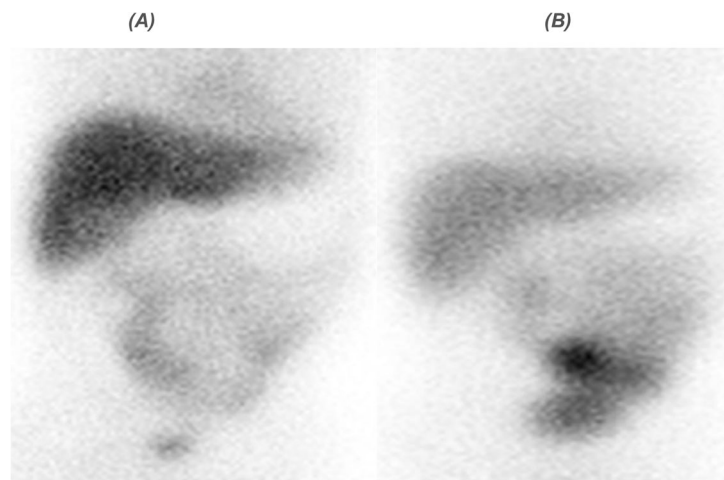


Fig. 5 HIDA scan of an 85-day-old infant with cholestatic jaundice: bowel activity was evident at 1-h image (a) which increased over time up to 4-h imaging (b) following radiotracer injection; it was interpreted negative for BA and finally diagnosed as NH (true negative for BA). Histopathological score was 4

two cases, as both of them showed reasonable hepatic extraction with persistent hepatogram up to 24-h image. However, one infant had lost to follow up while the other infant died before further diagnostic interventional procedures were conducted. Brittain et al. falsely interpreted 4 cases as BA, finally proved to have mechanical obstruction of non-BA etiology on laparotomy [22].

Adding single-photon emission computed tomography/computed tomography (SPECT/CT) in cases of no or atypical drainage could be helpful for evaluating the non-BA origin. A previous study documented that

combining HBS with SPECT/CT resulted in improved specificity and accuracy in diagnosing BA [27].

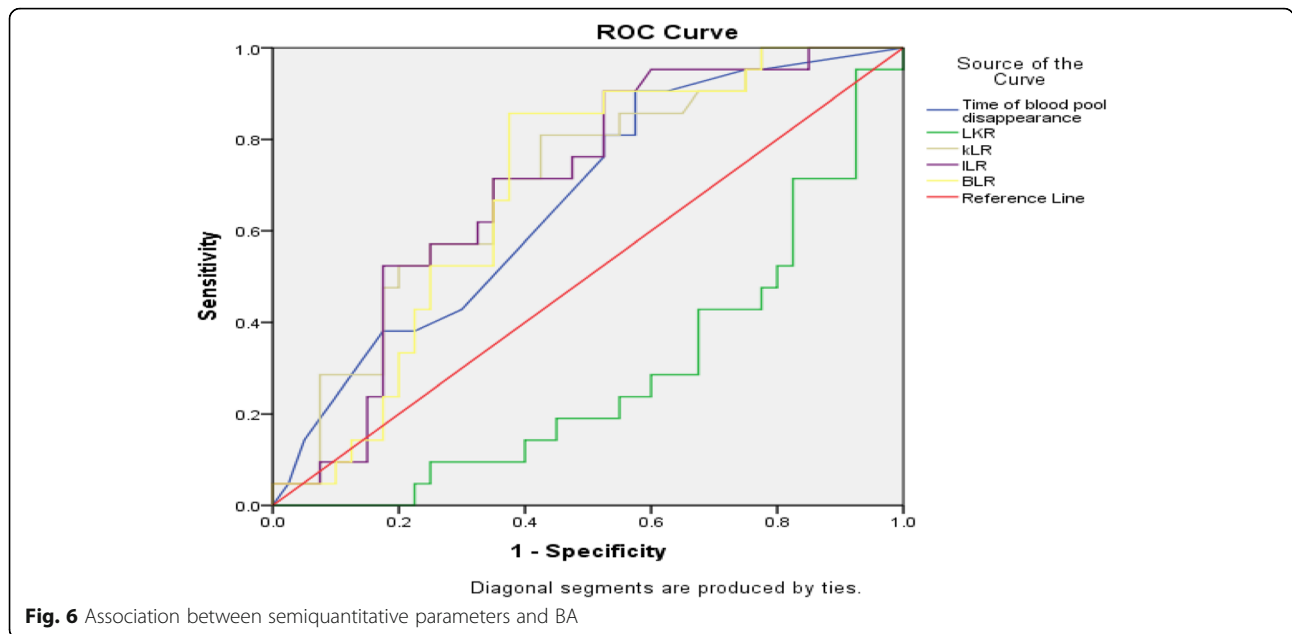
As shown by the present study, the false-positive results are the major constraint for HBS. Accordingly, we aimed to retrospectively evaluate the diagnostic efficiency of the semi-quantitative approach of HBS in an attempt to improve the specificity in addition to reducing the examination time required to reach a correct diagnosis. We utilized semiquantitative methods to calculate LKR, KLR, ILR, and BLR. To our knowledge, no previous study has evaluated the last 3 parameters (KLR, ILR, and BLR) as semi-quantitative parameters of HBS for suspected BA. We found that all of them demonstrated high specificity (97.5%) and sensitivity (95.5–100%) in diagnosing BA. We noticed that LKR was significantly lower for BA group than for NH group ($P = 0.006$), which comes in contrast to Liu et al. who used the same index to differentiate BA from NH and demonstrated that LKR of BA group was slightly higher than for NH group ($P < 0.05$) [28]. In the current study, significantly higher time of blood pool clearance noted in cases of BA ($P = 0.034$) could explain this un-expected finding which denoting impaired hepatic extraction efficiency with consequently alternative renal excretion. The higher mean of age (79.62 ± 32.8 days) of our study population compared to that of Liu et al.'s study (45.9 ± 23.4 days) might be the main underlying etiology for this discrepancy. Furthermore, a relatively small sample size and different IDA agent used in our study could be other aiding factors for different results.

In contrast, KLR, ILR, and BLR were significantly higher in cases with BA ($P = 0.008$, 0.011 , and 0.016 respectively). It is worth noting that KLR had a higher AUC (0.707) than ILR and BLR (0.698 for both)

Table 3 Semiquantitative analysis of HIDA scan

| Parameter | Pathologic diagnosis | | P-value |
|------------------------------|----------------------|-------------|---------|
| | BA (21) | NH (40) | |
| Blood pool clearance in min. | | | |
| • Mean (SD) | 62.3 ± 95.9 | 31.8 ± 66.8 | 0.034** |
| • Median (IQR) | 15 (46) | 15 (28) | |
| LKR: | | | |
| • Mean (SD) | 2.13 ± 2 | 4.8 ± 4.1 | 0.006** |
| • Median (IQR) | 1.6 (2) | 3.2 (5.5) | |
| KLR: | | | |
| • Mean (SD) | 0.8 ± 0.6 | 0.48 ± 0.5 | 0.008** |
| • Median (IQR) | 0.6 (0.9) | 0.3 (0.4) | |
| ILR: | | | |
| • Mean (SD) | 0.4 ± 0.25 | 0.3 ± 0.25 | 0.011** |
| • Median (IQR) | 0.4 (0.3) | 0.2 (0.2) | |
| BLR: | | | |
| • Mean (SD) | 0.22 ± 0.15 | 0.14 ± 0.1 | 0.016** |
| • Median (IQR) | 0.2 (0.1) | 0.1 (0.1) | |

Mann-Whitney test**



indicating that KLR was the best semi-quantitative parameter to predict BA.

Regarding the 15-points histopathological scoring system, our results revealed that the median histopathological score to be 9 for BA and 3.5 for NH, which is comparable to 10 for BA and 4 for NH in a recent similar study [15]. As mentioned above, we encountered a total of 10 false results for BA in our HBS evaluation. Two false negative results, both of them demonstrated high histopathological scoring (≥ 7). On the other hand, 8 false positive results were reported, except for only one result had score (≥ 7); the other 7 demonstrated low histopathological scoring (< 7). Comparable to the results of previous studies [29, 30], we found that histopathological scoring with a cutoff point ≥ 7 had 85.7% sensitivity and 95% specificity for predicting BA. Also, Prasath Sathiah et al. reported a similar specificity (96% vs. 95%), yet a higher sensitivity (92% vs. 85.7%) for histopathological scoring. Different reported sensitivity may be attributable to different reference standard used for analysis; we relied on histopathological examination of liver biopsy as a reference standard while the gold standard in the other study was per-operative cholangiogram [15].

Limitations

Being a retrospective study, clinical data were not completely accessible. In addition, sonographic evaluation of the gall bladder as well as the serum level of gamma-glutamyl transpeptidase which were previously reported as strong indicators for BA [12, 16, 31] were not available. On the other hand, the advantages of the current study included utilization of novel time saving semi-quantitative parameters in addition to histopathological scoring that was conducted by an experienced pathologist.

Conclusion

HBS is a non-invasive diagnostic tool, which is frequently used in diagnosis of BA. Despite its high sensitivity, the specificity of this imaging modality is relatively low. The time-saving semi-quantitative approach evaluated in our study had an incremental value in improving the diagnostic performance of HBS in diagnosing BA; we found that KLR was the best used novel parameter for this purpose. However, larger multicenter studies are needed before this approach can be applied. In addition, our findings confirmed the importance of a detailed histo-morphological evaluation of liver biopsy in all cases of NC.

Table 4 AUCs of the quantitative parameters

| Variable | AUC (95% CI) | Cut-off | Sensitivity | Specificity | P value |
|------------------------------|---------------------|----------------|-------------|-------------|---------|
| LKR | 0.286 (0.154–0.417) | ≥ 0.49 | 95.2 | 97.5 | 0.006 |
| KLR | 0.707 (0.573–0.840) | ≥ 0.063 | 100 | 97.5 | 0.008 |
| ILR | 0.698 (0.565–0.831) | ≥ 0.048 | 100 | 97.5 | 0.011 |
| BLR | 0.698 (0.556–0.823) | ≥ 0.027 | 100 | 97.5 | 0.016 |
| Time of blood pool clearance | 0.664 (0.525–0.803) | ≥ 1.5 min | 95.2 | 77.5 | 0.036 |

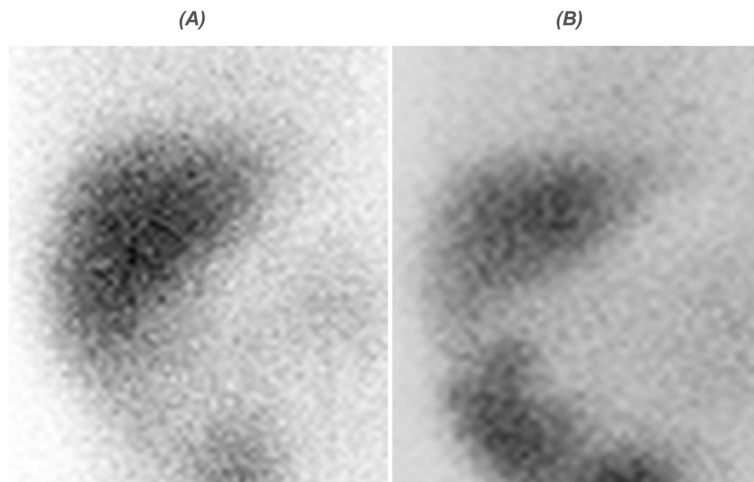


Fig. 7 HIDA scan of a 60-day-old infant with cholestatic jaundice: no bowel activity could be seen up to 1-h image (a), while evident tracer excretion into bowel was noted at 2-h imaging (b) following radiotracer injection. It was interpreted as negative for BA, yet finally diagnosed as BA (false negative for BA). Histopathological score was 10

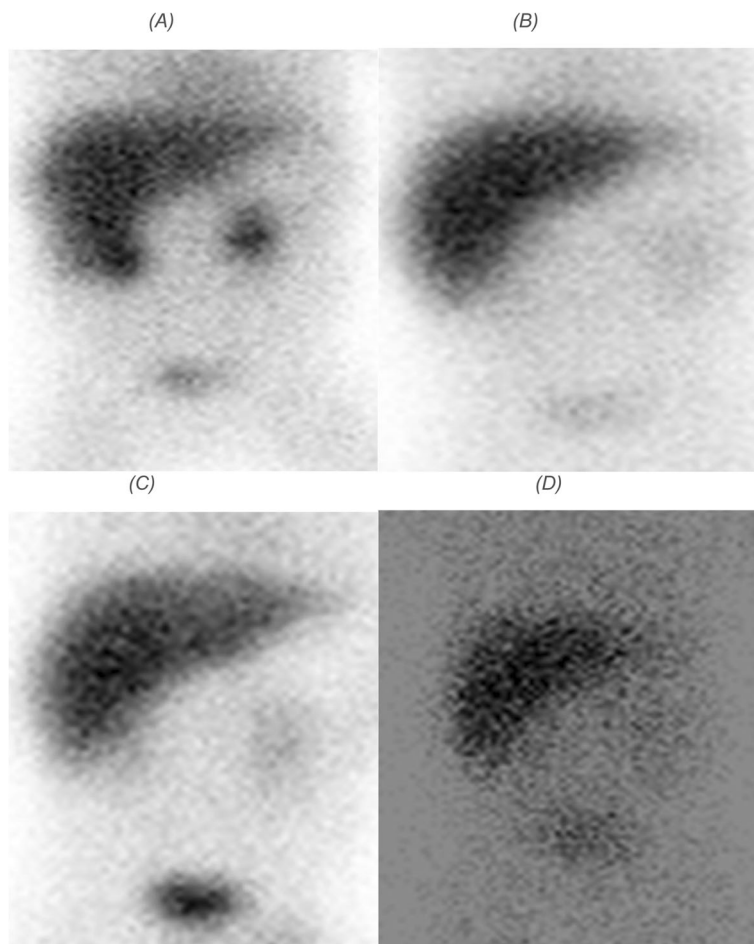


Fig. 8 HIDA scan of a 32-day-old infant with cholestatic jaundice: no bowel activity could be seen at 30-min (a), 4-h (b), 6-h (c), and 24-h imaging (d) following radiotracer injection. It was interpreted as BA, yet finally diagnosed as NH (false positive for BA). Histopathological score was 2

Abbreviations

BA: Biliary atresia; NH: Neonatal hepatitis; NC: Neonatal cholestasis; HBS: Hepatobiliary scintigraphy; HIDA: Hepatobiliary iminodiacetic acid; LKR: Liver-kidney ratio; KLR: Kidney-liver ratio; ILR: Intestinal-liver ratio; BLR: Background-liver ratio; HIDA: Hepatic iminodiacetic acid

Acknowledgements

Not applicable.

Authors' contributions

Study concepts: NM, NR, RM, SM. Study design: NM, NR, RM. Data acquisition: NR, RM. Data analysis and interpretation: NM, NR, RM. Statistical analysis: NR. Manuscript preparation: NM, NR, RM. Manuscript editing: NM. Manuscript review: NM, NR, RM, SM. All authors read and approved the final manuscript.

Funding

No external funding was obtained for this study.

Availability of data and materials

The datasets used and analyzed during the current study are available from the corresponding author on reasonable request.

Declarations

Ethics approval and consent to participate

This study was performed in line with the principles of the Declaration of Helsinki. Approval was granted by the Ethics Committee of faculty of medicine, Assiut University, Egypt, with IRB number 17300342. Informed consent was waived due to the retrospective nature of the study.

Consent for publication

No separate individual consent was obtained from patients' parents for this study as it was retrospective in nature, and the examinations were carried out as part of routine clinical care. No patient-identifying information is included in the manuscript material.

Competing interests

The authors declare that they have no competing interest.

Author details

¹Department of Clinical Oncology and Nuclear Medicine, Faculty of Medicine, Assiut University, Assiut, Egypt. ²Department of Pathology, Faculty of Medicine, Assiut University, Assiut, Egypt. ³Department of Pediatrics, Faculty of Medicine, Assiut University, Assiut, Egypt.

Received: 20 January 2021 Accepted: 30 March 2021

Published online: 16 April 2021

References

- De Bruyne R, Van Biervliet S, Vande VS, Van Winckel M (2011) Clinical practice. *Eur J Pediatr* 170(3):279–284. <https://doi.org/10.1007/s00431-010-1363-8>
- Fawaz R, Baumann U, Ekong U, Fischler B, Hadzic N, Mack CL et al (2017) Guideline for the evaluation of cholestatic jaundice in infants: joint recommendations of the north American Society for Pediatric Gastroenterology, Hepatology, and nutrition and the European Society for Pediatric Gastroenterology, Hepatology, and nutrition. *J Pediatr Gastroenterol Nutr* 64(1):154–168
- Mandelia A, Lal R, Mutt N (2017) Role of hepatobiliary scintigraphy and preoperative liver biopsy for exclusion of biliary atresia in neonatal cholestasis syndrome. *Indian J Pediatr* 84(9):685–690. <https://doi.org/10.1007/s12098-017-2408-z>
- He J-P, Hao Y, Wang X-L, Yang X-J, Shao J-F, Feng J-X (2016) Comparison of different noninvasive diagnostic methods for biliary atresia: a meta-analysis. Springer
- Cistaro A, Massollo M (2016) Nuclear medicine in pediatric gastrointestinal diseases. In: *Clinical nuclear medicine in pediatrics*. Springer, pp 149–171
- Anand SS, Handa RK, Singh J, Sinha I (2006) Hepato-biliary scintigraphy in diagnosis of biliary atresia. *Med J Armed Forces India* 62(1):20–21. [https://doi.org/10.1016/S0377-1237\(06\)80146-2](https://doi.org/10.1016/S0377-1237(06)80146-2)
- Elgazzar AH, Sarikaya I (2018) Hepatobiliary system. In: *Nuclear medicine companion*. Springer, pp 203–217
- Krebs S, Dunphy M (2017) Role of nuclear medicine in diagnosis and management of hepatopancreatobiliary disease. In: *Blumgart's surgery of the liver, biliary tract and pancreas, 2-volume set*. Elsevier, pp 285–315
- Sultana N, Jabin Z, Bashir M, Parveen R, Begum SMF, Begum R et al (2015) Role of hepatobiliary scintigraphy and ultrasonography in the diagnosis of biliary atresia in infant with neonatal jaundice—experiences in NINMAS. *Bangladesh J Nucl Med* 18(1):51–53
- Rebollar-Rangel JA, Escobedo-Torres P, Flores-Nava G (2017) Etiology of neonatal jaundice in children admitted for phototherapy. *Rev Mex Pediatr* 84(3):88–91
- Zhou H, Li J, Wei H, Li A, Wang X, Zhang X, Lu Q, Chen S, Wei Z (2020) A novel timesaving and semiquantitative method for radionuclide hepatobiliary scintigraphy for suspected biliary atresia. *Ann Palliat Med* 9(1):63–69. <https://doi.org/10.21037/apm.2019.12.07>
- Abou-Taleb A, Abdelhameed W, Ahmed A, El-Hennawy A (2019) Non-invasive diagnostic methods for differentiation of biliary atresia from neonatal hepatitis in upper Egypt. *Int J Pediatr* 7(4):9265–9275
- Sathiah P, Basu D, Kar R, Jagadisan B, Kumaravel S (2018) Evaluation of liver biopsies using histopathological scoring system in neonatal hepatitis and biliary atresia: correlation with clinico-radiological and biochemical parameters. *J Clin Diagn Res* 12(2):15–19
- Yang J-G, Ma D-Q, Peng Y, Song L, Li C-L (2009) Comparison of different diagnostic methods for differentiating biliary atresia from idiopathic neonatal hepatitis. *Clin Imaging* 33(6):439–446. <https://doi.org/10.1016/j.clinimag.2009.01.003>
- Dehghani SM, Haghightat M, Imanieh MH, Geramizadeh B (2006) Comparison of different diagnostic methods in infants with cholestasis. *World J Gastroenterol* 12(36):5893–5896. <https://doi.org/10.3748/wjg.v12.i36.5893>
- Dong C, Zhu H, Chen Y, Luo X, Huang Z (2018) Clinical assessment of differential diagnostic methods in infants with cholestasis due to biliary atresia or non-biliary atresia. *Curr Med Sci* 38(1):137–143. <https://doi.org/10.1007/s11596-018-1857-6>
- Donia AES, Ibrahim SM, Kader M, Saleh AM, El-Hakim MS, El-Shorbagy MS et al (2010) Predictive value of assessment of different modalities in the diagnosis of infantile cholestasis. *J Int Med Res* 38(6):2100–2116. <https://doi.org/10.1177/147323001003800626>
- Ghazy RM, Adawy NM, Khedr MA, Tahoun MM (2018) Biliary atresia recent insight. *Egypt Pediatr Assoc Gaz* 66(1):1–8. <https://doi.org/10.1016/j.jepag.2017.12.001>
- Kianifar HR, Tehrani S, Shojaei P, Adinehpour Z, Sadeghi R, Kakhki VRD, Keshtgar AS (2013) Accuracy of hepatobiliary scintigraphy for differentiation of neonatal hepatitis from biliary atresia: systematic review and meta-analysis of the literature. *Pediatr Radiol* 43(8):905–919. <https://doi.org/10.1007/s00247-013-2623-3>
- Muthukanagarajan SJ, Karnan I, Srinivasan P, Sadagopan P, Manickam S (2016) Diagnostic and prognostic significance of various histopathological features in extrahepatic biliary atresia. *J Clin Diagn Res JCDR* 10(6):EC23
- Adeyemi A, States L, Wann L, Lin HC, Rand EB (2020) Biliary excretion noted on hepatobiliary iminodiacetic acid scan does not exclude diagnosis of biliary atresia. *J Pediatr* (220):245–248
- Kim H, Park S, Ha S, Kim JS, Kim DY, Oh M (2019) False-negative hepatobiliary scintigraphy for biliary atresia. *Nucl Med Mol Imaging* 53(5):356–360. <https://doi.org/10.1007/s13139-019-00606-w>
- Brittain JM, Kvist N, Johansen LS, Borgwardt L (2016) Hepatobiliary scintigraphy for early diagnosis of biliary atresia. *Dan Med J* 63:A5253
- Sevilla A, Howman-Giles R, Saleh H, Trpezanovski J, Concannon R, Williams K, Chung D, Uren R (2007) Hepatobiliary scintigraphy with SPECT in infancy. *Clin Nucl Med* 32(1):16–23. <https://doi.org/10.1097/01.rlu.0000249860.41139.a6>
- Liu X, Qi-Lian R, Shi-Liang Z, Jun-Hong L, Zhi-Xiao W (2018) The value of 99mTc-EHIDA hepatobiliary scintigraphy with different liver/kidney ratio in the distinguish of infant persistent jaundice. *J Med Diagn Meth* 7(267):2
- Krishna OHR, Sultana N, Malleboyina R, Kumar AN, Reddy KR, Rao BN (2014) Efficacy of the seven feature, fifteen point histological scoring system and CD56 in interpretation of liver biopsies in persistent neonatal cholestasis: a five-year study. *Indian J Pathol Microbiol* 57(2):196. <https://doi.org/10.4103/0377-4929.134662>
- Lee WS, Looi LM (2009) Usefulness of a scoring system in the interpretation of histology in neonatal cholestasis. *World J Gastroenterol* 15(42):5326–5333. <https://doi.org/10.3748/wjg.15.5326>
- Chen X, Dong R, Shen Z, Yan W, Zheng S (2016) Value of gamma-glutamyl transpeptidase for diagnosis of biliary atresia by correlation with age. *J Pediatr Gastroenterol Nutr* 63(3):370–373. <https://doi.org/10.1097/MPG.0000000000001168>

Publisher's Note

Springer Nature remains neutral with regard to jurisdictional claims in published maps and institutional affiliations.