

REVIEW

Open Access



Optical neuroimaging: advancing transcranial magnetic stimulation treatments of psychiatric disorders

Shixie Jiang^{1*}, Linda L. Carpenter² and Huabei Jiang³

Abstract

Transcranial magnetic stimulation (TMS) has been established as an important and effective treatment for various psychiatric disorders. However, its effectiveness has likely been limited due to the dearth of neuronavigational tools for targeting purposes, unclear ideal stimulation parameters, and a lack of knowledge regarding the physiological response of the brain to TMS in each psychiatric condition. Modern optical imaging modalities, such as functional near-infrared spectroscopy and diffuse optical tomography, are promising tools for the study of TMS optimization and functional targeting in psychiatric disorders. They possess a unique combination of high spatial and temporal resolutions, portability, real-time capability, and relatively low costs. In this mini-review, we discuss the advent of optical imaging techniques and their innovative use in several psychiatric conditions including depression, panic disorder, phobias, and eating disorders. With further investment and research in the development of these optical imaging approaches, their potential will be paramount for the advancement of TMS treatment protocols in psychiatry.

Keywords: Optical imaging, Functional near-infrared spectroscopy, Diffuse optical tomography, Transcranial magnetic stimulation, Major depressive disorder, Panic disorder, Phobia, Bulimia nervosa, Psychiatric disorders

Introduction

Transcranial magnetic stimulation (TMS) was first developed in 1985 by Barker et al. [1]. Since its conception, it has rapidly become an important research and clinical tool for the study and treatment of various psychiatric disorders [2]. The alternating magnetic field created by passing an electrical current through an insulated coil is capable of noninvasively modulating neural activity. This magnetic field penetrates the scalp and skull directly beneath the coil to induce neuronal depolarization and subsequent activation or inhibition [3]. In principle, TMS can therefore be used to promote improvement of abnormal neural activity and restore the dysfunctional brain networks that underpin psychiatric symptoms. Over the

past decade, TMS has become a standard therapy for adults with depression who are resistant to traditional treatments, and numerous clinical trials have shown the benefits of TMS for a wide array of neuropsychiatric conditions. However, its effectiveness has likely been limited due to the dearth of neuronavigational tools for targeting purposes, unclear ideal stimulation parameters, and a lack of knowledge regarding the physiological response of the brain to TMS in each psychiatric condition [4]. As such, the development of neuroimaging modalities has been a promising area of research that has been pursued in order to understand the mechanisms of TMS and improve its overall impact.

Unlike strokes or other focal neurological disorders, psychiatric disorders typically do not cause visible changes on standard structural imaging techniques, including magnetic resonance imaging (MRI) and computed tomography (CT) [5]. Instead, disorders such as depression or schizophrenia can only be imaged using

*Correspondence: jiangs@stanford.edu

¹ Department of Psychiatry and Behavioral Sciences, Stanford University School of Medicine, Palo Alto CA 94305, USA
Full list of author information is available at the end of the article

functional imaging modalities that depict the activity of abnormal brain networks [6]. These techniques include functional magnetic resonance imaging (fMRI), single photon emission computed tomography (SPECT), positron emission tomography (PET), magnetoencephalography (MEG), and electroencephalography (EEG) [7–9]. Neuroimaging has thus offered valuable insights into the pathophysiology of various psychiatric disorders in recent decades and has been crucial for identifying promising biomarkers and treatment targets. However, despite the usefulness of these modalities, their application can be limited in the pursuit of improving the critical TMS parameters, as described above.

Several studies have utilized fMRI, SPECT, and EEG to predict outcomes and optimize TMS treatment approaches for psychiatric disorders [10–12]. One of the most promising findings to date comes from the development of connectivity analysis software using resting-state fMRI data to guide TMS coil placement to an optimal scalp location over the dorsolateral prefrontal cortex (DLPFC) for more precise targeting and improved outcomes in depression [13]. However, none of these imaging modalities can be used concurrently with TMS to provide information about dynamic brain changes during active stimulation sessions. Without knowledge of how the brain responds during a stimulation interval, personalization and optimization of spatial targets, pulse frequencies, treatment intensity, and other aspects of TMS delivery cannot be achieved. While fMRI-based targeting holds considerable potential, the acquisition of MRI data is not safe or feasible for many psychiatric patients because of the presence of non-removable metal or the inability to fit or remain still for prolonged periods in the scanner. Importantly, EEG, fMRI, and MEG are the only modalities that possess the temporal resolution necessary to evaluate any acute response to brain stimulation [14–16]. Unfortunately, they all rely on signals that involve the electromagnetic spectrum, and TMS produces very potent magnetic and electrical fields. Thus, the overall resolution and quality of the images and data generated by these imaging techniques are subject to significant measurement artifacts. To understand the acute physiological neural responses produced by TMS and targeted stimulation to modulate a specific brain region or network, no technique is adequate. One solution to this conundrum has emerged from the advent and development of optical imaging techniques that can be used in humans.

Optical neuroimaging

In 1977, Jöbsis [17] was the first to demonstrate the feasibility of measuring blood and tissue oxygenation changes in the brain of a living organism by employing

near-infrared (NIR) light. Since then, the field of optical neuroimaging has progressed into a robust and diverse area of research with many basic science, translational, and clinical studies that have benefited from the unique elements of light to image the brain. NIR light can provide important functional imaging data by detecting intrinsic changes in absorption, fluorescence, or scattering. A broad armamentarium of exogenous contrast media can be utilized as well to capture further data [18]. Oxy- and de-oxyhemoglobin are chromophores that, along with cytochromes and metabolites, are commonly measured to capture markers of functional activation within the brain, similar to conventional functional imaging techniques that estimate activity [19]. Optical imaging provides a plethora of benefits though over standard functional imaging modalities. These include real-time capabilities, reduced costs, decreased subject movement restriction, a wider variety of contrast agents, lack of ionizing radiation, and portability [18]. Additionally, for the purpose of studying the effects of TMS on the brain, optical imaging does not cause any significant electromagnetic interferences due to inherent property differences. Thus, concurrent imaging of the acute modulation of brain activity during a TMS session can be accomplished using NIR-based technology. To study the effects of TMS in patients with psychiatric disorders, two notable optical imaging techniques have been successfully utilized: functional near-infrared spectroscopy (fNIRS) and diffuse optical tomography (DOT).

fNIRS is based on the basic principles of NIR spectroscopy, and the term, ‘functional’ was denoted after its use in the first human studies published in the early 1990s [20, 21]. fNIRS is capable of detecting changes in the optical properties of the human cortex from multiple measurement sites simultaneously, with the results displayed in a topographical map or image over a precise region. It exploits the fact that human tissues are transparent to light in the NIR spectral window (650–1000 nm) and NIR light is effectively absorbed by chromophores (e.g., hemoglobin in small vessels) or scattered in tissues [22]. By measuring increases in oxy-hemoglobin and concomitant decreases in de-oxyhemoglobin, fNIRS captures acute markers of increased local arteriolar vasodilation, thus increasing local cerebral blood flow and volume in targeted areas. This hemodynamic response highlights the concept of neurovascular coupling, which is then used as a surrogate for neuronal activity in the brain [23]. The benefits of fNIRS for investigating TMS effects include the aforementioned reasons, with an emphasis on portability, low cost, and compatibility with concurrent stimulation. There are multiple companies marketing multichanneled fNIRS devices that can be purchased for a fraction of the price of an fMRI scanner. Given

the small size of the interface and the computer setup [24], these devices can be easily operated and readily moved from subject to subject. DOT is a modern non-invasive NIR-based technique that can be viewed as an extension of fNIRS, similar to the distinction between magnetic resonance spectroscopy and MRI. Unlike the two-dimensional topographic approach of fNIRS, DOT uses multiple NIR wavelengths and overlapping channels, along with a range of source-detector distances for data acquisition [25]. This allows for the quantification of hemodynamic responses occurring at various depths within the brain and the production of three-dimensional images of high spatial and temporal resolution [26]. By obtaining volumetric functional information, DOT offers an attractive alternative approach to three-dimensional functional neuroimaging. Although both of these modalities focus on blood oxygen level-dependent signals, the difference between them lies in the dependence of fMRI on the measurement of mainly de-oxyhemoglobin [27]. Moreover, since DOT can simultaneously measure all types of hemoglobin signals, this creates the capability to distinguish differences in the timing, localization, and magnitude of neurovascular coupling that escape detection by fMRI, thus generating a more informative image of dynamic changes in the brain [28–31]. Notably, similar to fNIRS, DOT is also quite inexpensive, portable, and mobile, and there are new systems of wearable DOT devices with increasingly flexible interfaces on the horizon [32–34].

Concurrent optical neuroimaging and TMS in psychiatric disorders

In psychiatric disorders, fNIRS and DOT have been successfully utilized for the concurrent imaging of the brain during TMS. Studies have focused on patients with various diagnoses, including depressive, anxiety, and eating disorders. The primary advantage of these techniques is that both may offer useful metrics for evaluating treatment response, disease status, symptom severity, or functional targeting for the optimization of TMS treatment parameters. Furthermore, they provide an attractive option to study and understand the neurophysiological effects of TMS. Table 1 provides a summary of published studies using fNIRS or DOT in relation to the application of TMS.

In 2000, Eschweiler et al. [35] were the first to demonstrate the potential utility of optical neuroimaging for informing TMS therapy. In a small sham-controlled cross-over study for patients with major depressive disorder, fNIRS was employed to measure hemoglobin changes in the prefrontal cortex during a computer-based task (mental arithmetic or left or right-handed mirror drawing). The absence of a task-related increase

in total hemoglobin concentration predicted the clinical response to a course of active repetitive TMS (rTMS) in the trial. Interestingly, the paper describing these initial results was published during the ascent of fMRI studies designed to understand the neural circuitry underlying depression, and prior to any fMRI-TMS paired imaging studies [44]. The dominance of fMRI in the field of functional imaging may be the reason why, despite these positive results, no follow-up investigation was attempted after the Eschweiler study until 2018, when Shinba et al. [36] published their findings. In a cohort of patients with treatment refractory depression, fNIRS was used to continuously record hemoglobin changes over the bilateral frontal cortex during two entire rTMS sessions (37.5 mins per session, first and last treatments in the series). Their results demonstrated that higher values of the frontal lobe hemodynamic response during stimulation correlated with greater reductions in depressive symptoms as a patient approached the end of the TMS treatment course. Huang et al. [37] further validated the fNIRS-TMS approach in a larger study in which fNIRS measurements during a verbal fluency task were used to predict treatment response to TMS and to monitor normalization of hemodynamic response to the task.

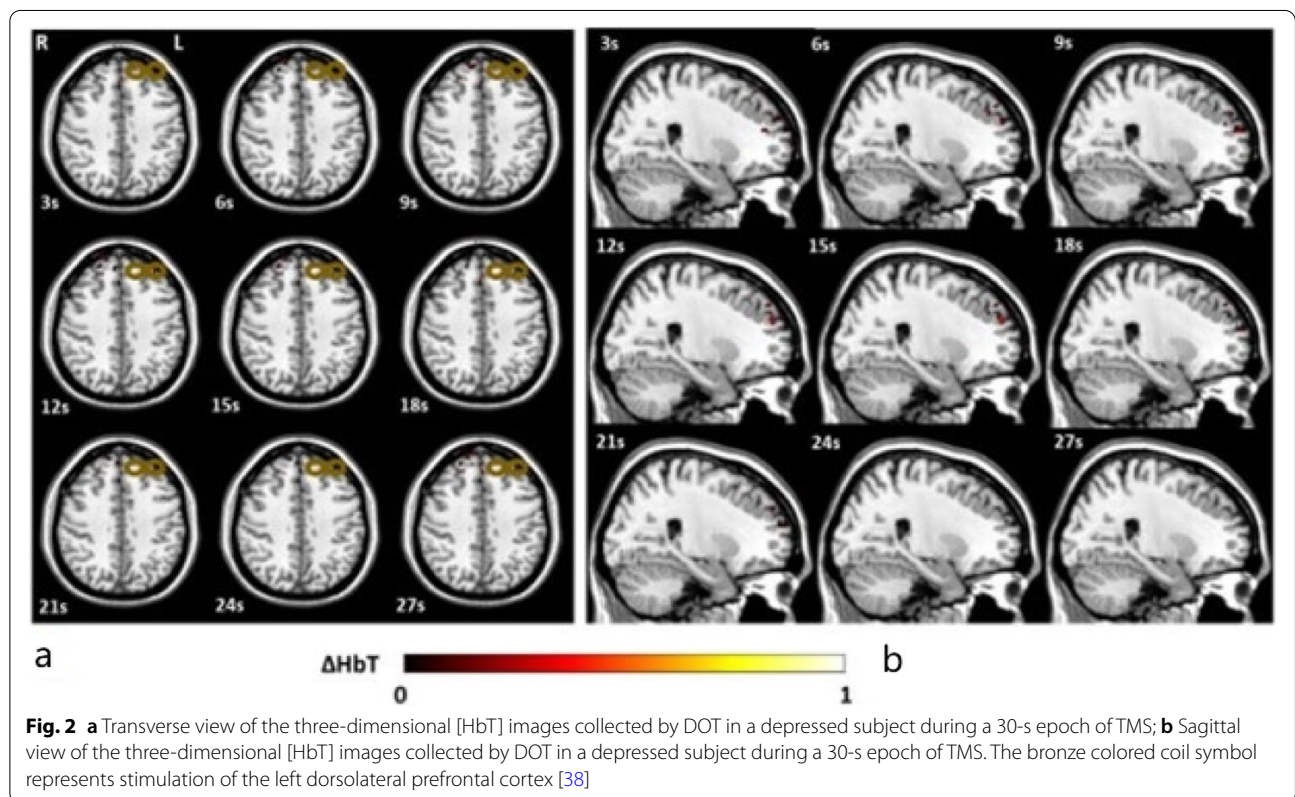
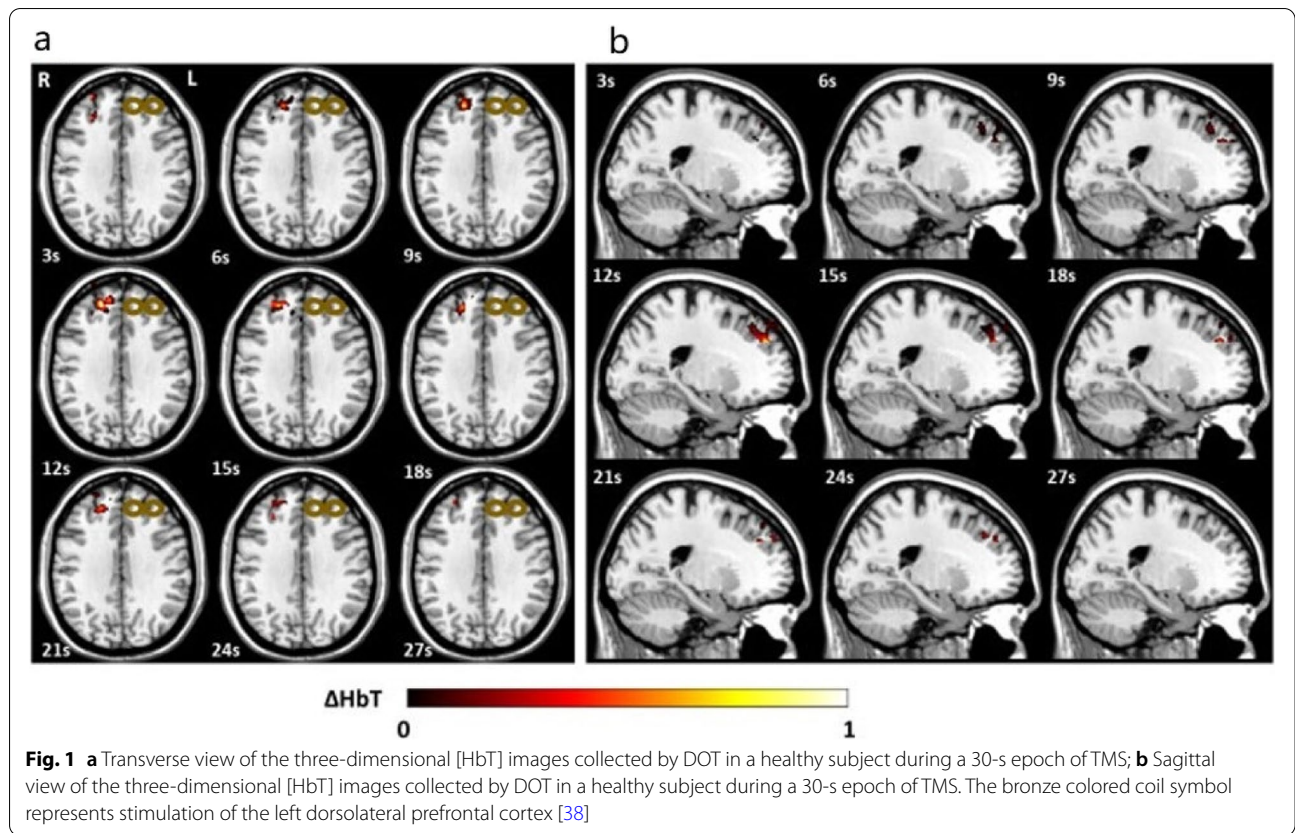
In 2021, our group applied DOT imaging concurrent with stimulation for the first time to demonstrate that depressed patients, in comparison with healthy subjects, had abnormal neurovascular responses to TMS, as evidenced by a decreased volume and magnitude of DLPFC activation during TMS treatments (Figs. 1 and 2) [38]. TMS-evoked hemodynamics were immediately blunted in depressed patients and remained diminished during the entire stimulation and inter-training periods of a treatment session. In contrast, healthy subjects had much more robust and enhanced responses, reflecting the recruitment of greater DLPFC volume. While previous experiments with fNIRS have focused only on the two-dimensional response to TMS, the inclusion of depth information with DOT may provide a precise approach for biomarker development to guide TMS parameters and optimize brain targeting.

Offline assessments of cortical hemodynamics during cognitive task performance have proven useful in predicting rTMS treatment outcomes. Dresler et al. [39] published an exploratory, retrospective case study of patients with comorbid panic disorder and major depressive disorder who received high-frequency rTMS treatment. fNIRS measurements of the bilateral prefrontal cortex during an emotional Stroop task (with panic and neutral stimuli) before and after the course of TMS treatments showed that increased cortical activation bilaterally correlated with positive treatment responses. Deppermann et al. [40, 41] conducted a double-blind sham-controlled

Table 1 Summary of published studies using optical neuroimaging concurrently with TMS

Reference	Psychiatric disorder	Sample size	Optical imaging technique	Imaging site (s)	Activation task	TMS stimulation parameters	Stimulation site	Results
Eschweiler et al., 2000 [35]	Major depressive disorder	12	fNIRS	Bilateral prefrontal cortex	Mental arithmetic; left and right-handed mirror drawing	10 Hz, 10 s duration, 20 trains total, 90% RMT	Left DLPFC	Pre-TMS [HbT] changes during task correlated with changes in HAM-D scores
Shinba et al., 2018 [36]	Major depressive disorder	15	fNIRS	Bilateral frontal cortex	None; resting state	10 Hz, 4 s duration, 26 s inter-train interval, 3000 pulses, 120% RMT	Left DLPFC	Maintenance and magnitude of [HbO] during stimulation session was related to effectiveness of TMS
Huang et al., 2022 [37]	Major depressive disorder	40 depressed; 40 healthy	fNIRS	Bilateral prefrontal cortex	Verbal fluency task	2 Hz, 10 s duration, 3 s inter-train interval, 2600 pulses, 90% RMT	Right DLPFC	Increased [HbO] from baseline to post-treatment in depressed patients positively correlated to reduction of HAM-D scores
Jiang et al., 2021 [38]	Major depressive disorder	7 depressed; 6 healthy	DOT	Contralateral DLPFC	None; resting state	10 Hz, 4 s duration, 26 s inter-train interval, 3000 pulses, 100% RMT	Left DLPFC	Depressed subjects observed to have a lower magnitude and volume of [HbO] and [HbT]
Dresler et al., 2009 [39]	Panic disorder	1	fNIRS	Bilateral prefrontal cortex	Emotional Stroop task	10 Hz, 2 s stimulation, 8 s inter-train interval, 2400 pulses, 120% RMT	Left DLPFC	Increased bilateral [HbO] after TMS treatment
Deppermann et al., 2014 [40]	Panic disorder	44	fNIRS	Bilateral prefrontal cortex	Verbal fluency task	15 pulses per second, 2 s duration, 600 pulses, 80% RMT	Left DLPFC	Increase in [HbO] in left inferior frontal gyrus during and post-TMS correlated with anxiety scores
Deppermann et al., 2017 [41]	Panic disorder	44	fNIRS	Bilateral prefrontal cortex	Emotional Stroop task	15 pulses per second, 2 s duration, 600 pulses, 80% RMT	Left DLPFC	Increased [HbO] in bilateral regions during and post-TMS
Deppermann et al., 2016 [42]	Phobia	41 with phobia; 42 healthy	fNIRS	Bilateral prefrontal cortex	Emotional Stroop task	15 pulses per second, 2 s duration, 600 pulses, 80% RMT	Left DLPFC	Increased [HbO] in bilateral regions during and post-TMS
Sutoh et al., 2016 [43]	Bulimia nervosa	8	fNIRS	Bilateral prefrontal cortex	Food photo task	10 Hz, 5 s duration, 55 s inter-train interval, 1000 pulses, 110% RMT	Left DLPFC	Significant decrease in [HbO] in left DLPFC after single treatment

RMT Resting motor threshold, HbT Hemoglobin concentration, HbO Oxyhemoglobin concentration, HAM-D Hamilton Depression Rating Scale



trial with 44 panic disorder patients using prefrontal cortex fNIRS measurements during a verbal fluency task and an emotional Stroop task at pre-treatment baseline and following a 4-week course of TMS therapy. Their findings confirmed that prefrontal hypoactivation during the tasks was corrected after TMS treatment, even when reported improvements in anxiety symptoms were not evident following the course of TMS. These methods were also used in another study by the same research group, which focused on spider phobias or arachnophobia [42]. However, in this study, TMS was not found to normalize functional dysconnectivity between the inferior frontal gyrus and DLPFC that was initially present in patients with spider phobias. The authors speculated that their results were confounded by the additional virtual reality challenge performed along with TMS in the study.

Finally, fNIRS has also been employed to assess whether cerebral oxygenation during self-regulatory control tasks could be modulated by TMS in a small cohort of patients with bulimia nervosa [43]. Significant decreases in hemoglobin concentrations in the left DLPFC were observed after a single TMS treatment delivered to the same region. This hemodynamic change correlated strongly with decreases in subjective ratings for desire to eat, urge to eat, and sense of hunger, thus providing preliminary data for the use of fNIRS for monitoring treatment response after sample exposure to TMS. The findings also suggest a novel causal mechanism for how TMS may exert inhibitory control and decrease food cravings in patients with eating disorders.

Challenges and limitations

Despite the early successes of optical neuroimaging in TMS studies, there are a number of obstacles to overcome to advance the development of these imaging techniques. These include depth sensitivity, movement artifacts, and physiological-signal contamination.

The depth-sensitivity and penetration limits of NIR light are complex and multifaceted. These characteristics of NIR light depend on a plethora of NIRS application details, including the technology itself, the parameters used, and the neuroanatomical features of the subject being imaged. All these can significantly affect the physical properties of the light being absorbed and scattered by the brain, with differing depths possessing dynamic coefficient changes that require different calculations [23, 24]. The putative depth that can be reliably imaged (especially with commercial devices) is estimated to be in the 2–3 cm range (below the scalp surface) on average [45–47]. Further depths of 4–5 cm have been reported using higher wavelengths (808 nm or more) [48–50]. Due to its more advanced signal properties and sophisticated software interface, DOT is able to more consistently produce

images in the 4–5 cm depth range, compared to fNIRS [25, 38, 51]. Additionally, recent experiments using time- or frequency-domain detection modes appear to mitigate some of the depth sensitivity limitations encountered with the standard continuous-wave design [52]. However, this problem certainly limits the utility of NIR light for imaging deeper structures within the brain, which can be salient for understanding many psychiatric disorders. For example, fMRI data collected before and after a 4- to 6- week course of TMS for depression have revealed that stimulation of the DLPFC indirectly modulates subgenual anterior cingulate cortex hyperactivity and normalizes dysregulated activity in the insula, amygdala, and other subcortical structures [10, 53, 54]. The ability to obtain functional images of these deeper areas during TMS is vital for understanding the effects of this treatment modality in patients with depression. Thus, depth sensitivity remains a barrier for optical neuroimaging.

Another common limitation inherent to any functional neuroimaging method is its vulnerability to movement artifacts. The changes in blood oxygenation and blood flow related to neural activity may be subtle relative to motion-related signal changes, thus creating challenges for the interpretation of hemodynamic responses in a specified region [55]. Such artifacts can degrade image quality, leading to confounded statistical analyses and inaccurate conclusions [56]. During optical neuroimaging procedures, motion occurring between the optical fiber and scalp of the subject can negatively affect image acquisition and cause decoupling and variation in the measured optical signal [57]. The most common type of motion artifact is a transient, high amplitude change in intensity, which subsides immediately after the motion ends. Depending on the magnitude of motion during the data acquisition procedures, whole datasets may be rendered useless when this type of artifact occurs in fMRI. However, when imaging with fNIRS or DOT, temporary and unaffected periods of data can still be captured and well utilized for analysis because of the higher tolerance of head/scalp motion secondary to design differences of the interface itself [58]. This tolerance is likely due to algorithm differences and the use of mesh-based headgear that can be fitted to the subject's head with customized optode-scalp distances in optical imaging techniques, compared to the fixed and rigid design of fMRI. Standard techniques for preventing excessive movement artifacts include the careful design of optode arrays, minimization of subject motion using visual fixation, reduced stimuli, comfortable positioning, and the application of advanced post-processing methodologies [25]. Dynamic head motion can also be a problem for optical imaging during standard TMS

Table 2 Comparison of optical imaging to conventional functional imaging techniques

Techniques	Spatial resolution	Temporal resolution	Size/portability	Average cost (estimated per United States dollar)
fNIRS	Centimeter	Milliseconds	Small; portable	Thousands to tens of thousands
DOT	Millimeter	Milliseconds	Small; portable	Thousands to tens of thousands
fMRI	Millimeter	Seconds	Large; not portable	Millions
EEG	Centimeter	Milliseconds	Small; portable	Thousands to tens of thousands
MEG	Centimeter	Milliseconds	Large; not portable	Millions
PET	Millimeter	Minutes	Large; not portable	Millions
SPECT	Centimeter	Minutes	Large; not portable	Hundreds of thousands

treatments. Current solutions involve the use of rigid head fixation and chin resting frames, but the development of new algorithms to compensate for head motion during stimulation is needed to advance this area of clinical research [59, 60].

The threat of physiological signal contamination is common to all the imaging systems. Conventional functional imaging interfaces must account for signals propagated by non-neuronal sources, including proximal muscle activity, the subject’s cardiac and respiration cycles, spontaneous brain pulsations, and thermal noise related to the scanning process [58, 61, 62]. fNIRS and DOT must also mitigate the effects of environmental light pollution [23]. As such, the optimal imaging environment is made as dark as possible, which can be uncomfortable for some subjects. For TMS applications, in particular, the stimulation itself is accompanied by a vibration of the coil and a relatively loud clicking sound. Although these events are typically brief and associated with minimal motion, they can still introduce mechanical noise that should be accounted for in the selection of optode arrangements and data processing methodologies. Moreover, magnetic pulses emanating from the TMS coil can induce direct changes in the musculature surrounding the stimulation site and within the microvasculature of the scalp. New techniques involving multivariate superficial signal regressions have been developed to attempt to isolate neural signals from any surrounding confounders [63, 64]. Relative to other brain imaging methods, DOT also suffers from this problem less because of its inherent imaging reconstruction algorithm that separates the scalp layers from the brain [38, 64]. Other proposed approaches for minimizing these obstacles include positioning the TMS coil further from the source detectors (i.e., measuring the signal at a location more distant from the coil), designing a custom interface with carefully separated optodes, or placing the coil above the optical interface and increasing the baseline power to overcome the weakened and more distant resultant magnetic field [65]. Table 2 summarizes the differences between DOT,

fNIRS, and other conventional functional neuroimaging techniques.

Future directions

Understanding the mechanisms underlying TMS effects and optimizing TMS protocols for improved treatment outcomes are critical areas of clinical research that can benefit from further experiments conducted with optical imaging techniques. The fNIRS and DOT studies published thus far have demonstrated preliminary but promising findings that will inform subsequent clinical trials and cross-validation studies. While many brain imaging modalities are useful for understanding the chronic effects of stimulation in both healthy volunteers and clinical samples, optical neuroimaging is particularly well-suited to advance the field in the optimization of TMS treatment features.

With regard to the selection of specific TMS parameters (e.g., pulse frequency, pattern, stimulation train durations, and rest intervals), fNIRS and DOT interfaces are uniquely poised to assist with the personalization of treatment protocols for psychiatric disorders. An ideal tool for guiding TMS protocol selection would permit each patient to briefly sample various stimulation parameters and rapidly generate target engagement metrics to inform clinicians of the neuromodulatory effects of each protocol. The results of this procedure could be used to estimate future symptom reduction following multiple applications of a specific type of stimulation. Given their localization capabilities and the real-time quantification of image analysis, optical modalities are perfectly suited for capturing such data, even in a naturalistic treatment setting. In addition, Shinba et al. [36] and Jiang et al. [38] demonstrated the feasibility of this paradigm, as immediate changes in hemoglobin concentrations during stimulation trains, as well as evoked changes observed during a single TMS treatment session, were reliably obtained and correlated with TMS response. Monitoring hemodynamic biomarkers such as those elicited by DOT during a typical 6-week course of daily TMS treatment sessions

could theoretically inform the need for adjustments to various stimulation parameters in order to personalize the TMS protocol and optimize the effects of stimulation for the reduction of specific symptom clusters.

Another area to be explored in future research is the role of optical neuroimaging in generating data for functional connectivity analyses to guide the spatial targeting of TMS systems. For several psychiatric disorders (e.g., depressive disorders, anxiety disorders, schizophrenia), resting-state fMRI has been used to identify regions or networks within various cortical and subcortical structures, where dysfunctional connectivity appears to be associated with prominent symptoms of the disorder. As these pathological circuits are further elucidated, the use of neuroimaging-based navigation algorithms for precise placement of the TMS coil to target them may be critical for optimizing treatment outcomes [66–68]. Such a targeting strategy could be readily implemented with optical neuroimaging devices, given the sophisticated software interfaces and high degree of portability and flexibility they offer. fNIRS and DOT have been utilized in functional connectivity studies to identify brain networks in the visual, sensorimotor, language, and auditory systems in healthy subjects and patients with Alzheimer's disease [69–72]. Further advancement of functional connectivity and other imaging-based TMS targeting approaches for treating neuropsychiatric disorders is imminent and could be accelerated by the deployment of optical imaging systems in research and clinical settings.

Finally, further development of optical imaging biomarkers is essential for implementing a personalized medical approach for noninvasive brain stimulation. The vast majority of optical neuroimaging studies on neuropsychiatric disorders have relied on absorption-based techniques for measuring hemoglobin as the main chromophore of interest. However, other chromophores may be viable candidates for the assessment of functional activity within the human brain. Cytochrome c oxidase (COX) is the final enzyme in the electron transport chain of the mitochondria. It is responsible for the maintenance of the transmembrane proton gradient, which is paramount for the synthesis of adenosine triphosphate, the main source of cellular energy. Mitochondrial dysfunction driven by impaired COX levels has been proposed as a contributing factor to the pathophysiology of depression and bipolar disorders [73]. A recent study by Holper et al. [74] used fNIRS for the first time to evaluate the COX chromophore and observed that lower COX levels correlated inversely with depression severity. In light of their potential for simultaneously acquiring functional data regarding the acute hemodynamic response as well as

metabolic rates, optical imaging techniques may prove uniquely valuable for the advancement of our understanding of the biological underpinnings of psychopathology and for optimizing TMS treatment strategies.

Conclusions

Optical neuroimaging techniques are highly promising tools for the study of TMS mechanisms and for the development of ways to optimize TMS therapeutic effects on psychiatric disorders. In this context, they stand out from other imaging methods owing to their combination of high resolution, portability, real-time capability, and relatively low cost. At present, there are no other well-developed or practical methods for accurately measuring functional brain activity with high spatial and temporal resolutions during the active application of TMS. There is a growing body of preliminary research describing the successful use of optical neuroimaging methods to predict TMS outcomes and elucidate the mechanisms relevant to psychiatric disease and recovery. However, much work remains to improve our noninvasive neuromodulation treatments and alleviate the burdens associated with these neuropsychiatric disorders. Through further investment in the development of these tools, fNIRS and DOT may play an essential role in advancing the science needed to understand salient neurocircuit pathologies and personalize TMS care for more rapid, robust, and durable treatment outcomes.

Abbreviations

TMS: Transcranial magnetic stimulation; rTMS: Repetitive transcranial magnetic stimulation; fNIRS: Functional near-infrared spectroscopy; DOT: Diffuse optical tomography; MRI: Magnetic resonance imaging; CT: Computed tomography; fMRI: Functional magnetic resonance imaging; SPECT: Single photon emission computed tomography; PET: Positron emission tomography; MEG: Magnetoencephalography; EEG: Electroencephalography; DLPFC: Dorsolateral prefrontal cortex; NIR: Near-infrared; COX: Cytochrome c oxidase; HbT: Hemoglobin concentration; RMT: Resting motor threshold; HbO: Oxyhemoglobin concentration; HAM-D: Hamilton Depression Rating Scale.

Acknowledgements

Not applicable.

Authors' contributions

SJ conceived and drafted the manuscript in its entirety; LL and HJ contributed significant revisions and edits to the manuscript. All authors reviewed and edited the final version of the manuscript. The author(s) read and approved the final manuscript.

Funding

Not applicable.

Availability of data and materials

Not applicable.

Declarations

Competing interests

Dr. Huabei Jiang is currently an associate editor of *Visual Computing for Industry, Biomedicine, and Art*. Dr. Linda Carpenter's staff at Butler Hospital have received research support from Janssen, Neuronetics, Neuroliet, Affect Neuro, and Nexstim; she has received consulting income from Janssen, Neuronetics, Sage Therapeutics, Affect Neuro, Neuroliet, Sunovion, and Otsuka. Dr. Shixie Jiang has no relevant disclosures or conflicts of interest to report.

Author details

¹Department of Psychiatry and Behavioral Sciences, Stanford University School of Medicine, Palo Alto CA 94305, USA. ²Department of Psychiatry and Human Behavior, Butler Hospital, Alpert Medical School of Brown University, Providence RI 02903, USA. ³Department of Medical Engineering, University of South Florida, Tampa FL 33613, USA.

Received: 3 June 2022 Accepted: 22 August 2022

Published online: 08 September 2022

References

- Barker AT, Jalinous R, Freeston IL (1985) Non-invasive magnetic stimulation of human motor cortex. *Lancet* 325(8437):1106-1107. [https://doi.org/10.1016/S0140-6736\(85\)92413-4](https://doi.org/10.1016/S0140-6736(85)92413-4)
- Lisanby SH, Kinnunen LH, Crupain MJ (2002) Applications of TMS to therapy in psychiatry. *J Clin Neurophysiol* 19(4):344-360. <https://doi.org/10.1097/00004691-200208000-00007>
- George MS, Nahas Z, Borckardt JJ, Anderson B, Foust MJ, Burns C et al (2007) Brain stimulation for the treatment of psychiatric disorders. *Curr Opin Psychiatry* 20(3):250-254. <https://doi.org/10.1097/YCO.0b013e3280ad4698>
- George MS (2019) Whither TMS: a one-trick pony or the beginning of a neuroscientific revolution? *Am J Psychiatry* 176(11):904-910. <https://doi.org/10.1176/appi.ajp.2019.19090957>
- Agarwal N, Port JD, Bazzocchi M, Renshaw PF (2010) Update on the use of MR for assessment and diagnosis of psychiatric diseases. *Radiology* 255(1):23-41. <https://doi.org/10.1148/radiol.09090339>
- Masdeu JC (2011) Neuroimaging in psychiatric disorders. *Neurotherapeutics* 8(1):93-102. <https://doi.org/10.1007/s13311-010-0006-0>
- McGuire PK, Matsumoto K (2004) Functional neuroimaging in mental disorders. *World Psychiatry* 3(1):6-11.
- Newson JJ, Thiagarajan TC (2019) EEG frequency bands in psychiatric disorders: a review of resting state studies. *Front Hum Neurosci* 12:521. <https://doi.org/10.3389/fnhum.2018.00521>
- Uhlhaas PJ, Liddle P, Linden DEJ, Nobre AC, Singh KD, Gross J (2017) Magnetoencephalography as a tool in psychiatric research: current status and perspective. *Biol Psychiatry: Cogn Neurosci Neuroimaging* 2(3):235-244. <https://doi.org/10.1016/j.bpsc.2017.01.005>
- Cash RFF, Cocchi L, Lv JL, Fitzgerald PB, Zalesky A (2021) Functional magnetic resonance imaging-guided personalization of transcranial magnetic stimulation treatment for depression. *JAMA Psychiatry* 78(3):337-339. <https://doi.org/10.1001/jamapsychiatry.2020.3794>
- Jha S, Chadda RK, Kumar N, Bal CS (2016) Brain SPECT guided repetitive transcranial magnetic stimulation (rTMS) in treatment resistant major depressive disorder. *Asian J Psychiatr* 21:1-6. <https://doi.org/10.1016/j.ajp.2016.02.003>
- Jin Y, Phillips B (2014) A pilot study of the use of EEG-based synchronized Transcranial Magnetic Stimulation (sTMS) for treatment of Major Depression. *BMC Psychiatry* 14:13. <https://doi.org/10.1186/1471-244X-14-13>
- Weigand A, Horn A, Caballero R, Cooke D, Stern AP, Taylor SF et al (2018) Prospective validation that subgenual connectivity predicts antidepressant efficacy of transcranial magnetic stimulation sites. *Biol Psychiatry* 84(1):28-37. <https://doi.org/10.1016/j.biopsych.2017.10.028>
- Bestmann S, Baudewig J, Siebner HR, Rothwell JC, Frahm J (2005) BOLD MRI responses to repetitive TMS over human dorsal premotor cortex. *NeuroImage* 28(1):22-29. <https://doi.org/10.1016/j.neuroimage.2005.05.027>
- Shibasaki H (2008) Human brain mapping: hemodynamic response and electrophysiology. *Clin Neurophysiol* 119(4):731-743. <https://doi.org/10.1016/j.clinph.2007.10.026>
- Farzan F, Barr MS, Wong W, Chen R, Fitzgerald PB, Daskalakis ZJ (2009) Suppression of γ -oscillations in the dorsolateral prefrontal cortex following long interval cortical inhibition: a TMS-EEG study. *Neuropsychopharmacology* 34(6):1543-1551. <https://doi.org/10.1038/npp.2008.211>
- Jöbsis FF (1977) Noninvasive, infrared monitoring of cerebral and myocardial oxygen sufficiency and circulatory parameters. *Science* 198(4323):1264-1267. <https://doi.org/10.1126/science.929199>
- Hillman EMC (2007) Optical brain imaging in vivo: techniques and applications from animal to man. *J Biomed Opt* 12(5):051402. <https://doi.org/10.1117/1.2789693>
- Morone KA, Neimat JS, Roe AW, Friedman RM (2017) Review of functional and clinical relevance of intrinsic signal optical imaging in human brain mapping. *NeuroPhotonics* 4(3):031220. <https://doi.org/10.1117/1.NPh.4.3.031220>
- Okada F, Tokumitsu Y, Hoshi Y, Tamura M (1993) Gender- and handedness-related differences of forebrain oxygenation and hemodynamics. *Brain Res* 601(1-2):337-342. [https://doi.org/10.1016/0006-8993\(93\)91733-9](https://doi.org/10.1016/0006-8993(93)91733-9)
- Hoshi Y, Tamura M (1993) Detection of dynamic changes in cerebral oxygenation coupled to neuronal function during mental work in man. *Neurosci Lett* 150(1):5-8. [https://doi.org/10.1016/0304-3940\(93\)90094-2](https://doi.org/10.1016/0304-3940(93)90094-2)
- Delpy DT, Cope M (1997) Quantification in tissue near-infrared spectroscopy. *Philos Trans Roy Soc B: Biol Sci* 352(1354):649-659. <https://doi.org/10.1098/rstb.1997.0046>
- Elwell CE, Cooper CE (2011) Making light work: illuminating the future of biomedical optics. *Philos Trans Roy Soc A: Math Phys Eng Sci* 369(1955):4358-4379. <https://doi.org/10.1098/rsta.2011.0302>
- Ferrari M, Quaresima V (2012) A brief review on the history of human functional near-infrared spectroscopy (fNIRS) development and fields of application. *NeuroImage* 63(2):921-935. <https://doi.org/10.1016/j.neuroimage.2012.03.049>
- Jiang HB (2017) Diffuse optical tomography. CRC Press, Boca Raton. <https://doi.org/10.1201/b10482>
- Hoshi Y, Yamada Y (2016) Overview of diffuse optical tomography and its clinical applications. *J Biomed Opt* 21(9):091312. <https://doi.org/10.1117/1.JBO.21.9.091312>
- Obata T, Liu TT, Miller KL, Luh WM, Wong EC, Frank LR et al (2004) Discrepancies between BOLD and flow dynamics in primary and supplementary motor areas: application of the balloon model to the interpretation of BOLD transients. *NeuroImage* 21(1):144-153. <https://doi.org/10.1016/j.neuroimage.2003.08.040>
- Culver JP, Durduran T, Furuya D, Cheung C, Greenberg JH, Yodh AG (2003) Diffuse optical tomography of cerebral blood flow, oxygenation, and metabolism in rat during focal ischemia. *J Cereb Blood Flow Metab* 23(8):911-924. <https://doi.org/10.1097/01.WCB.0000076703.71.231.BB>
- Wolf M, Wolf U, Toronov V, Michalos A, Paunescu LA, Choi JH et al (2002) Different time evolution of oxyhemoglobin and deoxyhemoglobin concentration changes in the visual and motor cortices during functional stimulation: a near-infrared spectroscopy study. *NeuroImage* 16(3):704-712. <https://doi.org/10.1006/nimg.2002.1128>
- Jasdzewski G, Strangman G, Wagner J, Kwong KK, Poldrack RA, Boas DA (2003) Differences in the hemodynamic response to event-related motor and visual paradigms as measured by near-infrared spectroscopy. *NeuroImage* 20(1):479-488. [https://doi.org/10.1016/s1053-8119\(03\)00311-2](https://doi.org/10.1016/s1053-8119(03)00311-2)
- Culver JP, Siegel AM, Franceschini MA, Mandeville JB, Boas DA (2005) Evidence that cerebral blood volume can provide brain activation maps with better spatial resolution than deoxygenated hemoglobin. *NeuroImage* 27(4):947-959. <https://doi.org/10.1016/j.neuroimage.2005.05.052>
- Vidal-Rosas EE, Zhao HB, Nixon-Hill RW, Smith G, Dunne L, Powell S et al (2021) Evaluating a new generation of wearable high-density diffuse optical tomography technology via retinotopic mapping of the adult visual cortex. *NeuroPhotonics* 8(2):025002. <https://doi.org/10.1117/1.NPh.8.2.025002>
- Villringer A, Planck J, Hock C, Schleinkofer L, Dirnagl U (1993) Near infrared spectroscopy (NIRS): a new tool to study hemodynamic changes during activation of brain function in human adults. *Neurosci Lett* 154(1-2):101-104. [https://doi.org/10.1016/0304-3940\(93\)90181-j](https://doi.org/10.1016/0304-3940(93)90181-j)

34. Obrig H, Villringer A (2003) Beyond the visible—imaging the human brain with light. *J Cereb Blood Flow Metab* 23(1):1–18. <https://doi.org/10.1097/01.WCB.0000043472.45775.29>
35. Eschweiler GW, Wegerer C, Schlotter W, Spandl C, Stevens A, Bartels M et al (2000) Left prefrontal activation predicts therapeutic effects of repetitive transcranial magnetic stimulation (rTMS) in major depression. *Psychiatry Res: Neuroimaging* 99(3):161–172. [https://doi.org/10.1016/S0925-4927\(00\)0062-7](https://doi.org/10.1016/S0925-4927(00)0062-7)
36. Shinba T, Kariya N, Matsuda S, Matsuda H, Obara Y (2018) Increase of frontal cerebral blood volume during transcranial magnetic stimulation in depression is related to treatment effectiveness: a pilot study with near-infrared spectroscopy. *Psychiatry Clin Neurosci* 72(8):602–610. <https://doi.org/10.1111/pcn.12680>
37. Huang JX, Zhang JQ, Zhang TY, Wang P, Zheng Z (2022) Increased prefrontal activation during verbal fluency task after repetitive transcranial magnetic stimulation treatment in depression: a functional near-infrared spectroscopy study. *Front Psychiatry* 13:876136. <https://doi.org/10.3389/fpsy.2022.876136>
38. Jiang SX, Huang JY, Yang H, Wagoner R, Kozel FA, Currier G et al (2021) Neuroimaging of depression with diffuse optical tomography during repetitive transcranial magnetic stimulation. *Sci Rep* 11(1):7328. <https://doi.org/10.1038/s41598-021-86751-9>
39. Dresler T, Ehlis AC, Plichta MM, Richter MM, Jabs B, Lesch KP et al (2009) Panic disorder and a possible treatment approach by means of high-frequency rTMS: a case report. *World J Biol Psychiatry* 10(4):991–997. <https://doi.org/10.1080/15622970902898147>
40. Deppermann S, Vennwald N, Diemer J, Sickinger S, Haeussinger FB, Notzon S et al (2014) Does rTMS alter neurocognitive functioning in patients with panic disorder/agoraphobia? An fNIRS-based investigation of prefrontal activation during a cognitive task and its modulation via sham-controlled rTMS. *Biomed Res Int* 2014:542526. <https://doi.org/10.1155/2014/542526>
41. Deppermann S, Vennwald N, Diemer J, Sickinger S, Haeussinger FB, Dresler T et al (2017) Neurobiological and clinical effects of fNIRS-controlled rTMS in patients with panic disorder/agoraphobia during cognitive-behavioural therapy. *NeuroImage: Clin* 16:668–677. <https://doi.org/10.1016/j.nicl.2017.09.013>
42. Deppermann S, Notzon S, Krocze A, Rosenbaum D, Haeussinger FB, Diemer J et al (2016) Functional co-activation within the prefrontal cortex supports the maintenance of behavioural performance in fear-relevant situations before an iTBS modulated virtual reality challenge in participants with spider phobia. *Behav Brain Res* 307:208–217. <https://doi.org/10.1016/j.bbr.2016.03.028>
43. Sutoh C, Koga Y, Kimura H, Kanahara N, Numata N, Hirano Y et al (2016) Repetitive transcranial magnetic stimulation changes cerebral oxygenation on the left dorsolateral prefrontal cortex in bulimia nervosa: a near-infrared spectroscopy pilot study. *Eur Eat Disord Rev* 24(1):83–88. <https://doi.org/10.1002/erv.2143>
44. Fox MD, Buckner RL, White MP, Greicius MD, Pascual-Leone A (2012) Efficacy of transcranial magnetic stimulation targets for depression is related to intrinsic functional connectivity with the subgenual cingulate. *Biol Psychiatry* 72(7):595–603. <https://doi.org/10.1016/j.biopsych.2012.04.028>
45. Strangman GE, Zhang Q, Li Z (2014) Scalp and skull influence on near infrared photon propagation in the Colin27 brain template. *NeuroImage* 85:136–149. <https://doi.org/10.1016/j.neuroimage.2013.04.090>
46. Okada E, Delpy DT (2003) Near-infrared light propagation in an adult head model. II. Effect of superficial tissue thickness on the sensitivity of the near-infrared spectroscopy signal. *Appl Opt* 42(16):2915–2921. <https://doi.org/10.1364/ao.42.002915>
47. Hamblin MR (2016) Shining light on the head: photobiomodulation for brain disorders. *BBA Clin* 6:113–124. <https://doi.org/10.1016/j.bbacli.2016.09.002>
48. Tedford CE, DeLapp S, Jacques S, Anders J (2015) Quantitative analysis of transcranial and intraparenchymal light penetration in human cadaver brain tissue. *Lasers Surg Med* 47(4):312–322. <https://doi.org/10.1002/lsm.22343>
49. Pitzschke A, Lovisa B, Seydoux O, Zellweger M, Pfeleiderer M, Tardy Y et al (2015) Red and NIR light dosimetry in the human deep brain. *Phys Med Biol* 60(7):2921–2937. <https://doi.org/10.1088/0031-9155/60/7/2921>
50. Yaroslavsky AN, Schulze PC, Yaroslavsky IV, Schober R, Ulrich F, Schwarzmair HJ (2002) Optical properties of selected native and coagulated human brain tissues *in vitro* in the visible and near infrared spectral range. *Phys Med Biol* 47(12):2059–2073. <https://doi.org/10.1088/0031-9155/47/12/305>
51. Habermehl C, Holtze S, Steinbrink J, Koch SP, Obrig H, Mehnert J et al (2012) Somatosensory activation of two fingers can be discriminated with ultrahigh-density diffuse optical tomography. *NeuroImage* 59(4):3201–3211. <https://doi.org/10.1016/j.neuroimage.2011.11.062>
52. Lange F, Tachtsidis I (2019) Clinical brain monitoring with time domain NIRS: a review and future perspectives. *Appl Sci* 9(8):1612. <https://doi.org/10.3390/app9081612>
53. Ishida T, Dierks T, Strik W, Morishima Y (2020) Converging resting state networks unravels potential remote effects of transcranial magnetic stimulation for major depression. *Front Psychiatry* 11:836
54. Chen FJ, Gu CZ, Zhai N, Duan HF, Zhai AL, Zhang X (2020) Repetitive transcranial magnetic stimulation improves amygdala functional connectivity in major depressive disorder. *Front Psychiatry* 11:732. <https://doi.org/10.3389/fpsy.2020.00732>
55. Havsteen I, Ohlhues A, Madsen KH, Nybing JD, Christensen H, Christensen A (2017) Are movement artifacts in magnetic resonance imaging a real problem?—A narrative review. *Front Neurol* 8:232. <https://doi.org/10.3389/fneur.2017.00232>
56. Van Dijk KRA, Sabuncu MR, Buckner RL (2012) The influence of head motion on intrinsic functional connectivity MRI. *NeuroImage* 59(1):431–438. <https://doi.org/10.1016/j.neuroimage.2011.07.044>
57. Brigadoi S, Ceccherini L, Cutini S, Scarpa F, Scatturin P, Selb J et al (2014) Motion artifacts in functional near-infrared spectroscopy: a comparison of motion correction techniques applied to real cognitive data. *NeuroImage* 85:181–191. <https://doi.org/10.1016/j.neuroimage.2013.04.082>
58. Scarapicchia V, Brown C, Mayo C, Gawryluk JR (2017) Functional magnetic resonance imaging and functional near-infrared spectroscopy: insights from combined recording studies. *Front Hum Neurosci* 11:419. <https://doi.org/10.3389/fnhum.2017.00419>
59. Richter L, Trillenber P, Schweikard A, Schlaefler A (2013) Stimulus intensity for hand held and robotic transcranial magnetic stimulation. *Brain Stimul* 6(3):315–321. <https://doi.org/10.1016/j.brs.2012.06.002>
60. Chronicle EP, Pearson AJ, Matthews C (2005) Development and positioning reliability of a TMS coil holder for headache research. *Headache* 45(1):37–41. <https://doi.org/10.1111/j.1526-4610.2005.05008.x>
61. Huh Y, Choi Y, Hong KJ, Hu W, Kang J, Jung JH et al (2013) Development of filtering methods for PET signals contaminated by RF pulses for combined PET-MRI. *IEEE Trans Nucl Sci* 60(5):3205–3211. <https://doi.org/10.1109/TNS.2013.2274075>
62. Yilmaz G, Budan AS, Urgan P, Topkara B, Türker KS (2019) Facial muscle activity contaminates EEG signal at rest: evidence from frontalis and temporalis motor units. *J Neural Eng* 16(6):066029. <https://doi.org/10.1088/1741-2552/ab3235>
63. Gagnon L, Perdue K, Greve DN, Goldenholz D, Kaskhedikar G, Boas DA (2011) Improved recovery of the hemodynamic response in diffuse optical imaging using short optode separations and state-space modeling. *NeuroImage* 56(3):1362–1371. <https://doi.org/10.1016/j.neuroimage.2011.03.001>
64. Gregg NM, White BR, Zeff BW, Berger AJ, Culver JP (2010) Brain specificity of diffuse optical imaging: improvements from superficial signal regression and tomography. *Front Neuroener* 2:14. <https://doi.org/10.3389/fnene.2010.00014>
65. Parks N (2013) Concurrent application of TMS and near-infrared optical imaging: methodological considerations and potential artifacts. *Front Hum Neurosci* 7:592
66. Luber BM, Davis S, Bernhardt E, Neacsu A, Kwapil L, Lisanby SH et al (2017) Using neuroimaging to individualize TMS treatment for depression: toward a new paradigm for imaging-guided intervention. *NeuroImage* 148:1–7. <https://doi.org/10.1016/j.neuroimage.2016.12.083>
67. Cole EJ, Phillips AL, Bentzley BS, Stimpson KH, Nejad R, Barmak F et al (2022) Stanford neuromodulation therapy (SNT): a double-blind randomized controlled trial. *Am J Psychiatry* 179(2):132–141. <https://doi.org/10.1176/appi.ajp.2021.20101429>
68. Brady RO Jr, Gonsalvez I, Lee I, Öngür D, Seidman LJ, Schmahmann JD et al (2019) Cerebellar-prefrontal network connectivity and negative

- symptoms in schizophrenia. *Am J Psychiatry* 176(7):512-520. <https://doi.org/10.1176/appi.ajp.2018.18040429>
69. White BR, Snyder AZ, Cohen AL, Petersen SE, Raichle ME, Schlaggar BL et al (2009) Resting-state functional connectivity in the human brain revealed with diffuse optical tomography. *NeuroImage* 47(1):148-156. <https://doi.org/10.1016/j.neuroimage.2009.03.058>
 70. Zhang H, Zhang YJ, Lu CM, Ma SY, Zang YF, Zhu CZ (2010) Functional connectivity as revealed by independent component analysis of resting-state fNIRS measurements. *NeuroImage* 51(3):1150-1161. <https://doi.org/10.1016/j.neuroimage.2010.02.080>
 71. Molavi B, May L, Gervain J, Carreiras M, Werker JF, Dumont GA (2014) Analyzing the resting state functional connectivity in the human language system using near infrared spectroscopy. *Front Hum Neurosci* 7:921. <https://doi.org/10.3389/fnhum.2013.00921>
 72. Metzger FG, Schopp B, Haeussinger FB, Dehnen K, Synofzik M, Fallgatter AJ et al (2016) Brain activation in frontotemporal and Alzheimer's dementia: a functional near-infrared spectroscopy study. *Alzheimers Res Ther* 8(1):56. <https://doi.org/10.1186/s13195-016-0224-8>
 73. Giménez-Palomo A, Dodd S, Anmella G, Carvalho AF, Scaini G, Quevedo J et al (2021) The role of mitochondria in mood disorders: from physiology to pathophysiology and to treatment. *Front Psychiatry* 12:546801. <https://doi.org/10.3389/fpsy.2021.546801>
 74. Holper L, Lan MJ, Brown PJ, Sublette EM, Burke A, Mann JJ (2019) Brain cytochrome-c-oxidase as a marker of mitochondrial function: a pilot study in major depression using NIRS. *Depress Anxiety* 36(8):766-779. <https://doi.org/10.1002/da.22913>

Publisher's Note

Springer Nature remains neutral with regard to jurisdictional claims in published maps and institutional affiliations.

Submit your manuscript to a SpringerOpen[®] journal and benefit from:

- ▶ Convenient online submission
- ▶ Rigorous peer review
- ▶ Open access: articles freely available online
- ▶ High visibility within the field
- ▶ Retaining the copyright to your article

Submit your next manuscript at ▶ [springeropen.com](https://www.springeropen.com)
