


CASE REPORT

Open Access



Return-to-work after interlaminar endoscopic sequestrectomy: case series

Ismail Bozkurt^{1,2*} , Cagri Canbolat³, Kemal Paksoy³, Salim Senturk³ and Onur Yaman³

Abstract

Background Considering the epidemiology of single-level lumbar disc herniations (LDH) in the young and active patients, the impact on working capacity is highly relevant. The timing of return-to-work after lumbar surgery through various modalities differs greatly. This may be partly due diverse disparate surgical approaches along with differences in patient and surgeon. The purpose of this paper is to provide evidence for a return-to-work policy after endoscopic sequestrectomy and discuss possible clues to a faster recovery of patients that did not receive a sick-leave report via a case series.

Case presentation The sample comprises fourteen cases of single-level LDH that underwent endoscopic interlaminar sequestrectomy and did not receive a sick-leave report and were advised to return-to-work whenever they felt fit so. Time until return-to-work, pre- and post-operative leg VAS pain scores and amount of analgesic used post-operatively were retrospectively analyzed. Fourteen patients were operated on using the same technique and on average returned to work after 6.6 ± 1.8 days, used 3.7 ± 2.5 analgesic tablets before returning to work and had a postoperative leg VAS pain score of 1.4 ± 1.2 . No patient requested a sick-leave report during the follow-up period of 1 month.

Conclusions The patients in this case series had a remarkably short period of sick-leave and a low number of analgesic usage. These findings may be due to selection of patients who were operated on specifically for leg pain with the absence of lower back pain suggesting integrity of annulus fibrosus. We can postulate that intraoperative preservation of lamina, facet joint and annulus fibrosus along with reassurance of the surgeon suggesting to return-to-work whenever fell fit so were the key factors in the swifter recovery of the patients.

Keywords Lumbar, Spine, Surgery, PELD, Return-to-work, Interlaminar

Background

Lumbar disc herniation (LDH) is considered to be the main cause of sciatica and lumbar discectomy remains to be the most employed modality for the surgical treatment of LDH [1]. Although classical laminectomy was first described in 1934, the overall trend towards micro

approach has made way for microdiscectomy described by Yasargil and Caspar in 1977 [2]. Over the last 2 decades, percutaneous minimally invasive spine surgery (MISS) has increased tremendously partly overtaking classical approaches in some instances [3]. This shift has mostly arisen from the target of reduced collateral tissue damage and a shorter refractory period before work.

In 1996, Kambin [4] opened a new chapter in the era of lumbar discectomy by introducing the endoscope through a transforaminal approach and the interlaminar approach was then after described in the late 1990s [5]. The minimally invasive procedures have aimed for numerous advantages and have been successful at it. A retrospective matched cohort study revealed equal rates in postoperative leg pain and recurrence rate

*Correspondence:

Ismail Bozkurt
ibozkurt85@gmail.com

¹ Department of Neurosurgery, Medical Park Ankara Hospital, Kent Koop Mah 1868. Sok, Batikent Blv. No:15, 06680 Ankara, Turkey

² Department of Neurosurgery, School of Medicine, Yuksek Ihtisas University, Ankara, Turkey

³ Memorial Spine Center, Neurosurgery Clinic, Istanbul, Turkey

when compared with microdiscectomy but percutaneous endoscopic lumbar discectomy (PELD) proved to be advantageous in back pain, operation time, intraoperative blood loss, hospital stay and return-to-work [5]. A meta-analysis of 1585 patients revealed similar results where complication rate and recurrence were similar to microdiscectomy but PELD group had a diminished hospital stay and return-to-work period [6]. Sequestrectomy also has also yielded lower consumption of analgesics postoperatively in a systematic review but with a very low level of evidence [7].

With the technological advances of high-resolution endoscopes, optics and digital cameras, PELD has been employed by surgeons in search for smaller skin incision, less collateral damage, better access to the disc space and reduced irritation of nervous structures [3]. It also made way for exclusive sequestrectomy—removal of the offending disc fragment alone—without the disruption of lamina, facet joint or annulus fibrosus (AF) in selected patients via interlaminar approach. This minimally invasive approach with the preservation of bony and ligamentous structures allowing for an accelerated recovery period has put the need for a return-to-work guideline after PELD.

The evidence based clinical guideline for the treatment of LDH by the North American Spine Society has stated that sequestrectomy yielded better results in physical and social functioning, use of analgesics and overall outcome after 2 years [8]. Creating an annual burden of \$100 billion in the US alone [9], the superiority with decreased hemorrhage, decreased use of analgesics, and faster recovery period leading to diminished socioeconomic loss, PELD is gaining tremendous popularity.

In this case series, fourteen patients who were operated for LDH via percutaneous endoscopic interlaminar discectomy (PEID) who were allowed to return-to-work whenever they felt fit so were analyzed in terms of average days of rest, pre- and post-operative leg pain and average use of analgesics.

Case presentation

A written patient consent form from all the patients and ethics board approval from Cankiri Karatekin University (No. 473/010321) was obtained prior to the study. The study was carried out according to the latest revision of the Helsinki Declaration regarding medical research involving human subjects.

To evaluate the factors affecting return-to-work after surgery, a 2-year period was analyzed for patients that have undergone PEID. Patients that had laminotomy performed, facet joint violation or annulus fibrosus disruption were excluded. Also lower back pain was considered an exclusion criteria suggesting an interruption of the

disc capsule; AF. Patients that required a sick-leave report due to their institutional requirements were excluded. Only patients that underwent single-level L4–5 or L5–S1 interlaminar sequestrectomy as described below were included in the study group. Preoperative MRI confirmation of single-level migrated LDH, intact posterior longitudinal ligament and AF along with absence of foraminal stenosis (Figs. 1 and 2) comprised the inclusion criteria revealing fourteen patients. The operations were performed by a single surgeon (SS) at two different hospitals. Patients were prescribed non-selective COX inhibitors for postoperative pain; Naproxen Sodium 500 mg or Diclofenac Potassium 50 mg when allergy was present and were advised to use them on necessary basis with a maximum of 2 tablets per day.

Surgical procedure

After general anesthesia the patients were positioned in prone situ for the jack-knife position. The surgical site was prepped and draped with povidone iodine after the treatment level was localized using a C-arm fluoroscopy. The patients were administered Cefazolin 2gr for

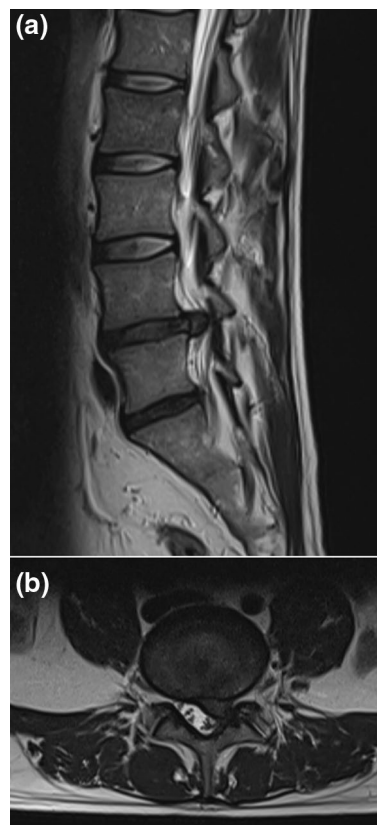


Fig. 1. 36-year-old male patient with a left L4–5 disc herniation with reserved disc height and no foraminal stenosis. **a** T2-weighted sagittal view; **b** T2-weighted axial view

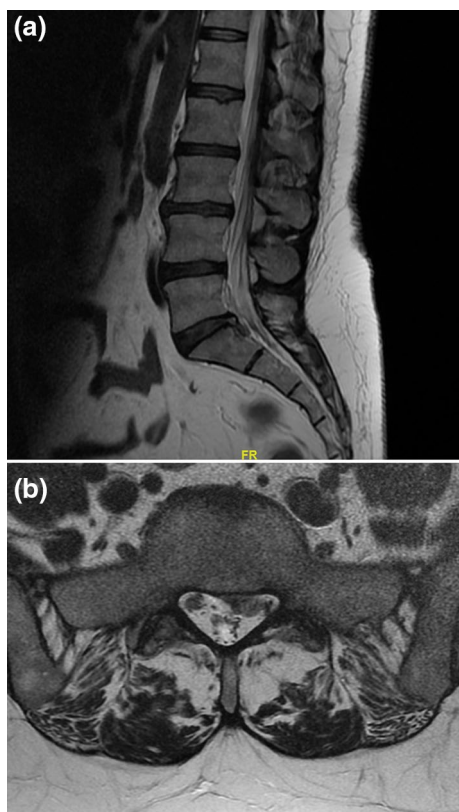


Fig. 2. 52-year-old female patient with a left L5–S1 disc herniation with an intact posterior longitudinal ligament. **a** T2-weighted sagittal view; **b** T2-weighted axial view

prophylaxis. All procedures were performed with a paramedian posterior approach measuring 7 mm in length and 5 mm lateral to the midline. The RIWOSPINE Endoscopic Spine System (Richard Wolf Surgical Instrument Company, Vernon Hills, Illinois, USA) with the VERTEBRIS interlaminar attachment was used for all operations. A tubular dilator was used for muscular dilatation and guided directly towards lig. flavum. A working sleeve with an outer diameter of 6.9 mm and inner 4.1 mm was used with continuous irrigation and observation via a 25° angled endoscope. After visualization of lig. flavum, vertical dissection was performed. For cases that did not allow for dissection, a punch forceps was used to create a 3×5 mm opening. The root was retracted medially to allow for sequestrectomy via grasping forceps at the shoulder. The capsule of the intervertebral disc was not disrupted and the facet joint was not involved in any way. Continuous irrigation was used for hemostasis. The fragment was always checked for concordance with preoperative MRI. At the end of the procedure, the root was carefully inspected for adequate decompression. The skin was sutured with a single 3-0 Nylon stitch. Meticulous hemostasis was applied so no drainage was inserted.

Outcome measures

Incidence of intra and postoperative complications, length of stay at the hospital, pre and postoperative leg VAS pain scores, amount of analgesic tablets used after the surgery and days off before continuing to work were collected. To evaluate postoperative lower back pain, a phone call was made and The Oswestry Disability Index (ODI) [10] questionnaire was applied. Demographic information and profession was also recorded.

Results

Fourteen different patients that were operated on via percutaneous interlaminar lumbar sequestrectomy had an average age of 40 ± 7 at the time of surgery. The average time from radicular pain onset to surgery was 6.2 ± 1.1 weeks. The surgical intervention on average lasted for 38 ± 12 min with an average blood loss of 22 cc. Eight of the patients were male. The patients returned to work on average after 6.64 ± 1.87 days. All but one patient was a white collar worker who were employed at a desk job at an administrative position requiring no extra physical effort. All the patients were employed full time with a minimum 35 h/week. But the professional goalkeeper had a rigorous physical training program after returning to work 4 days after surgery, started physical exercises after 10 days and played in a professional match after a month. Patients on average used 3.8 ± 2.5 analgesic tablets before returning to work. Preoperative leg VAS pain score on average was 8.6 ± 1.1 and had a postoperative leg VAS pain score of 1.4 ± 1.2 . On average the patients had an ODI of 1.7% on the 7th day of surgery with 5 patients reporting no pain or disability at all (Table 1). No patient requested a sick-leave report during the follow-up period of 6 months. Patient numbers 6 and 8 used a single analgesic tablet on the first day of returning to work. No patient has yet presented with symptoms of recurrence. No intra or postoperative complications were observed. The patients were ambulatory 4–6h after surgery. Eight of the patients were discharged on the night of the operation while the rest were discharged a day after.

Conclusions

Management of return-to-work days after lumbar discectomy vary greatly. For classical discectomy, a large variance of 4–12 weeks have been presented [11–14]. This discrepancy has been attributed to work status before surgery, younger age, male gender, higher pre-operative function score and smoking. Hence making a standard algorithm nearly impossible but allowing physicians to evaluate these factors and implementing them on-patient basis. Which makes the Royal College of Surgeons of England recommendation fit for situation “*You do not*

Table 1 List of operated patients

Patient	Age	Sex	Profession	Surgery	Pre-operative VAS	Post-operative VAS	Analgesic use (tablet)	Days off	ODI
1	36	M	White collar	Left L5–S1	10	2	3	7	0
2	41	M	White collar	Right L5–S1	7	3	5	10	2
3	53	M	White collar	Right L4–5	9	0	1	3	2
4	39	M	White collar	Left L5–S1	7	0	3	5	2
5	33	M	White collar	Right L4–5	9	1	4	7	0
6	48	F	White collar	Left L4–5	10	1	5	10	4
7	47	M	White collar	Right L5–S1	8	3	10	7	4
8	51	F	White collar	Left L4–5	8	0	3	7	4
9	41	F	White collar	Left L4–5	10	2	1	7	2
10	36	M	White collar	Right L5–S1	9	0	1	5	0
11	31	M	Football player	Left L4–5	9	0	1	4	2
12	27	F	White collar	Left L5–S1	10	2	3	7	0
13	36	F	White collar	Left L5–S1	7	3	6	7	0
14	40	F	White collar	Left L5–S1	8	3	7	7	2
	40±7	Average±SD			8.6±1.1	1.4±1.2	3.8±2.5	6.6±1.8	

need your GP's permission to go back to work—this is ultimately your decision.” To clarify, there is no consensus nor there should be on returning to work after a single-level lumbar discectomy or sequestrectomy. A surgeon should evaluate each patient in their own framework, taking into account preoperative findings, intraoperative techniques, and the social and work environment of the patient along with psychological status. In selected patients, advising for returning to work whenever they felt fit so in the absence of debilitating pain and capability of physical abilities would result in an ideal return-to-work period for that specific patient.

Expectedly, the same variance is present in endoscopic discectomy. Although the availability of data on return-to-work after endoscopic discectomy is scarce, faster recovery period ranging from 14 to 28 days [5, 15, 16] have been discussed. The return-to-work time period in this study may have differed from previous published data due to several reasons.

The patients selected for this case series were absent of lower back pain suggesting a near intact AF confirmed by MRI. In addition, AF was not disturbed throughout the procedures, only sequestrectomy was performed. Previous studies have revealed free nerve endings of AF that may be sensitized by annular tears. The stimulation of AF and posterior longitudinal ligament stretching reproduced lower back pain confirming the main pain source [17]. The interlaminar approach also allowed us to preserve the facet joint completely without disturbing any aspect of the capsule. This approach specifically for the L4–5 and L5–S1 levels also allows for entrance into the epidural space with a good visualization of the radix

without violating the integrity of the lamina in any way. Previous studies have shown that preservation of muscular, ligamentous and osseous structures resulted in faster rehabilitation due to decreased postoperative pain and earlier return-to-work [18]. The salvation of healthy tissue is the main cornerstone of MISS and in this case series contributed to lack of lower back pain and earlier return-to-work.

In this case series, lig. flavum was managed mostly by lig. flavum protective approach of dissecting it vertically to gain entrance into the epidural space. For cases that did not allow for dissection, an opening measuring 3×5 mm via punch forceps was made. Previous studies have revealed increased postoperative pain after rigorous lig. flavum removal [19]. In this manner, a transforaminal approach is superior as lig. flavum is left completely intact. But just as so the lamina and facet joint are protected in contrast to the first descriptions of PEID, 10 of the patients in this case series were successfully operated without any violation to the lig. flavum. The technique described by Lee et al. [19] was employed in the vertical dissection of lig. flavum and the bevel of working channel was inserted. But contrary to the described method, discography through transforaminal approach was not employed. In addition, all patients in this case series presented with a sequestrum at the shoulder of the nerve root. Axillary disc herniations to our experience required lamina removal.

The patient selection also consisted of those who did not seek a sick-leave report post-operatively, consisting mainly of those who were self-employed. Blue collar workers requiring manual labor usually work at jobs

where their employer seeks a sick-leave report. White collar workers mostly perform desk or administrative work requiring little manual labor which would correlate with previous findings. In a study where post-operative recovery times were evaluated, a worker's compensation claim and physically demanding occupations correlated with longer periods of sick leave [12] roughly defining blue collar workers. The white collar workers in this study were mostly employed in their own businesses thus a longer recovery period would result in less earnings which may have hastened their recovery.

A single patient in this case series was a 31-year-old professional football player in the position of goalkeeper. He was able to return-to-work after 4 days, started workouts 10 days after surgery and played in a professional match a month after the surgery. Further studies focusing on the employment of sports players may reveal beneficial results as the literature review yielded only a single case report. A 60-year-old Japanese dentist was operated for bilateral L4–5 disc herniation via PELD and returned to work 5 days later and played golf 3 months later [20].

Although football players are not considered a blue collar worker, the immense amount of physical exercises along with an expectation of soaring performance does summate for manual labor. Despite the data supporting a longer recovery time for lumbar discectomy in patients performing manual labor as stated above, this patient was in good physical condition and health otherwise. Previous publications have put forward the importance of pre-operative physical status of patients in accelerated recovery and may explain the swift recovery in this case. In a very large cohort study from the NeuroPoint-SD registry, the preoperative physical functional score along with male gender and younger age correlated with a faster return-to-work [13].

PEID can be performed under local, spinal or general anesthesia. All patients were given the three options, but all of them selected general anesthesia. Our previous experience with local and spinal anesthesia required additional sedation, creating a similar post-anesthesia status. The short duration of the operation along with minimal blood loss resulted in a fast recovery post-operatively, allowing the patients to be mobilized 4–6 h after surgery and discharged on the night of the surgery.

While there are numerous meta analyses on the effectiveness of analgesics and their combinations after lumbar surgery, there is scarce data focusing on the amount of consumption upon need for basis. A study evaluated effect of ketoprofen, a propionate like naproxen, and its combination with propacetamol after disc surgery. The patients received 50 mg of ketoprofen every 6 h for 48 h, roughly corresponding to 8 tablets of naproxen [21]. A similar study evaluated the effect of indomethacin, an

acetate like diclofenac. The patients received 100 mg of indomethacin every 12 h for 3 days, roughly equating to 6 tablets of diclofenac [22]. Although the analgesics used in this case series has no equivalent analysis in the literature, broadly speaking the patients opted for diminished use of analgesics. The reduction in leg pain VAS scores reflects this attitude.

We must also note the psychological impact of the surgeon advising the patient to return-to-work whenever they felt fit so. Stigmatizing a standard time frame for recovery and implementing this to the patient may delay the recovery period as the patient is convinced that they will heal at the end of that same standard time frame. The effect of self-efficacy and illness perception on the outcome of surgery has been evaluated previously for orthopedic surgery [23] but remains a virgin field for spine disorders. The patients did not seek a sick-leave report in this case series and were advised and optimistically encouraged to recover in a short period of time. This may have influenced the shorter return-to-work duration as well. In a study where 152 patients were operated for LDH, patients were not restricted for physical activity after surgery and were encouraged to return-to-work as soon as possible [12]. This reassurance by the surgeons allowed the patients to return-to-work after a short amount of time at an average of 1.2 weeks after surgery.

While there are no studies evaluating the cost-effectiveness of endoscopic approach to traditional microdiscectomy, surmounting evidence of shorter hospital stay, earlier return-to-work and lower use of narcotics along with higher rates for returning to previous work would contribute to the potential cost-effectiveness [24].

Although early ambulation is correlated with early recurrence, in a study where 300 patients were operated for LDH via three different endoscopic approaches, the average recurrence rate was found to be 9.33 with PELD having the lowest recurrence rate of 7% [25]. The same study yielded an average recurrence time of 3.26 months. However, no patient has presented with a recurrence after a 6 month follow-up.

It must be noted that this is a case series of fourteen patients and does have limitations. It is a case series and a retrospective analysis thus is prone to selection bias. It lacks a control arm being a case series. Most of the patients are white collar works with a lighter workload. This may be a contributing factor for favorable outcome. A cohort study comparing patients with lower back pain and comparison of work load factors is necessary. The effect of the surgical techniques employed, along with absence of lower back pain preoperatively and the amount of workload should be analyzed with control and comparison groups in a cohort study. In

addition, the follow-up period of 6 months is relatively short compared with other studies.

During the last decade almost all surgical interventions have shifted towards minimally invasive approaches and spine surgery is not exempt from it. The main goal in PELD is to preserve healthy tissue, protect the patient from long-term complications and decrease the recovery period. In this case series of fourteen patients operated for single-level LDH via endoscopic interlaminar sequestrectomy, the possible underlying factors for a swift recovery period via the evaluation of patient, surgical and psychological factors have been shared. The time period for return-to-work after minimally invasive approach is a predictor for a successful operation and we have aimed to put forward possible variables contributing to this factor.

Abbreviations

LDH	Lumbar disc herniation
MISS	Minimally invasive spine surgery
PELD	Percutaneous endoscopic lumbar discectomy
AF	Annulus fibrosus
PEID	Percutaneous endoscopic interlaminar discectomy
VAS	Visual analog scale
ODI	Oswestry Disability Index

Acknowledgements

The authors would like to acknowledge all the patients giving consent to have their results published.

Author contributions

IB: conceptualization, methodology, software, writing original draft. CC, KP: investigation, data curation. SS: formal analysis, investigation, surgery, review and editing. OY: supervision, visualization.

Funding

This research received no specific grant from any funding agency in the public, commercial, or not-for-profit sectors. No corporate, government or institutional funding has been received.

Availability of data and materials

All data related to this study can be requested from the corresponding author via e-mail.

Declarations

Ethics approval and consent to participate

Ethics board approval from Cankiri Karatekin University (No. 473/010321) was obtained prior to the study. The study was carried out according to the latest revision of the Helsinki Declaration regarding medical research involving human subjects. Informed written consent was acquired from all patients before the study.

Consent for publication

A written patient consent form from all the patients was obtained.

Competing interests

The authors have no competing interests related to this study.

Received: 27 July 2022 Accepted: 6 February 2024

Published online: 16 February 2024

References

- Gugliotta M, da Costa BR, Dabis E, Theiler R, Jüni P, Reichenbach S, et al. Surgical versus conservative treatment for lumbar disc herniation: a prospective cohort study. *BMJ Open*. 2016;6(12): e012938. <https://doi.org/10.1136/bmjopen-2016-012938>.
- Aydin M, Sasani M, Oktenoglu T, Durmaz MO, Bozkus H, Keskin F, et al. Clinical evaluation of 34 cases treated with sequestrectomy: minimum two year follow up. *Int J Surg Open*. 2017;1(8):11–4. <https://doi.org/10.1016/j.ijso.2017.05.004>.
- Priola SM, Ganau M, Raffa G, Scibilia A, Farrash F, Germanò A. A Pilot study of percutaneous interlaminar endoscopic lumbar sequestrectomy: a modern strategy to tackle medically-refractory radiculopathies and restore spinal function. *Neurospine*. 2019;16(1):120–9. <https://doi.org/10.14245/ns.1836210.105>.
- Kambin P, Casey K, O'Brien E, Zhou L. Transforaminal arthroscopic decompression of lateral recess stenosis. *J Neurosurg*. 1996;84:462. <https://doi.org/10.3171/jns.1996.84.3.0462>.
- Ahn SS, Kim SH, Kim DW, Lee BH. Comparison of outcomes of percutaneous endoscopic lumbar discectomy and open lumbar microdiscectomy for young adults: a retrospective matched cohort study. *World Neurosurg*. 2016;86:250–8. <https://doi.org/10.1016/j.wneu.2015.09.047>.
- Qin R, Liu B, Hao J, Zhou P, Yao Y, Zhang F, et al. Percutaneous endoscopic lumbar discectomy versus posterior open lumbar microdiscectomy for the treatment of symptomatic lumbar disc herniation: a systemic review and meta-analysis. *World Neurosurg*. 2018;120:352–62. <https://doi.org/10.1016/j.wneu.2018.08.236>.
- Azarhomayoun A, Chou R, Shirdel S, Lakeh MM, Vaccaro AR, Rahimi-Movaghar V. Sequestrectomy versus conventional microdiscectomy for the treatment of a lumbar disc herniation: a systematic review. *Spine*. 2015;40(24):E1330–9. <https://doi.org/10.1097/BRS.0000000000001174>.
- Kreiner DS, Hwang SW, Easa JE, Resnick DK, Baisden JL, Bess S, North American Spine Society, et al. An evidence-based clinical guideline for the diagnosis and treatment of lumbar disc herniation with radiculopathy. *Spine J*. 2014;14(1):180–91. <https://doi.org/10.1016/j.spinee.2013.08.003>.
- Amin RM, Andrade NS, Neuman BJ. Lumbar disc herniation. *Curr Rev Musculoskelet Med*. 2017;10(4):507–16. <https://doi.org/10.1007/s12178-017-9441-4>.
- Fairbank JC, Pynsent PB. The Oswestry disability index. *Spine*. 2000;25(22):2940–52. <https://doi.org/10.1097/00007632-200011150-00017>. (discussion 2952).
- Koebbe CJ, Maroon JC, Abla A, El-Kadi H, Bost J. Lumbar microdiscectomy: a historical perspective and current technical considerations. *Neurosurg Focus*. 2002;13(2):E3. <https://doi.org/10.3171/foc.2002.13.2.4>.
- Carragee EJ, Han MY, Yang B, Kim DH, Kraemer H, Billys J. Activity restrictions after posterior lumbar discectomy. A prospective study of outcomes in 152 cases with no postoperative restrictions. *Spine*. 1999;24(22):2346–51. <https://doi.org/10.1097/00007632-199911150-00010>.
- Than KD, Curran JN, Resnick DK, Shaffrey CI, Ghogawala Z, Mummaneni PV. How to predict return to work after lumbar discectomy: answers from the NeuroPoint-SD registry. *J Neurosurg Spine*. 2016;25(2):181–6. <https://doi.org/10.3171/2015.10.SPINE15455>.
- Atarod M, Mirzamohammadi E, Ghandehari H, Mehrdad R, Izadi N. Predictive factors for return to work after lumbar discectomy. *Int J Occup Saf Ergon*. 2019;24:1–6. <https://doi.org/10.1080/10803548.2019.1600890>.
- Perez-Cruet MJ, Foley KT, Isaacs RE, Rice-Wyllie L, Wellington R, Smith MM, et al. Microendoscopic lumbar discectomy: technical note. *Neurosurgery*. 2002;51(5 Suppl):S129–36.
- Choi KC, Kim JS, Park CK. Percutaneous endoscopic lumbar discectomy as an alternative to open lumbar microdiscectomy for large lumbar disc herniation. *Pain Physician*. 2016;19(2):E291–300.
- diZerega GS, Traylor MM, Alphonso LS, Falcone SJ. Use of temporary implantable biomaterials to reduce leg pain and back pain in patients with sciatica and lumbar disc herniation. *Materials*. 2010;3(5):3331–68. <https://doi.org/10.3390/ma3053331>.
- Kim HS, Park JY. Comparative assessment of different percutaneous endoscopic interlaminar lumbar discectomy (PEID) techniques. *Pain Physician*. 2013;16(4):359–67.
- Lee JS, Kim HS, Jang JS, Jang IT. Structural preservation percutaneous endoscopic lumbar interlaminar discectomy for L5-S1 herniated nucleus

- pulposus. *Biomed Res Int.* 2016;2016:6250247. <https://doi.org/10.1155/2016/6250247>.
20. Sugiura K, Yamashita K, Manabe H, Ishihama Y, Tezuka F, Takata Y, et al. Prompt return to work after bilateral transforaminal full-endoscopic lateral recess decompression under local anesthesia: a case report. *J NeuroSurg A Cent EurNeurosurg.* 2020. <https://doi.org/10.1055/s-0040-1712463>.
 21. Fletcher D, Nègre I, Barbin C, François A, Carreres C, Falgueirettes C, et al. Postoperative analgesia with iv propacetamol and ketoprofen combination after disc surgery. *Can J Anaesth.* 1997;44(51):479–85. <https://doi.org/10.1007/BF03011934>.
 22. McGlew IC, Angliss DB, Gee GJ, Rutherford A, Wood AT. A comparison of rectal indomethacin with placebo for pain relief following spinal surgery. *Anaesth Intensive Care.* 1991;19(1):40–5. <https://doi.org/10.1177/0310057X9101900107>.
 23. Waldrop-Valverde D, Lightsey OR, Ethington CA, Woemmel CA, Coke AL. Self-efficacy, optimism, health competence, and recovery from orthopedic surgery. *J Couns Psychol.* 2001;48(2):233–8. <https://doi.org/10.1037/0022-0167.48.2.233>.
 24. Hofstetter CP, Hofer AS, Wang MY. Economic impact of minimally invasive lumbar surgery. *World J Orthop.* 2015;6(2):190–201. <https://doi.org/10.5312/wjo.v6.i2.190>.
 25. Kim HS, You JD, Ju CI. Predictive scoring and risk factors of early recurrence after percutaneous endoscopic lumbar discectomy. *Biomed Res Int.* 2019. <https://doi.org/10.1155/2019/6492675>.

Publisher's Note

Springer Nature remains neutral with regard to jurisdictional claims in published maps and institutional affiliations.