

RESEARCH

Open Access



Toxic effects of an organophosphate pesticide, envoy 50 SC on the histopathological, hematological, and brain acetylcholinesterase activities in stinging catfish (*Heteropneustes fossilis*)

Rabeya Akter¹, Mst Arzu Pervin¹, Halima Jahan¹, Sharmin Ferdewsi Rakhi^{1,2}, A. H. M. Mohsinul Reza^{1,3} and Zakir Hossain^{1*}

Abstract

Background: Freshwater fish in Bangladesh are adversely affected by the washed off pesticides, used in agriculture. The aim of this study was to evaluate the impacts of a commonly used organophosphate pesticide on freshwater stinging catfish, *Heteropneustes fossilis*, which envisioned that the possible threats might occur by this organophosphate group to other species in the wild.

Methodology: To study the potential hazards of Envoy 50 SC on *H. fossilis*, fry of the fish were exposed to the acute toxicity tests. Changes in the hematological parameters, organ-specific histomorphologies, and brain acetylcholinesterase (AChE) activities were determined by treating the fish with agricultural recommended dose and below that dose of 0.015 and 0.0075 ppm, respectively.

Results: LC₅₀ of Envoy 50 SC for the fish was determined as 0.151 (0.014–0.198) ppm. Pesticide abruptly altered the normal tissue structures of the gill, liver, and kidney. The major alterations included were the gill lamellae missing, gill clubbing, hyperplasia, nuclear hypertrophy, vacuolation, glomerular expansion, increasing diameter of the renal tubules, hemorrhage, necrosis, and pyknosis. In blood cells, changes observed in the peripheral nuclear erythrocyte were large lymphocyte, dead cell, fusion of the cells, binucleated cells, tear-shaped cells, ghost cells, senile cells, and abnormal structures of the cells. Significantly lower ($P < 0.05$) red blood cell (RBC) count and AChE activities in fish brain due to the pesticide exposure suggested the reasons of abrupt behavior, increased oxygen consumption, and fish mortality at higher concentration of this organophosphate pesticide.

Conclusion: The presence of pesticides, even at low concentrations, caused deleterious effects on the earlier life stages of a comparatively harder and robust fish, suggesting a wider range effect on the more sensitive wild life, in particular decrease in survival in their native environment. Therefore, measures should be taken to minimize the risk of contamination of the aquatic environment by such toxic chemicals.

Keywords: Envoy 50 SC, Stinging catfish, Fish toxicology, Tissue damage, Hematology, Acetylcholinesterase

* Correspondence: zakir.fbg@bau.edu.bd

¹Department of Fisheries Biology and Genetics, Faculty of Fisheries, Bangladesh Agricultural University, Mymensingh 2202, Bangladesh
Full list of author information is available at the end of the article

Background

Over the last few decades, due to the significant impacts on aquatic flora and fauna, the problem associated with the environmental pollution has been a concern worldwide (Zahra, 2017; Özkara, Akyıl, & Konuk, 2016; Rakhi, Reza, Hossen, & Hossain, 2013). Toxic organic pollutants that include a large number of agrochemicals, such as pesticides, many of which are non-biodegradable and carcinogenic, are consistently being used in crop fields. As a result, fish and other aquatic biota, exposed to the pesticide-contaminated water are at much higher risk of dying (Katagi, 2010; Reza, Rakhi, Hossen, & Hossain, 2017). Seepage of pesticides into rivers and streams can be highly lethal to aquatic life and often might change the bionetwork of a particular area (Mensah, Palmer, & Muller, 2014; Sánchez-Bayo, Goka, & Hayasaka, 2016). Moreover, repeated exposure to sublethal doses of some pesticides can cause physiological, behavioral, and environmental modifications by endangering fish population, abandonment of nests and broods, decreased immunity to diseases, and decreased predator avoidance (Saaristo et al., 2018; Hamilton et al., 2016). Additionally, pesticides can accumulate in water bodies and affect the source of food for young fish by actively altering the trophic levels (Lew, Lew, Biedunkiewicz, & Szarek, 2013; Hossain, Rahman, & Mollah, 2001). Pesticides can also abruptly alter the lower trophic levels that instigate the fish to forage further, exposing them to greater risks of predators. Generally, insecticides are more toxic to aquatic life than herbicides and fungicides (Aktar, Sengupta, & Chowdhury, 2009); therefore, their tremendous use for the domestic sphere is required to be reconsidered. However, the sooner a pesticide degrades in the atmosphere, the less menace it might cause to aquatic life (Gill & Garg, 2014).

Envoy 50 SC is a wide-ranging commonly used organophosphate (OP) insecticide, used commercially to control foliar insects in croplands (Rusyniak & Nanagas, 2004). Accumulation of this OP insecticide in different aquatic organisms, particularly in fish through air drift or surface runoff adversely affects them (Varo et al., 2002). This chemical is a well-known acetylcholinesterase inhibitor, which plays a crucial role in neurotransmission by rapid hydrolysis of neurotransmitter acetylcholine (ACh) to choline and acetate at cholinergic synapses (Kwong, 2002). Therefore, they can alter the neurological responses of non-target organisms even at very low concentrations (Grue, Gibert, & Seeley, 1997; Hamilton et al., 2016).

During the contaminant exposure, histopathological observations can give insights into the organism's health and responses towards the stressors, and therefore have been widely used biomarkers, both in the laboratory and field studies (Yancheva, Velcheva, Stoyanova, &

Georgieva, 2016; Schwaiger et al., 1997; Thophon et al., 2003; Hook, Gallagher, & Batley, 2014). Histopathological biomarkers are very useful for examining the structure of vital organs (gills, kidney, and liver) when respiration, excretion, or detoxification processes are affected by environmental contaminants (Gernhofer, Pawet, Schramm, Müller, & Triebkorn, 2001). Additionally, hematological parameters have also been used as health indicators to assess the physiological status of fish and other vertebrates (Chandra & Chandra, 2013; Blahova et al., 2014; Al-Asgah, Abdel-Warith, Younis, & Allam, 2015). Blood biochemistry profiles and hematology of organisms are gaining increasing importance due to its value in monitoring the health status rapidly and effectively (Hrubec, Cardinale, & Smith, 2000). Hematological characteristics can be used as a sensitive index to screen the pathophysiological changes in fish (Kori-Siakpere, Ake, & Idoge, 2005).

Acetylcholinesterase (AChE) is a functional key enzyme of the nervous system for the termination of the nerve impulses by hydrolyzing the neurotransmitter acetylcholine. Inhibitions of AChE results in the accretion of acetylcholine in the central and peripheral synapses and subsequently modify the physiological and neuroendocrine processes (Sandahl, Baldwin, Jenkins, & Scholz, 2005). Such physiological variations can lead to a succession of behavioral changes that include impeded swimming performances, altered social behavior, reduced foraging, and greater predation risks. Therefore, AChE is also a widely used biomarker to give insight to the environmental and pathological perspectives (Lionetto, Caricato, Calisi, Giordano, & Schettino, 2013; Richetti et al., 2011).

Stinging catfish, *Heteropneustes fossilis*, is a freshwater fish with a high yield potential, often found in ponds, ditches, swamps, marshes, and in the rice fields of Southeast Asia (Jha & Rayamajhi, 2010). This species has become increasingly popular due to its delicious taste, appealing market price, and medicinal and nutritional values. It has been proved to be a good candidate for aquaculture due to its very hardy nature. The presence of the accessory respiratory organs also enables this species to survive additional few hours even if outside the water (Khan, Islam, & Hossain, 2003). Although, *H. fossilis* breeds in confined waters during the monsoon months, they can also breed in ponds, derelict ponds, and ditches when sufficient rain water accumulates, which make this fish one of the most susceptible species for exposure to the aquatic pollutants.

In the present study, as a model fish, fry of freshwater stinging catfish, *H. fossilis* was selected to evaluate the Envoy 50 SC-mediated toxicity. Histopathological observations of major organs, changes in hematological parameters, and brain acetylcholinesterase activity were

investigated to understand the probable threats elicited by this organophosphate pesticide during the early life stages of this fish in the wild.

Methods

Sites of the experiment

The bioassay was conducted in the Wet Laboratory of the Department of Fisheries Biology and Genetics, Faculty of Fisheries, Bangladesh Agricultural University, Mymensingh, Bangladesh. The histological study and AChE activities were carried out by using Genetics and Biotechnology Laboratory of the Department of Fisheries Biology and Genetics and Department of Surgery and Obstetrics, Bangladesh Agricultural University, Mymensingh, Bangladesh, respectively.

Experimental design

The study for each treatment was conducted in glass aquaria in triplicates, situated in the Wet Laboratory of the Department of Fisheries Biology and Genetics, Bangladesh Agricultural University, Mymensingh, Bangladesh. Envoy 50 SC was collected from an authorized dealer at Mymensingh town, Bangladesh. Fries of *H. fossilis* were collected from the local fish market and were acclimated in the laboratory condition prior to the experiment. Fish were kept unfed throughout the experimental period (Pandey, Singh, Singh, & Das, 2009). Glass aquaria were properly cleaned and filled with chlorine-free 35 L of tap water and 10 *H. fossilis* with an average length and weight of 1.4 ± 0.14 cm and 1.05 ± 0.12 g, respectively, were acclimated for 2 days. Concentrations of pesticides (0.00375, 0.0075, 0.015, 0.03, 0.06, 0.12, 0.24, and 0.36 ppm) were adjusted and a control was maintained where fish were kept in pesticide-free water. Air stone was used to increase the water circulation in the aquarium. The temperature and pH were measured daily using a mercury centigrade thermometer and a pH meter (Model: pH ep Tester, Romania), respectively. Over the experimental time-frame, dissolved oxygen (DO) in the aquarium was traced using a dissolved oxygen meter (Model: HI 9146-DO meter, Romania). During the pesticide exposure, dead fish were removed, and mortality was recorded daily. The LC_{50} for the fish at 96 h was determined through the acute toxicity tests.

Histopathological study

To observe the histopathological effects of Envoy 50 SC, *H. fossilis* was exposed at agricultural recommended dose (0.015 ppm) and below (0.0075 ppm) the agricultural recommended dose in glass aquaria and maintained for 7 days. The agricultural recommended dose was calculated considering a 20-cm water depth in rice field. A control group was also maintained exposed to

pesticide-free water. Following exposure, the gills, liver, and kidney were collected and preserved in 10% neutral buffered formalin for further analysis. The paraffin wax-embedded samples were sectioned ($5 \mu\text{m}$) with a microtome machine (Leica JUNG RM 2035). After that, the sections were stained with hematoxylin (H) and eosin (E) stains, proceeding through various chemicals of different concentration and time schedule. After staining, the sections were mounted with Canada balsam and kept overnight for permanent slide. Photomicrography of the stained samples was done by using a photomicroscope (OLYMPUS CX41, Japan).

Hematological alteration with pesticide-treated fish

To count the red blood cells, fish were exposed at two different concentrations (i. e., 0.015 and 0.0075 ppm) of Envoy 50 SC for 7 days in triplicates with 4 fish in each group. Group without pesticide treatment served as control. For the study of morphological alterations of erythrocytes, blood smears were prepared on glass slides from fresh unheparinized blood at 7-day-exposed fish. They were air dried, fixed in methanol, and stained with Wright's Giemsa. Blood corpuscles were then examined by immersion oil microscopy and photographed. Photographs were taken with the help of Intel Pentium Q3X computer-attached microscope under $400 \times$ lens (OLYMPUS CX41, Japan). Red blood cells were counted according to the modified method of Math et al. (2016).

The number of RBC per cubic millimeter was calculated by using the following formula:

$$\text{Total RBC (mm}^3\text{)} = \frac{\text{No. of cells} \times \text{dilution factor} \times \text{depth factor}}{\text{Total No. of small squares}} \\ = \text{number cubic mm}$$

Measurement of the AChE activity

For the AChE activity analysis, *H. fossilis* were exposed to 0.015 ppm pesticide containing water in glass aquaria for 10 days. Fish exposed to pesticide-free water was kept as control. Following exposure, the whole brain was dissected out and placed in ice-cold 0.1-M sodium phosphate buffer (pH 8.0). In this study, brain sample was used as in teleost, AChE is maximally distributed in brain (Kopecka, Rybakowas, Barsiene, & Pempkowiak, 2004; Ferenczy, Szegletes, Balint, Abraham, & Nemcsok, 1997). Fish brains were then weighed and homogenized using a glass Teflon homogenizer in homogenization buffer (0.1 M sodium phosphate buffer, 0.1% Triton X-100, and pH 8.0) to achieve a final concentration of 20 mg tissue/ml phosphate buffer. Brain tissue homogenate was centrifuged at 2000 rpm for 10 min at 4°C , and supernatant was removed. An aliquot of supernatant was then removed and measured for protein according to Lowry, Rosebrough, Farr, and Randall (1951) using

bovine serum albumin in homogenization buffer as a standard. A standard curve of known absorbance (bovine serum albumin) was plotted and used to determine the sample protein concentration.

AChE activity was measured according to the method of Ellman, Courtney, Andres, and Featherstone (1961), as optimized by Habig, Giulio, and Donia (1988) and Sandahl et al. (2005). Tissue homogenate (50 µl) was added to 900 µl of cold sodium phosphate buffer (0.1 M containing 0.1% Triton X-100, pH 8.0) and 50 µl of 5,5-dithiobis (2-nitrobenzoic acid) (DTNB; 6 mM), then vortexed and allowed to stand at room temperature for 10 min. Aliquots of 200 µl in triplicate was then placed into microtitre plate wells. The reaction was started with the addition of 50 µl of acetylthiocholine chloride (15 mM) specific for fish (Jash, Chatterjee, & Bhattacharya, 1982). Changes in absorbance was measured with a microplate reader (Model: SPECTRA max 340PC384) at 412 nm.

The rate was calculated as follows:

$$R = 5.74(10^{-4})\Delta A/C_0$$

where R = Rate in moles substrate hydrolyzed per minute per gram of tissue, ΔA = Change in absorbance per min, and C_0 = Original concentration of tissue.

AChE activity was calculated (nmol/min/mg protein).

Statistical analysis

Data obtained from the acute toxicity tests were evaluated using the Probit analysis statistical method to find the LC_{50} values. Student t test and one-way analysis of variance (ANOVA) were used for analyzing the data of AChE and blood cells, respectively. A post hoc Waller Duncan multiple test range was performed considering a 5% significant level using SPSS ver. 17.0 computer software program.

Results

Physicochemical parameters

During the experimental period, temperature, DO, and pH were recorded regularly. The average temperature, initial DO, and pH were recorded as 27.0 ± 3.0 °C, 7.5 ± 1.0 ppm, and 9.3 ± 2.1 , respectively. Data of the oxygen concentration (Table 1) in the aquaria exhibited a declining trend in the DO content with the increasing concentration of pesticide exposure in comparison to the control group that was consistent until the starting of the mortality.

Observation of the behavioral changes

The behaviors of tested fries of *H. fossilis* were observed throughout the experimental period. Some of their vertebral column on the caudal region were bent and showed abnormal swimming (Fig. 1). Several atypical behaviors such as restlessness, antenna movements, loss of balance, and prompt operculum activities were observed when the fries started to be affected by the test. At the acute level, frequent surfacing, gulping with increased mucus discharge, and loss of balance have been observed.

LC_{50} of envoy 50 SC for *H. fossilis*

The LC_{50} of Envoy 50 SC for *H. fossilis* was 0.151 (0.014–0.198) at 96 h (Table 2).

Histopathological observation of fish exposed to pesticides

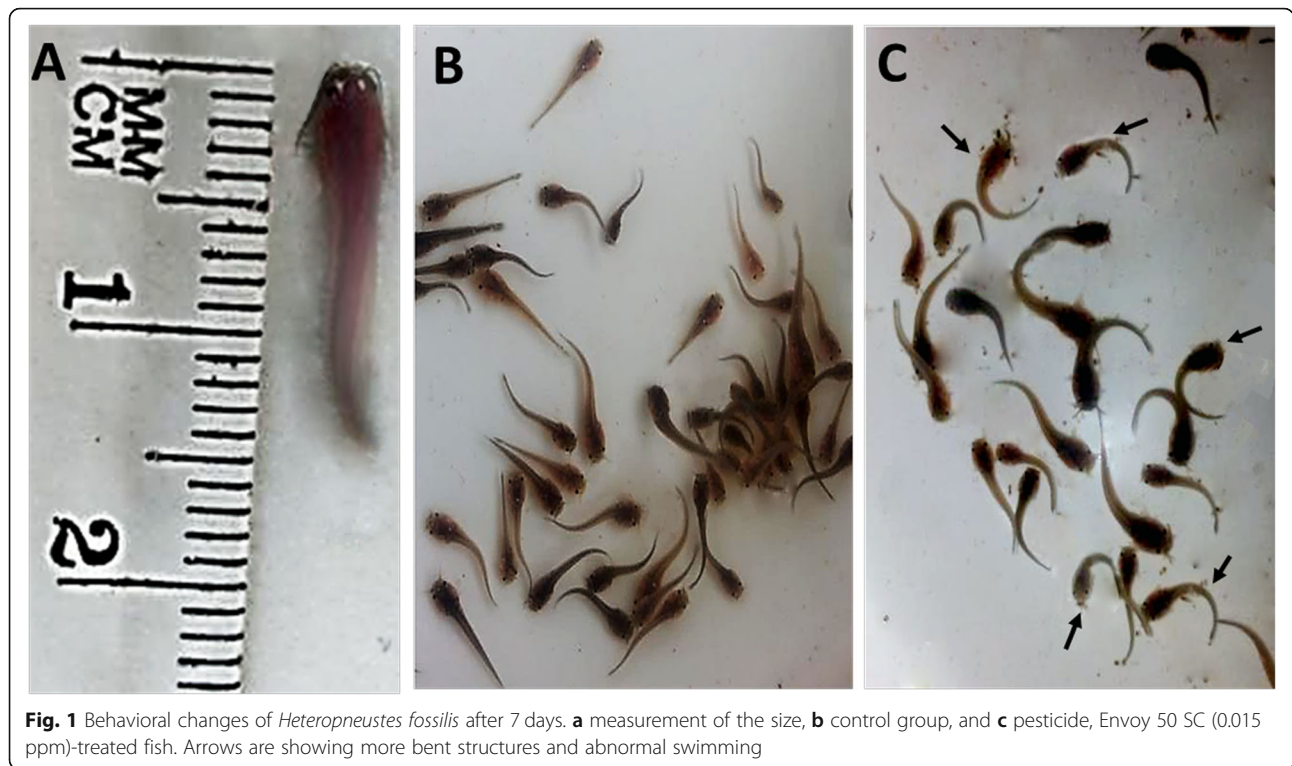
H. fossilis were exposed to Envoy 50 SC at two different concentrations, agricultural recommended dose of 0.015 ppm and half of the agricultural recommended dose of 0.0075 ppm. Structural changes were observed in gills, liver, and kidneys and compared with those of the control. No pathology has been observed in the gill arch and primary and secondary gill lamellae of the control group, whereas at the dose of 0.015 ppm, blood congestion,

Table 1 Changes in dissolved oxygen and fish mortality during the experimental period

Pesticide (ppm)	0 day		2 days		5 days		7 days		Mortality (Total)	DO (%) change after 5 days
	Mortality	DO (ppm)	Mortality	DO (ppm)	Mortality	DO (ppm)	Mortality	DO (ppm)		
0.00	0	7.5 ± 1.0	0	7.35 ± 1.0	0	7.25 ± 1.0	0	7.10 ± 1.0	0	3.33
0.00375	0	7.5 ± 1.0	0	7.30 ± 1.0	0	7.15 ± 1.0	0	7.0 ± 1.0	0	4.67
0.0075	0	7.5 ± 1.0	0	7.25 ± 1.0	0	7.15 ± 1.0	0	7.0 ± 1.0	0	4.67
0.015	0	7.5 ± 1.0	0	7.18 ± 1.0	0	7.08 ± 1.0	0	6.94 ± 1.0	0	5.60
0.03	0	7.5 ± 1.0	0	7.13 ± 1.0	0	7.05 ± 1.0	0	6.90 ± 1.0	0	6.0
0.06	0	7.5 ± 1.0	01	7.0 ± 1.0	02	6.95 ± 1.0	03	6.90 ± 1.0	06	7.33
0.12	0	7.5 ± 1.0	01	7.0 ± 1.0	04	6.96 ± 1.0	06	–	11	7.20
0.24	0	7.5 ± 1.0	03	6.93 ± 1.0	07	6.89 ± 1.0	09	–	19	8.13
0.36	0	7.5 ± 1.0	03	6.90 ± 1.0	11	6.85 ± 1.0	12	–	26	8.67

$N = 30$

(–) Not measured



hyperplasia, curling of secondary lamellae, hemorrhage, epithelial hyperplasia, clubbing, and necrosis were found in the gill (Fig. 2).

Hepatocytes and kidney cells appeared normal in the control group. At 0.015 ppm concentrations, mild alterations were found in the liver tissue (cytoplasmic vacuolation, nuclear hypertrophy, hemorrhage, pyknotic area, vacuolation) (Fig. 3), but more serious alteration of the kidney histology was observed at the same concentration of the pesticide: glomerular expansion, increasing the diameter of renal tubule, necrosis, pyknosis, vacuolation, and hemorrhage. Similar pathologies were also observed at the lower concentration of the pesticide (0.0075 ppm) but to a lesser extent for liver tissue (Fig. 4).

Table 2 LC₅₀ of *Heteropneustes fossilis*

Conc. (ppm)	No. of dead fish	Mortality (%)	LC ₅₀ (P < 0.05)	χ ² value
0.00	0	0	0.151 (0.014–0.198)	15.02
0.00375	0	0		
0.0075	0	0		
0.015	0	0		
0.03	0	0		
0.06	6	20		
0.12	11	36.7		
0.24	19	63.3		
0.36	26	86		

N = 30

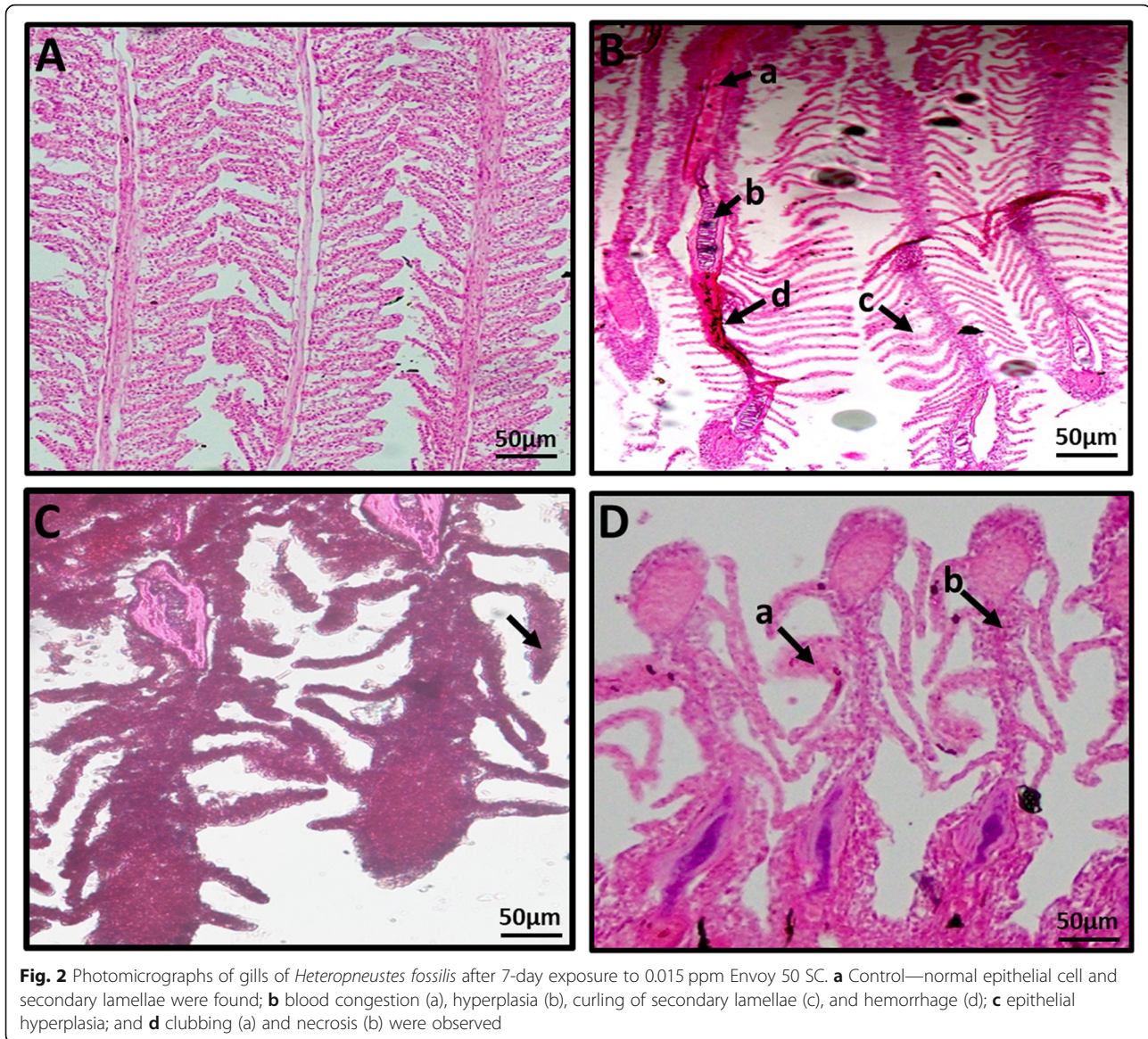
Nevertheless, in the below agricultural doses, pathologies also have been identified in the gills and liver (Figs. 5 and 6), but it was comparatively less than those of the agricultural recommended doses. However, compared with other organs, pathologies were found almost similar in kidneys (Fig. 7) in both doses.

Hematological alteration of pesticide-treated fish

Uniform blood smears from normal healthy unpoluted fish samples revealed that each erythrocyte was an oval-shaped cell with a concentric nucleus with the outer edge of the cell. At the dose of 0.015 ppm of Envoy 50 SC, large lymphocyte, dead cell, fusion of cells, binucleated cell, tear-shaped cell, ghost cell, senile cell, and abnormal shape of the cells were found (Fig. 8). The mean blood cell counts were significantly higher ($P < 0.05$) at 0.0075 ppm as $4.74 \pm 0.80 (10^6 \text{ mm}^3)$ and at 0.015 ppm as $3.84 \pm 0.35 (10^6 \text{ mm}^3)$ compared with those of the control as $6.05 \pm 0.12 (10^6 \text{ mm}^3)$.

AChE activity of fish brain exposed to envoy 50 SC

The AChE activity in the brain of *H. fossilis* was calculated as $75.7 \pm 5.9 \text{ nmol/min/mg protein}$ in control and $42.6 \pm 5.8 \text{ nmol/min/mg protein}$ at the dose of 0.015 ppm that showed significant ($P < 0.05$) inhibition compared with the control group (Fig. 9).



Discussion

This study was conducted on a freshwater stinging catfish, *H. fossilis*, to understand the possible effects of the commonly used organophosphate pesticides on the early life stages of this comparatively resilient fish species. In the present experiment, despite of using same conditions in all the aquariums, decreasing oxygen concentration in pesticide-exposed aquarium compared with the control group which presumably happened due to the elevated respiration of the stressed fish. These data were partly supported by another study, where oxygen consumption of some commonly cultured fish species, *Labeo rohita*, *Cirrhina mrigala*, *Catla catla*, *Hypophthalmichthys molitrix*, and *Ctenopharyngodon idella* fingerlings were determined through different thermal challenges (Tabinda et al., 2003). During the study, the lowest

oxygen utilization rates were determined at 30 °C, which was followed by the rapid death of most of the species. Moreover, the oxygen consumption rate was found much higher in other temperatures, where the study was performed in airtight 4-l bottles with stocking of 20 fish fingerlings. Although, the oxygen consumption rate was reported much higher for the fries in that study, in the present study, the condition was much different, where fish were kept in larger open-glass aquariums. Additionally, during stress conditions, being an air-breathing fish, *H. fossilis* depend more on aerial respiration, which causes the results of the change in DO more inconspicuous. However, more studies on oxygen consumption are required for completely understanding the stress responses of air-breathing fish due to the pesticide exposure.

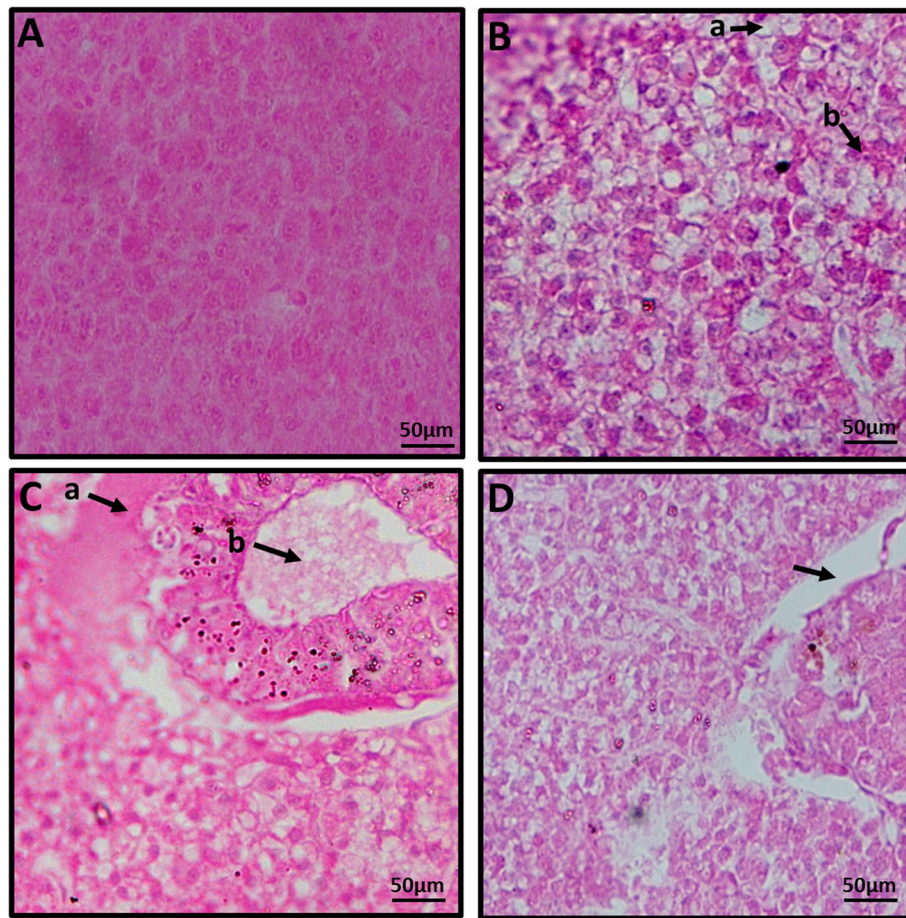


Fig. 3 Photomicrographs of liver of *Heteropneustes fossilis* after 7-day exposure to 0.015 ppm Envoy 50 SC. **a** Control—normal regular and systematic arrangement of hepatocytes were found; **b** cytoplasmic vacuolation (a) and nuclear hypertrophy (b); **c** hemorrhage (a) and pyknotic area (b); and **D** vacuolation were observed

The lethal effects of pesticides on test animals can be expressed as LC_{50} value. In the present study, the LC_{50} value of Envoy 50 SC was 0.151 ppm for *H. fossilis* at 96 h. Deka and Mahanta (2012) found that the LC_{50} value of Malathion was 0.98 ppm for *H. fossilis* at 96-h exposure, whereas Hossain, Haldar, and Mollah (2000) estimated the LC_{50} value of Diazinon as 2.97 ppm for *L. rohita* at 96-h exposure. Hossain et al. (2001) found the LC_{50} values were 0.3530 and 1.2809 ppm for Diazinon 60 EC and Dimecron 100 SCW, respectively, at 48-h exposure on a zooplankton, *Diaptomus*. Sharbidre, Metkari, and Patode (2011) recorded the LC_{50} values of methyl parathion and chlorpyrifos to guppy fish, *Poecilia reticulata*, were 8.48 ppm and 0.176 ppm, respectively. In addition, the LC_{50} values were 6.75, 22.95, and 375.26 ppm for *Anabas testudineus*, *Channa punctatus*, and *Barbodes gonionotus*, respectively, on Dimecron 100 SCW at 96 h (Hossain, Rahman, & Mollah, 2002). These indicated that the LC_{50} value is species specific, and different pesticides have different LC_{50} value.

Anomalous histology was observed under exposure to Envoy 50 SC. During histological study, mild to severe alteration in gills were recorded, whereas the pathologies were more noticeable at a higher dose than the lower one. Tissue-specific structural alterations from the polluted ecosystem have also been recognized (Marchand, Van Dyk, Pieterse, Barnhoorn, & Bornman, 2009) from other studies. The results of this study are also supported by Zodrow, Stegemanb, and Tanguay (2004), who recorded hypertrophy and fusion of secondary gill lamellae in zebrafish. Benli and Ozkul (2010) found telangiectasis at the tip of secondary gill lamellae following the 96-h exposure of Nile tilapia in an organophosphate pesticide. Reza et al. (2017) also found mentionable structural alterations with major pathological signs in the gills of 0.058 ppm organophosphate-treated *Labeo rohita*, which included gill clubbing, hemorrhage, and pyknosis.

The hepatocytes and other kidney tissues of *H. fossilis* showed ultrastructural damages compared with those of

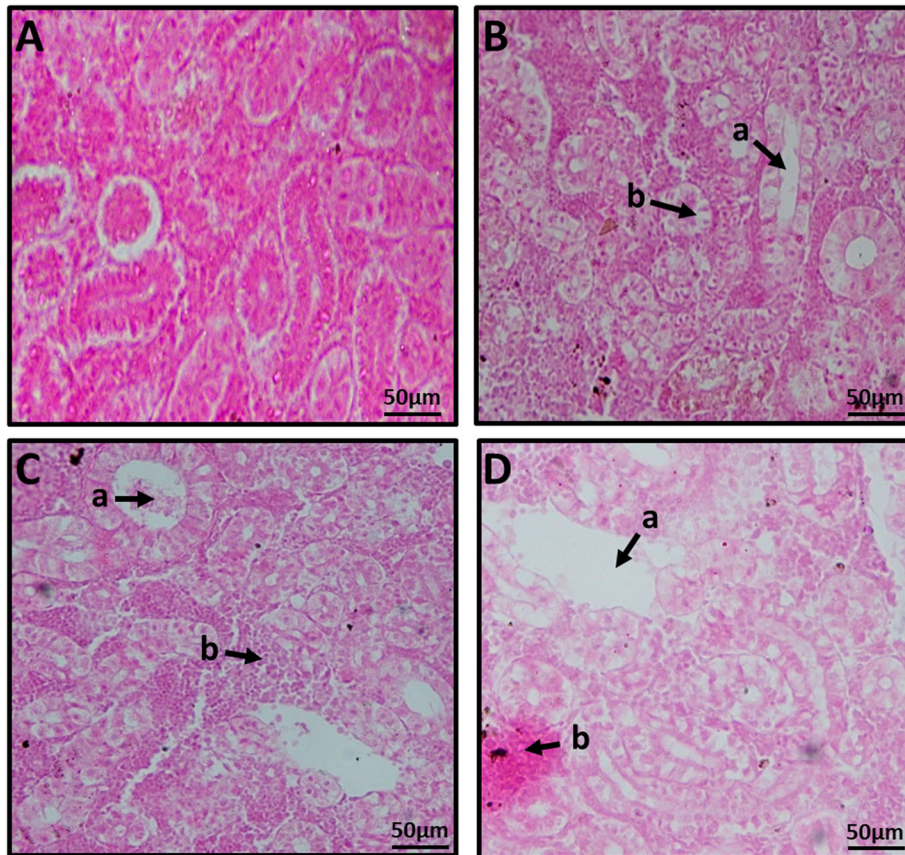


Fig. 4 Photomicrographs of the kidney of *Heteropneustes fossilis* after 7-day exposure to 0.015 ppm Envoy 50 SC. **a** Control—normal regular and systematic arrangement of kidney tubules and hematopoietic cells were found; **b** glomerular expansion (a) and increasing the diameter of renal tubule (b); **C** necrosis (a) and pyknosis (b); and **d** vacuolation (a) and hemorrhage (b) were observed

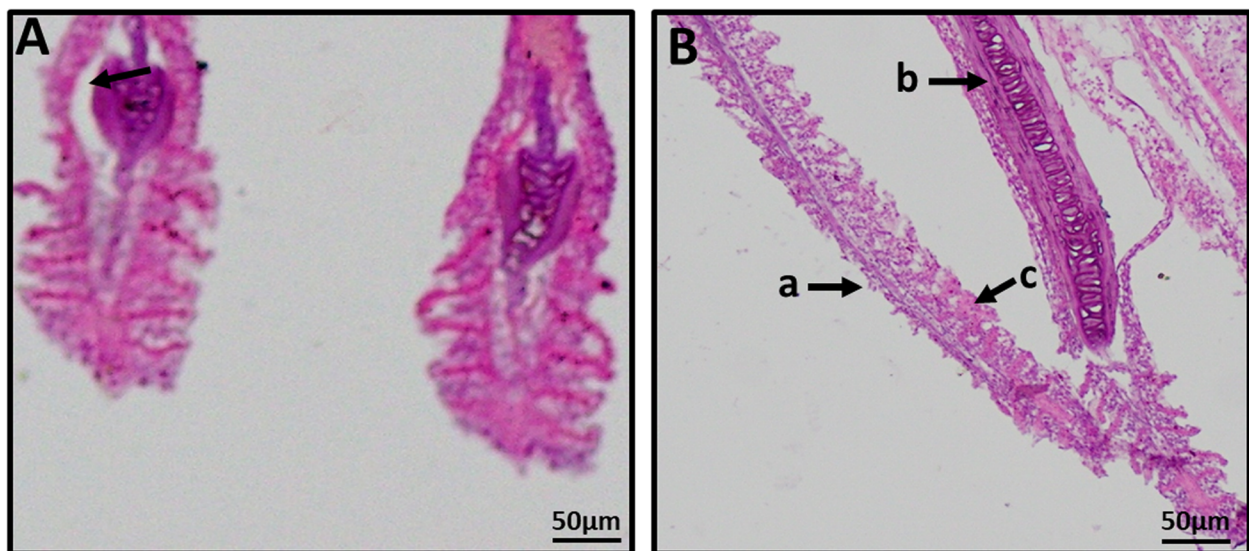


Fig. 5 Photomicrographs of gills of *Heteropneustes fossilis* after 7-day exposure to 0.0075 ppm Envoy 50 SC. **a** vacuolation and **b** missing of secondary gill lamellae (a), hyperplasia (b), and clubbing (c) were observed

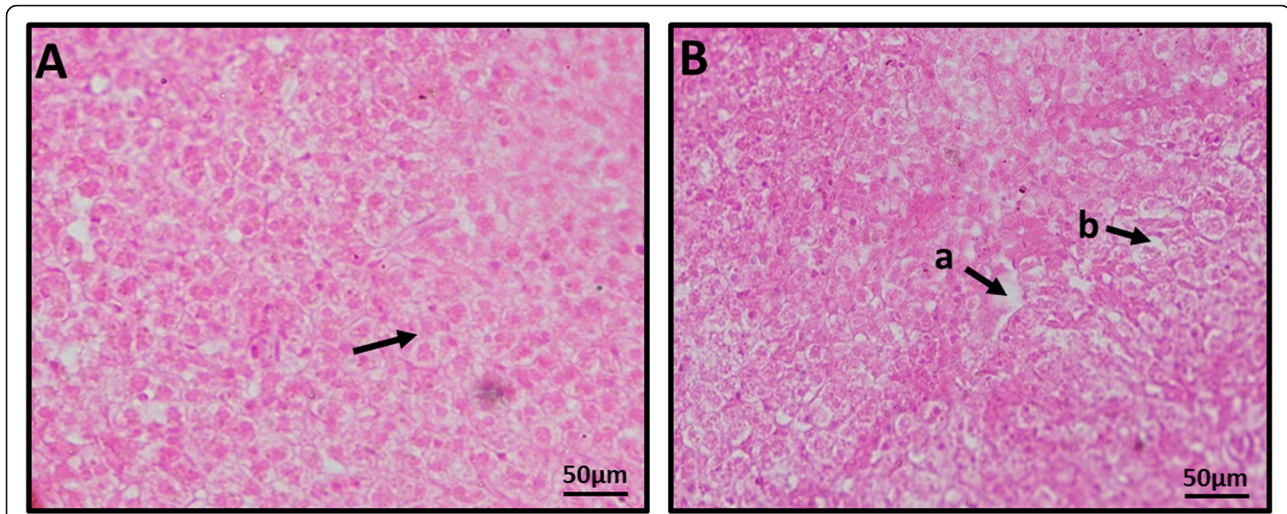


Fig. 6 Photomicrographs of liver of *Heteropneustes fossilis* after 7-day exposure to 0.0075 ppm Envoy 50 SC. Severe (a) nuclear hypertrophy and (b) vacuolation (a) and cytoplasmic vacuolation (b) were observed

the control group that included glomerular expansions, cellular degeneration, increased renal tubule diameter, pyknotic area, melanomacrophage, fatty degeneration, lipid droplets, vacuole, and hemorrhage formation in the hepatocytes. In kidneys, with both doses of pesticides, these pathologies have been observed, which might be due to the osmoregulatory function of the kidney. Similar results were also observed earlier by Hossain et al. (2002) and Rahman, Hossain, Mollah, and Ahmed (2002) from the organophosphate pesticide-exposed fish liver, whereas hypertrophy and lipidosis were prevalent in the study of Zodrow et al. (2004). Additionally, Oropesa, Cambero, Gómez, Roncero, and Soler (2009) reported lipid drops and necrotic foci in the *Cyprinus carpio* liver, while Reza et al. (2017) found severe

alterations like formation of vacuoles, hemorrhage, and fatty degeneration in 0.058 ppm Envoy 50 SC-treated *L. rohita* liver and moderate hemorrhage, fatty degeneration, and lipid droplets for the same species due to the exposure at 0.108 ppm. These results indicated that different pesticides and fish species showed similar pathologies.

Pathologies of the kidney of the pesticide-treated fish of the present study also partially agrees with Hossain et al. (2002) and Rahman et al. (2002), as they found comparatively more pathologies in *B. gonionotus*. Fischer-Scherl et al. (1991) acknowledged pathological alterations of renal corpuscles and renal tubule's components in *Oncorhynchus mykiss* during 28-day exposure of razine (5–40 µg/l). Additionally,

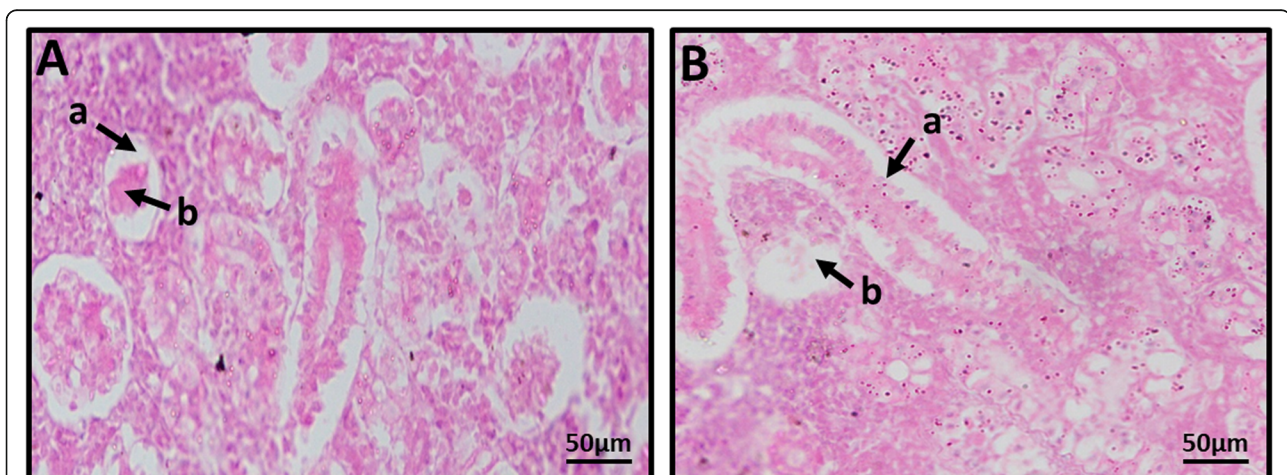


Fig. 7 Photomicrographs of kidney of *Heteropneustes fossilis* after 7-day exposure to 0.0075 ppm Envoy 50 SC. Severe (a) glomerular expansion (a) and cellular degeneration (b) and (b) increasing the diameter of renal tubule (a) and vacuolation (b) were observed

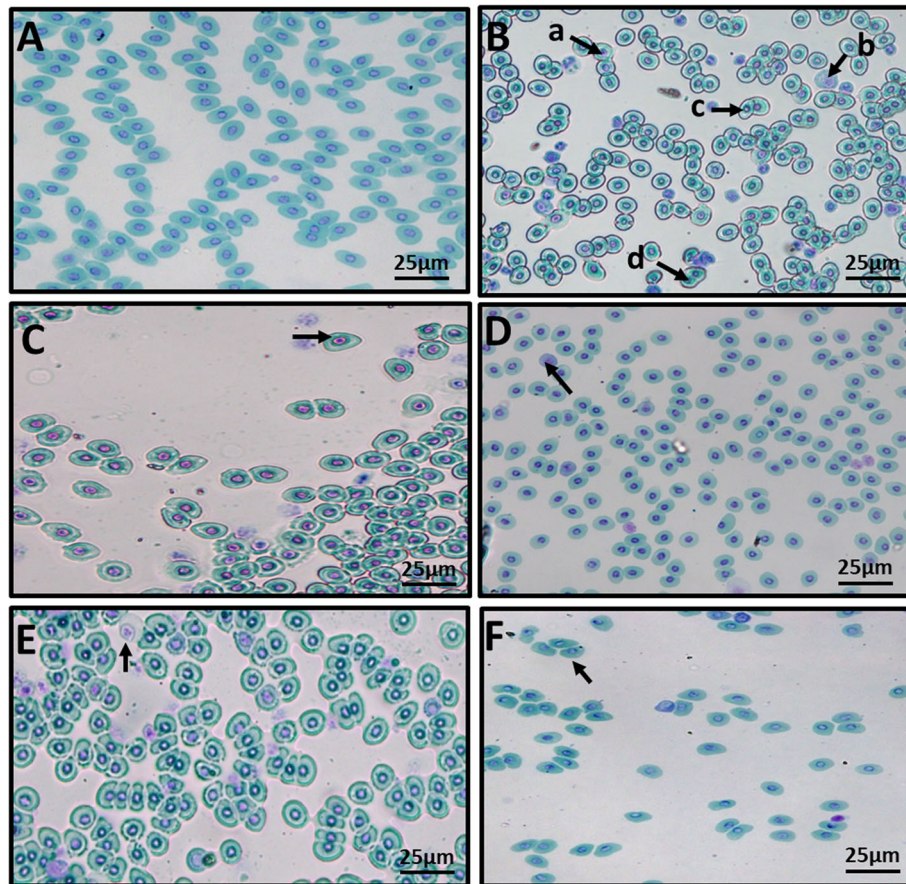


Fig. 8 Photomicrographs of blood smears of *Heteropneustes fossilis* after 8-day exposure to 0.015 ppm Envoy 50 SC. **a** Control—normal regular and systematic arrangement of nucleus of erythrocytes were found; **b** small nucleus (a), dead cell (b), fusion of cells (c), and binucleated cell (d); **c** tear-shaped cell; **d** ghost cell; **e** senile cell; and **f** abnormal shape of cells were observed

necrotic renal hemopoietic tissue and endothelial cells at 80–2800- $\mu\text{g/l}$ exposure have also been observed in the experimental group. Alike the results from this experiment, abnormalities in kidney tissues of rare minnow (*Gobiocypris rarus*) have significant toxic effects of atrazine (10 $\mu\text{g/l}$, 28-day exposure) in this species. Pathologies recorded from the study were lesions in kidney tissues, expansion in the lumen, necrotic and degenerative tubular epithelia, and shrinkage of the glomeruli (Yang, Zha, Li, Li, & Wang, 2010). Conversely, almost no differences between control and 2,3,7,8-Tetrachlorodibenzo-p-dioxin (TCDD)-exposed zebra fish kidney have been observed from a study of Zodrow et al. (2004). However, Reza et al. (2017) found slight structural changes with hemorrhage, mild vacuole, and degenerating kidney tubule at 0.058 ppm in *L. rohita*, whereas relatively lower effects with some melanin pigments and vacuoles have been observed from the *B. gonionotus* kidney tissues at the same dose. When the fish were treated with 0.108 ppm of Envoy 50 SC, pathologies studied were pyknosis, moderate hemorrhage and hyaline for *L. rohita*, and pyknosis, moderate vacuole, and necrosis

for *B. gonionotus* kidney. More structural impairments in *L. rohita* compared with those in *B. gonionotus* were indicators of susceptibility of the former species toward pesticide exposure.

Alterations of blood components are important biomonitoring tools in toxicological research because of the potentiality for rapid assessment of the chronic toxicities of a compound. Generally, any unfavorable changes in water quality are reflected in the blood of the aquatic organisms by separating the blood cells with thin epithelial membrane (Kori-Siakpere et al., 2005). In the present study, several changes in peripheral erythrocyte were found due to the exposure of 2 different concentrations of Envoy 50 SC. According to Adhikari, Sarkar, Chatterjee, Mahapatra, and Ayyappan (2004), and Evans and Claiborne (2005), biochemical and hematological indices can be useful diagnostic markers for the functional status and stress responses of fish during pesticide exposure. The results were also supported by other studies, where alteration in the blood parameters and histomorphologies of erythrocytes of *Cyprinus carpio* and

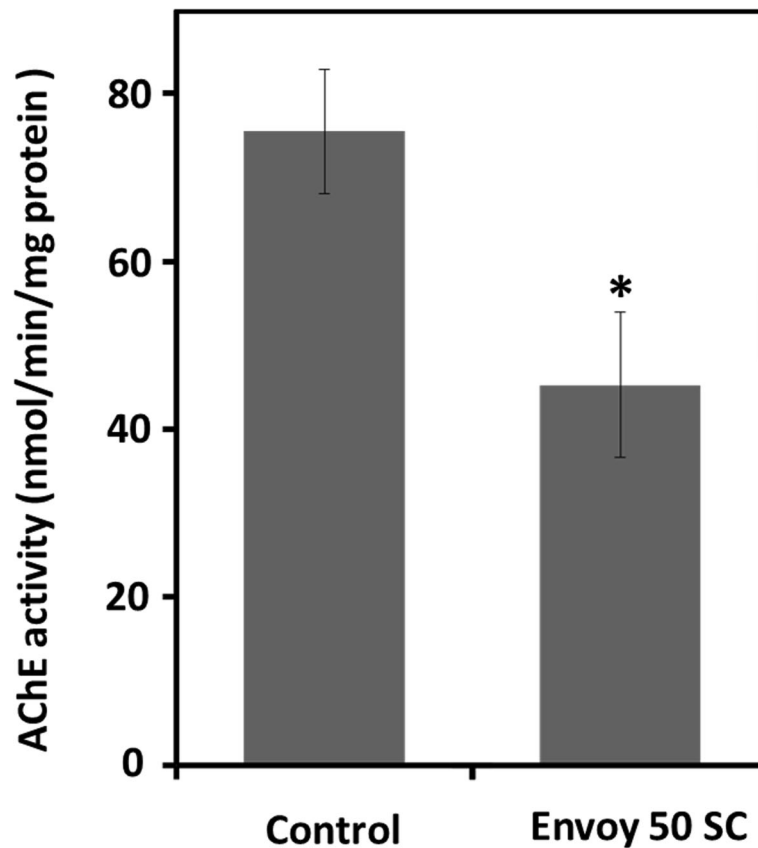


Fig. 9 AChE activity (nmol/min/mg protein) measured in brain of *Heteropneustes fossilis*. Fish exposed to 0.015 ppm Envoy 50 SC were compared with those of the control group. Data were presented as mean \pm SD. * $P < 0.05$

Puntius ticto have been observed due to the exposure of some chlorinated pesticides (Satyanarayan, Bejankiwar, Chaudhari, Kotangale, & Satyanarayan, 2004). Likewise, from another study by Maheswaran, Devapaul, Muralidharan, Velmurugan, and Ignacimuthu (2008), hematocrit quantity and morphology have been reported in altered condition due to the pollutant exposure in *Clarias batrachus*, which also partially support the results of the present study. Moreover, RBC is the vertebrate's central carriage to convey oxygen all through the body and the circulatory system through the gills of fish and proclaims oxygen into the tissues, which is followed by squeezing through the body's capillaries (Wikipedia contributors, Red blood cell, 2019). Therefore, in this study, lower RBC count due to the pesticide exposure might have affected the fish ability to effectively deliver oxygen to the tissues, which resulted in the attempt of increasing consumption rate of oxygen to recuperate the situation. With the increasing concentration of pesticides, the total system may fail and cause the death of *H. fossilis*.

AChE activity is an important biomarker for organophosphates and carbamate pesticides than other contaminants, inhibitions of which indicate the exposure and

effects of these chemicals in fish. In the present study, significant ($P < 0.05$) brain AChE inhibition was observed in pesticide-exposed fish. However, maximum inhibition in AChE activity (up to 51.49%) was reported from *L. rohita* that agrees with Sancho, Ferrando, and Andreu (1998), who described that exposure to 0.04 ppm fenitrothion (an organophosphate) produced a 57% decline in AChE activity, while 51% reduction was recorded for 0.02 ppm. Additionally, from a comparative study on 11 freshwater teleost species by Chuiko (2000), in vitro inhibition of brain and serum AChE by DDVP (an organophosphate pesticide) has been observed. Similar decline of AChE activities responsible for in vitro treatment with organophosphates has also been reported recently (Valbonesi, Brunelli, Mattioli, Rossi, & Fabbri, 2011; Rodrigues et al., 2011; Colovic, Krstic, Uscumlic, & Vasic, 2011). Moreover, Pessoa et al. (2011) showed behavioral changes in *O. niloticus* caused by the enzymatic inhibition during pesticide exposure, whereas reduced ammonium excretion and oxygen consumption was suggested by Barbieri, Augusto, and Ferreira (2011). Reza et al. (2017) also showed significant inhibition of AChE activity in *L. rohita* at 216.7 ± 11.0 , 207.3 ± 5.0 , and

146.7 ± 5.5 nmol/min/mg protein after exposure to Envoy 50 SC, Samcup 20 EC, and Dursban 20 EC, respectively. According to their study, exposure of *B. gonionotus* to Samcup 50 EC and Dursban 20 EC showed significant inhibition ($P < 0.05$), which were recorded as 242.0 ± 6.6 and 221.7 ± 60.3 nmol/min/mg protein, respectively. Furthermore, pesticide-treated *L. rohita* showed higher enzymatic inhibition (51.49%) than *B. gonionotus* (19.60%). The restlessness, hyperactivity with abrupt erratic swimming of *H. fossilis* fries in the present study, might have occurred due to the reduction of the AChE activity, which resulted in the accumulation of acetylcholine at synaptic junctions (Colović, Krstić, Lazarević-Pašti, Bondžić, & Vasić, 2013) and stimulated the peripheral nervous system that caused the modulation of the metabolic activities and more oxygen requirement (Pandey et al., 2009).

Conclusion

This study undoubtedly indicates that the presence of commonly used organophosphate pesticides in freshwater reservoirs could cause deleterious effects on the earlier life stages of a comparatively harder and robust fish, which ensures the threat pesticides might possess to other delicate wild species. Their physiological alterations may potentially decrease their survival rate in the nature. Therefore, measures should be taken to mitigate the possible contamination of the aquatic ecosystem by such toxic chemicals, and to strengthen the current findings, further continuation of research should be made. Additionally, more studies for their potential residual effects are required to be performed for completely understanding their hazardous impacts on aquatic ecosystems, with the requirements of using environmentally safe agricultural pesticides.

Abbreviations

AChE: Acetylcholinesterase; ANOVA: Analysis of variance; DO: Dissolved oxygen; OP: Organophosphate; RBC: Red blood cell

Acknowledgements

The authors are thankful to the authorized dealer of Mymensingh for providing fish for experimental purpose. The authors also thank Bangladesh Agricultural University, Mymensingh and Government of NST fellowship of Bangladesh in supporting and funding the present research.

Authors' contributions

RA has planned the experiment, determined the acetylcholinesterase activities, hematological parameters, and drafted the final article. MAP and HJ have determined histopathologies, collected the fish and helped RA to set the experiment. SFR and AHMMR helped in data collection, analysis, and final drafting of the manuscript. ZH critically supervised and helped in experimental planning with the addition of manuscript drafting. The author(s) read and approved the final manuscript.

Funding

The project was funded by Bangladesh Agricultural University Research System, Mymensingh, Bangladesh under the ORCID no. 0000-0001-7122-5299. There are also no contradictions among the authors concerning any

personal or professional relationships, affiliations, or beliefs regarding the research discussed in this manuscript.

Availability of data and materials

All data are available upon request.

Ethics approval

All animal procedures and treatment in this experiment were used agreeing the welfare recommendations of code of practice for the care and use of animals for scientific purposes of Bangladesh Agricultural University, approved by the Animal Welfare and Experimental Ethics Committee, BAU, Mymensingh-2202 (AWEEC/BAU/2019, 32) in accordance with the national guidelines for care and use of laboratory animals.

Consent for publication

Not applicable

Competing interests

The authors declare that there is no conflict of interest of academic or financial nature with any individual or organization.

Author details

¹Department of Fisheries Biology and Genetics, Faculty of Fisheries, Bangladesh Agricultural University, Mymensingh 2202, Bangladesh. ²Upazilla Fisheries Office, Kasba, Brahmanbaria, Bangladesh. ³School of Biological Science, College of Science and Engineering, Flinders University, Adelaide, Australia.

Received: 3 August 2019 Accepted: 2 July 2020

Published online: 16 July 2020

References

- Adhikari, S., Sarkar, B., Chatterjee, A., Mahapatra, C. T., & Ayyappan, S. (2004). Effects of cypermethrin and carbofuran on certain haematological parameters and prediction of their recovery in a freshwater teleost, *Labeo rohita* (Hamilton). *Ecotoxicology and Environmental Safety*, 58(2), 220–226. <https://doi.org/10.1016/j.ecoenv.2003.12.003>.
- Aktar, M. W., Sengupta, D., & Chowdhury, A. (2009). Impact of pesticides use in agriculture: Their benefits and hazards. *Interdisciplinary Toxicology*, 2(1), 1–12. <https://doi.org/10.2478/v10102-009-0001-7>.
- Al-Asgah, N. A., Abdel-Warith, A. W., Younis, E.-S. M., & Allam, H. Y. (2015). Haematological and biochemical parameters and tissue accumulations of cadmium in *Oreochromis niloticus* exposed to various concentrations of cadmium chloride. *Saudi Journal of Biological Sciences*, 22(5), 543–550. <https://doi.org/10.1016/j.sjbs.2015.01.002>.
- Barbieri, E., Augusto, L., & Ferreira, A. (2011). Effects of the organophosphate pesticide Folidol 600 on the freshwater fish, Nile tilapia (*Oreochromis niloticus*). *Pesticide Biochemistry and Physiology*, 99(3), 209–214. <https://doi.org/10.1016/j.pestbp.2010.09.002>.
- Benli, K. C. A., & Ozkul, A. (2010). Acute toxicity and histopathological effects of sublethal fenitrothion on Nile tilapia, *Oreochromis niloticus*. *Pesticide Biochemistry and Physiology*, 97(1), 32–35. <https://doi.org/10.1016/j.pestbp.2009.12.001>.
- Blahova, J., Modra, H., Sevcikova, M., Marsalek, P., Zelnickova, L., Skorik, M., & Svobodova, Z. (2014). Evaluation of biochemical, haematological, and histopathological responses and recovery ability of common carp (*Cyprinus carpio* L.) after acute exposure to atrazine herbicide. *BioMed Research International*, 2014(4), 980948. <https://doi.org/10.1155/2014/980948>.
- Chandra, S., & Chandra, H. (2013). Role of haematological parameters as an indicator of acute malarial infection in Uttarakhand state of India. *Mediterranean Journal of Hematology and Infectious Diseases*, 5(1), e2013009. <https://doi.org/10.4084/MJHID.2013.009>.
- Chuiiko, G. M. (2000). Comparative study of acetylcholinesterase and butyrylcholinesterase in brain and serum of several freshwater fish: Specific activities and in vitro inhibition by DDVP, an organophosphorus pesticide. *Comparative Biochemistry and Physiology Part C: Pharmacology, Toxicology and Endocrinology*, 127(3), 233–242. [https://doi.org/10.1016/s0742-8413\(00\)00150-x](https://doi.org/10.1016/s0742-8413(00)00150-x).
- Colović, M. B., Krstić, D. Z., Lazarević-Pašti, T. D., Bondžić, A. M., & Vasić, V. M. (2013). Acetylcholinesterase inhibitors: Pharmacology and toxicology. *Current*

- Neuropharmacology*, 11(3), 315–335. <https://doi.org/10.2174/1570159X11311030006>.
- Colovic, M. B., Krstic, D. Z., Uscumlic, G. S., & Vasic, V. M. (2011). Single and simultaneous exposure of acetylcholinesterase to Diazinon, chlorpyrifos and their photodegradation products. *Pesticide Biochemistry and Physiology*, 100(1), 16–22. <https://doi.org/10.1016/j.pestbp.2011.01.010>.
- Deka, S., & Mahanta, R. (2012). A study on the effect of organophosphorus pesticide malathion on hepato-renal and reproductive organs of *Heteropneustes fossilis* (Bloch). *The Science Probe*, 1(1), 1–13. <https://pdfs.semanticscholar.org/61b6/ecb9f9178f8b34acab55b735b50916f5ee94.pdf>.
- Ellman, G. L., Courtney, K. D., Andres, J. R. V., & Featherstone, R. M. (1961). A new and rapid colorimetric determination of acetylcholinesterase activity. *Biochemical Pharmacology*, 7(2), 88–95. [https://doi.org/10.1016/0006-2952\(61\)90145-9](https://doi.org/10.1016/0006-2952(61)90145-9).
- Evans, D. H., & Claiborne, J. B. (2005). *The physiology of fishes*. Boca Raton, Fla, USA: CRC Press.
- Ferenczy, J., Szegletes, T., Balint, T., Abraham, M., & Nemcsok, J. (1997). Characterization of acetylcholinesterase and its molecular forms in organs of five freshwater teleosts. *Fish Physiology and Biochemistry*, 16(6), 515–529. <https://doi.org/10.1023/A:1007701323808>.
- Fischer-Scherl, T., Veesser, A., Hoffmann, R. W., Kuhnhauser, C., Negele, R., & Ewingmann, T. (1991). Morphological effects of acute and chronic atrazine exposure in rainbow trout (*Oncorhynchus mykiss*). *Archives of Environmental Contamination and Toxicology*, 20(4), 454–461. <https://doi.org/10.1007/BF01065833>.
- Gernhofer, M., Pawet, M., Schramm, M., Müller, E., & Triebkorn, R. (2001). Ultrastructural biomarkers as tools to characterize the health status of fish in contaminated streams. *Journal of Aquatic Ecosystem Stress and Recovery*, 8(3–4), 241–260. <https://doi.org/10.1023/A:1012958804442>.
- Gill, H.K., & Garg, H. (2014). Pesticides: Environmental impacts and management strategies. Pesticides – Toxic Aspects, Marcelo L. Larramendy and Sonia Soloneski, IntechOpen. <https://www.intechopen.com/books/pesticides-toxic-aspects/pesticides-environmental-impacts-and-management-strategies>. Accessed 01 July 2019.
- Grue, C. E., Gibert, P. L., & Seeley, M. E. (1997). Neurophysiological and behavioral changes in non-target wildlife exposed to organophosphate and carbamate pesticides: Thermoregulation, food consumption, and reproduction. *American Zoologist*, 37(4), 369–388. <https://doi.org/10.1093/icb/37.4.369>.
- Habig, C., Giulio, D. R., & Donia, A. M. (1988). Comparative properties of channel catfish (*Ictalurus punctatus*) and blue crab (*Callinectes sapidus*) acetylcholinesterases. *Comparative Biochemistry and Physiology Part C: Comparative Pharmacology*, 91(2), 293–300. [https://doi.org/10.1016/0742-8413\(88\)90032-1](https://doi.org/10.1016/0742-8413(88)90032-1).
- Hamilton, P. B., Cowx, I. G., Oleksiak, M. F., Griffiths, A. M., Grahn, M., Stevens, J. R., ... Tyler, C. R. (2016). Population-level consequences for wild fish exposed to sublethal concentrations of chemicals – A critical review. *Fish and Fisheries*, 17(3), 545–566. <https://doi.org/10.1111/faf.12125>.
- Hook, S. E., Gallagher, E. P., & Batley, G. E. (2014). The role of biomarkers in the assessment of aquatic ecosystem health. *Integrated Environmental Assessment and Management*, 10(3), 327–341. <https://doi.org/10.1002/ieam.1530>.
- Hossain, Z., Haldar, G. C., & Mollah, M. F. A. (2000). Acute toxicity of chlorpyrifos, cadusafos and Diazinon to three Indian major carps (*Labeo rohita*, *Catla catla* and *Cirrhinus mrigala*) fingerlings. *Bangladesh Journal of Fisheries Research*, 4(2), 191–198. http://aquaticcommons.org/16464/1/BJFR.2_191.pdf. Accessed 01 July 2019.
- Hossain, Z., Rahman, M.Z., & Mollah, M.F.A. (2001). Effects of two organophosphorus pesticides Diazinon 60 EC and Dimecron 100 SCW on a zooplankton, *Diaptomus*. *Pakistan Journal of Biological Sciences*, 4(11), 1403–1405. <https://docsdrive.com/pdfs/ansinet/pjbs/2001/1403-1405.pdf>. Accessed 01 July 2019.
- Hossain, Z., Rahman, M.Z., & Mollah, M.F.A. (2002). Effect of Dimecron 100 SCW on *Anabas testudineus*, *Channa punctatus* and *Barbodes gonionotus*. *Indian Journal of Fisheries*, 49(4), 405–417. <http://epubs.icar.org.in/ejournal/index.php/IJF/article/view/8213/3229>. Accessed 24 October 2019.
- Hrubeč, T. C., Cardinale, J. L., & Smith, S. A. (2000). Haematology and plasma chemistry reference intervals for cultured tilapia (*Oreochromis hybrid*). *Veterinary Clinical Pathology*, 29(1), 7–12. <https://doi.org/10.1111/j.1939-165X.2000.tb00389.x>.
- Jash, N. B., Chatterjee, S., & Bhattacharya, S. (1982). Role of acetylcholine in the recovery of brain acetylcholinesterase in *Channa punctatus* (Bloch) exposed to Furadan. *Comparative Physiology and Ecology*, 7, 56–58.
- Jha, B.R., & Rayamajhi, A. (2010). *Heteropneustes fossilis* (errata version published in 2018). The IUCN Red List of Threatened Species 2010: e.T166452A135875733. 10.2305/IUCN.UK.2010-4.RLTS.T166452A6212487.en. Accessed 03 July 2019.
- Katagi, T. (2010). Bioconcentration, bioaccumulation, and metabolism of pesticides in aquatic organisms. In D. Whitacre (Ed.), *Reviews of Environmental Contamination and Toxicology. Reviews of Environmental Contamination and Toxicology (Continuation of Residue Reviews)*, vol 204. New York, NY: Springer. https://doi.org/10.1007/978-1-4419-1440-8_1.
- Khan, M. N., Islam, A. K. M. S., & Hossain, M. G. (2003). Marginal analysis of culture of stinging catfish (*Heteropneustes fossilis*, Bloch): Effect of different stocking densities in earthen ponds. *Pakistan Journal of Biological Sciences*, 6(7), 666–670. <https://doi.org/10.3923/pjbs.2003.666.670>.
- Kopecka, J., Rybakowas, A., Barsiene, J., & Pempkowiak, J. (2004). AChE levels in mussels and fish collected off Lithuania and Poland (southern Baltic). *Oceanologica*. 46(3), 405–418. <http://www.iopan.gda.pl/oceanologia/>. Accessed 03 July 2019.
- Kori-Siakpere, O., Ake, J. E. G., & Idoge, E. (2005). Haematological characteristics of the African snakehead, *Parachanna obscura*. *African Journal of Biotechnology*, 4(6), 527–530. <https://doi.org/10.5897/AJB2005.000-3096>.
- Kwong, T.C. (2002). Organophosphate pesticides: Biochemistry and clinical toxicology. *Therapeutic Drug Monitoring*, 24(1), 144–149. <https://www.ncbi.nlm.nih.gov/pubmed/11805735>. Accessed 01 July 2019.
- Lew, S., Lew, M., Biedunkiewicz, A., & Szarek, J. (2013). Impact of pesticide contamination on aquatic microorganism populations in the littoral zone. *Archives of Environmental Contamination and Toxicology*, 64(3), 399–409. <https://doi.org/10.1007/s00244-012-9852-6>.
- Lionetto, M. G., Caricato, R., Calisi, A., Giordano, M. E., & Schettino, T. (2013). Acetylcholinesterase as a biomarker in environmental and occupational medicine: New insights and future perspectives. *BioMed Research International*, 2013, 321213. <https://doi.org/10.1155/2013/321213>.
- Lowry, O.H., Rosebrough, N.J., Farr, A.L., & Randall, R.J. (1951). Protein measurement with the Folin phenol reagent. *Journal of Biological Chemistry*, 193(1), 265–275. <http://www.jbc.org/content/193/1/265.long>. Accessed 01 July 2019.
- Maheswaran, R., Devapaul, A., Muralidharan, S., Velmurugan, B., & Ignacimuthu, S. (2008). Haematological studies of fresh water fish, *Clarias batrachus* (L.) exposed to mercuric chloride. *International Journal of Integrative Biology*, 2(1), 49–54. <http://ijib.classicus.com/trns/2574241571887312.pdf>. Accessed 24 October 2019.
- Marchand, M. J., Van Dyk, J., Pieterse, G. M., Barnhoorn, I. E., & Bornman, M. S. (2009). Histopathological alterations in the liver of the sharp-toothed catfish *Clarias gariepinus* from polluted aquatic systems in South Africa. *Environmental Toxicology*, 24(2), 133–147. <https://doi.org/10.1002/tox.20397>.
- Math, M. V., Kattimani, Y. R., Khadkikar, R. M., Patel, S. M., Shanti, V., & Inamdar, R. S. (2016). Red blood cell count: Brief history and new method. *MGM Journal of Medical Sciences*, 3(3), 116–119. <https://doi.org/10.5005/jp-journals-10036-1104>.
- Mensah, P.K., Palmer, C.G., & Muller, W.J. (2014). Lethal and sublethal effects of pesticides on aquatic organisms: The case of a freshwater shrimp exposure to Roundup®. Pesticides – Toxic Aspects, Marcelo L. Larramendy and Sonia Soloneski, IntechOpen. <https://www.intechopen.com/books/pesticides-toxic-aspects/lethal-and-sublethal-effects-of-pesticides-on-aquatic-organisms-the-case-of-a-freshwater-shrimp-expo>. Accessed 01 July 2019.
- Oropesa, A. L., Cambero, J. P. G., Gómez, L., Roncero, V., & Soler, F. (2009). Effect of long-term exposure to simazine on histopathology, haematological, and biochemical parameters in *Cyprinus carpio*. *Environmental Toxicology*, 24(2), 187–199. <https://doi.org/10.1002/tox.20412>.
- Özkar, A., Akyıl, D., & Konuk, M. (2016). Pesticides, environmental pollution, and health, environmental health risk – Hazardous factors to living species. Marcelo L. Larramendy and Sonia Soloneski, IntechOpen. <https://www.intechopen.com/books/environmental-health-risk-hazardous-factors-to-living-species/pesticides-environmental-pollution-and-health>. Accessed 01 July 2019.
- Pandey, R.K., Singh, R.N., Singh, S., Singh, N.N., & Das, V.K. 2009. Acute toxicity bioassay of dimethoate on freshwater airbreathing catfish, *Heteropneustes fossilis* (Bloch). *Journal of Environmental Biology* 30(3), 437–440. http://www.jeb.co.in/journal_issues/200905_may09/paper_23.pdf. Accessed 01 July 2019.
- Pessoa, P. C., Luchmann, K. H., Ribera, A. B., Verasa, M. M., Correac, J. R. M. B., Nogueira, A. J., & Carvalho, P. S. M. (2011). Cholinesterase inhibition and behavioral toxicity of carbofenuron on *Oreochromis niloticus* early life stages.

- Aquatic Toxicology*, 105(3–4), 312–320. <https://doi.org/10.1016/j.aquatox.2011.06.020>.
- Rahman, M.Z., Hossain, Z., Mollah, M.F.A., & Ahmed, G.U. (2002). Effects of Diazinon 60 EC on *Anabas testudineus*, *Channa punctatus* and *Barbodes gonionotus*. *Naga*, the ICLARM quarterly, 25(2): 8–12. <https://www.researchgate.net/publication/227642224>. Accessed 01 July 2019.
- Rakhi, S. F., Reza, A. H. M. M., Hossen, M. S., & Hossain, Z. (2013). Alterations in histopathological features and brain acetylcholinesterase activity in stinging catfish, *Heteropneustes fossilis* exposed to polluted river water. *International Aquatic Research*, 5, 7. <https://doi.org/10.1186/2008-6970-5-7>.
- Reza, A. H. M. M., Rakhi, S. F., Hossen, M. S., & Hossain, Z. (2017). Organ specific histopathology and brain acetylcholinesterase inhibition in rohu, *Labeo rohita* and silver barb, *Barbonymus gonionotus*: Effects of three widely used organophosphate pesticides. *Turkish Journal of Fisheries and Aquatic Sciences*, 17, 821–832. https://doi.org/10.4194/1303-2712-v17_4_18.
- Ricchetti, S. K., Rosemberg, D. B., Ventura-Lima, J., Monserrat, J. M., Bogo, M. R., & Bonan, C. D. (2011). Acetylcholinesterase activity and antioxidant capacity of zebrafish brain is altered by heavy metal exposure. *Neurotoxicology*, 32(1), 116–122. <https://doi.org/10.1016/j.neuro.2010.11.001>.
- Rodrigues, S. R., Caldeira, C., Castro, B. B., Gonçalves, F., Nunes, B., & Antunes, S. C. (2011). Cholinesterase (ChE) inhibition in pumpkinseed (*Lepomis gibbosus*) as environmental biomarker: ChE characterization and potential neurotoxic effects of xenobiotics. *Pesticide Biochemistry and Physiology*, 99(2), 181–188. <https://doi.org/10.1016/j.pestbp.2010.12.002>.
- Rusyniak, D. E., & Nanagas, K. A. (2004). Organophosphate poisoning. *Seminars in Neurology*, 24(2), 197–204. <https://doi.org/10.1055/s-2004-830907>.
- Saaristo, M., Brodin, T., Balshine, S., Bertram, M. G., Brooks, B. W., Ehlman, S. M., ... Arnold, K. E. (2018). Direct and indirect effects of chemical contaminants on the behaviour, ecology and evolution of wildlife. *Proceedings of the Royal Society B: Biological Science*, 285(1885), 20181297. <https://doi.org/10.1098/rspb.2018.1297>.
- Sánchez-Bayo, F., Goka, K., & Hayasaka, D. (2016). Contamination of the aquatic environment with neonicotinoids and its implication for ecosystems. *Frontiers in Environmental Science*, 4, 71. <https://doi.org/10.3389/fenvs.2016.00071>.
- Sancho, E., Ferrando, M. D., & Andreu, E. (1998). In vivo inhibition of AChE activity in the European eel *Anguilla anguilla* exposed to technical grade fenitrothion. *Comparative Biochemistry and Physiology Part C: Pharmacology, Toxicology and Endocrinology*, 120(3), 389–395. [https://doi.org/10.1016/S0742-8413\(98\)10067-1](https://doi.org/10.1016/S0742-8413(98)10067-1).
- Sandahl, J. F., Baldwin, D. H., Jenkins, J. J., & Scholz, N. L. (2005). Comparative thresholds for acetylcholinesterase inhibition and behavioral impairment in coho salmon exposed to chlorpyrifos. *Environmental Toxicology and Chemistry*, 24(1), 136–145. <https://doi.org/10.1897/04-195R.1>.
- Satyanarayan, S., Bejankiwar, R.S., Chaudhari, P.R., Kotangale, J.P., & Satyanarayan, A. (2004). Impact of some chlorinated pesticides on the haematology of the fish *Cyprinus carpio* and *Puntius ticto*. *Journal of Environmental Sciences*, 16 (4), 631–634. <https://www.ncbi.nlm.nih.gov/pubmed/15495970>. Accessed 01 July 2019.
- Schwaiger, J., Wanke, R., Adam, S., Pawert, M., Honnen, W., & Triebkorn, R. (1997). The use of histopathological indicators to evaluate contaminant-related stress in fish. *Journal of Aquatic Ecosystem Stress and Recovery*, 6(1), 75–86. <https://doi.org/10.1023/A:1008212000208>.
- Sharbidre, A. A., Metkari, V., & Patode, P. (2011). Effect of methyl parathion and chlorpyrifos on certain biomarkers in various tissues of guppy fish, *Poecilia reticulata*. *Pesticide Biochemistry and Physiology*, 101, 132–141. <https://doi.org/10.1016/j.pestbp.2011.09.002>.
- Tabinda, A. B., Khan, M. A., Hany, O., Ayub, M., Hussain, M., Yasar, A., & Khan, M. A. (2003). Rate of oxygen consumption in fingerlings of major carps at different temperatures. *Pakistan Journal of Biological Sciences*, 6, 1535–1539. <https://doi.org/10.3923/pjbs.2003.1535.1539>.
- Thophon, S. M., Kruatrachue, E. S., Upathan, P., Pokethitiyook, S., Sahaphong, S., & Jarikhuan, S. (2003). Histopathological alterations of white seabass, *Lates calcarifer* in acute and subchronic cadmium exposure. *Environmental Pollution*, 121(3), 307–320. [https://doi.org/10.1016/S0269-7491\(02\)00270-1](https://doi.org/10.1016/S0269-7491(02)00270-1).
- Valbonesi, P., Brunelli, F., Mattioli, M., Rossi, T., & Fabbri, E. (2011). Cholinesterase activities and sensitivity to pesticides in different tissues of silver European eel, *Anguilla anguilla*. *Comparative Biochemistry and Physiology - Part C: Toxicology & Pharmacology*, 154(4), 353–359. <https://doi.org/10.1016/j.cbpc.2011.07.003>.
- Varo, I., Serrano, R., Pitarch, E., Amat, F., Lopez, F. J., & Navarro, J. C. (2002). Bioaccumulation of chlorpyrifos through an experimental food chain: Study of protein HSP70 as biomarker of sublethal stress in fish. *Archives of Environmental Contamination and Toxicology*, 42(2), 229–235. <https://doi.org/10.1007/s00244-001-0013-6>.
- Wikipedia contributors. Red blood cell. 2019. In Wikipedia, The Free Encyclopedia. https://en.wikipedia.org/w/index.php?title=Red_blood_cell&oldid=896416362. Accessed 31 June, 2019.
- Yancheva, V., Velcheva, I., Stoyanova, S., & Georgieva, E. (2016). Histological biomarkers in fish as a tool in ecological risk assessment and monitoring programs: A review. *Applied Ecology and Environmental Research*, 14(1), 47–75. https://doi.org/10.15666/aeer/1401_047075.
- Yang, L., Zha, J., Li, W., Li, Z., & Wang, Z. (2010). Atrazine affects kidney and adrenal hormones (AHs) related genes expressions of rare minnow (*Gobiocypris rarus*). *Aquatic Toxicology*, 97(3), 204–211. <https://doi.org/10.1016/j.aquatox.2009.09.005>.
- Zahra, K. (2017). Effects of environmental pollution on fish: A short review. Transylvanian review of systematical and. *Ecological Research*, 19(1), 49–60. <https://doi.org/10.1515/trser-2017-0005>.
- Zodrow, J. M., Stegemanb, J. J., & Tanguay, R. L. (2004). Histological analysis of acute toxicity of 2,3,7,8-tetrachlorodibenzo-p-dioxin (TCDD) in zebra fish. *Aquatic Toxicology*, 66(1), 25–38. <https://doi.org/10.1016/j.aquatox.2003.07.002>.

Publisher's Note

Springer Nature remains neutral with regard to jurisdictional claims in published maps and institutional affiliations.

Submit your manuscript to a SpringerOpen® journal and benefit from:

- Convenient online submission
- Rigorous peer review
- Open access: articles freely available online
- High visibility within the field
- Retaining the copyright to your article

Submit your next manuscript at ► [springeropen.com](https://www.springeropen.com)