



RESEARCH

Open Access



Could cough be an intraoperative indicator for venous air embolism in deep brain stimulation surgeries?: experiences from a large case series

Lin Shi^{1†}, Chao-Cai Zhang^{1†}, Jun-Ju Li^{2†}, Guan-Yu Zhu¹, Ying-Chuan Chen¹ and Jian-Guo Zhang^{1,3*}

Abstract

Background: Deep brain stimulation (DBS) surgery is usually performed with the patients located in a half-sitting position. Therefore, complications associated with such position accompany, such as venous air embolism (VAE), et al. However, because the patients are fully conscious during the surgery, they may have observable manifestations related to the complications that are otherwise inconspicuous in generally anesthetic surgeries. Thus, we designed this study to investigate the intraoperative manifestations of the potentially dangerous complication of VAE in the DBS surgery.

Methods: The medical records of a series of 705 consecutive patients who underwent DBS surgery in our hospital have been retrospectively reviewed. The clinical features, intraoperative manifestations and treatment of these patients were analyzed for evidence of VAE. The correlation between the cough intensity and other clinical features were investigated.

Results: Evidence of VAE were found in 16 patients. Statistical analyses showed that severe cough is associated with greater age ($p = 0.045$), longer coughing time ($p = 0.001$), more intensive tremor ($p = 0.032$), more complaints ($p = 0.036$), greater influences ($p = 0.009$), more treatment ($p = 0.003$) and longer hospitalization ($p = 0.003$).

Conclusions: Intraoperative intense and unremitting cough may be a noticeable indicator of possible VAE. Early recognition and effective management are essential to prevent unfavorable outcomes in such cases.

Keywords: Deep brain stimulation, Venous air embolism, Cough, Clinical features

Background

Deep brain stimulation (DBS), a novel neuromodulation technique, is widely used in the treatment of Parkinson's disease, dystonia and essential tremor, among other conditions [1–4]. Simultaneously, extensive research has been performed to investigate its possible application in other fields [5–10]. In China, over 2,000 patients had received DBS implantation by 2009 [11], and the total number of DBS surgeries has exceeded 1,000 at our center. In general, DBS surgery is relatively safe, with an

overall complication rate of 6.8–28.5 % [12–15]. Common complications include intracranial hemorrhages, seizures and intracranial pneumatoceles [12, 13]. Venous air embolism (VAE) is a less common complication of DBS surgery [16–19]. The presentations of VAE in DBS surgery include tachypnea, cough, chest pain, uncooperativeness, restlessness, agitation, electrocardiographic changes, decreased O₂ saturation (SO₂) and increased end-tidal CO₂ (ETCO₂), and alterations in vital signs (including heart rate [HR], respiration rate [RR] and blood pressure [BP]) [16, 18, 20–24]. An intense cough is considered the earliest and most important VAE indicator in DBS surgery [19, 25]. However, these symptoms are not characteristic, and distinguishing between VAE cough and a spontaneous cough may prove to be difficult. The question of whether cough intensity is related to VAE severity remains unclear.

* Correspondence: zjguo73@126.com

†Equal contributors

¹Department of Neurosurgery, Beijing Tiantan Hospital, Capital Medical University, Beijing, China

³Department of Functional Neurosurgery, Beijing Neurosurgical Institute, Capital Medical University, Tiantan West No.6, Dongcheng Dist., Beijing 100050, China

Full list of author information is available at the end of the article



Because of the differences in patient positioning and detection of VAE, the incidence varies in studies from different centers [17, 19, 24, 26]. We designed this retrospective study to further investigate this potentially dangerous complication in a consecutive series of 705 patients who underwent unilateral or bilateral DBS surgery.

Methods

This retrospective study was approved by the Institutional Review Board of Beijing Tiantan Hospital. The medical records of a series of 705 consecutive patients who underwent unilateral or bilateral DBS surgery at Beijing Tiantan Hospital over a period of 85 months were reviewed. The intraoperative events were analyzed for evidence of VAE during DBS surgery, and patients with evidence of VAE were defined as having coughing periods that began during surgery. Patients with a history of a chronic cough or a cough that presented before surgery were excluded. The clinical features, operative courses, post-operative conditions and treatment of these patients were noted and analyzed. To investigate the possible prognostic effects of a cough, these patients were divided into 3 groups based on the cough intensity. The clinical features of these patients were summarized and statistically analyzed by one-way ANOVA and the chi-square test.

The DBS procedures were standard and are described in previous reports [27, 28]. A stereotactic head frame (Leksell, Elekta, Stockholm, Sweden) was mounted under local anesthesia. A preoperative MRI scan was conducted using a 3.0 T MRI scanner (Signa System, GE Healthcare, Buckinghamshire, UK). After defining the line between the anterior commissure and posterior commissure on MRI images, the target location was determined from the 3D-FLASH T2-weighted MRI images using a combination of indirect and the direct methods. The indirect method was based on the anatomical knowledge that the STN is located 2 mm posterior to the midpoint of the anterior-posterior commissure line (the original point), 4 mm caudal to the original point, and 12 mm lateral to the original point. [29] The direct method used the 3D-FLASH T2-weighted image on which the red nuclei and STN were best displayed, and the target was usually the midpoint of the STN at the level of the anterior border of the red nucleus [30]. Initially, we roughly determined the target within the STN using the indirect method and then adjusted the location slightly using the direct method. Then, the target coordinates relative to the original point were computed automatically by the SurgiPlan System (Elekta, Stockholm, Sweden). MER was performed with the Leadpoint System (Medtronic, MN, US) to verify the target. DBS leads (Model 3389, Medtronic, MN, US) were implanted

along the same trajectory as the microelectrode when satisfactory STN signals were recorded. The effects of STN stimulation were tested using external neurostimulators (Model 37022, Medtronic, MN, US) and a programmer (Model 8840, Medtronic, MN, US). When longer test stimulation was needed, the distal end of the DBS lead was connected with an accessory cable (Model 3389, Medtronic, MN, US) with its stylet handle end left outside the head. After suturing the scalp, the patients were sent back to the ward with stimulators turned off. When temporary stimulation exhibited satisfactory effects, permanent neurostimulators (Activa series, Model 37602 or 37612, Medtronic, MN, US) were implanted. A month later an experienced technician was assigned to modulate the neurostimulators. In approximately a month's time, the neurostimulators were switched on.

Results

In our retrospective study, out of 705 patients, 16 patients (2.3 %) with evidence of VAE and without a chronic cough were found, including 9 males (56.2 %) and 7 females (43.8 %). The mean age of these patients was 67.8 (range 63–75) years. The data related to the 16 patients are shown in Table 1. These patients underwent DBS surgery for Parkinson's disease ($n = 14$, 87.5 %), dystonia ($n = 1$, 6.3 %) or essential tremor ($n = 1$, 6.3 %). The targets of the surgery included subthalamic nucleus ($n = 13$, 81.3 %), globus pallidus interna ($n = 2$, 12.5 %) and ventralis intermedius nucleus ($n = 1$, 6.3 %). The cough occurred in 9 (56.3 %) patients who underwent surgery on the left side and in 7 (43.8 %) patients who underwent surgery on the right side. All the patients were supine and in a semi-sitting position, with a head elevation of 30–45°. The patients were fully conscious with spontaneous breathing during the surgery. Electrocardiography was utilized, and pulse oxygen saturation (SpO₂), ET-CO₂, HR, RR and BP were continuously monitored. Neither transesophageal echocardiography nor transthoracic echocardiography was employed because these tools are invasive or unsuitable for conscious patients undergoing DBS surgery.

In these patients, a cough and other VAE presentations occurred following the drilling of the burr hole ($n = 6$, 37.5 %), after the dural incision ($n = 9$, 56.3 %) or during the microelectrode recording ($n = 1$, 6.3 %). Coughing was noted as the earliest and most conspicuous event in most of these patients and was anteceded by tachypnea in 2 patients (12.5 %). Coughs were divided into the following 3 types according to the description in the anesthesia records: mild and transient cough ($n = 6$, 37.5 %); evident and gradually attenuating cough ($n = 5$, 31.3 %); and intense and unremitting cough ($n = 5$, 31.3 %). Coughing events lasted for 1.5–15 min (mean = 6.0 min). During the coughing period, a tremor occurred in 14 patients (87.5 %), with 8 patients

Table 1 Clinical features of the VAE cases

No.	Age	Cough	Duration	Tremor	Other complaints	Influence	Hospitalized
1	63	++	5.5	-	-	None	7
2	68	+	2	+	+	None	6
3	75	+++	12	++	+	SO	8
4	73	+++	9	+++	+	DH, SS	11
5	67	+	3.5	+	+	None	6
6	63	+	2	+	-	None	7
7	67	++	4	+	-	None	6
8	74	+++	15	++	+	SO	10
9	63	++	8	+	-	SS	6
10	70	+	4	-	-	None	5
11	65	+	1.5	+	+	None	6
12	69	+++	11	+++	+	DH, SS	23
13	62	+	3	+	-	None	7
14	71	++	3	+	+	SS	7
15	66	+++	7	+++	+	SS	8
16	69	++	5.5	++	-	SO	6

Abbreviations: SO slowing the operation, SS surgery suspension, DH difficulty in hemostasis

1. Assessment of the cough during the surgery: +, mild and transient coughing periods during the surgery; ++, evident but gradually attenuating coughing periods during the surgery; +++, intensive and unremitting coughing periods during the surgery

2. Assessment of the tremor intensity during the cough: -, no tremor; +, mild tremor with little influence on the surgical site; ++, evident tremor with moderate shaking of the head, obscuring the surgical site; +++, violent whole-body tremor with gross shaking of the head, making it almost impossible to visualize the surgical site clearly

3. +, having more than one of these symptoms, including tachypnea, chest pain, chest distress and dyspnea; -, no other complaint was reported

having a mild tremor (not influencing the surgery, 50.0 %), 3 patients having an evident tremor (slowing the operation, 6.3 %) and 3 patients having a violent tremor (leading to suspension of the surgery, 6.3 %). Other symptoms included tachypnea, chest pain, chest distress and dyspnea, which occurred in 56.3 % of these patients. Electrocardiographic changes were found in 2 patients (12.5 %), with 1 arrhythmia and 1 premature beat; in 3 patients, electrocardiography could not be conducted because of mechanical issues. Cardiac troponin T, creatine kinase MB and myoglobin were tested in 7 patients (43.8 %), with no positive results. Increased ET_{CO}₂ ($n = 4$, 25.0 %), decreased SpO₂ ($n = 7$, 43.8 %) and changes in vital signs ($n = 9$, 56.3 %, including increases in HR, RR and BP) were noted in the anesthesia reports. In some patients, the results of ET_{CO}₂ and SpO₂ monitoring were not available because of mechanical issues or adventitious causes.

The surgical reports revealed the following effects of the aforementioned VAE presentations on the surgeries: operation delay ($n = 3$, 18.8 %), surgery suspension ($n = 5$, 31.3 %) and difficulty in hemostasis ($n = 2$, 12.5 %). In 8 patients, no influence was noted. Extemporaneous management was conducted in most cases, including calming directives, irrigating the surgical field with saline, rewaxing the bone edge of the burr hole, increasing the flow volume of oxygen, lowering the head elevation, performance of head CT and chest X-ray examinations, administration of

intravenous sedatives in small doses and intensive care unit observation after surgery. No intracranial hemorrhage was found. Chest X-ray examinations revealed increased pulmonary markings and focal edema in 2 patients (Fig. 1). The mean length of hospital stay was 8.1 d (range 5–22). With the exception of 2 patients, all other patients (83.3 %) recovered as expected after routine post-operative treatment.

In 2 patients (Case 4 and Case 12), a major cortical vein that was not clearly manifested under the thickened dura ruptured unexpectedly following the incision of the dura mater. Simultaneously, an initially moderate cough was gradually augmented with a body tremor. Initially, the bleeding was not rapid; however, with increased coughing and a whole-body tremor, the bleeding became violent and difficult to control. In one patient, the bleeding was stopped by packing a large amount of surgical (Surgicel, Ethicon, Johnson & Johnson, New Brunswick, NJ) onto the bleeding region. In the other patient, the bleeding was too rapid to be managed by routine hemostatic methods, most likely because of the increased BP and continuous coughing. Electrical coagulation of the ruptured vein under direct vision was impossible because of the rapid bleeding and violent head shaking. Even with the suction operating at full speed to clear the surgical site, the ruptured vein could not be visualized. The bleeding was finally stopped by risky

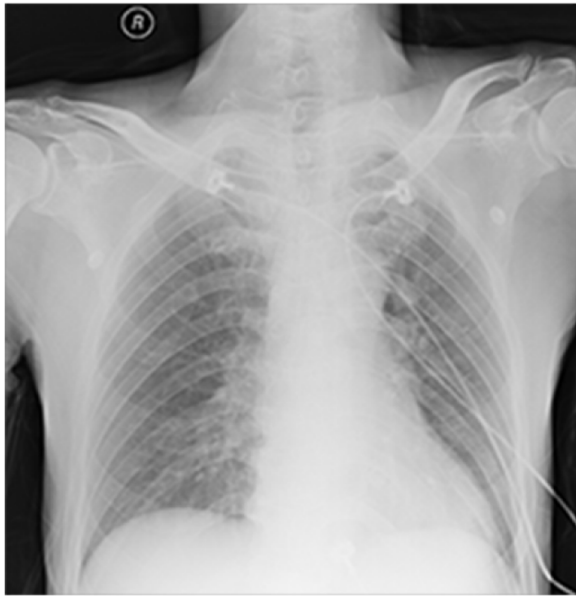


Fig. 1 A typical post-operative chest X-ray obtained from a patient with suspected VAE. The X-ray examination was conducted immediately after the surgery. The radiograph shows increased pulmonary markings and local pulmonary edema

electrical coagulation of the suspected bleeding vessel and its surrounding cortex at relatively high power, which is typically performed outside the dura. The cough gradually stopped within 9–11 min. No further surgical incidents occurred. These 2 patients were observed in the ICU for 24 h. Incomplete hemiplegia and light coma occurred post-operatively in Case 12 because of cerebral infarction under the burr hole (Fig. 2). With hydration therapy and treatment for the brain infarction, the patient was discharged after a 1-month period. Case 4 was discharged with no permanent neurological deficit after a prolonged length of stay (11 d).

To further evaluate the influence of coughing, we separated the patients into 3 groups based on the cough extent during DBS surgery and compared the major clinical

features among the groups (Table 2). As indicated in the table, there was no significant difference in the number of patients, mean age, sex, diagnosis, target of DBS surgery, operation side and occurrence of a cough during surgery among the groups ($p > 0.05$). However, the statistical analyses revealed that members of the “+++” group had greater age ($p = 0.045$), longer coughing time ($p = 0.001$), more intensive tremor ($p = 0.032$), more complaints ($p = 0.036$), greater influence ($p = 0.009$), more treatment ($p = 0.003$) and longer hospitalized ($p = 0.003$).

Discussion

VAE is a potentially fatal complication of neurosurgeries performed with the patients in a sitting position with the head elevated. In previous studies, it was expected that when the head is more than 5 cm higher than the heart, air could enter the venous system through an opening in a vessel [17, 18, 31]. The air in the vessel could be transported by the circulation and form emboli where the blood flow is slow, leading to complicated physiological alterations and fluctuations in SO_2 , $ETCO_2$, BP, HR, RR and other vital signs. In DBS surgery, however, patients who are completely conscious have different presentations, including coughing, tachypnea, chest pain and dyspnea. These presentations are not characteristic, and they typically occur prior to changes in the monitored indices. Thus, early identification and treatment of VAE are possible if coughing, tachypnea, chest pain and dyspnea receive appropriate attention. An uncontrollable cough following burr hole placement and dural incision is considered a strong indicator of VAE [19, 25]. Additionally, although a short episode of mild coughing could be non-specific, the combination of a mild cough and changes in the vital signs, including $ETCO_2$, SpO_2 , HR, RR and BP, is highly suggestive of VAE [16, 17, 26, 32].

Many clinicians are not aware of the association of VAE with coughing. Conscious patients might randomly cough during surgery; however, this type of cough is typically mild and transient, except in patients with a history of a chronic cough. VAE cough occurs shortly

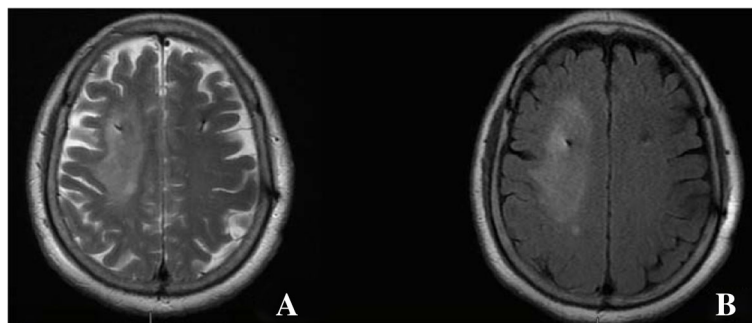


Fig. 2 Post-operative MRI images for Case 12 showing cerebral infarction under the burr hole around the right DBS lead. **a** T2-weighted imaging. **b** Fluid-attenuated inversion recovery imaging

Table 2 Comparison of clinical features among groups divided by cough extent

	ALL/Mean	+ ^a	++ ^a	+++ ^a	p value
Number	16	6	5	5	>0.5
Age	67.8	65.8	66.6	71.4	<0.05
Sex					>0.5
Male	9	3	3	3	
Female	7	3	2	2	
Diagnosis					>0.5
Parkinson's disease	14	5	4	5	
Dystonia	1	1	0	0	
Essential tremor	1	0	1	0	
Side					>0.1
Left	9	4	1	4	
Right	7	2	4	1	
Cough beginning					>0.1
BH	6	3	2	1	
DR	9	2	3	4	
MR	1	1	0	0	
Duration	6.0	2.7	5.2	10.8	<0.01
Tremor ^b					<0.05
-	2	1	1	0	
+	8	5	3	0	
++	3	0	1	2	
+++	3	0	0	3	
Other complaints					<0.05
-	7	3	4	0	
+	9	3	1	5	
Influence					<0.01
None	8	6	2	0	
Little influence*	6	0	3	3	
Great influence*	2	0	0	2	
Treatment ^c					<0.01
≤3	12	6	5	1	
>3	4	0	0	4	
Hospitalized	8.1	6.2	6.4	12.0	<0.01

Abbreviations: BH cough began with the burr hole placement, DR cough began with the dural incision, MR cough began with the microelectrode recording, *, Little influence on the surgery, leading to slowing of some operations; Great influence on the surgery, sometimes resulting in difficulty in hemostasis, surgery suspension and ICU observation

^aGroups were established based on the cough extent during DBS surgery: see Table 1

^bAssessment of the tremor intensity during the cough: see Table 1

^cTreatment of the coughing period during and after the surgery: ≤3, treatment of less than 3 procedures; >3, treatment of more than 3 procedures

after the placement of the burr hole or dural incision [19], indicating the correlation between a cough and this type of surgery. Neurosurgeons should be aware of this

relationship because it is helpful in VAE identification. Typically, a cough attenuates spontaneously. However, it could gradually worsen and become intense and unremitting. The action of coughing is complex and requires cooperation between the chest and abdominal muscles. Thus, when the patient has a severe coughing event, the chest and abdominal muscles contract intensively, resulting in enhancement of body tremor and head shaking, which would jeopardize the surgery. In our study, 14 patients exhibited a tremor, with 6 exhibiting a moderate or intense tremor that would significantly disturb the surgery and lead to prolongation or suspension of surgery. In the cases with complications in our study, the bleeding was not rapid initially; it was aggravated by increased coughing and tremor, which led to marked difficulty in achieving hemostasis. The bleeding was stopped by electrical coagulation of the vessel, which was associated with risks, and the procedure resulted in a post-operative cerebral infarction. If the surgical field was not blurred by marked head shaking, we might have been able to stop the bleeding with a less damaging method.

The incidence, clinical features, detection and treatment of VAE have been reported in previous studies. Detection of VAE is largely dependent on the clinical presentations during DBS surgery. We selected patients with a continuous cough or a mild cough plus other VAE presentations and patients without a chronic cough. Our results showed that the incidence of VAE is 2.3 %, which is nearly equivalent to that reported in previous studies [9, 17]. Considering that there were asymptomatic VAE cases and unidentified VAE cases, the assumed VAE incidence is likely to be an underestimation of the true incidence. We further analyzed the relationship between the cough intensity and the clinical features of the patients with a cough. We found that a severe cough is associated with greater age, a longer coughing time, more intensive tremor, more complaints, greater influence, more treatment and a longer hospitalized, suggesting that the cough intensity could be used to evaluate the extent of VAE. This finding indicated that an intense and unremitting cough during DBS surgery is highly suggestive of severe VAE, which merits attention particularly in elderly patients, because this type of cough is typically more complicated with a more unfavorable prognosis. In these cases, neurosurgeons should immediately stop the operation and take measures to prevent the entrance of additional air, including irrigating the surgical field with saline, rewaxing the bone edge of the burr hole, lowering the head level to reduce the pressure gradient toward the vein, increasing the oxygen supply, administering sedatives in small doses and asking the patients to relax. In this study, after varying durations of coughing, all the patients gradually stopped coughing, indicating that early recognition and prompt

management of VAE are essential to prevent unfavorable results.

Our study is limited in that the diagnosis of VAE relied largely on the description in the anesthesia and surgical records. However, many neurosurgeons and anesthesiologists have little experience with VAE and cannot identify VAE presentations in conscious patients. Additionally, many VAE patients do not manifest typical symptoms and might simply complain of discomfort that could go unnoticed by the surgical team. Due to these factors, the accuracy of an investigation based on anesthesia and surgical reports could be diminished. An additional limitation of our study is that more accurate detection methods, such as transesophageal echocardiography, transthoracic echocardiography and pulmonary artery pressure, were not employed at our center. The diagnosis of VAE in the operating room is generally based on clinical experiences, and invasive methods are not suitable because they cannot be utilized with conscious patients. ETCO₂ might be effective, however, ETCO₂ monitoring using a nasal cannula is less accurate and technically unstable [33, 34]. A severe cough or a combination of a cough plus other complaints is likely to indicate the presence of VAE, and such symptoms have been used as VAE criteria in other published studies [17, 19, 26].

Conclusions

To our knowledge, this is the first large series case study on the incidence and influence of VAE during DBS surgery in China. It is also the first study to investigate the significance of the severity of cough in predicting the outcome of VAE. Our results showed that neurosurgeons should be familiar with the features of VAE cough in DBS surgery. When coughing occurs, neurosurgeons should promptly discriminate between VAE cough and a spontaneous cough. Our data suggested that neurosurgeons should suspend surgery and take measures to prevent the aggravation of VAE in cases in which a cough coexists with an evident body tremor.

Acknowledgements

Not applicable.

Funding

This study was supported by the National Natural Science Funds (China), Grant No. 81171217. The funders had no role in the study design, data collection and analysis, decision to publish, or preparation of the manuscript.

Availability of data and material

All data generated or analysed during this study are included in this published article [and its supplementary information files].

Authors' contributions

Conception and design: J-GZ, LS. Acquisition of data: C-CZ, G-YZ, Y-CC. Analysis and interpretation of data: LS, J-JL. Drafting the article: LS, G-YZ, Y-CC. Critically revising the article: J-GZ. Reviewed the submitted version of the manuscript: J-GZ, LS, J-JL. Performed the statistical analysis: LS, C-CZ. Study supervision: J-GZ. All authors read and approved the final manuscript.

Competing interests

The authors declare that they have no competing interests.

Consent for publication

Not applicable.

Ethics approval and consent to participate

This retrospective study was approved by the Institutional Review Board of Beijing Tiantan Hospital.

Author details

¹Department of Neurosurgery, Beijing Tiantan Hospital, Capital Medical University, Beijing, China. ²Department of Neurosurgery, People's Hospital of Hainan Province, Haikou, Hainan, China. ³Department of Functional Neurosurgery, Beijing Neurosurgical Institute, Capital Medical University, Tiantan West No.6, Dongcheng Dist., Beijing 100050, China.

Received: 4 April 2016 Accepted: 23 August 2016

Published online: 18 September 2016

References

- Larson PS. Deep brain stimulation for movement disorders[J]. *Neurotherapeutics*. 2014;11(3):465–74.
- Munhoz RP, Cerasa A, Okun MS. Surgical treatment of dyskinesia in Parkinson's disease[J]. *Front Neurol*. 2014;5:65.
- Starr PA. Deep brain stimulation for other tremors, myoclonus, and chorea[J]. *Handb Clin Neurol*. 2013;116:209–15.
- Akram H, Miller S, Lagrata S, et al. Ventral tegmental area deep brain stimulation for refractory chronic cluster headache[J]. *Neurology*. 2016;86(18):1676–82.
- Howland RH. Update on deep brain stimulation[J]. *J Psychosoc Nurs Ment Health Serv*. 2014;52(4):23–6.
- Sankar T, Lipsman N, Lozano AM. Deep brain stimulation for disorders of memory and cognition[J]. *Neurotherapeutics*. 2014;11(3):527–34.
- Jaseja H. Deep Brain Stimulation in Intractable Epilepsy: Role of Pulse Width in Neuromodulation[J]. *Clin EEG Neurosci*. 2015;46(3):268–9.
- Salma A, Al-Otaibi F. Deep brain stimulation for obesity[J]. *J Neurosurg*. 2014;120(3):783–4.
- Bartsch C, Kuhn J. Deep brain stimulation for addiction, anorexia and compulsions. Rationale, clinical results and ethical implications [J]. *Nervenarzt*. 2014;85(2):162–8.
- Hariz M, Blomstedt P, Zrinzo L. Future of brain stimulation: new targets, new indications, new technology[J]. *Mov Disord*. 2013;28(13):1784–92.
- Hu WH, Zhang K, Meng FG, et al. Deep brain stimulation in movement and future[J]. *Neuromodulation*. 2012;15(3):251–9. 259.
- Beric A, Kelly PJ, Rezaei A, et al. Complications of deep brain stimulation surgery[J]. *Stereotact Funct Neurosurg*. 2001;77(1–4):73–8.
- Hardesty DE, Sackeim HA. Deep brain stimulation in movement and psychiatric disorders[J]. *Biol Psychiatry*. 2007;61(7):831–5.
- Lyons KE, Koller WC, Wilkinson SB, et al. Long term safety and efficacy of unilateral deep brain stimulation of the thalamus for parkinsonian tremor[J]. *J Neurol Neurosurg Psychiatry*. 2001;71(5):682–4.
- Voges J, Hilker R, Botzel K, et al. Thirty days complication rate following surgery performed for deep-brain-stimulation[J]. *Mov Disord*. 2007;22(10):1486–9.
- Moitra V, Permut TA, Penn RM, et al. Venous air embolism in an awake patient undergoing placement of deep brain stimulators[J]. *J Neurosurg Anesthesiol*. 2004;16(4):321–2.
- Hooper AK, Okun MS, Foote KD, et al. Venous air embolism in deep brain stimulation[J]. *Stereotact Funct Neurosurg*. 2009;87(1):25–30.
- Kumar R, Goyal V, Chauhan RS. Venous air embolism during microelectrode recording in deep brain stimulation surgery in an awake supine patient[J]. *Br J Neurosurg*. 2009;23(4):446–8.
- Chang EF, Cheng JS, Richardson RM, et al. Incidence and management of venous air embolisms during awake deep brain stimulation surgery in a large clinical series[J]. *Stereotact Funct Neurosurg*. 2011;89(2):76–82.
- Orebaugh SL. Venous air embolism: clinical and experimental considerations[J]. *Crit Care Med*. 1992;20(8):1169–77.
- Kimura BJ, Chaux GE, Maisel AS. Delayed air embolism simulating pulmonary thromboembolism in the intensive care unit: role of echocardiography[J]. *Crit Care Med*. 1994;22(11):1884–6.
- Wasnick JD, Vassallo SA, Hoffman WJ, et al. Venous air embolism and cervical microdissectomy[J]. *Anesth Analg*. 1995;81(6):1287–8.

23. Palmon SC, Moore LE, Lundberg J, et al. Venous air embolism: a review[J]. *J Clin Anesth*. 1997;9(3):251–7.
24. Deogaonkar A, Avitsian R, Henderson JM, et al. Venous air embolism during deep brain stimulation surgery in an awake supine patient[J]. *Stereotact Funct Neurosurg*. 2005;83(1):32–5.
25. Suarez S, Ornaque I, Fabregas N, et al. Venous air embolism during Parkinson surgery in patients with spontaneous ventilation[J]. *Anesth Analg*. 1999;88(4):793–4.
26. Leslie K, Hui R, Kaye AH. Venous air embolism and the sitting position: a case series[J]. *J Clin Neurosci*. 2006;13(4):419–22.
27. Rezai AR, Kopell BH, Gross RE, et al. Deep brain stimulation for Parkinson's disease: surgical issues[J]. *Mov Disord*. 2006;21 Suppl 14:S197–218.
28. Tarazi FI, Sahli ZT, Wolny M, et al. Emerging therapies for Parkinson's disease: from bench to bedside[J]. *Pharmacol Ther*. 2014;144(2):123–33.
29. Toda H, Sawamoto N, Hanakawa T, et al. A novel composite targeting method using high-field magnetic resonance imaging for subthalamic nucleus deep brain stimulation[J]. *J Neurosurg*. 2009;111(4):737–45.
30. Taoka T, Hirabayashi H, Nakagawa H, et al. "Sukeroku sign" and "dent internal-capsule sign"—identification guide for targeting the subthalamic nucleus for placement of deep brain stimulation electrodes[J]. *Neuroradiology*. 2009;51(1):11–6.
31. Swartz MA, Munz M, Stern MB. Respiratory failure following stereotactic neurosurgery in a 53-year-old woman[J]. *Chest*. 1997;111(4):1112–4.
32. Nazzaro JM, Lyons KE, Honea RA, et al. Head positioning and risk of pneumocephalus, air embolism, and hemorrhage during subthalamic deep brain stimulation surgery[J]. *Acta Neurochir (Wien)*. 2010;152(12):2047–52.
33. Dion JM, McKee C, Tobias JD, et al. Carbon dioxide monitoring during laparoscopic-assisted bariatric surgery in severely obese patients: transcutaneous versus end-tidal techniques[J]. *J Clin Monit Comput*. 2015;29(1):183–6.
34. Glenski JA, Cucchiara RF. Transcutaneous O₂ and CO₂ monitoring of neurosurgical patients: detection of air embolism[J]. *Anesthesiology*. 1986;64(5):546–50.

Submit your next manuscript to BioMed Central and we will help you at every step:

- We accept pre-submission inquiries
- Our selector tool helps you to find the most relevant journal
- We provide round the clock customer support
- Convenient online submission
- Thorough peer review
- Inclusion in PubMed and all major indexing services
- Maximum visibility for your research

Submit your manuscript at
www.biomedcentral.com/submit

