Fujita et al. Maxillofacial Plastic and Reconstructive Surgery (2019) 41:60
https://doi.org/10.1186/s40902-019-0243-z

Maxillofacial Plastic and Reconstructive Surgery

CASE REPORT Open Access

A case report of a long-term abandoned torn lingual nerve injury repaired by collagen nerve graft induced by lower third molar extraction

Shigeyuki Fujita*, Naoki Mizobata, Takashi Nakanishi and Itaru Tojyo

Abstract

Background: The lingual nerve plays an important role in multiple functions, including gustatory sensation and contact sensitivity and thermosensitivity. Misdiagnosed conservative treatments for serious lingual nerve (LN) injuries can induce the patient to serious mental disability. After continuous observation and critical diagnosis of the injury, in cases involving significant disruption of lingual nerve function, microneurosurgical reconstruction of the nerve is recommended. Direct anastomosis of the torn nerve ends without tension is the recommended approach. However, in cases that present significant gaps between the injured nerve ends, nerve grafts or conduits (tubes of various materials) are employed. Recently, various reconstruction materials for peripheral nerves were commercially offered especially in the USA, but the best method and material is still unclear in the world. There currently exists no conventional protocol for managing LN neurosensory deficiency in regard to optimal methods and the timing for surgical repair. In Japan, the allograft collagen nerve for peripheral nerves reconstruction was permitted in 2017, and we tried to use this allograft nerve and got a recommendable result.

Case presentation: This report is a long-term abandoned torn LN reconstructed with allograft nerve induced by the lower third molar extraction.

Conclusions: In early sick period, with the exact diagnosis, the LN disturbance should be managed. In a serious condition, the reconstruction with allograft nerve is one of the recommendable methods.

Keywords: Lingual nerve, Iatrogenic injury, Mandibular third molar extraction, Allograft collagen nerve

Background

Extraction of the mandibular third molars is one of the most popular procedures in oral and maxillofacial surgery. As a complication of tooth extraction, injuries of the lingual nerve (LN) may cause grave lingual sensory and taste disorders. The incidence is very rare; the paresthesia of patients is severe.

Misdiagnosed conservative treatments for serious LN injuries can induce the patient to serious mental disability. In this case, the patient had depended much upon psychotropic medicine for more than 3 years without a critical diagnosis for the disturbed LN. There currently exists no conventional protocol for managing LN neurosensory deficiency in regard to optimal methods and the timing for surgical repair. Recently, various reconstruction materials for peripheral nerves were commercially offered especially in the USA, but the best method and material is still unclear in the world. The Ministry of Health, Labor and Welfare of Japan permitted to use the allograft collagen nerve for peripheral nerve reconstruction in 2017; we tried to use this allograft nerve and got a recommendable result. The details of patients with iatrogenic LN disorders abandoned for 17 years which underwent microsurgical repair are explained.

* Correspondence: fujt@wakayama-med.ac.jp
Department of Oral and Maxillofacial Surgery, Wakayama Medical University, 811-1 Kimiidera, Wakayama, Wakayama Prefecture 641-8509, Japan

Case presentation

Present history

Two years before, a 59-year-old Japanese woman was referred to our department because of a mental anxiety and intense pain in the left tongue after the extraction of the right mandibular third molar 17 years ago. To manage such a serious perception abnormality, she had received stellate ganglion block (SGB) ten times and medical treatment in various psychosomatic medicine and psychiatry and received various medication of psychotropic drugs for more than 3 years. Without any effectiveness, she suddenly had dropped in panic disorder and depression many times.

On her first visit to our Department of Oral and Maxillofacial Surgery, Wakayama Medical University, we checked the details for the tongue perception with various medical examination methods for the first time.

Our neurosensory assessments included the following.

Subjective assessment

The subjective assessment done was the rating of the subjective sensation (visual analog scale) of the affected area, which was the most seriously bad limited right point.

Objective assessment

1) Brush stroke directional sensation with camel hair brush (brush); horizontal, vertical, and rotational stimulating movement were applied (0 means recognized not at all, 1 means recognized only one direction, 2 means recognized two directions, and 3 means recognized all movements): the left anterior region of her torn tongue revealed 3 but the posterior region indicated 0.
2) Pinprick test: sharp touch reaction with needle, which was indicated in poor reaction.
3) Static two-point discrimination (2PD): the left anterior region reacted in 8 mm but the left posterior region reacted in 15 mm.
4) Pressure pain threshold: the Semmens-Weinstein monofilament (SWM), composed of 20 different diameter monofilaments: 1 was assigned to the smallest diameter and 20 was the largest diameter monofilament. With each instrument, the anterior region of her torn tongue reacted with 5 and the posterior region reacted with 8.
5) Thermal discrimination (thermal): hot and cold sensation; hot water 42 °C; cold sensation, ice 0 °C, pin prick. Both her thermal reactions were positive.
6) Tinel's reaction on the torn lingual nerve: against this reaction, she received a violent sharp stabbing pain along the left side of her disturbed tongue.
7) Gustatory sensation assessed with localized testing discs (Sanwa Kagaku Kenkyusho, Japan): salty, sodium chloride 1 mol/l; sweet, sucrose 1 mol/l; sour, acetic acid 0.4 mol/l; bitter, quinine 0.1 mol/l, which were absent for all reagents on the injured side of her tongue. All the abovementioned inspections were performed at pre-operation and at 6 months after the microsurgery retrospectively. The outcome was analyzed with Sunderland grade and by the Medical Research Council Scale (MRCS). Summarizing such inspections of careful tests, we diagnosed this case as an old serious perception abnormality in the left LN. The detailed data is presented in Table 1.

After taking informed consent with patient and family, we decided to enforce the lingual nerve reconstruction with allograft nerve microsurgically.

Surgical procedure

Microsurgical treatment of LN injury was performed under general anesthesia. The LN was exposed through an intraoral mucosal incision. A large granuloma of LN adjacent to extracted cavity of third molar teeth was revealed. The granuloma and peripheral neuroma surrounding the torn LN about 14 mm length were removed completely (Fig. 1). Between each end of lingual nerves, allograft nerve

Table 1 Preoperative data of visual analog scale and another various assessments

Visual Analog Scale (VAS)

no pain — worst pain

Preoperation	Brush-Stroke Directional Discrimination	Two-Point Discrimination anterior / posterior	SWM Test anterior / posterior	Thermal Discrimination (Hot/Cold)	Tinel's Reaction	Gustatory sensation	Sunderland grade	MRCS
	0	8 / 15	5 / 8	weak / faintly allodynia	+	–	IV	S2 +

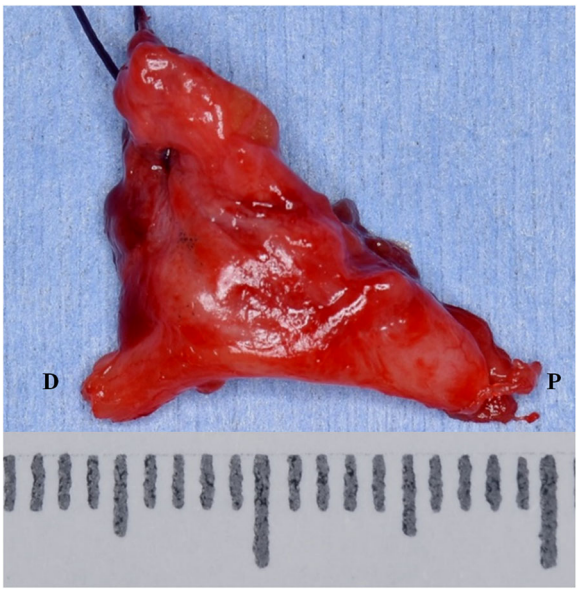

Fig. 1 The granuloma and peripheral neuroma. The removed torn LN and scar tissue was about 14mm length

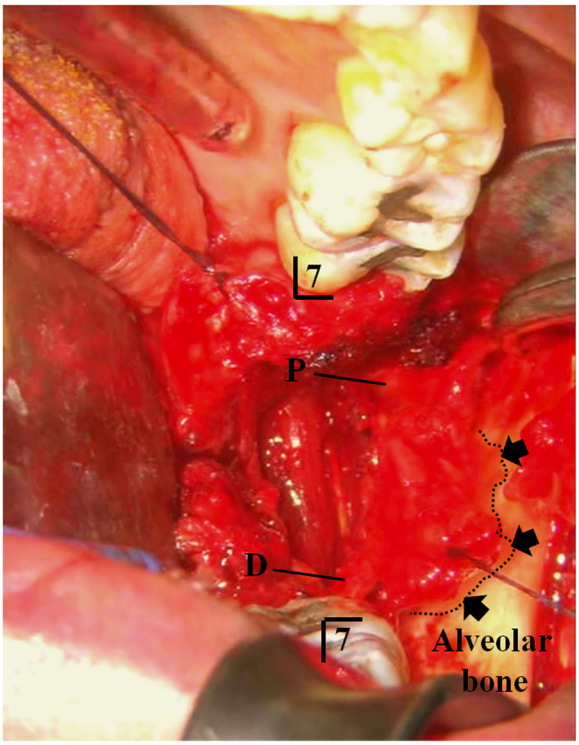

Fig. 2 LN injury site and a large granuloma of LN. Operative findings; the torn LN and scar tissue are identified in the socket of wisdom tooth (arrow). P: Proximal end LN, D: Distal end LN

(RENERVE®) about 18 mm length was inserted and sutured with 8-0 nylon in the microsurgical field (Figs. 2 and 3).

At 6 months and 1 year after the operation, the patient showed an amazingly improved sensory recovery reaction. The data of SWM test, 2PD, Tinel's reaction, and gustatory sensations improved remarkably (Table 2). It is incredible 1 year later of the microneurosurgical operation; she was free from psychotropic drugs except for a sleep inducer and regained a sound healthy daily life.

Discussion

The main cause of LN injury is inadequate exodontia. Therefore, clinicians have to learn adequate surgical technique of the third molar and must understand the risk factors associated with injury to the LNs. The torn LN injury should recover as soon as possible with the best methods.

Slight peripheral nerve injury may be healed spontaneously without any surgical management, for example, in the phase of neurapraxia on Seddon analysis. As a common sense, in the early phase of suspicious spontaneous healing, critical examination like a clinical neurosensory testing (CNT) should be performed as soon as possible [1]. Currently, the conventional protocol for managing LN neurosensory deficiency in regard to optimal methods and the timing for surgical repair is not recognized. In the case of completely damaged case, microsurgical reconstruction should be utilized. Generally, grafting is unadvisable for LN repair because the nerve path is tortuous enough to mobilize without tension [2]. The best functional nerve recovery may occur after direct apposition [3]. When a tensionless direct suturing is not possible, nerve grafting should be considered [4, 5]. Recently, peripheral nerve defect is intended to reconstruct with allograft nerve collagen about substitutes for nerve autograft, because nerve grafts can cause sensory defects in the donor site [6]. There are various types of nerve allografts, for example, Gore-Tex and absorbable allograft tubes [7, 8]. In our case, we utilized the allograft nerve RENERVE®. Previously, meaningful animal experiment and clinical research were done clearly as follows.

Okamoto et al. studied a potential of RENERVE®. With 12 adult female beagle dogs weighting 10–12 kg, the peroneal nerve was cut to make a 30-mm defect. The nerve defect was bridged by RENERVE®. Comprehensive functional, electrophysiological, morphometrical, and histological analyses were performed for 1 year after the operation. The wet weight of the tibialis anterior muscles was only 32.4% of the healthy side at 24 weeks, which recovered to 77.4% 52 weeks after denervation. Electrophysiological evaluation of the tibialis anterior muscle belly showed a polyphasic wave 52 weeks after the implantation, which was almost half amplitude compared with that of the control. The results from this study showed the detailed process of morphological, electrophysiological, and functional recovery of the

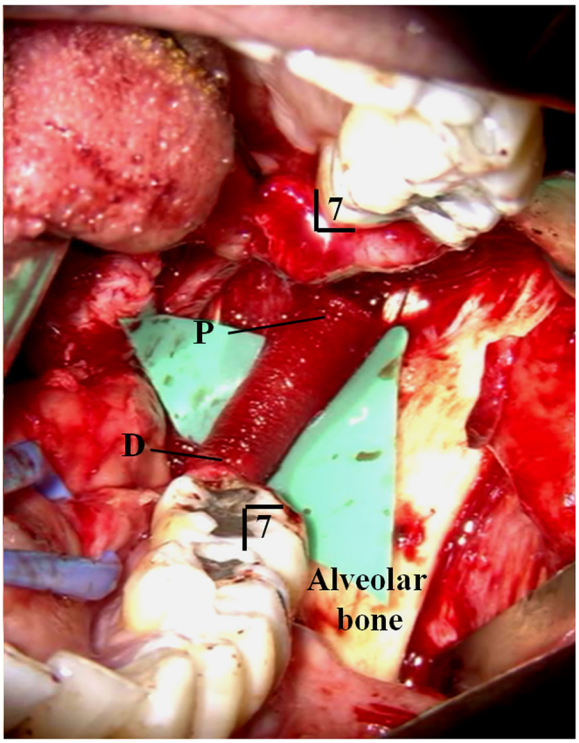

Fig. 3 Sutured LN through allograft nerve (RENERVE®). Operative findings; Between each end of rest LN, allograft nerve (RENERVE®) about 18mm length was inserted and sutured with 8-0 nylon in the microsurgical field

regenerated nerve, which would provide a scientific background for this novel therapy [9].

Saeki et al. made a clinical project to clarify the safety and efficacy of using RENERVE® in the treatment for nerve defects in humans. They conducted a multicenter, controlled, open-label study to compare the safety and efficacy of RENERVE® with those of the autologous nerve grafts. They included patients with sensory nerve defect of ≤ 30 mm, at the level of the wrist or a more distal location. They compared the sensory recovery using static two-point discrimination and adverse events between RENERVE® and autologous nerve grafting. As the result from these studies, the RENERVE® group included 49 patients, with a nerve defect of 12.6 mm. The autologous nerve graft group included 38 patients and nerve defect of 18.7 mm. The rate of recovery of sensory function at 12 months was 75% (36/49) for the RENERVE® group and 73.7% (28/38) in the autologous nerve group. No serious adverse events directly associated with the use of the RENERVE® were identified [10].

Time to repair played an important role in the overall surgical result, although the exact timing is still unclear. The patients with LN repair within 90 days of injury are said to have FSR within 1 year after repair in 93% of the cases [11]. Pogrel reported that microsurgical repair within 10 weeks of injury showed better results for FSR of the LN [12–14]. All the abovementioned opinions are in contrast with Robinson et al. Robinson et al. achieved a significant improvement in a number of sensory function categories including gustatory and functional results; however, they saw no correlation between time to repair and procedure success [15]. Minimally, we can agree with the opinion of Robinson et al. No consensus exists regarding the optimal methods and timing for disturbed lingual nerve repair. Our case had 17 years interval between the third molar teeth extraction and allograft collagen reconstruction. In spite of the extremely long span, we could get a precious result; There was recovery on gustatory sensation, 2PD, and SWT in the objective assessment, but unfortunately, in the subjective assessment, she is still angry with the first countermeasure of the dentist (Tables 1 and 2). Moreover, the important facts are the patient could be free from the heavy psychotropic drugs, which she continued to take in more than 7 years. The quality of her life was drastically refined after the operation (Fig. 4). the vein

Table 2 Postoperative data of visual analog scale and another various assessments

Visual Analog Scale (VAS)

no pain — worst pain

VAS(Subjective assessment) are the most right point in her postoperative data after 6months and 1year from the surgery.

After the surgery	Brush-Stroke Directional Discrimination	Two-Point Discrimination anterior / posterior	SWM Test anterior / posterior	Thermal Discrimination (Hot/Cold)	Tinel's Reaction	Gustatory sensation	Sunderland grade	MRCS
6 months	3	5 / 5	2 / 2	weak / faintly	—	bitter	I	S4
1 year	3	5 / 5	2 / 2	clear / clear	—	salt,sweet sour,bitter	I	S4

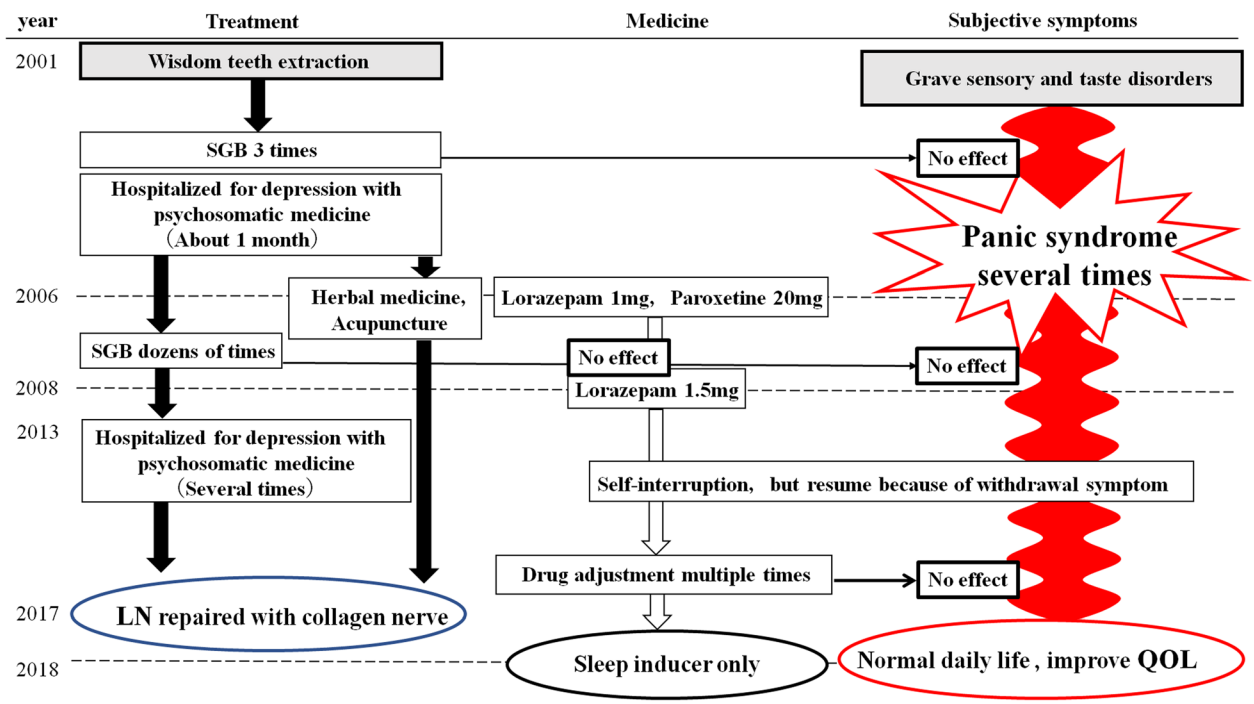

Fig. 4 Prognosis. The patient obliged to take heavy psychotropic drugs for a long time before LN reconstruction. After the operation, he could be free from the heavy psychotropic drugs. Quality of her life was drastically refined after this operation

graft cuff method and the allograft collagen nerve (RENERVE®).

Conclusion

In the early sick period, with the exact diagnosis like CNT, the LN disturbance should be managed. In a serious condition, the reconstruction with allograft nerve (RENERVE®) may be one of the recommendable methods.

Abbreviations

2PD: Two-point discrimination; CNT: Clinical neurosensory testing; LN: Lingual nerve; MRCS: Medical Research Council Scale; SGB: Stellate ganglion block; SWM: Semmens-Weinstein monofilament

Acknowledgements

None.

Authors' contributions

All authors read and approved the final manuscript. SF wrote the manuscript. TN and IT prepared the retrospective data. NM edited the diagram.

Funding

No funding was received.

Availability of data and materials

Not applicable.

Ethics approval and consent to participate

This study was performed in accordance with the Declaration of Helsinki for medical protocols. General consent was given by the patients.
The patients of this case agreed with providing information and the publication of papers.

Consent for publication

All participants of the paper agreed with providing information and the publication of papers.

Competing interests

The authors declare that they have no competing interests.

Received: 2 October 2019 Accepted: 27 November 2019
Published online: 23 December 2019

References

1. Miloro M, Ghali GE, Larsen PE, Waite P (2004) Peterson's principles of oral and maxillofacial surgery, 2nd edn. BC Decker Inc, Ontario, p p825
2. Bagheri SC, Meyer RA, Khan HA, Kuhmichel A, Steed MB (2010) Retrospective review of microsurgical repair of 222 lingual nerve injuries. J Oral Maxillofac Surg 68:715–723
3. Fujita S, Tojyo I, Yamada M, Go Y, Matsumoto T, Kiga N (2014) Outcome following lingual nerve repair with vein graft cuff: a preliminary report. J Oral Maxillofac Surg 72:1433 e1–1433 e7
4. Susarla SM, Lam NP, Donoff RB, Kaban LB, Dodson TB (2005) A comparison of patient satisfaction and objective assessment of neurosensory function after trigeminal nerve repair. J Oral Maxillofac Surg 63:1138–1144
5. Lam NP, Donoff RB, Kaban LB, Dodson TB (2003) Patient satisfaction after trigeminal nerve repair. Oral Surg Oral Med Oral Pathol Oral Radiol Endod 95:538–543
6. Bagheri SC, Meyer RA, Cho SH, Thoppay J, Khan HA, Steed MB (2012) Microsurgical repair of the inferior alveolar nerve: success rate and factors that adversely affect outcome. J Oral Maxillofac Surg 70:1978–1990
7. Farole A, Jamal BT (2008) Abioabsorbable collagen nerve cuff (NeuraGen) for repair of lingual and inferior alveolar nerve injuries: a case series. J Oral Maxillofac Surg 66:2058–2062
8. Bagheri SC, Meyer RA, Khan HA, Wallace J, Steed MB (2010) Microsurgical repair of the peripheral trigeminal nerve after mandibular sagittal split ramus osteotomy. J Oral Maxillofac Surg 68:2770–2782
9. Okamoto H, Hata K, Kagami H, Okada K, Ito Y, Narita Y, Hirata H, Sekiya I, Otsuka T, Ueda M (2010) Recovery process of sciatic nerve defect with

novel bioabsorbable collagen tubes packed with collagen filaments in dogs. J Biomed Mater Res A 92(3):859–868
10. Saeki M, Tanaka K, Imatani J, Okamoto H, Watanabe K, Nakamura T, Gotani H, Ohi H, Nakamura R, Hirata H (2018) Efficacy and safety of novel collagen conduits filled with collagen filaments to treat patients with peripheral nerve injury: a multicenter, controlled, open-label clinical trial. Injury 49(4): 766–774
11. Susarla SM, Kaban LB, Donoff RB, Dodson TB (2007) Does early repair of lingual nerve injuries improve functional sensory recovery? J Oral Maxillofac Surg 65:1070–1076
12. Pogrel MA (2002) The results of microneurosurgery of the inferior alveolar and lingual nerve. J Oral Maxillofac Surg 60:485–489
13. Pogrel MA, McDonald AR, Kaban LB (1998) Gore-Tex tubing as a conduit for repair of lingual and inferior alveolar nerve continuity defects: a preliminary report. J Oral Maxillofac Surg 56:319–321 discussion 321–2
14. Pogrel MA, Maghen A (2001) The use of autogenous vein grafts for inferior alveolar and lingual nerve reconstruction. J Oral Maxillofac Surg 59:985–988 discussion 988–93
15. Robinson P, Loescher A, Smith K (2000) A prospective, quantitative study on the clinical outcome of lingual nerve repair. Br J Oral Maxillofac Surg 38: 255–263

Publisher's Note