

BRIEF REPORT

Open Access



Transmission sources and severe rat lung worm diseases in travelers: a scoping review

Atibordee Meesing¹, Sittichai Khamsai^{1*}, Kittisak Sawanyawisuth^{1*}, Somsak Tiamkao¹, Wanchai Maleewong², Panita Limpawattana¹, Bundit Sawunyavisuth³, Chetta Ngamjarus⁴ and Watchara Boonsawat¹

Abstract

Background Rat lung worm disease (RLWD) has several clinical forms including eosinophilic meningitis (EOM) and two severe forms, eosinophilic meningoencephalitis (EOME) and eosinophilic radiculomyelitis (EORM). It remains unclear whether transmission sources are associated with severe forms of RLWD. This study aimed to evaluate if transmission factors are related to the severity of RLWD among travelers by using a scoping review of case reports.

Methods This was a review using five databases to retrieve case reports and case series of travelers with RLWD. Clinical data and transmission sources of reported cases diagnosed as RLWD were retrieved. The outcome of the study was occurrence of severe forms of RLWD defined as EOME, EORM, and combined EOME/EORM.

Results We retrieved 1,326 articles from five databases and 31 articles were included in the analysis. There were 84 cases eligible from 15 countries. Four cases were excluded. Seventy cases were in EOM group and 10 cases had EOME or EORM. Compared with the EOM group, the EOME, EORM, and combination EOME/EORM group had similar age, sex, and risk factors of consumptions of apple snails, shrimp and prawn, and salad/vegetables. The EOME group had higher proportion of consumption of African snails than the EOM group (60% vs 13.8%). However, only one study reported the consumption of African snails and the heterogeneity between studies and the small sample size impeded direct comparisons between groups.

Conclusions RLWD in travelers can be found in most continents and mostly get infected from endemic countries of RLWD. Further studies are required to evaluate the association between transmission vectors and severity of RLWD.

Keywords African giant snails, Pila snails, Apple snails, *Angiostrongylus cantonensis*

Introduction

Rat lung worm disease (RLWD), caused by *Angiostrongylus cantonensis* infection, is a global neurological disease. There are three main forms of the RLWD, namely, eosinophilic meningitis (EOM), eosinophilic meningoencephalitis (EOME), and ocular angiostrongyliasis [1, 2]. In addition, there are other forms of RLWD in the literatures, for example, gastrointestinal involvement, eosinophilic radiculomyelitis (EORM), and otoangiostrongyliasis [3–5]. These neurological symptoms may be resolved or persistent causing morbidity or mortality [6]. A previous study in Thailand reported that the mortality rate of EOME, a severe form, was as high as 80% [7].

*Correspondence:

Sittichai Khamsai
sittikh@kku.ac.th
Kittisak Sawanyawisuth
kittisak@kku.ac.th

¹ Department of Medicine, Faculty of Medicine, Khon Kaen University, 123 Mitraparp Road, Khon Kaen, Thailand 40002

² Department of Parasitology, Faculty of Medicine, Khon Kaen University, Khon Kaen, Thailand 40002

³ Department of Marketing, Faculty of Business Administration and Accountancy, Khon Kaen University, Khon Kaen, Thailand 40002

⁴ Department of Epidemiology and Biostatistics, Faculty of Public Health, Khon Kaen University, Khon Kaen, Thailand 40002



© The Author(s) 2023. **Open Access** This article is licensed under a Creative Commons Attribution 4.0 International License, which permits use, sharing, adaptation, distribution and reproduction in any medium or format, as long as you give appropriate credit to the original author(s) and the source, provide a link to the Creative Commons licence, and indicate if changes were made. The images or other third party material in this article are included in the article's Creative Commons licence, unless indicated otherwise in a credit line to the material. If material is not included in the article's Creative Commons licence and your intended use is not permitted by statutory regulation or exceeds the permitted use, you will need to obtain permission directly from the copyright holder. To view a copy of this licence, visit <http://creativecommons.org/licenses/by/4.0/>. The Creative Commons Public Domain Dedication waiver (<http://creativecommons.org/publicdomain/zero/1.0/>) applies to the data made available in this article, unless otherwise stated in a credit line to the data.

In addition to the people in the endemic areas [8], travelers are another group of persons at risk for RLWD [9]. It may be difficult for physicians to diagnose RLWD if history of traveling and exposure to *A. cantonensis* larvae is ignored [1, 6, 10, 11]. Humans can get RLWD by consumption of *A. cantonensis* containing foods including raw freshwater snails, fish, shrimp, or vegetables [12, 13]. Consumption of specific food (transmission sources) may cause severe RLWD. A previous study found that eating raw monitor lizard is associated with EOME in six patients as well as a case of eating raw frogs with wine [14–16]. However, there is no previous study on an association between transmission sources and severity of RLWD particularly in travelers. This scoping review aimed to describe transmission sources and severity of RLWD in travelers.

Methods

This was a scoping review by using five databases including PubMed, Scopus, Central database, ProQuest, and CINAHL database [17]. We included a case report or case series of travelers with RLWD. Those articles with an observational design, meta-analysis, or intervention study were excluded. The full search details were in Additional file 1: Appendix. The last search was performed on April 1, 2022. Searching included any articles published since the beginning of the database through April 1, 2022. Hand search was also applied to find additional online articles or data. Eligible articles were included after duplication removal. An initial screening was conducted to include relevant articles. Full text review was performed in those relevant articles; those reports in non-travelers were excluded. The extraction processes were executed by two independent authors (AM and SK). The diagnosis of RLWD was done clinically or by confirmation tests such as ELISA or other serological tests.

Clinical data and risk factors of RLWD were collected. The patients whose clinical data were not available were excluded. The studied variables included baseline characteristics and the risk factors including age, sex, transmission sources for RLWD. The transmission sources defined as raw or uncooked freshwater snails, slugs, shrimp/prawn, frogs, crabs, fish, monitor lizards, vegetables, salad, or water/juice. Study characteristics on time to diagnosis or incubation period, time to treatment, diagnosis of RLWD, confirmation test, treatment, and treatment outcomes were studied. An outbreak investigation was also reported. The outcome of the study was the occurrence of RLWD which was categorized as EOME, EORM and the combination of the two (EOME/EORM). Severe consequences including death and coma were also retrieved. Factors associated with the occurrence of EOME, EORM, and combined EOME/EORM were

analyzed and reported using descriptive statistics. The statistical analyses were performed by STATA software version 10.1 (College Station, Texas, USA).

Results

There were 1,326 related articles from five databases and 868 articles for screening as shown in the Prisma flow (Fig. 1). Of those, 834 articles were excluded due to non-relevance. There were 34 articles for full text review with three articles excluded due to non-traveler studies. In total, there were 31 articles included in the review [4, 18–47] with 84 patients from 15 countries around the world (Table 1). Thailand, USA, and South Korea were the top three countries with 25, 17, and 16 patients respectively. There were eight countries from Europe, two countries from Asia (China and Singapore), one country from Australasia (Australia), and another one country from South America (Brazil). Cases were reported from 1982 until 2019. The mortality rate was 2.38% (2 patients) with severe consequences in 5 patients (5.95%).

There were three major outbreaks reported with the highest numbers of patients [23, 27, 47]. The first outbreak was reported from Samoa by Kilks et al. in 1982 [47]. Sixteen out of 24 Korean fishermen (66.7%) who ate raw or uncooked snails developed RLWD: EOM or EORM. Those who ate cooked or did not eat snails did not have the RLWD. Three out of 16 (18.8%) had EOME: one patient died (33.3%).

Another outbreak from Taiwan was reported with 17 Thai patients [23]. The patients consumed raw apple snails from the ponds. All patients diagnosed as EOM and presented with acute headache, but only 11 patients had neck stiffness (64.7%) and 3 patients (17.6%) had pathognomonic hyperesthesia [11]. None of the patients developed severe EOME form. After treatment, all patients had an improvement from headache with minimal sequelae.

The final outbreak from the US reported 12 out of 23 medical students (52.2%) traveled to Jamaica [27]. All patients presented with headache and were diagnosed as EOM: nine patients were admitted (75.0%). Out of 12 patients, neck stiffness and hyperesthesia were found in 10 (83.3%) and 6 (50.0%) patients, respectively. Caesar salad was reported to be associated with the outbreak ($p=0.007$). No consumption of snails or slugs was reported by the patients. Headache was improved with one patient reported of fine tremor of the arms and legs.

There three outbreak investigations to assess the possible causes of RLWD by Slom et al. in Chicago, Wang et al. in Taiwan, and Kliks et al. in Hawaii [27, 36, 47]. Slom et al. investigated on 23 travelers returning from Jamaica, twelve of them diagnosed with RLWD (cases) and eleven without infection (controls). The authors used a structured questionnaire on food consumed in Jamaica and linked eating in one

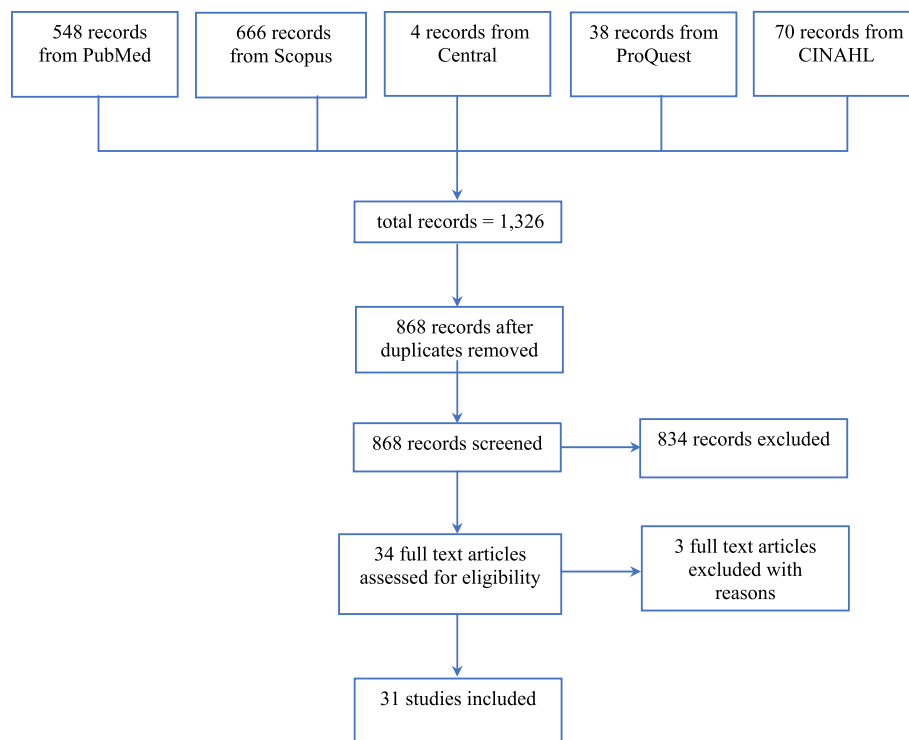


Fig. 1 A prisma flow chart of reported cases of rat lung worm disease caused by *Angiostrongylus cantonensis* in travelers

Table 1 Country and numbers of reported cases of rat lung worm disease caused by *Angiostrongylus cantonensis* in travelers (n = 84)

Country	Year	Numbers (%)	Infected country	Suspected foods	Mortality/ Severe consequences
Thailand	2001, 2011, 2018	25 (29.76)	Taiwan	Apple snails	1 coma
USA	1983, 2001, 2002, 2004, 2009, 2017	17 (20.24)	Jamaica, Tongo, Dominican Republic, South Pacific, USA ^a	Salad, raw snails, lettuce, crab, shrimp	1 severe
South Korea	1982	16 (19.05)	American Samoa	African snails	1 death
France	1988, 1996, 2002, 2008	8 (9.52)	French Polynesia	Prawn, raw fish	
Australia	1990, 1999	4 (4.76)	Fiji	Prawn	1 death
Switzerland	1995, 2004, 2019	3 (3.57)	French Polynesia, Cuba, Thailand	Raw fish	
Netherland	2015	2 (2.38)	Philippines	Salad, prawns	
Germany	2006, 2009	2 (2.38)	Dominican Republic, Thailand	Fish, clam, vegetables, salad	
Brazil	2004	1 (1.19)	Fiji	Vegetables	1 severe
Belgium	2007	1 (1.19)	Fiji	Salad, prawns	
Italy	2007	1 (1.19)	Dominican Republic	Shrimp	1 severe
UK	2007	1 (1.19)	Thailand	Snails, salad	
Croatia	2009	1 (1.19)	Malaysia	Vegetables, shrimp	1 severe
China	2019	1 (1.19)	China ^a	NA	
Singapore	2004	1 (1.19)	Korea	Salad	

NA Not available

^a Different part of country

specific restaurant and Caesar salad to RLWD ($p=0.001$ and 0.007 , respectively). Caesar salad contained romaine lettuce from the US and salted anchovies, no snails or mollusks were reported. The authors from Taiwan reported three patients consumed wine with snails from an irrigation canal. The snail meat was either seasoning or roasted for 5–10 min. The authors evaluated if there were any *A. cantonensis* larva in

five irrigations. *A. cantonensis* larvae were found in snails of all five irrigations with the infected rate of 12.1%, 14.9%, 17.9%, 26.1%, and 29.4%. The larvae were still after 120 min of seasoning or 20 min of roasting. Finally, another study evaluated numbers of snails consumed in the infected patients. The numbers of raw snails eaten by 9 out of 12 patients were reported: ranged from 2 to 5 snails.

Table 2 Study characteristics regarding diagnosis and treatments of rat lung worm disease caused by *Angiostrongylus cantonensis* in travelers ($n=84$)

Country (ref)	Time to diagnosis	Time to treatment	CSF white blood cells (cells/mm ³)	CSF eosinophils (%)	Confirmation test (no positive/total patients)	Treatment	Outcomes
Taiwan [23]	4–23 days	NA	0–1660	0–20	Serum Ab (16/17) CSF Ab (5/17) ^b	Steroid	Recovered
Taiwan [24]	3–80 days	NA	0–1660	0–73	Serum Ab (30/31) CSF Ab (5/17)	Steroid	Recovered with 2 deaths
USA [18]	4 weeks	2 weeks	152	25	NA	Aspirin, acetaminophen	Improved 8 days
USA [25]	5 days	4 weeks	246	3	Serum Ab to 31 kDa	None	3 months
USA [27]	6–31 days	NA	18–765	0–54 ^a	Serum Ab to 31 kDa (11/12)	Opioids, NSAIDs, steroid, LP	Improved 4–8 weeks
USA [30]	NA	3 days	278	61	Serum and CSF to 31 kDa	Brufen, gabapentin	Improved 8 weeks
USA [38]	1.5 months	1 month	270	12	CSF PCR	LP, steroid	Improved 2 months
USA [41]	5 weeks	2 weeks	NA	1 st : 55 (0) 2 nd : 754 (44)	Serum, CSF convalescent Ab to 31 kDa	Albendazole	NA
USA [47]	1–6 days	NA	12–2800	10–35	Serum ELISA (10/10)	Thiabendazole	Recovered 4–6 weeks with one death
France [35]	NA	14 days	1400	35	Serum convalescent Ab	Steroid, ivermectin	Improved 2 months with relapse at 6 months
Australia [22]	NA	6 days	55	0	Autopsy larva in pulmonary artery	IV methylprednisolone	Death
Australia [29]	NA	1 week	435	45	Serum Ab to 31 kDa	NA	Intubated
Switzerland [28]	Few days	NA	502	23	Serum Ab to 200, 95, 55, 31 kDa	NA	NA
Switzerland [44]	2 weeks	NA	1067	25	Serum convalescent Ab	Albendazole, steroid	Improved 2 weeks
Netherlands [37]	NA	7 days	1323	0	CSF PCR	NA	NA
Germany [31]	1 weeks	3 weeks	NA	NA	CSF Ab	Oral albendazole, steroid	Improved 4 weeks
Croatia [4]	35 days	17 days	320	6.5	Immunoblotting 31 kDa	Repeated LP	Improved 1 month
Belgium [34]	NA	27 days	342	40	Serum Ab	IV methylprednisolone	Improved 5 months

NA Not available, Ab Antibodies, CSF Cerebrospinal fluid, PCR Polymerase chain reaction, LP Lumbar puncture

^a Some patients had CSF eosinophils in the later LP

^b Larva detected in the CSF

Regarding study characteristics on diagnosis and treatment (Table 2), the incubation period was between 1 and 80 days. Cerebrospinal fluid (CSF) eosinophils ranged between 0 and 73%, while CSF white blood cells were reported from 0 to 2,800 cells/mm³. Note that CSF eosinophilia was not detected in the first lumbar puncture but was presented in the later lumbar puncture [27, 41]. Most studies used serum antibodies against *A. cantonensis* to 31 kDa antigenic bands, only two studies had recovered *A. cantonensis* larva in either CSF or pulmonary arteries [22, 23]. Corticosteroid and repeated lumbar puncture was the treatment regimen for severe cases. The clinical outcomes were mostly favorable except those with severe diseases. The recovery time was about 4–8 weeks in average.

Among 84 patients, four patients were excluded due to the absence of clinical data in the report. Most patients had EOM (70 patients; 87.50%), while 7 patients had EOME and 4 patients had EORM. Note that one patient had both EOME and EORM (Table 3). Compared with the EOM group, the EOME, EORM, and combination of EOME/EORM group had comparable age, sex, or risk factors of consumptions of apple snails, shrimp and prawn, and salad/vegetables (Table 2). The EOME group had a higher proportion of consumption of African snails than the EOM group (60.00% vs 13.85%) but there were comparable proportions of consumptions of African snails in the EORM and combination of both conditions group versus EOM group (Table 3).

Discussion

RLWD has been reported in travelers worldwide in almost all continents except in Africa. The most common countries of RLWD are Thailand, USA, and South Korea accounted for 69.0% (58/84 cases) as shown in

Table 1. Not only reported from other countries, Thailand is the most endemic are for RLWD [48]. There were 1337 reported cases out of 2827 cases worldwide (47.3%), while French Polynesia and USA were ranked as the third and fourth endemic countries resulting in several reported cases in travelers infected from and to these two countries (Table 1). There is no reported case from Africa may be due to limited travel in this continent as well as no reported cases previously. Note that study characteristics in travelers were comparable with previously reported. The maximum incubation period was slightly shorter than the studies in Thailand which had incubation at the most of 3 months [10–12]. CSF eosinophils, a diagnostic indicator, may be found in the later lumbar punctures as well as the convalescent serum antibodies against the *A. cantonensis* antigenic bands.

This study revealed that people infected RLWD by African giant snails had higher rate of EOME than the EOM group. Despite consumption of less than 10 African snails per patient, three of 12 Korean fishermen (25%) developed severe EOME [47]. However, only one study reported the consumption of African snails and the heterogeneity between studies and the small sample size impeded direct comparisons between groups. (Table 2). Patients with RLWD in Thailand usually have a history of eating raw freshwater snails such as *Pila* snails with quite a few number of snails [49, 50]. Additionally, very few cases of severe or EOME were reported in Thailand. A review of 527 patients with EOM found that none of them had severe RLWD or EOME [49], while reports from outside Thailand had more severe consequences such as EOME associated with African snails [51–53]. Compared with other transmission sources, African giant snails accounted for 17.4% of all sources (12 out of 69 cases) as shown

Table 3 Baseline characteristics and risk factors for eosinophilic meningoencephalitis (EOME), eosinophilic radiculomyelitis (EORM), or combination of eosinophilic meningoencephalitis and radiculomyelitis (EOME/EORM) caused by *Angiostrongylus cantonensis* in travelers

Factors	EOME		EORM		EOME/EORM	
	EOM n = 70	EOME n = 7	EOM n = 70	EORM n = 4	EOM n = 70	EOME/EORM ^a n = 10
Median age (range), years	29 (1–55)	21 (1–40)	29 (1–55)	45 (1–47)	29 (1–55)	30 (1–47)
Advanced age > 60 years	1 (3.13)	2 (33.33)	1 (3.13)	1 (25.00)	1 (3.13)	2 (22.22)
Male	56 (80.00)	6 (85.71)	56 (80.00)	3 (75.00)	56 (80.00)	8 (80.00)
African snails	9 (13.85)	3 (60.00)	9 (13.85)	0	9 (13.85)	3 (37.50)
Apple snails	24 (36.92)	1 (20.00)	24 (36.92)	0	24 (36.92)	1 (12.50)
Shrimp and prawn	12 (17.65)	0	12 (17.65)	2 (66.67)	12 (17.65)	2 (25.00)
Salad and vegetables	19 (27.94)	1 (20.00)	19 (27.94)	1 (33.33)	19 (27.94)	2 (25.00)

Data presented as number (percentage) unless indicated otherwise

^a One patient had both EOME and EORM

in Table 2. Note that only one case series reported on consumption of African giant snails in this review [47].

Presence of EORM is another factor for severe disease [47]. For EORM and combination of EOME/EORM outcomes, there is no significant factor associated with these outcomes. These findings may be due to small number of patients in EORM category (Table 2). The causative agent *A. cantonensis* is a neurotropic nematode but they usually migrate to meninges in humans. Random migration to spinal cord may cause severe disease as shown by one fatal case with the evidence of *A. cantonensis* larva in the lumbar spinal cord but not in the meninges or brain [47]. However, the number is too small to determine an association.

There are some limitations in this study. The design is a retrospective review of the database. Therefore, it may be some missing data shown in Table 2. Causal relationship may not be demonstrated. No correlation or meta-analysis was performed. Finally, in the EORM group had small sample size. Further larger studies are required.

Conclusions

RLWD in travelers can be found in most continents and mostly get infected from endemic countries of RLWD. Further studies are required to demonstrate the association between transmission vectors and severity of RLWD.

Supplementary Information

The online version contains supplementary material available at <https://doi.org/10.1186/s40794-022-00184-4>.

Additional file 1: Appendix. Searching strategies of reported cases of rat lung worm disease caused by *Angiostrongylus cantonensis* in travelers in five databases.

Acknowledgements

We would like to acknowledge Prof. Yukifumi Nawa for editing the final manuscript via Publication Clinic KKU, Thailand (PCO-879).

Authors' contributions

All authors were involved in study design. AM, SK, and KS were responsible for data collection. CN performed literature search. AM, SK, KS, BS and CN were involved in data analysis and interpretation. AM and SK wrote the manuscript. ST, WM, PL, and WB provided technical guidance and revised the manuscript. All authors read and approved the final version manuscript.

Funding

This study was supported by Distinguished Research Professor Grant, Thailand Research Fund (Grant no. DPG6280002) to Wanchai Maleewong.

Availability of data and materials

Data are available upon request.

Declarations

Ethics approval and consent to participate

Not required.

Consent for publication

Not applicable.

Competing interests

The authors declare that they have no competing interests.

Received: 10 January 2022 Accepted: 18 November 2022

Published online: 10 February 2023

References

- Sawanyawisuth K, Sawanyawisuth K. Treatment of angiostrongyliasis. *Trans R Soc Trop Med Hyg.* 2008;102:990–6.
- Sawanyawisuth K, Takahashi K, Hoshuyama T, Sawanyawisuth K, Senthong V, Limpawattana P, et al. Clinical factors predictive of encephalitis caused by *Angiostrongylus cantonensis*. *Am J Trop Med Hyg.* 2009;81:698–701.
- Sawanyawisuth K, Pugkhem A, Mitchai J, Intapan PM, Anunnatsiri S, Limpawattana P, et al. Abdominal angiostrongyliasis caused by *Angiostrongylus cantonensis*: a possible cause of eosinophilic infiltration in human digestive tract. *Pathol Res Pract.* 2010;206:102–4.
- Maretić T, Perović M, Vince A, Lukas D, Dekumyoy P, Begovac J. Meningitis and radiculomyelitis caused by *Angiostrongylus cantonensis*. *Emerg Infect Dis.* 2009;15:996–8.
- Chotmongkol V, Yimtae K, Intapan PM. *Angiostrongylus* eosinophilic meningitis associated with sensorineural hearing loss. *J Laryngol Otol.* 2004;118:57–8.
- Sawanyawisuth K, Sawanyawisuth K, Senthong V, Limpawattana P, Intapan PM, Tiamkao S, et al. Peripheral eosinophilia as an indicator of meningitic angiostrongyliasis in exposed individuals. *Mem Inst Oswaldo Cruz.* 2010;105:942–4.
- Chotmongkol V, Sawanyawisuth K. Clinical manifestations and outcome of patients with severe eosinophilic meningoencephalitis presumably caused by *Angiostrongylus cantonensis*. *Southeast Asian J Trop Med Public Health.* 2002;33:231–4.
- Khamsai S, Chindaprasit J, Chotmongkol V, Tiamkao S, Limpawattana P, Senthong V, et al. Clinical features of eosinophilic meningitis caused by *Angiostrongylus cantonensis* in Thailand: a systematic review: Clinical EOM. *Asia Pac J Sci Technol.* 2020;25:APST-25-02-09. Available from: <https://so01.tci-thaijo.org/index.php/APST/article/view/240510>. Cited 2022 Apr 20.
- Ansdell V, Wattanagoon Y. *Angiostrongylus cantonensis* in travelers: clinical manifestations, diagnosis, and treatment. *Curr Opin Infect Dis.* 2018;31:399–408.
- Sawanyawisuth K, Sawanyawisuth K, Senthong V, Limpawattana P, Phichaphop A, Intapan PM, et al. How can clinicians ensure the diagnosis of meningitic angiostrongyliasis? *Vector Borne Zoonotic Dis.* 2012;12:73–5.
- Sawanyawisuth K, Chotmongkol V. Eosinophilic meningitis. *Handb Clin Neurol.* 2013;114:207–15.
- Sawanyawisuth K, Sawanyawisuth K, Senthong V, Limpawattana P, Intapan PM, Maleewong W, et al. Clinical features and course of *Angiostrongylus cantonensis* eosinophilic meningitis in patients receiving supportive therapy. *Food Waterborne Parasitol.* 2020;21:e00095.
- Jarvi SI, Eamsobhana P, Quarta S, Howe K, Jacquier S, Hanlon A, et al. Estimating human exposure to rat lungworm (*Angiostrongylus cantonensis*) on Hawai'i Island: a pilot study. *Am J Trop Med Hyg.* 2020;102:69–77.
- Kanpittaya J, Jitpimolmard S, Tiamkao S, Mairiang E. MR findings of eosinophilic meningoencephalitis attributed to *Angiostrongylus cantonensis*. *AJNR Am J Neuroradiol.* 2000;21:1090–4.
- Tsai H-C, Lai P-H, Sy C-L, Lee SS-J, Yen C-M, Wann S-R, et al. Encephalitis caused by *Angiostrongylus cantonensis* after eating raw frogs mixed with wine as a health supplement. *Intern Med.* 2011;50:771–4.
- Panackel C, Vishad, Cherian G, Vijayakumar K, Sharma RN. Eosinophilic meningitis due to *Angiostrongylus cantonensis*. *Indian J Med Microbiol.* 2006;24:220–1.
- Namwaing P, Ngamjarus C, Sakaew W, Sawanyawisuth B, Sawanyawisuth K, Khamsai S, et al. Chest physical therapy and outcomes in primary

- spontaneous pneumothorax: a systematic review. *J Med Assoc Thai*. 2021;104:5165–8.
18. Fischer PR. Eosinophilic meningitis. *West J Med*. 1983;139:372–3.
 19. Scemama M, Chiron C, Georges P, Dulac O. [Radiculomyeloencephalitis caused by *Angiostrongylus cantonensis* in children]. *Arch Fr Pediatr*. 1988;45:417–9.
 20. Vuadens P, Regli F. Eosinophil meningoradiculitis caused by *Angiostrongylus cantonensis*. *Rev Neurol (Paris)*. 1995;151:354–6.
 21. Thobois S, Broussolle E, Aimard G, Chazot G. Ingestion of raw fish: a cause of eosinophilic meningitis caused by *Angiostrongylus cantonensis* after a trip to Tahiti. *Presse Med*. 1996;25:508.
 22. Cooke-Yarborough CM, Kornberg AJ, Hogg GG, Spratt DM, Forsyth JR. A fatal case of angiostrongyliasis in an 11-month-old infant. *Med J Aust*. 1999;170:541–3.
 23. Tsai HC, Liu YC, Kunin CM, Lee SS, Chen YS, Lin HH, et al. Eosinophilic meningitis caused by *Angiostrongylus cantonensis*: report of 17 cases. *Am J Med*. 2001;111:109–14.
 24. Tseng Y-T, Tsai H-C, Sy CL, Lee S-S, Wann S-R, Wang Y-H, et al. Clinical manifestations of eosinophilic meningitis caused by *Angiostrongylus cantonensis*: 18 years' experience in a medical center in southern Taiwan. *J Microbiol Immunol Infect*. 2011;44:382–9.
 25. Lo Re V, Gluckman SJ. Eosinophilic meningitis due to *Angiostrongylus cantonensis* in a returned traveler: case report and review of the literature. *Clin Infect Dis*. 2001;33:e112-115.
 26. de Roux-Serratrice C, Allègre T, Bensaïd T, Bigorgne C, Vassal D, Caillères S. Eosinophilic meningitis on returning from Tahiti. *Presse Med*. 2002;31:1219.
 27. Slom TJ, Cortese MM, Gerber SI, Jones RC, Holtz TH, Lopez AS, et al. An outbreak of eosinophilic meningitis caused by *Angiostrongylus cantonensis* in travelers returning from the Caribbean. *N Engl J Med*. 2002;346:668–75.
 28. Bärtschi E, Bordmann G, Blum J, Rothen M. Eosinophilic meningitis due to *Angiostrongylus cantonensis* in Switzerland. *Infection*. 2004;32:116–8.
 29. Batmanian JJ, O'Neill JH. Eosinophilic meningoencephalitis with permanent neurological sequelae. *Intern Med J*. 2004;34:217–8.
 30. Podwall D, Gupta R, Furuya EY, Sevigny J, Resor SR. *Angiostrongylus cantonensis* meningitis presenting with facial nerve palsy. *J Neurol*. 2004;251:1280–1.
 31. Rau C, Bialek R, Richter S, Lindner A. [Headache after a stay in the Dominican Republic]. *Dtsch Med Wochenschr*. 2006;131:1656–9.
 32. Jones MS, Mohanraj R, Shaunak S. Eosinophilic meningitis due to *Angiostrongylus cantonensis*: first reported case in the UK. *ACNR*. 2007;6:20–1. Available from: <https://www.semanticscholar.org/paper/Eosinophilic-Meningitis-due-to-Angiostrongylus-in-Jones-Mohanraj/588d56baa5b1246ff05e4c14d90876240272408d>. Cited 2022 Apr 19.
 33. Leone S, De Marco M, Ghirga P, Nicastri E, Esposito M, Narciso P. Eosinophilic meningitis in a returned traveler from Santo Domingo: case report and review. *J Travel Med*. 2007;14:407–10.
 34. Ali AB, Van den Enden E, Van Gompel A, Van Esbroeck M. Eosinophilic meningitis due to *Angiostrongylus cantonensis* in a Belgian traveller. *Travel Med Infect Dis*. 2008;6:41–4.
 35. Malvy D, Ezzedine K, Receveur M-C, Pistone T, Crevon L, Lemardeley P, et al. Cluster of eosinophilic meningitis attributable to *Angiostrongylus cantonensis* infection in French policemen troop returning from the Pacific Islands. *Travel Med Infect Dis*. 2008;6:301–4.
 36. Wang J-J, Chung L-Y, Lin R-J, Lee J-D, Lin C-W, Yen C-M. Eosinophilic meningitis risk associated with raw *Ampullarium canaliculatus* snails consumption. *Kaohsiung J Med Sci*. 2011;27:184–9.
 37. Lammers AJJ, Goorhuis A, van de Beek D, Grobusch MP, Bart A, van Gool T, et al. Eosinophilia à deux: a brain nagging souvenir from the Philippines. *Infection*. 2015;43:615–7.
 38. Prasadhrathsint K, Lewis J, Couturier MR. The brief case: *Angiostrongylus cantonensis* eosinophilic meningitis in a returned traveler. *J Clin Microbiol*. 2017;55:2880–3.
 39. Meyer C, Wynn DP, Pulst SM, Chen R, Digre K. Clinical reasoning: a 22-year-old man with diplopia. *Neurology*. 2017;89:e45–9.
 40. Luessi F, Sollors J, Torzewski M, Müller HD, Siegel E, Blum J, et al. Eosinophilic meningitis due to *Angiostrongylus cantonensis* in Germany. *J Travel Med*. 2009;16:292–4.
 41. Ramirez-Avila L, Slome S, Schuster FL, Gavali S, Schantz PM, Sejvar J, et al. Eosinophilic meningitis due to *Angiostrongylus* and *Gnathostoma* species. *Clin Infect Dis*. 2009;48:322–7.
 42. Lim JM, Lee CC, Wilder-Smith A. Eosinophilic meningitis caused by *Angiostrongylus cantonensis*: a case report and literature review. *J Travel Med*. 2004;11:388–90.
 43. Clouston PD, Corbett AJ, Pryor DS, Garrick R. Eosinophilic meningitis: cause of a chronic pain syndrome. *J Neurol Neurosurg Psychiatry*. 1990;53:778–81. Available from: <https://www.ncbi.nlm.nih.gov/pmc/articles/PMC1014256/>. Cited 2022 Apr 19.
 44. Brummaier T, Bertschy S, Arn K, Treumann T, Ruf M-T, Nickel B, et al. A blind passenger: a rare case of documented seroconversion in an *Angiostrongylus cantonensis* induced eosinophilic meningitis in a traveler visiting friends and relatives. *Trop Dis Travel Med Vaccines*. 2019;5:6.
 45. Guan H, Hoi C, Cui L, Chen L. Eosinophilic meningitis caused by infection of *Angiostrongylus cantonensis* in a traveler. *Chin J Contemp Neurol Neurosurg*. 2013;13:55–7. Available from: <http://manu21.magtech.com.cn/cjcn/CN/abstract/abstract459.shtml>. Cited 2022 Apr 19.
 46. Berger S. *Infectious Diseases of Taiwan* eBook. GIDEON; 2021. Available from: <https://www.gideononline.com/ebooks/infectious-diseases-of-taiwan/>. Cited 2022 Apr 20.
 47. Kliks MM, Kroenke K, Hardman JM. Eosinophilic radiculomyeloencephalitis: an angiostrongyliasis outbreak in American Samoa related to ingestion of *Achatina fulica* snails. *Am J Trop Med Hyg*. 1982;31:114–22.
 48. Wang Q-P, Lai D-H, Zhu X-Q, Chen X-G, Lun Z-R. Human angiostrongyliasis. *Lancet Infect Dis*. 2008;8:621–30.
 49. Khamtai S, Chindaprasirt J, Chotmongkol V, Tiamkao S, Limpawattana P, Senthong V, et al. Clinical features of eosinophilic meningitis caused by *Angiostrongylus cantonensis* in Thailand: a systematic review. *Asia-Pac J Sci Technol*. 2020;25:APST-25-02-09 6 pages.
 50. Eamsobhana P, Yoolek A, Yong H-S. Effect of Thai "koi-hoi" food flavoring on the viability and infectivity of the third-stage larvae of *Angiostrongylus cantonensis* (Nematoda: Angiostrongylidae). *Acta Trop*. 2010;113:245–7.
 51. Kwon E, Ferguson TM, Park SY, Manuzak A, Qvarnstrom Y, Morgan S, et al. A severe case of *Angiostrongylus* eosinophilic meningitis with encephalitis and neurologic sequelae in Hawaii. *Hawaii J Med Public Health*. 2013;72:41–5.
 52. Hwang KP, Chen ER, Chen TS. [Eosinophilic meningitis and meningoencephalitis in children]. *Zhonghua Min Guo Xiao Er Ke Yi Xue Hui Za Zhi*. 1994;35:124–35.
 53. Hwang KP, Chen ER. Clinical studies on angiostrongyliasis cantonensis among children in Taiwan. *Southeast Asian J Trop Med Public Health*. 1991;22(Suppl):194–9.

Publisher's Note

Springer Nature remains neutral with regard to jurisdictional claims in published maps and institutional affiliations.

Ready to submit your research? Choose BMC and benefit from:

- fast, convenient online submission
- thorough peer review by experienced researchers in your field
- rapid publication on acceptance
- support for research data, including large and complex data types
- gold Open Access which fosters wider collaboration and increased citations
- maximum visibility for your research: over 100M website views per year

At BMC, research is always in progress.

Learn more biomedcentral.com/submissions

