

ORIGINAL PAPER

Open Access



Effect of lateral hinge fractures for bone union and clinical outcomes following opening-wedge distal tibial tubercle osteotomy in comparison with opening-wedge high tibial osteotomy

Shuhei Otsuki^{1*} , Kuniaki Ikeda¹, Takashi Ishitani¹, Yoshinori Okamoto¹, Hitoshi Wakama¹ and Masashi Neo¹

Abstract

Purpose Although the effects of lateral hinge fractures (LHF) on bone union and clinical outcomes after opening-wedge high tibial osteotomy (OWHTO) have been established, the effects of LHF after opening-wedge distal tibial tubercle osteotomy (OWDTO) are unclear. We hypothesised that LHF after OWDTO would be associated with delayed bone union and result in poorer clinical outcomes than expected for LHF after OWHTO.

Methods This study enrolled 100 patients, with 50 OWDTO patients (18 men; mean age, 63.2 years) and 50 OWHTO patients compared based on the propensity score matched analysis. The effect of LHF on bone union was compared between the groups. Clinical outcomes were assessed using the Lysholm score and the Knee Injury and Osteoarthritis Outcome Score (KOOS) at the mean follow-up of 28 months.

Results There was no between-group difference in the incidence rate of LHF. However, the rate of bone union at the anterior flange in the presence of an LHF was significantly lower in the OWDTO (26%) than in the OWHTO (80%) 3 months postoperatively ($p < 0.05$), but no difference was observed 12 months postoperatively. The Lysholm score was significantly lower for patients with LHF following OWDTO than for OWDTO patients without LHF or OWHTO patients with/without LHF 3 and 12 months postoperatively ($p < 0.001$); Lysholm score and KOOS were not different at the final follow-up.

Conclusions LHF after OWDTO was associated with delayed bone union and poor clinical outcomes until 12 months. This information can guide decisions regarding the indications and the management of patients after OWDTO.

Level of evidence IV

Keywords Open-wedge distal tibial tubercle osteotomy, Bone union, Hinge fracture, Clinical outcome

Introduction

Although favourable clinical outcomes have been reported with opening-wedge high tibial osteotomy (OWHTO) [1, 2], progression of patellofemoral osteoarthritis (OA) resulting from decreased patellar height following OWHTO remains an issue of concern [3–5], especially for older patients [6].

*Correspondence:

Shuhei Otsuki
shuhei.otsuki@ompu.ac.jp

¹ Department of Orthopedic Surgery, Osaka Medical and Pharmaceutical University, 2-7 Daigakumachi Takatsuki, Osaka 569-8686, Japan

To minimize patellar height reduction, opening-wedge distal tibial tubercle osteotomy (OWDTO) was recommended so that OWHTO is performed below the tibial tuberosity; the descending incision begins distally in the frontal plane from the most anterior point of the transverse incision [3, 7, 8]. OWDTO is an alternative to OWHTO that provides similar favourable clinical outcomes while minimising unfavourable effects on the patellofemoral joint [3, 9, 10]. However, OWDTO is also associated with a risk of delayed union or non-union, just as lateral hinge fractures (LHF) are recognised as a risk factor in OWHTO [11–13].

LHF occurred in approximately 15–35% cases using X-rays and over 40% cases with CT scans of OWHTO [12, 14–16], and 27% of OWDTO [16], thus is not an uncommon complication for this procedure. LHF is a major cause of instability, leading to serious complications such as delayed bone union and correction loss [15] that might require additional surgery [17], and extended postoperative recovery, delayed return to daily activities, as well as a negative impact on patient-reported quality of life. However, the difference of bone union with LHF between OWHTO and OWDTO, and its effect on clinical outcomes remain unknown. Accordingly, this study aimed to evaluate the incidence of LHF and to compare clinical and radiographic outcomes between OWDTO and OWHTO using a propensity score-matched analysis. We hypothesised that LHF in OWDTO would be associated with delayed bone union and, thus, worse clinical outcomes compared to OWHTO.

Materials and methods

Statement of ethics

The methods of the study were approved by our institutional review board (No. 2022–023) and all patients provided written informed consent for the use of their data for research and publication.

Study design

This was a retrospective comparative study between OWDTO and OWHTO for OA of the knee. From January 2017 to December 2020, a total of 209 knees (203 patients) were enrolled in this study.

Surgical indications for DTO and OWHTO were OA of the medial compartment of the knee, flexion contracture of $<10^\circ$, and deformity of the proximal tibia in patients with a body mass index (BMI) of less than 35 kg/m^2 , without diabetes mellitus or with well-controlled disease, and a non-smoker.

OWDTO was performed on 67 knees of 30 men and 37 women, whose average age was 65.3 ± 8.4 years. For comparison, OWHTO was performed on 142 knees (54 men and 88 women) and the average age of the patients was 60.5 ± 9.4 years, which was significantly younger than that of OWDTO group (Table 1, $p < 0.01$). In the OWDTO group, 17 knees were excluded because 9 cases had incomplete data (KOOS) and 8 cases were lost to follow-up within 2 years; as a result, 50 knees were evaluated (Fig. 1). For the matching, the following clinically relevant potentially confounding covariates were chosen as previously proposed in the setting of alignment-correcting osteotomies [18]: age at surgery, sex, BMI, and postoperative correction angle. Fifty knees in the OWHTO group were enrolled via propensity score matching. The demographic data for both groups is presented in Table 1.

Surgical indication and procedure for OWDTO

Preoperative planning for OWHTO begins with the intended postoperative mechanical axis of the lower limb, which passes through the lateral tibial eminence as seen on the coronal view of whole-leg standing radiographs. For this study, the mechanical axis was analysed using digital planning software (TraumaCaD, BRAINLAB, Feldkirchen, Germany) with a picture archiving and communication system [5, 19]. Arthroscopy was performed

Table 1 Patient demographics

	OWDTO	OWHTO	<i>p</i> value
Total cases (<i>n</i> = 209)			
Age (years)	65.3 ± 8.4 (45–80)	60.5 ± 9.4 (40–75)	< 0.01
Knees (male / female patients)	67 (30/37)	142 (54/88)	0.35
BMI (kg/m^2)	25.1 ± 3.9 (16.2–33.1)	24.8 ± 3.6 (16.5–31.1)	0.60
Correction angle ($^\circ$)	8.9 ± 2.1 (6–13)	8.0 ± 2.7 (5–12)	0.26
Propensity score-matched cases (<i>n</i> = 100)			
Age (years)	63.2 (47–75)	63.3 (45–75)	0.55
Knees (male / female patients)	50 (18/32)	50 (18/32)	0.84
BMI (kg/m^2)	25.1 ± 3.0 (17.8–31.5)	24.9 ± 2.8 (17.6–31.1)	0.63
Correction angle ($^\circ$)	9.1 ± 1.5 (6–12)	8.9 ± 1.7 (7–12)	0.71

BMI body mass index, OWDTO opening-wedge distal tubercle osteotomy, OWHTO Opening-wedge high tibial osteotomy

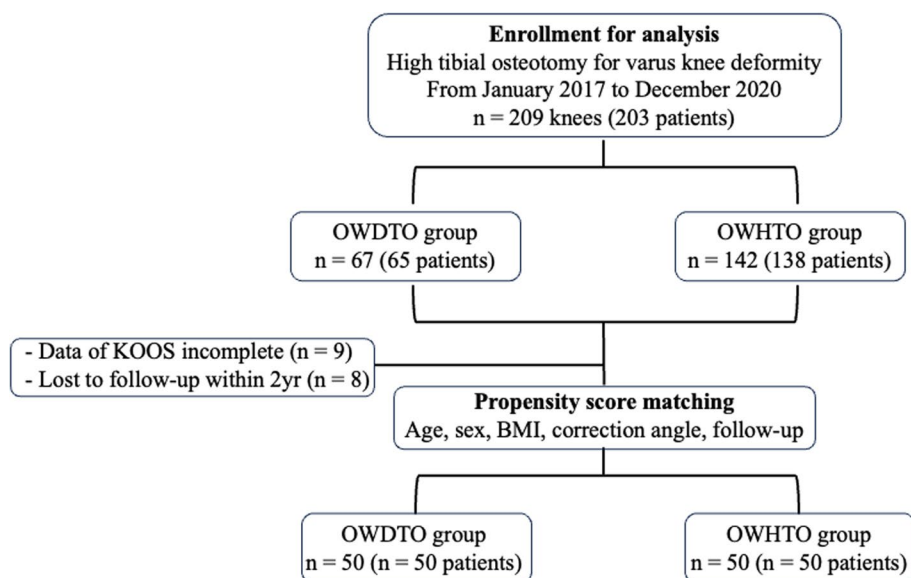


Fig. 1 Patient selection flowchart. OWDTO, opening-wedge distal tubercle osteotomy; OWHTO, opening-wedge high tibial osteotomy. BMI, body mass index

routinely prior to surgery to evaluate the degree of cartilage degeneration and quantified using the International Cartilage Repair Society (ICRS) grading system [20]. The indication for OWDTO was an ICRS cartilage degeneration grade at the patellofemoral joint more than grade II; OWHTO was selected for ICRS grades 0 or I, with knee joint flexion contracture $< 10^\circ$. Both HTOs were postoperative medial proximal tibial angle (MPTA) $\leq 95^\circ$.

The surgical procedure for OWDTO has been described in detail previously [7] and is briefly summarised here. The descending osteotomy incision line was located 40 mm distal to the knee joint line, with two guidewires inserted in a parallel orientation and directed toward the tip of the head of the fibula. The hinge position was located 5 mm medial to the lateral cortical margin at the upper level of the proximal tibiofibular joint. The ascending osteotomy was then performed with a 15-mm thickness of the tibial tuberosity, oriented at 90° to the descending incision line. A short pin was placed at the hinge point, serving as a custom-designed compass for an arc osteotomy of the distal tibial tuberosity. The length of the arc osteotomy was measured from the hinge point to the end of the descending osteotomy, with the starting point set 20 mm distal to the descending incision line. Finally, the gap created during the descending osteotomy was filled using TriS plate and β -tricalcium phosphate wedge spacers (Olympus Termo Biomaterials, Tokyo, Japan), as previously reported [21]. The distal part of the tibial tuberosity was then fixed using one or two 4-mm cannulated screws (Asnis III; Stryker, MI, USA). Two screws were inserted medial distal and lateral

proximal after arc osteotomy of the tibial tuberosity. Five patients (10%) were fixed using one screw because the size of the tibial tuberosity was small. Representative cases of X-rays of OWHTO and OWDTO are shown in Fig. 2. A single surgeon (S.O) performed the X-rays of all cases in this study.

Postoperatively, full weight-bearing was permitted on day 2 for both groups and range of motion exercises were started in the OWHTO group; however, OWDTO recipients were provided with a knee extension brace (NIPPON SIGMAX, Tokyo, Japan) for 2 weeks to prevent postoperative displacement at the tibial tuberosity. Muscle strengthening and passive range of motion exercises were initiated in both groups at week 2 postoperatively. All cases adopted this rehabilitation protocol in this study.

Radiographic and clinical evaluation

Pre- and postoperative knee alignment were evaluated using the weight-bearing line ratio (WBLR), measured using whole-leg standing radiographs and by the femorotibial angle (FTA) and MPTA measured using coronal view radiographs. Posterior tibial slope (PTS) and patellar height were assessed using the Caton-Deschamps (CD) index on sagittal view radiographs with 30 degrees of knee flexion. The presence of LHF was evaluated using the Takeuchi classification on postoperative radiographs and computed tomography (CT) images at 3 months postoperatively [13]. Representative CT images of bone union 3 months postoperatively are shown in Fig. 3. Bone union was detected in both

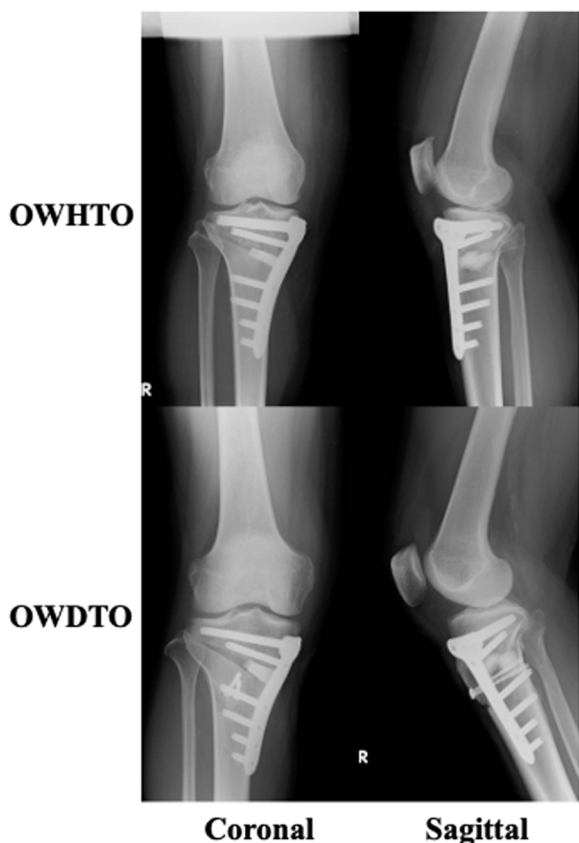

Fig. 2 Representative X-ray of OWDTO and OWHTO

the OWDTO and OWHTO groups in the absence of LHF. However, delayed union was observed in the lateral hinge and anterior flange in the OWDTO with

LHF, compared to the OWDTO group without LHF. Bone union was evaluated using the van Hemert classification at 12 months [22]. This classification was specific for the bone remodelling after high tibial osteotomy with bone substitute. All radiographic measurements were evaluated independently by two different co-authors, and interobserver and intraobserver reliability were over 0.90 in this study, as well as previously described [5]. Clinical outcomes were evaluated using the Lysholm score obtained preoperatively and at 3, 12 and 24 months postoperatively [23]. KOOS was compared preoperatively and at the final follow-up, which took place at an average of 28.8 (24–36) months.

Statistical analysis

The primary outcome was the rate of bone union 12 months postoperatively, with the comparison between the OWDTO and OWHTO groups evaluated using the Wilcoxon test. Pre- to postoperative changes in lower limb alignment were compared between the two groups using the Wilcoxon test. The incidence rate of LHF and the association between LHF and delayed union were compared between the two groups using the chi-squared test. The association between LHF and the Lysholm score was compared between groups using the chi-squared test. Analyses were performed using JMP Pro (version 15.1.0; SAS Institute), with significance set at a *p*-value of <0.05. A power analysis was performed using bone union as the primary outcome (G*power, version 3.1.9.2, Dusseldorf, Germany). For an α -value of 0.05 and power of 0.8, a total of at least 52 knees was required for evaluation of between-group differences.

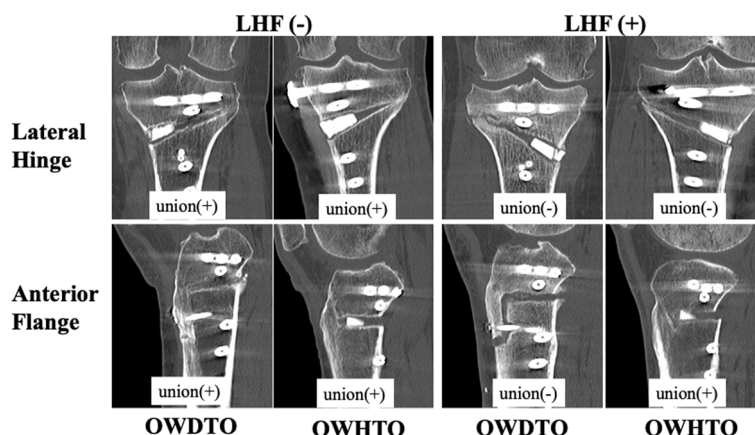


Fig. 3 Coronal computed tomography images for the OWDTO and OWHTO patients. Coronal computed tomography images for the OWDTO and OWHTO groups, showing patients with and without a lateral hinge fracture. Bone union at the lateral hinge and anterior flange are shown for the OWDTO and OWHTO groups 3 months postoperatively. Bone union is observable in panels. OWDTO, opening-wedge distal tubercle osteotomy; OWHTO, opening-wedge high tibial osteotomy. *delayed bone union

Table 2 Change in knee alignment measures from baseline to post-OWHTO and OWDTO

	OWDTO (n = 50)	OWHTO (n = 50)	p value
WBLR (%)			
pre	19.8 ± 10.9	20.4 ± 10.2	0.80
post	59.2 ± 8.1	58.6 ± 2.9	0.79
FTA (°)			
pre	181.4 ± 2.4	182.0 ± 2.9	0.26
post	171.1 ± 2.6	171.6 ± 2.3	0.58
MPTA (°)			
pre	83.4 ± 2.1	84.0 ± 2.9	0.22
post	91.6 ± 2.0	91.7 ± 2.2	0.51
PTS (°)			
pre	6.9 ± 2.3	7.6 ± 2.8	0.22
post	8.3 ± 3.0	9.0 ± 2.9	0.21
CD index			
pre	0.95 ± 0.17	0.99 ± 0.08	0.26
post	0.98 ± 0.11	0.88 ± 0.10*	< 0.01

WBLR weight-bearing line ratio, FTA femorotibial angle, MPTA medial proximal tibial angle, PTS posterior tibial slope, CD index Caton-Deschamps index

* $p < 0.001$ within-group change

Table 3 Incidence of lateral hinge fracture with OWDTO and OWHTO

	OWDTO (n = 50)	OWHTO (n = 50)	p value
LHF (+)	27 (13/14)	20 (10/10)	0.90
LHF (-)	23 (5/18)	30 (8/22)	0.68

Number of knees and sex of the patients (male/female) are shown. Between-group p value evaluated using the chi-squared test (χ^2), $p = 0.16$

LHF lateral hinge fracture, OWDTO opening-wedge distal tubercle osteotomy, OWHTO opening-wedge high tibial osteotomy

Results

There were no significant differences between the groups in terms of lower limb alignment indices (WBLR, FTA, MPTA, and PTS). Regarding within-group differences, there was a significant pre- to postoperative decrease in the CD index for the OWHTO group (Table 2, * $p < 0.001$),

and lower in comparison to OWDTO (Table 2, $p < 0.01$). LHF occurred in 47 patients and all LHF were Takeuchi classification type 1 and did not delay the rehabilitation protocol. LHF occurred in 27 patients (54%) with OWDTO procedures, which was not significantly different from its occurrence in 20 patients (40%) in OWHTO procedures and the ratio of sex in LHF was not significantly different (Table 3). Age, BMI and correction angle were not significantly different in both groups. However, bone union at the anterior flange was significantly delayed in the OWDTO group with LHF (26%) compared to the OWDTO group without LHF (78%), and the OWHTO groups with LHF (80%) and without LHF (87%) at postoperative 3 months (Table 4; * $p < 0.001$). Regarding complications, there were two fractures and one screw-loosening at the tibial tuberosity in the OWDTO group with LHF and one fracture in the OWHTO group requiring additional surgery for fixation at the tibial tuberosity at 2 weeks postoperatively. An additional two cases were delayed in starting the rehabilitation program, especially the range of motion (ROM) exercises for 1 month. However, loss of correction angle was not detected in all cases, and bone union 12 months postoperatively was not significantly different between the OWDTO and OWHTO groups with and without LHF (Table 5). The postoperative Lysholm score was significantly lower for the OWDTO group with LHF compared to the OWDTO group without LHF and the OWHTO groups with and without LHF at 3 and 12 months postoperatively (Fig. 4; * $p < 0.001$), whereas it was not significantly different at postoperative 24 months and for the KOOS at the final follow-up (Fig. 4, Table 6).

Discussion

The most important findings of this study were that LHF occurred after OWDTO as well as OWHTO; however, LHF after OWDTO was detected by delayed bone union especially at the anterior flange, with poorer clinical outcomes.

LHF frequently occur in the area surrounding knee osteotomy sites. These hinge fractures have been classified by Takeuchi et al. for OWHTOs [13]. Complications

Table 4 Incidence rate of bone union with and without presence of a lateral hinge fracture 3 months postoperatively

Bone union	LHF (-)		LHF (+)	
	OWDTO (n = 23)	OWHTO (n = 30)	OWDTO (n = 27)	OWHTO (n = 20)
Anterior	18 (78%)	26 (87%)	7 (26%)*	16 (80%)
Lateral	23 (100%)	30 (100%)	11 (41%)	9 (45%)

Between-group p -value evaluated using the chi-squared test (χ^2); LHF (-), absence of a lateral hinge fracture; LHF (+), presence of a lateral hinge fracture

OWDTO opening-wedge distal tibial tubercle osteotomy, OWHTO opening-wedge high tibial osteotomy

* $p < 0.05$ versus an OWDTO in the corresponding group

Table 5 Bone union achieved at postoperative 12 months, according to the van Hemert classification phase (0–5)

van Hemert Phase	2	3	4	5	p value
LHF (-)					
OWDTO (n=23)	1	2	5	15	0.29
OWHTO (n=30)	0	5	11	14	
LHF (+)					
OWDTO (n=27)	6	4	10	7	0.09
OWHTO (n=20)	1	9	6	4	

Between-group p value evaluated using the chi-squared test (χ^2); LHF (-), absence of a lateral hinge fracture; LHF (+), presence of a lateral hinge fracture
 OWDTO opening-wedge distal tibial tubercle osteotomy, OWHTO opening-wedge high tibial osteotomy

of LHF, including delayed bone union, loss of alignment correction, and sustained lateral pain, have previously been reported [13, 24–26]. In the current study, delayed union of the anterior flange was associated with LHF after OWDTO but not after OWHTO, reflecting differences in the biomechanical effects of OWDTO compared to those of OWHTO (Fig. 5). Specifically, OWDTO produces less compression across the osteotomy site compared to OWHTO, with the patellar tendon producing traction on the anterior flange, leading to lower overall mechanical stability [4]. Although a stable fixation is reached, the postoperative rehabilitation protocol for the OWDTO needs no adjustments due to the new technique [3], the occurrence of LHF following OWDTO results in a high magnitude of stress on the plate and screw fixation, as no bony or tendon connection remains at the osteotomy site. Furthermore, knee joint ROM exercises induce additional traction forces at the tibial tuberosity

via the patellar tendon. Accordingly, care should be taken in determination of when to initiate ROM exercises post-OWDTO owing to the risk of tibial tuberosity fracture and screw loosening, especially in patients with high BMI or osteoporosis.

Previous studies have reported similar clinical outcomes after OWHTO with and without LHF [13, 27, 28]. Our study, comparing outcomes between patients with and without LHF after OWHTO and OWDTO, identified lower Lysholm scores, as the measure of clinical outcomes, until 12 months postoperatively among patients who developed LHF after OWDTO. This measure resulted in a longer time taken for returning to activities of daily living and work. Moreover, one patient in this group required additional surgery for treatment of unstable tibial tuberosities.

Additional surgical techniques might be required to prevent the LHF [29], for example, protective K-wire has been shown to significantly decrease the risk of hinge fractures [30, 31]. To improve clinical outcomes of LHF after OWDTO, previous studies have suggested the use of gap fillers created from autologous iliac crest; allogenic bone grafts; or bone graft substitutes such as β -TCP, hydroxyapatite and, autologous osteophytes [32, 33]. Supplementing stability of the osteotomy site with percutaneous lag screws may also improve stability in cases of LHF after OWDTO [34]. The limitations of our study need to be acknowledged. Foremost is its retrospective design, and propensity score-matched analysis was used to account for the differences in the patients' background characteristics between the OWDTO and OWHTO groups. Second, the surgical indications and postoperative rehabilitation program for OWDTO and

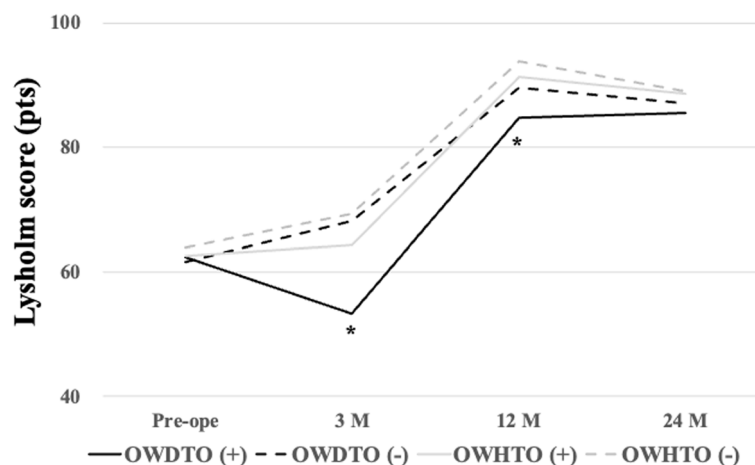


Fig. 4 Comparison of clinical outcomes, measured using the Lysholm score, between the OWDTO and OWHTO groups. The score was lower for patients with a lateral hinge fracture (LHF) in the OWDTO compared to all other groups (OWDTO without LHF, OWHTO with and without an LHF) 3 and 12 months postoperatively (*, $p < 0.01$). OWDTO, opening-wedge distal tubercle osteotomy; OWHTO, opening-wedge high tibial osteotomy; OWHTO (-), OWHTO without LHF; OWHTO (+), OWHTO with LHF

Table 6 Comparison of Knee Injury and Osteoarthritis Outcome Score between OWDTO and OWHTO associated with lateral hinge fracture

	OWDTO			OWHTO		
	LFH (+)	LFH (-)	P value	LFH (+)	LFH (-)	P value
Preoperative						
Symptom	62.8 ± 19.5	69.6 ± 18.6	0.43	69.0 ± 16.8	66.3 ± 14.3	0.57
Pain	56.1 ± 17.6	50.6 ± 18.5	0.28	67.7 ± 11.7	62.3 ± 12.5	0.16
ADL	71.5 ± 15.2	75.7 ± 14.8	0.43	77.5 ± 10.6	71.8 ± 14.2	0.15
Sports	36.1 ± 21.7	41.9 ± 30.2	0.60	35.5 ± 14.4	36.8 ± 21.1	0.82
QoL	35.6 ± 22.3	38.3 ± 24.7	0.94	32.2 ± 15.9	33.8 ± 19.3	0.78
Final Follow-up						
Symptom	75.4 ± 16.1	79.2 ± 14.0	0.24	75.6 ± 15.0	83.0 ± 13.3	0.09
Pain	75.9 ± 14.7	78.3 ± 17.2	0.32	76.2 ± 16.1	82.3 ± 11.1	0.14
ADL	82.7 ± 11.8	85.2 ± 11.3	0.31	83.6 ± 9.6	88.4 ± 7.3	0.07
Sports	50.0 ± 26.5	59.1 ± 25.6	0.25	57.9 ± 23.4	67.6 ± 22.0	0.16
QoL	56.5 ± 20.5	62.1 ± 22.5	0.16	56.8 ± 21.3	68.0 ± 19.5	0.08

p value using the Wilcoxon test. OWDTO; open wedge distal tubercle osteotomy, OWHTO; open wedge high tibial osteotomy; LFH (+), presence of a lateral hinge fracture; LFH (-), absence of a lateral hinge fracture

ADL activities of daily living, QoL quality of life

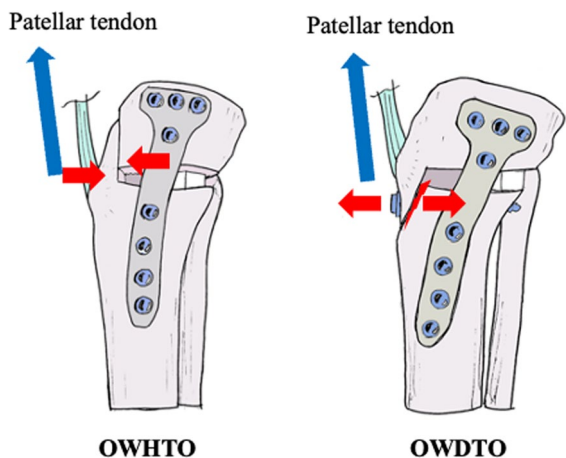


Fig. 5 Mechanism leading to a delayed union at the anterior flange. The anterior flange is compressed by the patellar tendon during knee flexion following OWHTO. By comparison, the anterior flange is pulled apart by the patellar tendon during knee motion after OWDTO. A lateral hinge fracture (LHF) causes greater instability, especially with OWDTO. OWDTO, opening-wedge distal tubercle osteotomy; OWHTO, opening-wedge high tibial osteotomy

OWHTO differed, particularly in terms of patellofemoral cartilage degeneration, which was more severe in the OWDTO group than in the OWHTO group, and thus may have influenced the process of postoperative bone union and clinical outcomes including the Lysholm score and KOOS.

Conclusion

LHF following OWDTO increased the risk of delayed bone union, especially at the anterior flange, and poor clinical outcomes were observed until 12 months post-operatively compared to OWHTO. Rehabilitation programs should be judiciously prescribed when LHF occurs following OWDTO.

Abbreviations

- BMI Body mass index
- CD index Caton-Deschamps index
- CT Computed tomography
- FTA Femorotibial angle
- ICRS International Cartilage Repair Society
- KOOS Knee Injury and Osteoarthritis Outcome Score
- LHF Lateral hinge fractures
- MPTA Medial proximal tibial angle
- OA Osteoarthritis
- OWDTO Opening-wedge distal tubercle osteotomy
- OWHTO Opening-wedge high tibial osteotomy
- PTS Posterior tibial slope
- ROM Range of motion
- WBLR Weight-bearing line ratio

Acknowledgements

We thank Editage for the English language editing of our text.

Authors' contributions

SO, KI and MN study design. SO analyzed the data and wrote the manuscript. KI, TI, YO, HW and MN revised manuscript. All authors agreed to the final version of the manuscript.

Funding

This research did not receive any specific grants from funding agencies in the public, commercial, or not-for-profit sectors.

Declarations

Ethics approval and consent to participate

Ethical approval was obtained from the Institution's review board (no. 2022–023).

Consent for publication

All participants provided written informed consent.

Competing interests

The authors have no conflicts of interest to declare.

Received: 13 August 2023 Accepted: 16 November 2023

Published online: 14 December 2023

References

- Floerkeimer S, Staubli AE, Schroeter S, Goldhahn S, Lobenhoffer P (2013) Outcome after high tibial open-wedge osteotomy: A retrospective evaluation of 533 patients. *Knee Surg Sports Traumatol Arthrosc* 21:170–180
- Lobenhoffer P, Agneskirchner JD (2003) Improvements in surgical technique of valgus high tibial osteotomy. *Knee Surg Sports Traumatol Arthrosc* 11:132–138
- Gaasbeek RDA, Sonneveld H, van Heerwaarden RJ, Jacobs WCH, Wymenga AB (2004) Distal tuberosity osteotomy in open wedge high tibial osteotomy can prevent patella infera: A new technique. *Knee* 11:457–461
- Ogawa H, Matsumoto K, Yoshioka H, Sengoku M, Akiyama H (2020) Fracture of the tibial tubercle does not affect clinical outcomes in medial opening wedge high tibial osteotomy with distal tibial tubercle osteotomy. *Arch Orthop Trauma Surg* 142:607–613
- Otsuki S, Murakami T, Okamoto Y, Nakagawa K, Okuno N, Wakama H, Neo M (2018) Risk of patella baja after opening-wedge high tibial osteotomy. *J Orthop Surg (Hong Kong)* 26:2309499018802484
- Otsuki S, Wakama H, Ikeda K, Okuno N, Okamoto Y, Okayoshi T, Matsuyama J, Neo M (2021) Progression of pelvic retroversion is a critical factor for clinical outcome after Opening-wedge high tibial osteotomy among elderly patients. *J Exp Orthop* 8:65
- Akiyama T, Osano K, Mizu-Uchi H, Nakamura N, Okazaki K, Nakayama H, Takeuchi R (2019) Distal Tibial Tuberosity Arc Osteotomy in Open-Wedge Proximal Tibial Osteotomy to Prevent Patella Infra. *Arthrosc Tech* 8:e655–e662
- Longino PD, Birmingham TB, Schultz WJ, Moyer RF, Giffin JR (2013) Combined tibial tubercle osteotomy with medial opening wedge high tibial osteotomy minimizes changes in patellar height: A prospective cohort study with historical controls. *Am J Sports Med* 41:2849–2857
- Horikawa T, Kubota K, Hara S, Akasaki Y (2020) Distal tuberosity osteotomy in open-wedge high tibial osteotomy does not exacerbate patellofemoral osteoarthritis on arthroscopic evaluation. *Knee Surg Sports Traumatol Arthrosc* 28:1750–1756
- Ogawa H, Matsumoto K, Yoshioka H, Sengoku M, Akiyama H (2020) Distal tibial tubercle osteotomy is superior to the proximal one for progression of patellofemoral osteoarthritis in medial opening wedge high tibial osteotomy. *Knee Surg Sports Traumatol Arthrosc* 28:3270–3278
- Goshima K, Sawaguchi T, Shigemoto K, Iwai S, Nakanishi A, Inoue D, Shima Y (2019) Large opening gaps, unstable hinge fractures, and osteotomy line below the safe zone cause delayed bone healing after open-wedge high tibial osteotomy. *Knee Surg Sports Traumatol Arthrosc* 27:1291–1298
- Van Raaij TM, Brouwer RW, De Vlieger R, Reijman M, Verhaar JAN (2008) Opposite cortical fracture in high tibial osteotomy: Lateral closing compared to the medial opening-wedge technique. *Acta Orthop* 79:508–514
- Takeuchi R, Ishikawa H, Kumagai K, Yamaguchi Y, Chiba N, Akamatsu Y, Saito T (2012) Fractures around the lateral cortical hinge after a medial opening-wedge high tibial osteotomy: A new classification of lateral hinge fracture. *Arthroscopy* 28:85–94
- Choi HG, Kim JS, Jung YS, Yoo HJ, Lee YS (2021) Prediction and Development of Preventive Strategies for Lateral Hinge Fracture During Opening Wedge High Tibial Osteotomy Based on Osteotomy Configurations. *Am J Sports Med* 49:2942–2954
- Lee SJ, Kim JH, Baek E, Ryu HS, Han D, Choi W (2021) Incidence and Factors Affecting the Occurrence of Lateral Hinge Fracture After Medial Opening-Wedge High Tibial Osteotomy. *Orthop J Sports Med* 8:23259671211035372
- Ogawa H, Nakamura Y, Matsumoto K, Akiyama H (2023) Incidence and risk factors for lateral hinge fractures in medial opening wedge high tibial osteotomy and medial opening wedge distal tibial tuberosity osteotomy. *Knee* 44:245–252
- Stoffel K, Stachowiak G, Kuster M (2004) Open wedge high tibial osteotomy: Biomechanical investigation of the modified Arthrex Osteotomy Plate (Puddu Plate) and the TomoFix Plate. *Clinical Biomech* 19:944–950
- Rupp MC, Lindner F, Winkler PW, Muench LN, Mehl J, Imhoff AB, Siebenlist S, Feucht MJ (2023) Clinical Effect of Isolated Lateral Closing Wedge Distal Femoral Osteotomy Compared to Medial Opening Wedge High Tibial Osteotomy for the Correction of Varus Malalignment: A Propensity Score-Matched Analysis. *Am J Sports Med* 51:437–445
- Kim HJ, Lee HJ, Shin JY, Park KH, Min SG, Kyung HS (2017) Preoperative planning using the picture archiving and communication system technique in high tibial osteotomy. *J Orthop Surg (Hong Kong)* 25:2309499016684701
- Hjelle K, Solheim E, Strand T, Muri R, Brittberg M (2002) Articular cartilage defects in 1,000 knee arthroscopies. *Arthroscopy* 18:730–734
- Jeon JW, Jang S, Ro DH, Lee MC, Han HS (2021) Faster bone union progression and less sclerosis at the osteotomy margin after medial opening-wedge high tibial osteotomy using highly porous β -tricalcium phosphate granules versus allogeneic bone chips: A matched case-control study. *Knee* 29:33–41
- Van Hemert WLW, Willems K, Anderson PG, Van Heerwaarden RJ, Wymenga AB (2004) Tricalcium phosphate granules or rigid wedge preforms in open wedge high tibial osteotomy: A radiological study with a new evaluation system. *Knee* 11:451–456
- Tegner Y, Lysholm J (1985) Rating Systems in the Evaluation of Knee Ligament Injuries. *Clin Orthop Relat Res* 198:43–49
- Miller BS, Downie B, McDonough EB, Wojtyls EM (2009) Complications After Medial Opening Wedge High Tibial Osteotomy. *Arthroscopy* 25:639–646
- Ogawa H, Matsumoto K, Akiyama H, Ogawa v H, Surgeon O, Matsumoto v K, Akiyama v H, Joint B (2017) The prevention of a lateral hinge fracture as a complication of a medial opening wedge high tibial osteotomy a case control study. *Bone Joint J* 99:887–893
- Staubli AE, Jacob HAC (2010) Evolution of open-wedge high-tibial osteotomy: Experience with a special angular stable device for internal fixation without interposition material. *Int Orthop* 34:167–172
- Song JH, Bin S il, Kim JM, Lee BS (2021) Unstable Lateral Hinge Fracture or Occult Complete Osteotomy Adversely Affects Correction Accuracy in Open-Wedge High Tibial Osteotomy. *Arthroscopy* 37:3297–3306
- Song KY, Koh IJ, Kim MS, Choi NY, Jeong JH, In Y (2020) Early experience of lateral hinge fracture during medial opening-wedge high tibial osteotomy: incidence and clinical outcomes. *Arch Orthop Trauma Surg* 140:161–169
- Gulagaci F, Jacquet C, Ehlinger M, Sharma A, Kley K, Wilson A, Parratte S, Ollivier M (2020) A protective hinge wire, intersecting the osteotomy plane, can reduce the occurrence of perioperative hinge fractures in medial opening wedge osteotomy. *Knee Surg Sports Traumatol Arthrosc* 28:3173–3182
- Dessyn E, Sharma A, Donnez M, Chabrand P, Ehlinger M, Argenson JN, Parratte S, Ollivier M (2020) Adding a protective K-wire during opening high tibial osteotomy increases lateral hinge resistance to fracture. *Knee Surg Sports Traumatol Arthrosc* 28:751–758
- Didier A, Favreau H, Ollivier M, Jmal H, Bonnet F, Bahlouli N, Martz P, Ehlinger M (2022) Experimental investigation of the risk of lateral cortex fracture during valgus tibial osteotomy. *Orthop Traumatol Surg Res* 108:103428

32. Akiyama T, Okazaki K, Mawatari T, Ikemura S, Nakamura S (2016) Autologous Osteophyte Grafting for Open-Wedge High Tibial Osteotomy. *Arthrosc Tech* 5:e989–e995
33. Ishihara K, Okazaki K, Akiyama T, Akasaki Y, Nakashima Y (2017) Characterisation of osteophytes as an autologous bone graft source. *Bone Joint Res* 6:73–81
34. Ma H-H, Lobenhoffer P, Yang JC-S (2022) The benefits of a percutaneous supplemental screw to reinforce the hinge of a medial open wedge tibial osteotomy. *Arch Orthop Trauma Surg* 143:3707–3713

Publisher's Note

Springer Nature remains neutral with regard to jurisdictional claims in published maps and institutional affiliations.

Submit your manuscript to a SpringerOpen[®] journal and benefit from:

- ▶ Convenient online submission
- ▶ Rigorous peer review
- ▶ Open access: articles freely available online
- ▶ High visibility within the field
- ▶ Retaining the copyright to your article

Submit your next manuscript at ▶ [springeropen.com](https://www.springeropen.com)
