


CASE REPORT

Open Access



Sebaceous carcinoma of the lip: a case report and review of the literature

Michele Di Cosola¹, Francesca Spirito¹, Mariateresa Ambrosino¹, Pasquale Somma², Andrea Santarelli³, Stefania Staibano² and Lorenzo Lo Muzio^{1*} 

Abstract

Background: Sebaceous carcinoma is a very rare, aggressive, malignant tumor arising in the adnexal epithelium of the sebaceous gland. Sebaceous carcinoma in the oral cavity is extremely rare, with only 14 cases reported in literature. We reported the fourth case of sebaceous carcinoma involving the lip

Case presentation: A 71-year-old Caucasian male smoker presented an ulcerated lesion in the lateral region of the lower lip. The patient stated that the lesion had been present for 1 year. The past medical history was unremarkable. Extraoral examination revealed a markedly ulcerated, exophytic, irregularly shaped, indurated mass of the lower right labial region, measuring 1.8 cm in size. The nodular lesion, located at the point of transition between mucosa and skin, showed a central ulceration. No other intraoral lesions were identified. The clinical differential diagnosis included squamous cell carcinoma, basal cell carcinoma with sebaceous differentiation, and salivary gland neoplasms. Operation was performed under local anesthesia. On histopathological examination, the tumor was composed by nodules or sheet of cells separated by a fibrovascular stroma. The neoplastic tissue was deeply infiltrating, involving the submucosa and even the underlying muscle. Neoplastic cells showed a range of sebaceous differentiation with finely vacuolated rather than clear cytoplasm. Neoplastic cells were positive for S-100 protein and epithelial membrane antigen, but negative for carcinoembryonic antigen. Based on these findings, a diagnosis of sebaceous carcinoma of the lower lip was rendered.

Conclusion: The histogenesis, differential diagnosis, and clinicopathological conditions of this disease according to literature are reviewed. Sebaceous carcinoma should be distinguished from other tumors full of vacuolated clear cells. A periodic acid-Schiff stain and immunohistochemical stain for Ki-67, P53, cytokeratin, S-100, epithelial membrane antigen, and androgen receptor can be useful for the diagnosis.

Keywords: Sebaceous carcinoma, Lower lip, Immunohistochemistry, Case report

Introduction

Sebaceous carcinoma (SC) is a rare neoplasm. To date, fewer than 400 cases have been reported in literature. Due to its low incidence and not universally accepted histopathological classification, it can present diagnostic problems [1]. Generally, the lesions arise in the

meibomian glands of the eyelid. However, extraocular localization in the head and neck region has also been reported [1–3]. The salivary glands too are considered an uncommon site, even if some cases arising in the parotid gland have been recognized [4]. While several reports document sebaceous adenomas arising from sebaceous glands of the oral cavity, oral sebaceous carcinomas are extremely rare.

Sebaceous glands in the oral mucosa are widely found in approximately 80% of adults and are called Fordyce granules [5, 6]. Due to their high incidence rate, Fordyce

*Correspondence: lorenzo.lomuzio@unifg.it; lomuziol@tin.it; llomuzio@tin.it

¹ Department of Clinical and Experimental Medicine, University of Foggia, Via Carelli 28, 71100 Foggia, Italy
Full list of author information is available at the end of the article



© The Author(s) 2022. **Open Access** This article is licensed under a Creative Commons Attribution 4.0 International License, which permits use, sharing, adaptation, distribution and reproduction in any medium or format, as long as you give appropriate credit to the original author(s) and the source, provide a link to the Creative Commons licence, and indicate if changes were made. The images or other third party material in this article are included in the article's Creative Commons licence, unless indicated otherwise in a credit line to the material. If material is not included in the article's Creative Commons licence and your intended use is not permitted by statutory regulation or exceeds the permitted use, you will need to obtain permission directly from the copyright holder. To view a copy of this licence, visit <http://creativecommons.org/licenses/by/4.0/>. The Creative Commons Public Domain Dedication waiver (<http://creativecommons.org/publicdomain/zero/1.0/>) applies to the data made available in this article, unless otherwise stated in a credit line to the data.

granules are considered a normal anatomic variation [5, 6]. These granules appear as small asymptomatic yellow–white papules or granules in the oral mucosa. It seems that these intraoral sebaceous glands can rarely give rise to a variety of sebaceous neoplasms, such as sebaceous carcinoma [7]. Since 1991, when Damm *et al.* described the first known report in the English-language literature of sebaceous carcinoma presenting as an intraoral tumor [8], only 14 cases have been described (Table 1) [2, 3, 7–18].

Regardless of the localization, sebaceous malignancies must be considered aggressive neoplasms with potential for regional and distant metastases. Treatment of this tumor points to a wide surgical excision with safe margins. Eventually, implicated regional lymph nodes have to be excised too [19, 20]. Disagreement still exists concerning the efficacy of postsurgical irradiation and/or chemotherapy [1, 19, 20].

We reported herein a case of SC arising in the lateral edge of the lower lip in a 71-year-old man. To the best of our knowledge, this is the fourth case described in lips.

Case report

A 71-year-old Caucasian male smoker presented an ulcerated lesion in the lateral region of the lower lip (Fig. 1A). He had past medical history of tobacco abuse with 15 cigarettes/day smoking history without any other remarkable medical or family history. The patient stated that the lesion had been present for 1 year, but he did not complain of any pain symptoms. No previous trauma in face or mouth was recalled. Extraoral examination revealed a markedly ulcerated, exophytic, irregularly shaped, indurated mass of the lower right labial region, measuring 1.8 cm in size. The nodular lesion, located at the point of transition between mucosa and skin, showed a central ulceration. No other intraoral lesions were identified.

On palpation, the neck was soft with full range of motion, and there was no evidence of lymphadenopathy or tenderness. The patient was in good health and had no evidence of disease.

The clinical differential diagnosis included squamous cell carcinoma, basal cell carcinoma with sebaceous differentiation (BCCSD), and salivary gland neoplasms.

Routine laboratory analysis was performed before surgery, and no abnormal findings were detected.

The operation was performed under local anesthesia. The lesion was removed with 0.5 cm of free margins and a W-shaped wedge. The defect was primarily closed. The postoperative course was uneventful.

Four-micron-thick serial sections were obtained from formalin-fixed, paraffin-embedded surgical specimens. One section was stained with hematoxylin–eosin.

Immunohistochemistry was performed on the remaining serial sections using the labeled streptavidin-biotin complex system (DAKO) to study the expression of epithelial membrane antigen (EMA), S-100 protein, and carcinoembryonic antigen (CEA), using the following primary antibodies: anti-EMA (057 M Biogenex; 1:100), anti-S100 (058 P Biogenex; 1:100), and anti-CEA (365 M Biogenex; 1:100).

On histopathological examination, the tumor was composed by nodules or sheet of cells separated by a fibrovascular stroma. The neoplastic tissue was deeply infiltrating, involving the submucosa and even the underlying muscle (Fig. 1B). Neoplastic cells showed a range of sebaceous differentiation with finely vacuolated rather than clear cytoplasm. Also, areas with squamous differentiation were present. Large nuclei with large nucleoli, as well as scattered and atypical mitoses, were observed (Fig. 1B, inset). Neoplastic cells were positive for S-100 protein (Fig. 1C) and EMA (Fig. 1D), but negative for CEA. Based on these findings, a diagnosis of sebaceous carcinoma of the lower lip was rendered. Following the diagnosis, the patient underwent a complete clinical and radiographic evaluation to identify any regional or distant metastases. Because no metastases were detected, no further treatment was deemed necessary. Follow-up visits were performed every 6 months for 3 years.

All clinical and diagnostic steps are summarized in Table 2.

Discussion

Glands with sebaceous differentiation are often found in the oral cavity, and sebaceous differentiation may also be detected in the major salivary glands. Nevertheless, SC is rare in these anatomic sites [3, 21]. Sebaceous glands may be present in the lip, as described by Miles [21]. Literature data indicate that extraocular sebaceous carcinomas are less aggressive than orbital ones. Furthermore, the former rarely metastasized [19]. However a recent study, involving 2422 cases of SC over 10 years, showed that, among extraocular head and neck SC cases, none of the orbital tumor metastasized to the locoregional lymph nodes whereas two of five cases of extraocular SC metastasized to locoregional lymph nodes [20].

A comprehensive literature review identified only 15 cases of intraoral SC, of which the primary sites reported were the buccal mucosa, mouth floor, upper labial mucosa, palate, gingiva, and tongue. The majority of cases of SC occur on the buccal mucosa (5/15, 22.22%). Other sites include the labial mucosa with 4/15 (26%), anterior floor of mouth with 2/15 (13%), gingiva with 2/15 (13%), palate with 1/15 (7%), and tongue with 1/15 (7%), with 11/15 being men (73.3%) and 4/15 women (26.7%). The age ranged from 11 to 81 years old (mean

Table 1 Reported cases of primary intraoral sebaceous carcinoma

Authors	Year	Country	Sex	Age (years)	Smoker	Site	Size (cm)	Case	Tumor involving other structures	Treatment	Follow-up (years)
1 Damm et al. [8]	1991	USA	M	53	Unknown	Buccal mucosa (parotid duct)	3	Intraoral sebaceous carcinoma	No	Excision	5
2 Abuzeid et al. [9]	1996	Saudi Arabia	F	11	No	Buccal mucosa	3	Intraoral sebaceous carcinoma	Submandibular salivary gland, two lymph nodes	Excision	2
3 Liu et al. [10]	1997	Taiwan	M	68	Unknown	Buccal mucosa	2.5	Sebaceous carcinoma of buccal mucosa	No	Excision	3
4 Li et al. [11]	1997	Japan	M	78	Yes	Buccal mucosa	3.5	Oral sebaceous carcinoma	Surrounding muscle	Excision	6
5 Handschel et al. [3]	2003	Germany	F	80	No	Anterior floor of the mouth	1.5	Intraoral sebaceous carcinoma	No	Excision	1
6 Alawi et al. [2]	2005	USA	M	66	Yes	Upper lip	1.5	Sebaceous carcinoma of the oral mucosa	No	Excision	1
7 Innocenzi et al. [12]	2005	Italy	F	68	No	Upper lip	2	Sebaceous carcinoma	No	Excision	3
8 Gomes et al. [13]	2007	Brazil	M	55	Yes	Floor of mouth	Not reported	Intraoral sebaceous carcinoma	Mandible body and ramus, masseter muscle	Excision, chemotherapy, radiotherapy	1
9 Wang et al. [14]	2010	USA	M	50	No	Buccal mucosa	4.6	Sebaceous carcinoma of the oral cavity	No	Excision + radiation therapy	<1
10 Oshiro et al. [15]	2010	Japan	M	66	Unknown	Tongue and dorsum	2.5	Primary sebaceous carcinoma of the tongue	Cervical lymph nodes bilaterally, lung	Intraarterial chemotherapy/radiation	Died after 17 months
11 Rowe et al. [16]	2016	USA	M	76	Yes	Anterior maxillary gingiva	3	Intraoral sebaceous carcinoma metastatic to the lung and subcutis	Skin of thigh/buttocks/lungs	Excision + chemotherapy	<1
12 Greenall et al. [17]	2015	UK	M	81	Unknown	Right upper lip	Not reported	sebaceous carcinoma	Soft tissues of the right upper lip, buccal space, retromolar trigone (Fig. 2), pterygo-palatine fossa, and apex of the infratemporal fossa	Palliative radiotherapy	Not reported
13 Wetzell et al. [18]	2015	USA	M	75	Yes	Maxillary gingiva	Not reported	Sebaceous carcinoma	No	Excision	Not reported

Table 1 (continued)

Authors	Year	Country	Sex	Age (years)	Smoker	Site	Size (cm)	Case	Tumor involving other structures	Treatment	Follow-up (years)
14 Lu et al. [7]	2021	China	F	62	Unknown	Soft palate	2	Intraoral sebaceous carcinoma	No	Excision	Not reported
15 Present case	2021	Italy	M	71	Yes	Lip	1.8	Sebaceous carcinoma	No	Excision	3

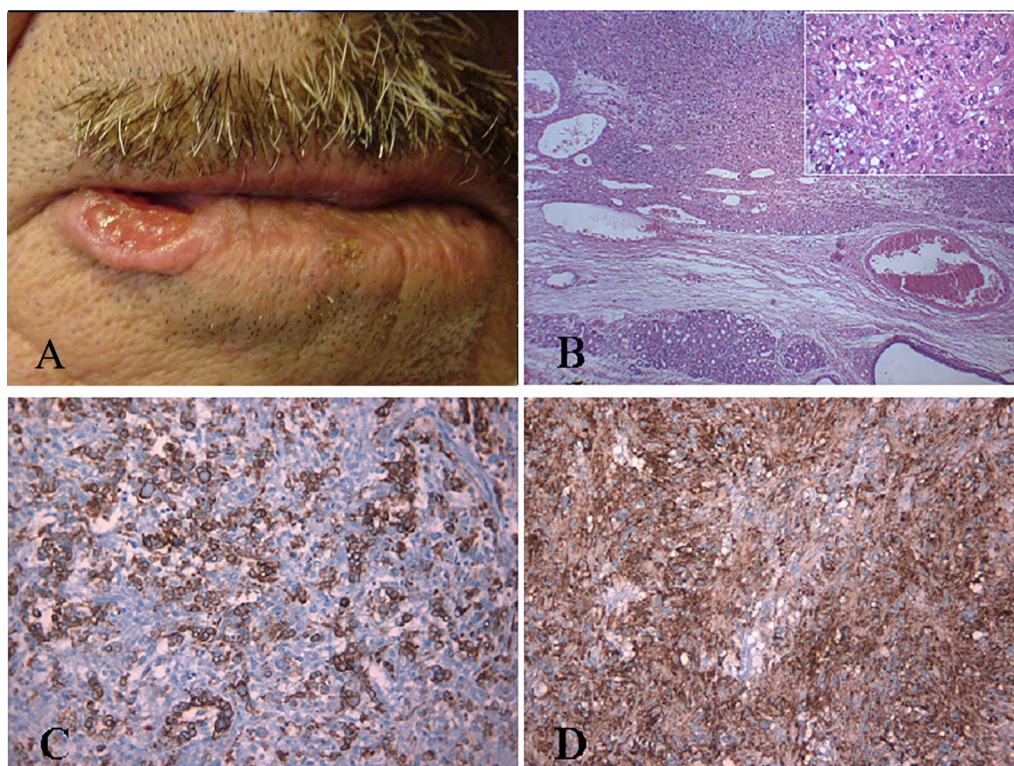


Fig. 1 **A** Clinical features of the lesion before surgical treatment; **B** Submucosal sebaceous carcinoma showing an infiltrative pattern (E&E $\times 40$) and nests of atypical clear cells with scattering squamous differentiation (inset, E&E $\times 400$); **C** The neoplastic cells were positive for S-100 (Avidin/Biotin Method or ABC $\times 200$); **D** The neoplastic cells were positive for epithelial membrane antigen (ABC $\times 200$)

64 years). The reported size of 12 lesions ranged from 1.5 to 4.6 cm (mean 2.55 cm), while 6/15 cases (40%) showed involvement of contiguous sites or presence of metastasis to lymph nodes or lung. Data about smoking seem to be very interesting, with 6/10 being smokers (60%).

In the present case, a diagnosis of oral SC was made based on clinical detection of an ulcerated, exophytic, irregularly shaped, indurated mass on the lower right labial region and histopathological findings of nodules or sheet of cells separated by a fibrovascular stroma, deeply infiltrating, and neoplastic cells showing sebaceous and squamous differentiation. To the best of our knowledge, this is the fourth case of SC of the lip described in literature.

Although SC may be found among the multiple sebaceous neoplasms occurring in association with multiple visceral carcinomas in Muir–Torre syndrome [22], the lip was the only localization of SC in the present case.

SC must be distinguished from basal cell carcinoma with sebaceous differentiation (BCCSD). Basal cell carcinoma is characterized by superficial plate-like proliferation of basaloid and/or squamoid cells, with broad attachments to the overlying epidermis. The cells did

not show high cytological atypia or atypical mitoses. Clusters of mature cells are abruptly interposed among otherwise typical basaloid cell nests, without transitional form [23, 24]. However, differential diagnosis could be particularly difficult because areas of sebaceous differentiation may have similar distribution in both lesions [25]. As in the present case, the involvement of epidermis or dermis favors the diagnosis of SC, but unfortunately is not invariably present [25].

The diagnosis may be facilitated by lipophilic stains on frozen sections or immune stains for EMA and S-100. While SC results diffusely positive for both previously mentioned antibodies, BCCSD shows reactivity only in areas with evident sebaceous differentiation [26–29]. SC must also be differentiated from squamous cell carcinoma (SCC) with hydropic degeneration. However, the latter shows a different pattern of growth. Moreover, cytological atypia and atypical mitoses are more evident and neoplastic cells are positive for cytokeratin and EMA, but negative for S-100 [26, 29].

Like other extremely rare neoplasms, the optimal treatment of SC is not fully conclusive. The therapeutic options range from wide excision to pre- and postoperative radiotherapy with or without chemotherapy [26].

Table 2 Clinical and diagnostic steps

1. Appearance of an ulcerated lesion in the lateral region of the lower lip;
2. After the lesion had been present for 1 year, the patient presented for specialist medical consultation;
3. The patient underwent full examination of oral and extraoral tissues and a markedly ulcerated, exophytic, irregularly shaped, indurated mass of the lower right labial region, measuring 1.8 cm in size, was revealed;
4. An excisional biopsy with 0.5 cm of free margins and W-shaped wedge was performed;
5. Four-micron-thick serial sections were obtained from a formalin-fixed, paraffin-embedded surgical specimen;
6. One section was stained with hematoxylin–eosin for histopathological examination;
7. Immunohistochemistry was performed to study the expression of EMA and CEA;
8. Based on the findings, a diagnosis of sebaceous carcinoma of the lower lip was rendered;
9. Following the diagnosis, the patient underwent a complete clinical and radiographic evaluation to identify any regional or distant metastases.

In our case, wide excision of the lesion was performed without other postoperative therapy. The patient is alive without evidence of recurrence or metastases after 36 months of follow-up.

Conclusion

A rare case of SC in a patient's lip was observed. Radical surgery was carried out. The histogenesis, differential diagnosis, and clinicopathological conditions of this disease according to literature are reviewed. SC should be distinguished from other tumors full of vacuolated clear cells. Useful biomarkers to help verify the diagnosis can be Ki-67, P53, CK, PAS, S-100, EMA, and AR. Postoperative chemotherapy and radiotherapy were not adopted in the present case, as the postoperative pathology showed negative tumor margins and there was no evidence of lymph node metastasis; the patient was relatively satisfied with the surgery.

Acknowledgements

Not applicable.

Author contributions

AM and LLM reviewed the literature and contributed to manuscript drafting; SA reviewed the literature and contributed to manuscript drafting; SS and SP performed pathological analyses and interpretation and contributed to manuscript drafting; DCM reviewed the literature and drafted the manuscript. All authors read and approved the final manuscript.

Funding

This research did not receive any specific grant from funding agencies in the public, commercial, or not-for-profit sectors.

Availability of data and materials

Not applicable.

Declarations

Ethics approval and consent to participate

Not required by the relevant ethics committee. The patient signed an informed consent form for the treatment provided.

Consent for publication

Written informed consent was obtained from the patient for publication of this case report and any accompanying images. A copy of the written consent is available for review by the Editor-in-Chief of this journal.

Competing interests

The authors declare that they have no competing interests

Author details

¹Department of Clinical and Experimental Medicine, University of Foggia, Via Carelli 28, 71100 Foggia, Italy. ²Department of Biomorphological and Functional Sciences, University of Naples "Federico II", 80121 Naples, Italy. ³Dipartimento di Scienze Cliniche Specialistiche e Odontostomatologiche, Università Politecnica delle Marche, 60121 Ancona, Italy.

Received: 13 September 2021 Accepted: 28 April 2022

Published online: 18 June 2022

References

1. Bailet JW, Zimmerman MC, Arnstein DP, Wollman JS, Mickel RA. Sebaceous carcinoma of the head and neck. Case report and literature review. *Arch Otolaryngol Head Neck Surg.* 1992;118(11):1245–9.
2. Alawi F, Siddiqui A. Sebaceous carcinoma of the oral mucosa: case report and review of the literature. *Oral Surg Oral Med Oral Pathol Oral Radiol Endod.* 2005;99(1):79–84.
3. Handschel J, Herbst H, Brand B, Meyer U, Piffko J. Intraoral sebaceous carcinoma. *Br J Oral Maxillofac Surg.* 2003;41(2):84–7.
4. Eshal Leal F, Garcia-Rostan y Perez GM, Garatea Crelgo J, Gorriaran Terberos M, Arzo Sainz de Murieta E. Sebaceous carcinoma of salivary gland. Report of two cases of infrequent location. *An Otorrinolaringol Ibero Am.* 1997;24(4):401–13.
5. Halperin V, Kolas S, Jefferis KR, Huddleston SO, Robinson HB. The occurrence of Fordyce spots, benign migratory glossitis, median rhomboid glossitis, and fissured tongue in 2,478 dental patients. *Oral Surg Oral Med Oral Pathol.* 1953;6(9):1072–7.
6. Miles AE. Sebaceous glands in the lip and cheek mucosa of a man. *Br Dent J.* 1958;105:235–48.
7. Lu Q, Fu XY, Huang Y. Sebaceous carcinoma of the right palate: case report and literature review. *Gland Surg.* 2021;10(5):1819–25.
8. Damm DD, O'Connor WN, White DK, Drummond JF, Morrow LW, Kenady DE. Intraoral sebaceous carcinoma. *Oral Surg Oral Med Oral Pathol.* 1991;72(6):709–11.
9. Abuzeid M, Gangopadhyay K, Rayappa CS, Antonios JI. Intraoral sebaceous carcinoma. *J Laryngol Otol.* 1996;110(5):500–2.
10. Liu CJ, Chang KW, Chang RC. Sebaceous carcinoma of buccal mucosa. Report of a case. *Int J Oral Maxillofac Surg.* 1997;26(4):293–4.
11. Li TJ, Kitano M, Mukai H, Yamashita S. Oral sebaceous carcinoma: report of a case. *J Oral Maxillofac Surg.* 1997;55(7):751–4.
12. Innocenzi D, Balzani A, Lupi F, Panetta C, Skroza N, Cantoresi F, et al. Morpheiform extra-ocular sebaceous carcinoma. *J Surg Oncol.* 2005;92(4):344–6.
13. Gomes CC, Lacerda JC, Pimenta FJ, do Carmo MA, Gomez RS. Intraoral sebaceous carcinoma. *Eur Arch Otorhinolaryngol.* 2007;264(7):829–32.

14. Wang H, Yao J, Solomon M, Axiotis CA. Sebaceous carcinoma of the oral cavity: a case report and review of the literature. *Oral Surg Oral Med Oral Pathol Oral Radiol Endod.* 2010;110(2):e37-40.
15. Oshiro H, Iwai T, Hirota M, Mitsudo K, Tohnai I, Minamimoto R, et al. Primary sebaceous carcinoma of the tongue. *Med Mol Morphol.* 2010;43(4):246-52.
16. Rowe ME, Khorsandi AS, Urken GR, Wenig BM. Intraoral sebaceous carcinoma metastatic to the lung and subcutis: case report and discussion of the literature. *Head Neck.* 2016;38(1):E20-4.
17. Greenall CJ, Drage NA. Sebaceous carcinoma of the lip: comparing normal lip and cheek anatomy with the imaging features of a rare cutaneous malignancy. *Ultrasound.* 2015;23(2):126-9.
18. Wetzel S, Pacelli P, Reich R, Freedman P. Sebaceous carcinoma of the maxillary gingival: first reported case involving the gingiva. *Oral Surg Oral Med Oral Pathol Oral Radiol.* 2015;120(1):e1-3.
19. Duman DG, Ceyhan BB, Celikel T, Ahiskali R, Duman D. Extraorbital sebaceous carcinoma with rapidly developing visceral metastases. *Dermatol Surg.* 2003;29(9):987-9.
20. Bassetto F, Baraziol R, Sottosanti MV, Scarpa C, Montesco M. Biological behavior of the sebaceous carcinoma of the head. *Dermatol Surg.* 2004;30(3):472-6.
21. Miles AEW. Sebaceous glands in the lip and cheek mucosa of man. *Br Dent J.* 1958;105:235-48.
22. Elder D, Elenitas R, Ragsdale BD. Tumors of the epidermal appendage. *Lever's histopathology of the skin.* 8 ed. Philadelphia: Lippincott; 1997. p. 768-9.
23. Friedman KJ, Boudreau S, Farmer ER. Superficial epithelioma with sebaceous differentiation. *J Cutan Pathol.* 1987;14(4):193-7.
24. Lee MJ, Kim YC, Lew W. A case of superficial epithelioma with sebaceous differentiation. *Yonsei Med J.* 2003;44(2):347-50.
25. Wolfe JTI, Wick MR, Campbell RJ. Sebaceous carcinoma of the oculocutaneous adnexa and extraocular skin. In: Wick MR, editor. *Pathology of unusual malignant cutaneous tumors.* New York: Marcel Dekker; 1985. p. 77-106.
26. Rulon DB, Helwig EB. Cutaneous sebaceous neoplasms. *Cancer.* 1974;33(1):82-102.
27. Ohara N, Taguchi K, Yamamoto M, Nagano T, Akagi T. Sebaceous carcinoma of the submandibular gland with high-grade malignancy: report of a case. *Pathol Int.* 1998;48(4):287-91.
28. Ansai S, Hashimoto H, Aoki T, Hozumi Y, Aso K. A histochemical and immunohistochemical study of extra-ocular sebaceous carcinoma. *Histopathology.* 1993;22(2):127-33.
29. Siriwardena BS, Tilakaratne WM, Rajapakshe RM. A case of sebaceous carcinoma of the parotid gland. *J Oral Pathol Med.* 2003;32(2):121-3.

Publisher's Note

Springer Nature remains neutral with regard to jurisdictional claims in published maps and institutional affiliations.

Ready to submit your research? Choose BMC and benefit from:

- fast, convenient online submission
- thorough peer review by experienced researchers in your field
- rapid publication on acceptance
- support for research data, including large and complex data types
- gold Open Access which fosters wider collaboration and increased citations
- maximum visibility for your research: over 100M website views per year

At BMC, research is always in progress.

Learn more biomedcentral.com/submissions

