

CASE REPORT

Open Access



# Elbow flexion reconstruction after arm-sparing excision for high-grade triton sarcoma: a case report

Elise Lupon<sup>1,2\*</sup>, Christine Chevreau<sup>3</sup>, Alexandre Gaston Lellouch<sup>2,4</sup>, Dimitry Gangloff<sup>1,5</sup> and Thomas Meresse<sup>1,5</sup>

## Abstract

**Background:** Soft tissue sarcomas affecting the root of an upper extremity raise the question of limb amputation depending on their location, size, and malignancy. Malignant triton tumors are a rare subtype of neurofibrosarcomas that have been poorly reported in the literature. We report the case of a challenging reconstruction of the upper extremity using a pedicled latissimus dorsal flap.

**Case presentation:** A 25-year-old Occidental man was referred to our sarcoma unit for the management of a large, high-grade malignant peripheral nerve sheath tumor with no regional or distant extension and very fast progression. He was treated first by concomitant neoadjuvant radiotherapy and chemotherapy. Carcinologic excision was performed “en bloc” including the skin, the tumor, and the flexor muscles of our patient’s elbow. Coverage of the skin defect and elbow flexion restoration were achieved by using a homolateral pedicled musculocutaneous latissimus dorsi flap. Histological analysis showed an R0 resection. The reconstruction process recovered a complete bending of his elbow. He is still in remission at 26 months follow-up.

**Conclusions:** A malignant triton tumor is a rare, aggressive, and high-grade sarcoma. It was successfully treated and this case report describes an effective treatment modality. Reconstructive surgery, allowing large, complete tumor removal, is indispensable after neoadjuvant chemotherapy and radiotherapy.

**Keywords:** Malignant peripheral nerve sheath tumor, Malignant triton tumor, Neurofibrosarcoma, Rhabdomyoblastic differentiation

## Introduction

Sarcomas are rare malignant tumors associated with a unfavourable prognosis. They can affect all tissues and there are many histological forms. Limbs represent 65% of the locations: 50% at the lower extremity and 15% at the upper extremity [1]. Sarcomas of the root of limbs raise the question of amputation of the affected limb

depending on their location, size, and malignancy [2–4]. Malignant peripheral nerve sheath tumors (MPNSTs) are a rare anatomopathological subtype of soft tissue sarcomas (STSs), which account for approximately 2% of cancers; MPNSTs have an incidence estimated at between 4 and 5 cases/100,000 [5] and account for approximately 2% of STSs [6, 7]. In approximately 15% of cases, there are heterotopic elements. MPNSTs with heterotopic elements that are striated muscle fibers are called triton tumors; they are mainly described in patients with neurofibromatosis type 1 (NF1) with aggressive behavior [8]. The therapeutic management modalities of MPNST do not present any specificity and are similar to the recommendations defined for all STSs [9], with the

\* Correspondence: [elupon@mgh.harvard.edu](mailto:elupon@mgh.harvard.edu)

<sup>1</sup>Department of Plastic surgery, University Toulouse III Paul Sabatier, Toulouse, France

<sup>2</sup>Vascularized Composite Allotransplantation Laboratory, Center for Transplantation Sciences, Massachusetts General Hospital, Harvard Medical School, 55 Blossom Street, Boston, MA 02114, USA

Full list of author information is available at the end of the article



© The Author(s). 2020, corrected publication 2020. **Open Access** This article is licensed under a Creative Commons Attribution 4.0 International License, which permits use, sharing, adaptation, distribution and reproduction in any medium or format, as long as you give appropriate credit to the original author(s) and the source, provide a link to the Creative Commons licence, and indicate if changes were made. The images or other third party material in this article are included in the article's Creative Commons licence, unless indicated otherwise in a credit line to the material. If material is not included in the article's Creative Commons licence and your intended use is not permitted by statutory regulation or exceeds the permitted use, you will need to obtain permission directly from the copyright holder. To view a copy of this licence, visit <http://creativecommons.org/licenses/by/4.0/>. The Creative Commons Public Domain Dedication waiver (<http://creativecommons.org/publicdomain/zero/1.0/>) applies to the data made available in this article, unless otherwise stated in a credit line to the data.

following “pivotal” steps: multidisciplinary team discussion (MTD), histologic diagnostic before any treatment [10], and surgical management consisting of complete excision, with microscopically healthy margins (called R0 excision). There have been very few reports of management modalities for triton tumors.

We present the case of a young man with a rare subtype of MPNST with a rhabdo-myo-chondrosarcomatous contingent who was able to keep his affected limb functional because of neoadjuvant radiochemotherapy and large excision surgery with reconstruction in one step.

### Case presentation

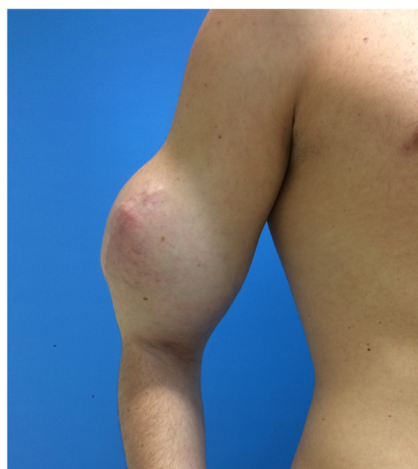A 25-year-old Occidental man was referred to our sarcoma unit after an inadequate “whoops” surgery excision for a 5.3 cm mass of the biceps brachial muscle of his right dominant upper extremity. A histological analysis revealed a high-grade MPNST sarcoma. He had no significant past medical history. He smoked half a pack of cigarettes a day for 5 years. No case of NF1 had been found in his past family history. A chest computed tomography (CT) scan and positron emission tomography (PET) scan work-up for spread were negative, and a postoperative magnetic resonance imaging (MRI) was performed. The tumor was staged T2N0M0 according to the TNM classification.

Our multidisciplinary staff decided to start a neoadjuvant radio-chemotherapy treatment, which was urgent in view of the aggressivity of the tumor, the incomplete initial surgery, and the macroscopic residue shown on the MRI. Our patient initially refused this treatment. He came back 5 months later with a voluminous painful and fast-growing mass affecting the anterolateral surface of

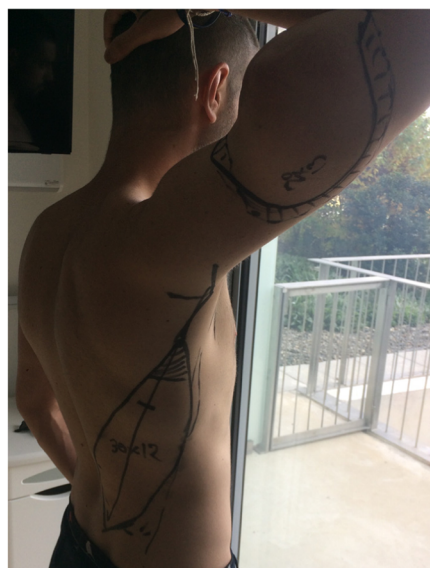his arm with a radial paralysis. The tumor worsened and was evaluated T3bN0M0 at this time. He finally accepted the treatment.

Chemotherapy with an anthracycline and ifosfamide, that is Adriamycin (doxorubicin) and Holoxan (ifosfamide), and concomitant radiotherapy were administered. More specifically, four cycles of doxorubicin and ifosfamide, including 3 days of treatment every 21 days, were administered. Regarding radiotherapy, our patient received 50.4 Gray in 28 fractions of 1.8 gray each.

The surgical procedure was planned 6 weeks after the last radiotherapy session (Fig. 1). A MRI showed a tumor with a 15 cm long axis and the different ratios of the tumor to the neurovascular elements were specified (Fig. 2). The surgery was performed in lateral decubitus. Carcinologic excision was performed “en bloc” removing all tissues surrounding the tumor. A macroscopically complete resection was performed, without fragmentation or visualization of the tumor (Fig. 3). The removal of elbow flexor muscles, long head of the biceps muscle, coracobrachialis muscle, anterior brachial muscle, and brachioradial muscle, was necessary. A part of the deltoid muscle and the short head of the triceps were also removed without major consequences to their function. The vascular and nerve pedicles could all be preserved, except the musculocutaneous nerve. The resection was carried out deep down to the bone with removal of the periosteum. Distally, the vessels and nerves were released up to elbow groove and the tendon of the long head of the biceps brachii was preserved. After tumor resection, the tissue defect was extensive (Fig. 4).

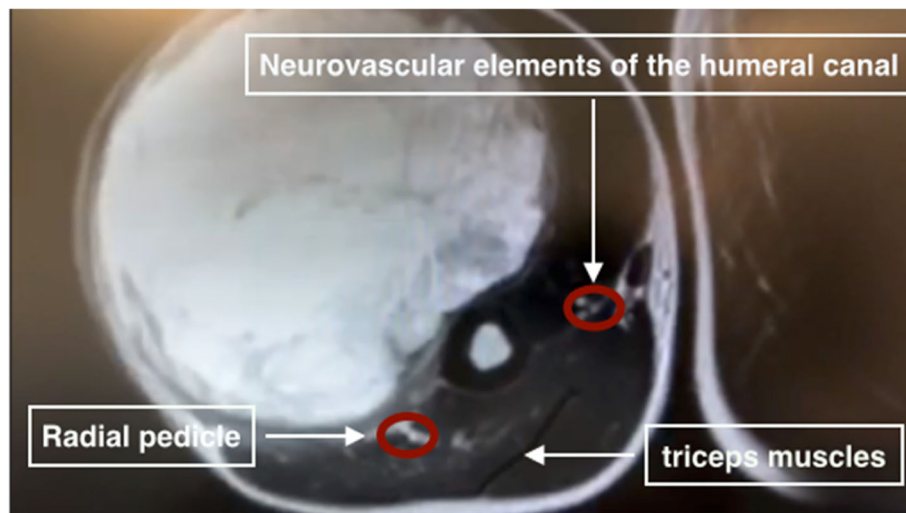


A.



B.

**Fig. 1** Tumor removal planned with reconstruction by a large dorsal musculocutaneous flap. **a** Tumor in place, front view. **b** Preoperative drawing of the tumor removal and pallet of the large dorsal muscle, dorsal view



**Fig. 2** Imaging of the tumor and its relationship to peripheral neurovascular elements

The skin coverage and elbow flexion restoration were performed by a large homolateral pedicled latissimus dorsi (LD) flap with a large vertical skin island (30 × 12 cm). The LD muscle was harvested with its distal insertion fascia, on the iliac crest, in order to create a neotendon. There was no detachment of the LD muscle from his humeral tendon. A subcutaneous tunnel was made under the remaining skin of his arm and the flap could go from the back to his arm. Reconstruction of the flexion of his elbow was done suturing the remaining tendon of the biceps brachial muscle to the LD flap neotendon. The donor site was closed with high tension because of lack of laxity in this young patient.

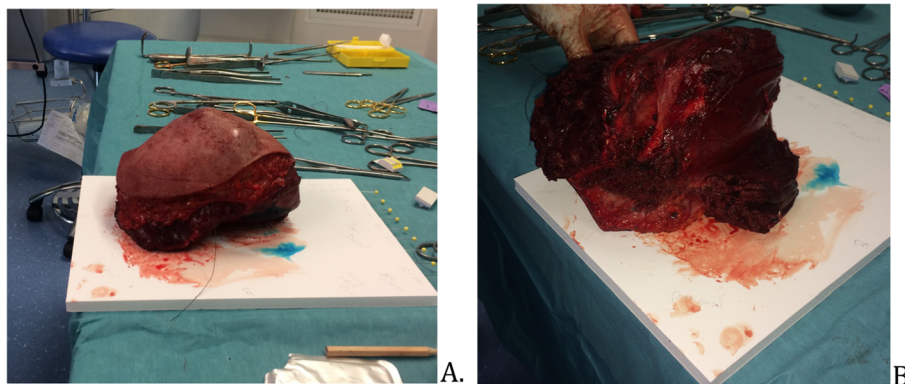
The mass was sent to histology, showing a complete excision of the tumor R0 with a minimum margin of 0.5 mm against the humeral impression including the interposition of the periosteum (Fig. 5), other margins were: 4 mm opposite the impression of the radial nerve, 9 mm laterally, and more than 10 mm in the other directions.

This high-grade spindle cell and pleomorphic sarcoma had a dual heterologous component of cartilage and striated muscle type and long bundles of nerve appearance in some areas. This was a rare subtype of sarcoma: a malignant triton tumor (MTT) or MPNST with heterologous chondrosarcomatous and rhabdomyosarcomatous heterologous contingent. There was 50% necrosis and 25% viable tumor cells indicating a partial therapeutic response to chemotherapy. No postoperative complication was noticed (Fig. 6). Our patient was healed at a 3-week postoperative consultation.

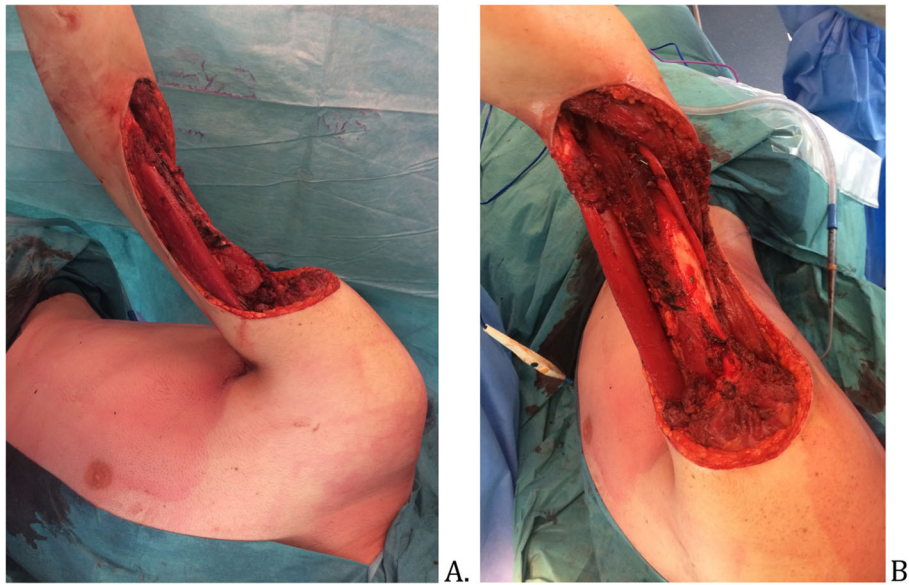
Physiotherapy was started at 6 weeks. At 6 months, he was able to get back to work and physical activity. He recovered a full range of motion of the elbow (video 1). The average active bending of the elbow was 140°. At 2-year follow-up, no recurrence was diagnosed (local MRI and thoracic CT scan).

### Discussion

We report the case of a young man with a MTT. He had a limb-sparing excision with functional reconstruction



**Fig. 3** Surgical part enclosed in healthy tissues, with an invisible tumor. **a** External view. **b** Internal view

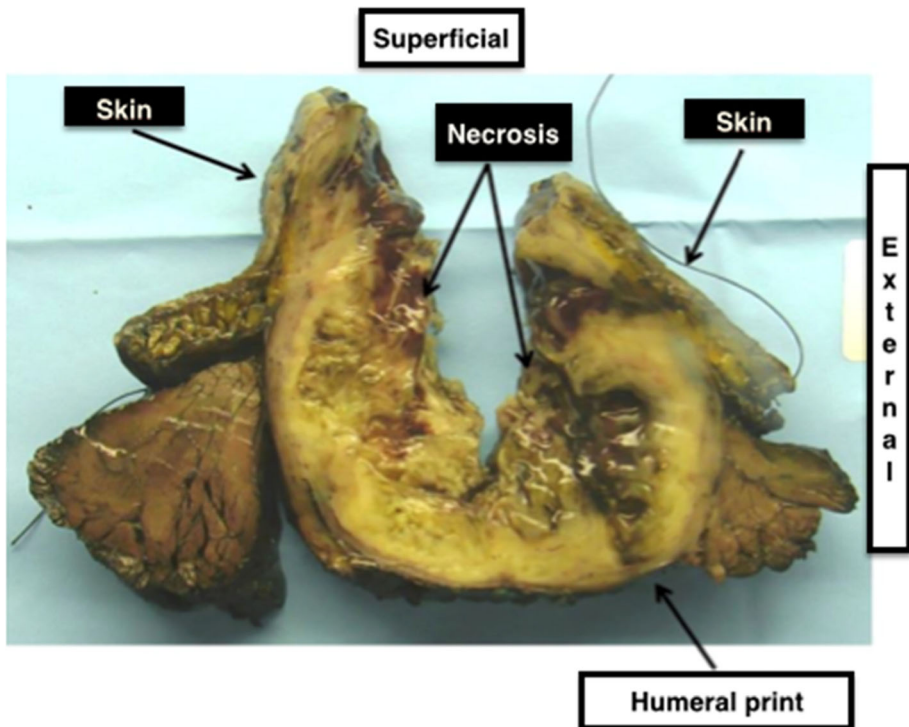


**Fig. 4** Skin defect after tumor resection. **a** Profile view. **b** Front view

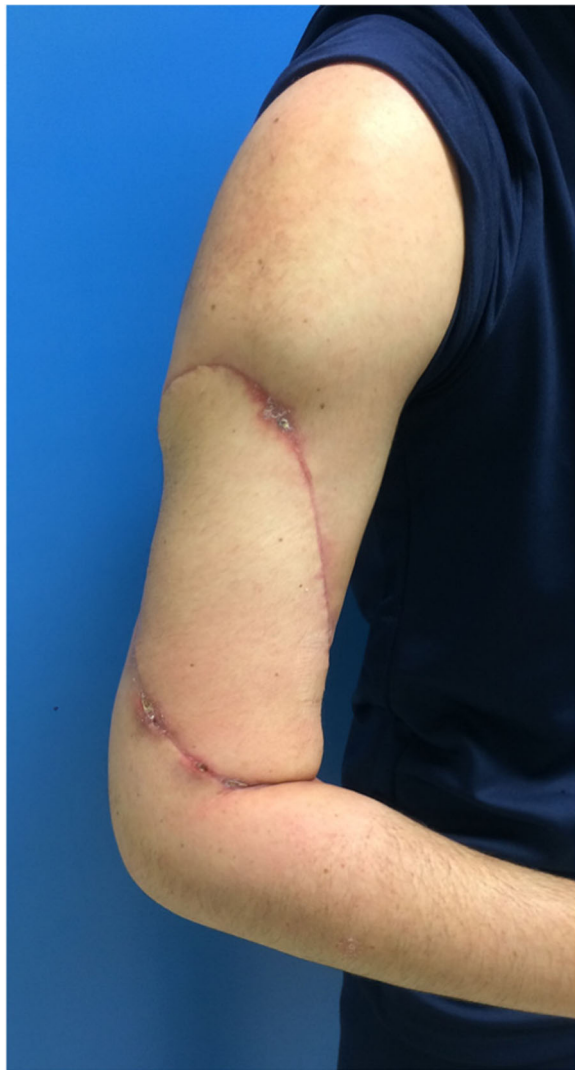and kept a full range of motion. We share this case because triton tumors are very rare and few cases are reported.

MTT is a rare subtype of MPNST; it is a neurogenic tumor in which the neurological component induces the

production of skeletal muscle [8, 11]. This composite neoplasia was initially described by Masson and Martin in 1938; this tumor is extremely rare, with less than 100 cases reported to date [12]. It mainly manifests itself at the cephalic, cervical, and trunk levels. The diagnosis is



**Fig. 5** Histological analysis of the tumor



**Fig. 6** Postoperative flap aspect

based on the presence of malignant rhabdomyoblasts and Schwann cells [13]. The head and neck are the most frequent sites of damage (one-third of lesions), followed by the trunk and lower limbs [14]. Usually seen in people under 35 years of age, the prognosis for MTT is much worse than that of MPNST with an expected 5-year survival rate of 12.5% [15–17]. The sporadic appearance of MTTs in the upper limbs, without NF1 or prior irradiation, is rarely described in the literature. The estimated incidence of MPNST in patients with NF1 is 2 to 5% compared to 0.0001% in the general population and approximately 69% of reported cases of MTT are associated with von Recklinghausen disease [18]. The pathogenesis of sporadic MPNST is poorly known, but the available data suggest different genetic abnormalities from MPNST on NF1, the main one being the independence of NF1 loss in more than half of cases [19].

Cytogenetic studies have revealed some karyotypic changes associated with this tumor. There is a break in 11p15, considered a region of myogenic differentiation. This gene is probably responsible for rhabdomyoblastic differentiation. The amplification of *c-myc* oncogene is probably responsible for its aggressive biological behavior [20, 21]. There are still too many errors in initial management, as was the case for our patient, who is nevertheless a crucial and well-documented case [9], which can lead to a significant loss of opportunity for patients [22–25].

There are no specific guidelines for the management of MTTs and therefore the guidelines used are those for STSs. International recommendations have been established to manage such tumors, in an attempt to standardize the therapeutic approach to sarcomas and to get better results [9, 26–28].

A consensus appeared: as soon as a sarcoma tumor is suspected, a thorough imaging assessment must be associated with a biopsy to allow preparation of the surgical procedure in the framework of a multidisciplinary consultation. The excision should take off the whole tumor en bloc. The adjuvant treatment may include radiotherapy and chemotherapy after multidisciplinary consultation.

Thus, the management of MTTs is that of high-grade sarcomas according to the classification of sarcomas by the National Federation of Cancer Control Centers [29]. The only curative treatment for MPNST and most of the prognoses of sarcomas, in the event of a negative extension assessment, are based on broad, complete surgical excision. This corresponds to surgery with a margin of healthy peritumoral tissue, with microscopically healthy removal limits (R0). This surgery must be planned, once the anatomopathological diagnosis has been made, and performed by a surgeon specialized in the management of sarcomas. We had thus scheduled our surgery in a multidisciplinary consultation meeting 6 weeks before the last sessions of the neoadjuvant treatment and the surgical strategy had also been anticipated at the start of treatment at the first surgical consultation. Unplanned resection (whoops surgery) remains a common problem in the management of sarcoma and can seriously compromise the patient's vital prognosis by increasing morbidity and worsening surgical outcomes [30]. The surgical tumor margin (STM) is the most important measure of sarcoma treatment success, but the definition of the STM has remained a source of controversy. In fact, there is a multitude of literature on sarcoma excision and local recidivism and the margin classifications used vary considerably.

Our resection has been classified R0 according to the Union for International Cancer Control classification. There was an area where the nerve was only separated from the tumor by fat, leaving doubt about R1 excision

on histological analysis. This risk, anticipated on imaging and identified during the operation, was accepted because in the worst case it would have corresponded to a programmed R1 resection. In fact, the Toronto Margin Context Classification does not find any significant difference in long-term survival between a programmed near-positive margin excision (R1) and a healthy margin excision (R0) [31].

However, this lack of consistency between and within margin classification systems has been highlighted [32]. We believe that there is no quantified margin to be respected. The main part of this surgery consists in taking with the tumors intact an anatomical unit of interposition (which is often a fascia), as shown by some authors [33, 34]. This concept derives from the work of Enneking *et al.* [35] in which a reactive zone around sarcomas contains tumor cells. This work specifies that resection through this layer is a “marginal” excision, while surgery outside this layer is called “broad.” When an entire compartment is resected, then the resection is considered radical. If the tumor itself is pierced at any stage, then this is considered intralesional excision [36]. In fact, very high levels of local control (94%) can be achieved in STSs with negative margins [37]. Chemotherapy can significantly improve this margin [38, 39]. The indications for adjuvant and neoadjuvant treatments do not present any specificity for MPNST compared to STSs in general. The principle of neoadjuvant treatment is discussed (depending on age, grade, lesioned topography, that is, suprafascial or subfascial plane tumor) in the presence of a disease that cannot be re-secured from the outset, or of excision requiring mutilating surgery. It must be discussed on a case-by-case basis, in a multidisciplinary consultation meeting [7–9]. Currently, there are no recommendations for chemotherapy in MTTs. Our center opted, in a multidisciplinary consultation meeting, to carry out neoadjuvant radiochemotherapy. The objective of this preoperative chemotherapy was to reduce tumor size and optimize the surgical procedure. The tumor decreased by 5 cm and a recovery of radial paralysis was gradually observed after the initiation of chemotherapy and it was, and argued to be, as conservative as possible on the radial nerve which was probably compressed by the tumor rather than invaded. A recent study showed that preoperative neoadjuvant chemotherapy for the treatment of sarcoma significantly improves limb recovery, disease control, and overall survival, and is an effective and safe option for patients with osteosarcoma [40]. We believe that when surgical reconstruction is possible downstream, neo-chemotherapy and neo-radiotherapy are justified and optimal in the conservative treatment of these high-grade STSs. The authors of the few publications concerning MTT have different recommendations for radiochemotherapy and no optimal strategy has been determined [41–43]. In fact, given the rarity of MTTs, no large-scale

trials have been conducted to assess the appropriateness of adjuvant therapy. It was pointed out that reports on successfully processed MTT cases are useful in helping to establish an effective treatment modality [41].

With advances in chemotherapy and surgical techniques, the trend in the treatment of sarcomas continues to progress towards limb conservation [4]. When the limb can be conserved, however, there are challenging problems with the coverage of loss of tissues and loss of function that can be caused by tumor ablation. Plastic surgery allows, for the surgery of limb sarcomas, the avoidance of amputation because of a wide, optimal, and uncompromising excision while ensuring the coverage of the loss of substance and rebuilding function. Plastic surgery is therefore today an essential specialty in a sarcoma referral center. In our case, the loss of the anterior muscle compartment would have compromised the possibility of bending the elbow. However, elbow flexion is a vital function in daily life, especially when reaching for the mouth and dressing alone. We chose a coverage and reconstruction of the elbow flexion by a large dorsal musculocutaneous flap because it provides a high strength and an active range of motion. There is little morbidity at the donor site (except for crutch users, patients with paraplegia, and those who practice climbing). However, it should be noted that there was a significant and unsightly enlargement of the back-sampling scar in our patient, due to a direct high-tension closure, because of the need for a huge skin paddle on a young adult skin with very little laxity.

A skin paddle combined with a flap of LD muscle is particularly useful in such cases, as presented here, where there is a defect in the soft tissues of the arm. It is a reliable flap, especially in irradiated areas with a high risk of scarring disorders, which allows the safe coverage of a very large cutaneous defect. The result in terms of flexion recovery is obtained immediately, which allows very early rehabilitation [44]. All other options for coverage by local muscle transfer were not possible due to the size of the area to be covered. Free flaps, which are more difficult to re-innervate than the large pedicled LD flap, were excluded due to the deterioration of the receiving environment through chemotherapy and tissue irradiation.

## Conclusion

MTTs are a rare subtype of high-grade STSs that can affect upper extremities. Reconstructive surgery associated with radiochemotherapy is essential for tumor control, oncologic outcome, and limb function preservation.

## Supplementary information

Supplementary information accompanies this paper at <https://doi.org/10.1186/s13256-020-02384-y>.

**Additional file 1: Video 1.** Postoperative monitoring.

**Acknowledgements**

The authors would like to acknowledge the patient for participating in this study.

**Authors' contributions**

EL analyzed and interpreted available data regarding the disease; had the idea of the publication and wrote the manuscript. CC provided clinical management of the patient from an oncology perspective. AGL contributed by revising the manuscript critically for important intellectual content. DG interpreted available data and revised the manuscript critically for important intellectual content. TM designed and performed plastic surgical flap reconstruction for the patient. All authors have read and approve the final manuscript.

**Funding**

None.

**Availability of data and materials**

The dataset used and analyzed during the current study is available from the corresponding author on reasonable request.

**Ethics approval and consent to participate**

Not required by institution for case report.

**Consent for publication**

The patient has consented to this publication. Written informed consent was obtained from the patient for publication of this case report and accompanying images. A copy of the written consent is available for review by the Editor-in-Chief of this journal.

**Competing interests**

None.

**Author details**

<sup>1</sup>Department of Plastic surgery, University Toulouse III Paul Sabatier, Toulouse, France. <sup>2</sup>Vascularized Composite Allotransplantation Laboratory, Center for Transplantation Sciences, Massachusetts General Hospital, Harvard Medical School, 55 Blossom Street, Boston, MA 02114, USA. <sup>3</sup>Medical Oncology, Comprehensive Cancer Center, Claudius Regaud Institute, Institut Universitaire du Cancer de Toulouse Oncopole, 1, avenue Irène Joliot-Curie, 31059 Toulouse, France. <sup>4</sup>Department of Plastic Surgery, European George Pompidou Hospital, University of Paris, Paris, France. <sup>5</sup>Department of Plastic Surgery, Institut Universitaire du Cancer de Toulouse Oncopole, Institut Claudius Regaud, 1, avenue Irène Joliot-Curie, 31059 Toulouse, France.

Received: 9 January 2020 Accepted: 2 April 2020

Published online: 04 July 2020

**References**

- Bui B-N, Blay J-Y, Bonichon F, Bonvalot S, Chevalier-Place A, Coindre J-M, et al. Standards, Options et Recommandations 2006. Prise en charge des patients adultes atteints de sarcome des tissus mous, de sarcome utérin ou de tumeur stromale gastro-intestinale. *Oncologie*. 2007;9(2):173–7.
- Clark MA, Thomas JM. Major amputation for soft-tissue sarcoma. *Br J Surg*. 2003;90(1):102–7.
- Kristen H, Knahr K, Salzer M. Atypical amputations of bone tumors of the lower extremity (author's transl). *Arch Orthop Unfallchir*. 1975;83(1):91–107.
- Traven SA, Brinton DL, Walton ZJ, Leddy LR. A propensity-score matched analysis of limb salvage vs amputation for osteosarcoma. *J Surg Oncol*. 2019;120:1252–8.
- Ng VY, et al. Incidence and survival in sarcoma in the United States: a focus on musculoskeletal lesions. *Anticancer Res*. 2013;33(6):2597–604.
- Durbin AD, Ki DH, He S, Look AT. Malignant Peripheral Nerve Sheath Tumors. *Adv Exp Med Biol*. 2016;916:495–530.
- Valentin T, Le Cesne A, Ray-Coquard I, Italiano A, Decanter G, Bompas E, Isambert N, Thariat J, Linassier C, Bertucci F, Bay JO, Bellesoeur A, Penel N, Le Guellec S, Filleron T, Chevreau C. Management and prognosis of malignant peripheral nerve sheath tumors: The experience of the French Sarcoma Group (GSF-GETO). *Eur J Cancer*. 2016;56:77–84.
- Stasik CJ, Tawfik O. Malignant peripheral nerve sheath tumor with rhabdomyosarcomatous differentiation (malignant triton tumor). *Arch Pathol Lab Med*. 2006;130(12):1878–81.
- ESMO / European Sarcoma Network Working Group. Soft tissue and visceral sarcomas: ESMO Clinical Practice Guidelines for diagnosis, treatment and follow-up. *Ann Oncol*. 2012;23 Suppl 7:92–9.
- Tuttle R, Kane JM 3rd. Biopsy techniques for soft tissue and bowel sarcomas. *J Surg Oncol*. 2015;111(5):504–12.
- Leroy K, Dumas V, Martin-Garcia N, et al. Malignant peripheral nerve sheath tumors associated with neurofibromatosis type 1: a clinicopathologic and molecular study of 17 patients. *Arch Dermatol*. 2001;137:908–13.
- Enzinger FM, Weiss SW 2nd. C.V. Mosby Company. St. Louis: *Soft Tissue Tumors*; 1988. p. 1230–40.
- Ducatman BS, Scheithauer BW. Malignant peripheral nerve sheath tumor with divergent differentiation. *Cancer*. 1984;54(6):1049–57.
- James JA, Bali NS, Sloan P, Shanks JH. Low Grade malignant triton tumor of the oral cavity. *Oral Surg Oral Med Oral Pathol Oral Radiol Endod*. 2003;95(6):699–704.
- Tumeurs des tissus mous - Groupe Sarcomes FNCLCC - Tome I - 2004 - Tumeurs à cellules fusiformes.
- Brooks JS, Freeman M, Enterline HT. Malignant "Triton" tumors: natural history and immunohistochemistry of nine cases with literature review. *Cancer*. 1985;55(11):2543–9.
- McComb EN, McComb RD, DeBoer JM. Cytogenetic analysis of malignant triton tumor and a malignant peripheral nerve sheath tumor and a review of the literature. *Cancer Genet Cytogenet*. 1996;91(1):8–12.
- Malerba M, Garofalo A. A rare case of nerve-sheath sarcoma with rhabdomyoblastic differentiation (malignant triton tumor). *Tumori*. 2003;89(4 Suppl):246–50.
- Bottillo I, et al. Germline and somatic NF1 mutations in sporadic and NF1-associated malignant peripheral nerve sheath tumours. *J Pathol*. 2009;217(5):693–701.
- Haddadin MH, Hawkins AL, Long P, et al. Cytogenetic study of malignant triton tumor: a case report. *Cancer Genet Cytogenet*. 2003;144:100–5.
- Strauss BL, Gutmann DH, Dehner LP, et al. Molecular analysis of malignant triton tumors. *Hum Pathol*. 1999;30:984–8.
- Kang S, Yoo HJ, Kim HS, Han I. Soft tissue sarcoma misdiagnosed as benign peripheral neurogenic tumor. *J Orthop Sci*. 2015;20(1):180–5.
- Presant CA, Russell WO, Alexander RW, Fu YS. Soft-tissue and bone sarcoma histopathology peer review: the frequency of disagreement in diagnosis and the need for second pathology opinions. The Southeastern Cancer Study Group experience. *J Clin Oncol*. 1986;4(11):1658–61.
- Nicholas RS, Stodell M. An important case of misdiagnosis: keloid scar or high-grade soft-tissue sarcoma? *BMJ Case Rep*. 2014;2014:bcr2014203600.
- Patel A, Davies AM, James SL. Imaging of extremity soft tissue masses: pitfalls in diagnosis. *Br J Hosp Med (Lond)*. 2015;76(6):344–52. <https://doi.org/10.12968/hmed.2015.76.6.344>.
- Cormier JN, Pollock RE. Soft tissue sarcomas. *CA Cancer J Clin*. 2004;54:94–109.
- Von Mehren M, Randall RL, Benjamin RS, et al. Soft Tissue Sarcoma, Version 2.2018, NCCN Clinical Practice Guidelines in Oncology. *J Natl Compr Cancer Netw*. 2018;16(5):536–63.
- Casali PG, Abecassis N, Aro HT, et al. Soft tissue and visceral sarcomas: ESMO-EURACAN Clinical Practice Guidelines for diagnosis, treatment and follow-up. *Ann Oncol*. 2018;29(Suppl 4):iv51–67. [published correction appears in *Ann Oncol*. 2018 Oct 1;29(Suppl 4):iv268–iv269] [published correction appears in *Ann Oncol*. 2018 Oct;29 Suppl 4:iv268–iv269].
- Trojani M, Contesso G, Coindre JM, Rouesse J, Bui NB, de Mascarel A, Goussot JF, David M, Bonichon F, Lagarde C. Soft-tissue sarcomas of adults: study of pathological prognostic variables and definition of a histopathological grading system. *Int J Cancer*. 1984;33(1):37–42.
- Tedesco NS, Henshaw RM. Unplanned Resection of Sarcoma. *J Am Acad Orthop Surg*. 2016;24(3):150–9.
- Gundle KR, Kafchinski L, Gupta S, Griffin AM, Dickson BC, Chung PW, Catton CN, O'Sullivan B, Wunder JS, Ferguson PC. Analysis of Margin Classification Systems for Assessing the Risk of Local Recurrence After Soft Tissue Sarcoma Resection. *J Clin Oncol*. 2018;36(7):704–9.
- Hasley I, Gao Y, Blevins AE, Miller BJ. The Significance of a "Close" Margin in Extremity Sarcoma: A Systematic Review. *Iowa Orthop J*. 2018;38:123–30.
- Grimer RJ. On the effect of setting of a positive surgical margin in soft tissue sarcoma. *Cancer*. 2014;120(18):2803–5.

34. Gerrand CH, Wunder JS, Kandel RA, *et al.* Classification of positive margins after resection of soft-tissue sarcoma of the limb predicts the risk of local recurrence. *J Bone Joint Surg (B)*. 2001;83:1149–55.
35. Enneking WF, Spanier SS, Malawer MM. The effect of the anatomic setting on the results of surgical procedures for soft part sarcomas of the thigh. *Cancer*. 1981;47:1005–22.
36. Enneking WF, Maelle GE. The effect of inadvertent tumour contamination of wounds during the surgical resection of musculoskeletal neoplasms. *Cancer*. 1988;62:1251–6.
37. O'Donnell PW, Griffin AM, Eward WC, *et al.* The effect of the setting of a positive surgical margin in soft tissue sarcoma. *Cancer*. 2014;120:2866–75.
38. Gronchi A, Verderio P, De Paoli A, *et al.* Quality of surgery and neoadjuvant combined therapy in the ISG-GEIS trial on soft tissue sarcomas of limbs and trunk wall. *Ann Oncol*. 2013;24:817–23.
39. Kroep JR, Ouali M, Gelderblom H, Le Cesne A, Dekker TJ, Van Glabbeke M, Hogendoorn PC, Hohenberger P. First-line chemotherapy for malignant peripheral nerve sheath tumor (MPNST) versus other histological soft tissue sarcoma subtypes and as a prognostic factor for MPNST: an EORTC soft tissue and bone sarcoma group study. *Ann Oncol*. 2011;22(1):207–14.
40. Zhu W, Zhu L, Bao Y, Zhong X, Chen Y, Wu Q. Clinical evaluation of neoadjuvant chemotherapy for osteosarcoma. *J BUON*. 2019;24(3):1181–5.
41. Ishikawa M, Chou H, Imamura N, Shimazu Y, Ono K. Malignant triton tumor of the left thoracic cavity: a case report. *J Surg Case Rep*. 2019;2019(8):rjz246.
42. Bruzzone E, Melloni I, Barra S, Fraternali Orcioni G, Cocito L. A rare case of intracranial malignant triton tumor arising in the middle cranial fossa: a case report and review of the literature. *Folia Neuropathol*. 2018;56(3):229–34.
43. Jaing TH, Chuang CC, Jung SM, Wu CT, Tseng CK, Chen CS. Malignant triton tumor of the cervical spine: report of one case and review of the literature. *Pediatr Neonatol*. 2015;56(1):58–61.
44. Stevanovic MV, Cuéllar VG, Ghiassi A, Sharpe F. Single-stage Reconstruction of Elbow Flexion Associated with Massive Soft-Tissue Defect Using the Latissimus Dorsi Muscle Bipolar Rotational Transfer. *Plast Reconstr Surg Glob Open*. 2016;4(9):e1066.

## Publisher's Note

Springer Nature remains neutral with regard to jurisdictional claims in published maps and institutional affiliations.

**Ready to submit your research? Choose BMC and benefit from:**

- fast, convenient online submission
- thorough peer review by experienced researchers in your field
- rapid publication on acceptance
- support for research data, including large and complex data types
- gold Open Access which fosters wider collaboration and increased citations
- maximum visibility for your research: over 100M website views per year

**At BMC, research is always in progress.**

Learn more [biomedcentral.com/submissions](https://biomedcentral.com/submissions)

