

RESEARCH

Open Access



Enlarged NT (≥ 3.5 mm) in the first trimester – not all chromosome aberrations can be detected by NIPT

Malgorzata I. Srebnik^{1*}, Merel C. de Wit², Karin E. M. Diderich¹, Lutgarde C. P. Govaerts¹, Marieke Joosten¹, Maarten F. C. M. Knapen^{2,3}, Marnix J. Bos¹, Gerda A. G. Looye-Bruinsma¹, Mieke Koningen¹, Attie T. J. I. Go², Robert Jan H. Galjaard¹ and Diane Van Opstal¹

Abstract

Background: Since non-invasive prenatal testing (NIPT) in maternal blood became available, we evaluated which chromosome aberrations found in our cohort of fetuses with an enlarged NT in the first trimester of pregnancy (tested with SNP microarray) could be detected by NIPT as well.

Method: 362 fetuses were referred for cytogenetic testing due to an enlarged NT (≥ 3.5 mm). Chromosome aberrations were investigated using QF-PCR, karyotyping and whole genome SNP array.

Results: After invasive testing a chromosomal abnormality was detected in 137/362 (38 %) fetuses. 100/362 (28 %) cases concerned trisomy 21, 18 or 13, 25/362 (7 %) an aneuploidy of sex chromosomes and 3/362 (0.8 %) triploidy. In 6/362 (1.6 %) a pathogenic structural unbalanced chromosome aberration was seen and in 3/362 (0.8 %) a susceptibility locus for neurodevelopmental disorders was found. We estimated that in 2–10 % of fetuses with enlarged NT a chromosome aberration would be missed by current NIPT approaches.

Conclusion: Based on our cohort of fetuses with enlarged NT we may conclude that NIPT, depending on the approach, will miss chromosome aberrations in a significant percentage of pregnancies. Moreover all abnormal NIPT results require confirmatory studies with invasive testing, which will delay definitive diagnosis in ca. 30 % of patients. These figures are important for pretest counseling enabling pregnant women to make informed choices on the prenatal test. Larger cohorts of fetuses with an enlarged NT should be investigated to assess the additional diagnostic value of high resolution array testing for this indication.

Keywords: Array, Microdeletion, NIPT, Nuchal translucency, NT, Submicroscopic chromosomal abnormalities, Prenatal diagnosis

Abbreviations: CNV, Copy number variation; CRL, Crown rump length; CV, Chorionic villi; DD, Developmental delay; GMDD, Generalized mosaicism with discrepant direct results; ID, Intellectual disability; MLPA, Multiplex ligation-dependent probe amplification; NIPT, Non-invasive prenatal test; NT, Nuchal translucency; QF-PCR, Quantitative fluorescence-polymerase chain reaction; RAD, Rapid aneuploidy detection; SL, Susceptibility locus

* Correspondence: m.srebnik@erasmusmc.nl

¹Department of Clinical Genetics, Erasmus Medical Center, Wytemaweg 80, 3015, CN, Rotterdam, The Netherlands

Full list of author information is available at the end of the article



Background

Nuchal translucency (NT) measurement is widely used as a marker of fetal abnormalities both of chromosomal and non-chromosomal origin [1–3]. A fetal NT > 99th percentile is by definition found in about 1 % of pregnancies [4]. Enlarged NT is not only associated with aneuploidies and other chromosome abnormalities, but also with a number of genetic syndromes, as well as with structural congenital anomalies, mainly cardiac defects [3, 5, 6]. The majority of fetuses with NT \geq 3.5 mm have a normal karyotype and the pregnancy outcome is highly dependent on the absence of anomalies on expert fetal ultrasound examination [7]. Since non-invasive prenatal testing (NIPT) in maternal blood became available, we evaluated which chromosome aberrations found in our cohort of fetuses with an enlarged NT in the first trimester of pregnancy (tested with SNP microarray) could be detected by NIPT as well. The results of this study can be used in pre-test counseling, which can be helpful for making informed choice between invasive and non-invasive genetic testing.

Methods

362 women carrying a fetus with an enlarged NT (\geq 3.5 mm) in the first trimester were prospectively referred for Illumina SNP genotyping array as described before [8, 9]. Fetal material was obtained through chorionic villi sampling (311 cases) or amniocentesis (51 cases) after the NT was measured as a part of the first trimester combined screening or as part of the routine first trimester crown rump length (CRL) measurement for pregnancy dating. Samples collected in our central location and 3 satellite hospitals between 1st September 2011 until 31st March 2016 that were routinely referred for SNP array testing (0.15 Mb resolution) were included in this cohort. All cytogenetic tests were done in one central laboratory. This cohort overlaps slightly with the cohort published before [10]. To create a homogenous cohort as much as possible we excluded the following cases:

- fetuses referred for hydrops foetalis,
- fetuses referred for enlarged NT with co-existing congenital anomalies evident on the CRL scan or the NT scan

All samples were tested with QF-PCR or MLPA to detect common aneuploidies (rapid aneuploidy detection - RAD). When RAD detected trisomy 21 or 13, such samples were karyotyped (GTG banding analysis) to assess the recurrence risk. Cases of triploidy or trisomy 18 were not further tested. All cases showing normal RAD results or sex-chromosomal aneuploidy were tested with Illumina SNP array (HumanCytoSNP-12 or Infinium_CytoSNP_850K with analysis resolution of ca. 0.15 Mb) as described before [8].

To answer our research question we have divided chromosome aberrations in the following groups:

- 1) autosomal aneuploidies
- 2) sex-chromosome aneuploidies that may be detected by NIPT when sex-chromosomes analysis is included in the test
- 3) triploidy
- 4) pathogenic structural unbalanced chromosome aberrations (both microscopic and submicroscopic)
- 5) susceptibility loci for neurodevelopmental disorders.

Further, we evaluated which aberrations would theoretically be missed by current NIPT approaches (NIPT tests were not routinely performed in this cohort). To be able to make this assessment, for the purpose of this paper, we assumed that all non-mosaic aneuploidies (both autosomal and sex-chromosomal) would be detectable by current NIPT [11] as well as structural unbalanced aberrations larger than 10 Mb [12, 13]. We report estimated percentages of abnormal cases missed by particular NIPT approaches with Agresti–Coull (adjusted Wald) 95 % confidence intervals, which have higher coverage probability than large-sample Wald intervals, in particular for small proportions [14, 15].

Results

The distribution of chromosomal abnormalities according to NT within the study population is presented in Table 1. The diagnostic flow was shown in Fig. 1. 38 % (137/362) of the cases showed abnormal cytogenetic results, which are presented in Table 2. The most common aberration was trisomy 21 (17 % 63/362) and in total in 28 % (100/362) of the cases an autosomal aneuploidy was detected (trisomy 21, 18 or 13). In 6/362 (1.6 %) a pathogenic unbalanced structural chromosome aberration was found: 5 were microscopically visible (>10 Mb) and 1 was submicroscopic (an atypical 22q11 microdeletion) [16]. There were three cases (3/362, 0.8 %) that showed a susceptibility locus for a neurodevelopmental disorder (2 cases of 15q11 microdeletion and one case of 16p11.2 microdeletion), these aberrations are probably not related to the enlarged NT.

Table 2 also shows the estimated percentage of cases that could be missed by current NIPT approaches in each category of chromosome aberrations. Based on our estimation a chromosomal anomaly would be undetected by NIPT in about 2–10 % of patients, depending on the approach used (Table 3).

Discussion

Nuchal fluid accumulation may be caused by several factors, therefore, diverse genetic abnormalities may be expected in such fetuses. Taking this and numerous advantages of genomic microarrays [17] into account we

Table 1 Distribution of chromosomal abnormalities according to NT within the study population ($n = 362$)

NT in mm	Number of cases in the cohort (%)	Number of cases with chromosome aberrations (% within the category)
3.5–4.4	179 (49 %)	35 (19 %)
4.5–5.4	68 (19 %)	32 (47 %)
5.5–6.4	42 (11.6 %)	30 (71 %)
6.5–7.4	24 (6.6 %)	14 (58.3 %)
7.5–8.4	14 (3.9 %)	6 (43 %)
≥8.5	10 (2.8 %)	6 (60 %)
unknown (hygroma colli, where NT measurement was not specified)	25 (7 %)	14 (56 %)
Total	362	137 (38 %)

have chosen a whole genome SNP array technique for cytogenetic investigations in cases of an enlarged NT [8, 9]. In the present study, we prospectively investigated the frequency of (sub) microscopic aberrations in this group of fetuses. Since non-invasive prenatal testing (NIPT) in maternal blood became available and the patients can face a choice between an invasive and non-invasive testing, we evaluated how high the risks of missing a pathogenic chromosome finding can be in a cohort of fetuses with enlarged NT measurement.

Autosomal aneuploidies and triploidy

Although most of the anomalous fetuses showed trisomy 13, 18 or 21 (100/137, 73 %) and NIPT seems to be an

excellent and safe test with a high positive predictive value in this selected high risk group, there are some drawbacks that have to be taken into account. One has to be aware of the risk of false-negative NIPT results for the common trisomies [18, 19]. 3.5 % of Down/Patau/Edwards syndrome cases would potentially be missed by NIPT due to generalized mosaicism with discrepant direct results (GMDD) [20]. Therefore, as shown in Table 2, at least 3 trisomic cases in the cohort presented in this paper (3.5 % out of 100 cases) would potentially be also missed if this cohort was tested with NIPT as a first-tier test. Additionally, other potential causes for false-negative NIPT results such as a low fetal DNA fraction (e.g. due to a high maternal body mass index) or technical failures, should also be taken into account [21]. The detection of triploidy is problematic as well. Although are SNP approaches are able to detect triploidy [22, 23], in our knowledge, there are no data showing that this could be achieved in assays based on whole genome shallow sequencing.

Sex-chromosome aneuploidies

The second most common group of aberrations in fetuses with an enlarged NT is monosomy X (5.5 % 20/362, Table 2). Gil and colleagues showed that cfDNA tests could detect monosomy X in about 90 % of the cases [24], so at least 2 cases of monosomy X (10 % out of 20 cases) would be missed in this cohort. An accurate non-invasive detection of fetal monosomy X remains problematic due to several reasons. First of all, chromosomal mosaicism is common in sex chromosomal aneuploidy [25]. A low percentage of abnormal cells in the cytotrophoblast and co-existence of different abnormal cell lines may mask the actual chromosome aberration (e.g. 45,X/47,XXX) and lead to false negative results. There is also a maternal factor influencing the results as normal adult females show an age-related loss of X-chromosomes [26]. This mosaicism of chromosome X influences the positive predictive value in case of a monosomy X detection [27]. Moreover, finding sufficient Y-chromosome loci that are informative for copy number quantification may be difficult [28], causing monosomy X detection to be highly dependent on the NIPT method used. These difficulties are reflected in the recent literature that showed very limited follow-up of monosomy X cases diagnosed non-invasively [21, 29]. So although some authors suggest that there are accurate methods to detect fetal sex chromosomal aneuploidy in maternal plasma [30, 31], recent clinical experience shows low positive predictive value for monosomy X. This situation can be expected since the fetal DNA in maternal plasma is derived from the cytotrophoblast of chorionic villi (CV) and cytogenetic studies in CV already showed that sex-chromosomal aneuploidy in the

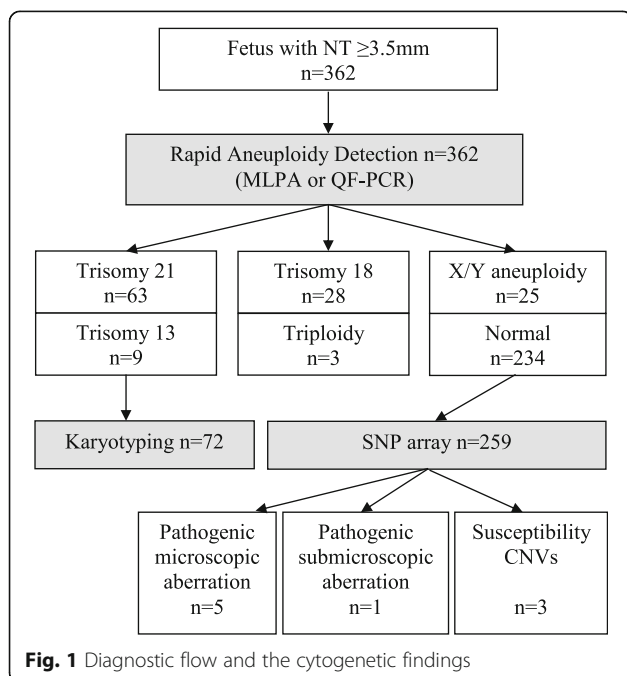
**Fig. 1** Diagnostic flow and the cytogenetic findings

Table 2 Results of cytogenetic testing in fetuses with enlarged NT (≥ 3.5 mm) or hygroma colli in the first trimester in fetuses referred for cytogenetic testing

Type of chromosome aberration	Number of fetuses <i>n</i> = 362	Potential detection by current NIPT approaches	% of anomalies that are going to be missed due to placental mosaicism or current testing resolution (>7–10 Mb)
Autosomal aneuploidy		Yes	3.5 % is likely to be missed [20, 49, 50] 0.8 % (3/362)
Trisomy 21	63 (17 %)		
Trisomy 18	28 (7.7 %)		
Trisomy 13	9 (2.5 %)		
Sex-chromosomal aneuploidy		Yes (if X/Y analysis are included)	10 % of monosomy X are likely to be missed [24] 0.5 % (2/362)
Monosomy X ^a	20 (5.5 %)		Mosaic samples are most probably missed 0.5 % (2/362)
XXX	2 (0.5 %)		
XXY	1 (0.3 %)		
Mosaic X/XY	2 (0.5 %)		
Triploidy	3 (0.8 %)	Yes (if SNP approach is applied)	Most of the current approaches cannot detect triploidy, and so far it is not possible to combine targeted SNP analysis with high coverage and whole genome profiling with high resolution 0.8 % (3/362)
Pathogenic unbalanced chromosome aberrations:	6 (1.6 %)	Larger than 10 Mb Yes (if whole genome profiling with resolution of 10 Mb is applied)	1/6 cases would be potentially missed: 0.3 % (1/362)
1) 46,XY,der [9] t (9;13) (q33.1;q12.11),-13 (NT 4.9 mm; 116 Mb gain at 9p24-q33)			
2) 46,XX,del [8] (p23.1) inv dup [8] (p11.21p23.1) (NT 4.6 mm; 28 Mb gain at 8p)			
3) 45,XX,der [4] t (4;15) (q32.1;q13.3),-15dn (hygroma colli; 34 Mb loss at 4p)			
4) arr [hg19] 9p24.3p22.2 (46,587-18,277,618) x1 (NT 5.2 mm; 18 Mb loss at 9p)			
5) arr [hg19] 1q32.1q44 (202,542,202-249,218,992) x3,9p24.3p24.1 (46,587-7,017,391) x1 (NT 3.6 mm, 47 Mb gain at 1q, 7 Mb loss 9p)			
6) atypical 22q11 microdeletion of paternal origin arr [hg19] 22q11.21 (21,111,299-21,463,730) x1 pat (NT 4.3 mm, >0.5 Mb)			
Susceptibility loci for neurodevelopmental disorders:	3 (0.8 %)	No	So far genome wide detection of submicroscopic aberrations is not feasible. All will be missed 0.8 % (3/362)
1) 15q11 microdeletion of NIPA1/NIPA2 of paternal origin arr [hg18] 15q11.2 (20,191,584-21,025,923) x1pat (NT 4.7 mm)			
2) 15q11 microdeletion of NIPA1/NIPA2 of maternal origin arr [hg19] 15q11.2 (22,299,434-23,272,733) x1mat (NT 4.4 mm)			
3) <i>de novo</i> 16q11.2 microdeletion arr [hg19] 16p11.2 (29,595,483-30,198,151) x1dn (hygroma colli)			
Total number abnormal cases	137 (38 %)		

^aOne case showed also isochromosome Xp (case published before in [51])

cytotrophoblast of CV (STC-villi, short term cultured villi) is often not representative for the actual fetal karyotype [19, 32].

Pathogenic unbalanced structural aberrations

Although an enlarged NT was observed in fetuses with unbalanced translocations, no significant differences were seen in a study that evaluated the role of nuchal translucency (NT) in the prediction of unbalanced translocation in offspring of couples carrying balanced translocations [33]. A recent study of Christiansen and colleagues showed that the distributions for NT measurements in

case of an aberration other than trisomy 21, 13 or 18 more closely resembled that of the normal population [34]. So the detection of rare unbalanced chromosome anomalies in cohorts with an enlarged NT may be co-incidental. Nevertheless karyotypically visible unbalanced chromosome aberrations are likely to be detected by whole genome profiling NIPT approaches [12, 13, 35]. Unfortunately it is difficult to assess how many may be missed due to their mitotic origin and absence in the cytotrophoblast.

The incidence of pathogenic submicroscopic chromosomal abnormalities in fetuses with an enlarged NT has been studied by only few groups [36–41] resulting in

Table 3 Percentage of abnormal cases missed by particular NIPT approaches. Additionally as 3.5 % of trisomy 13, 18 and 21 would be missed due to placental mosaicism 3/362 (0.8 %) cases were included in all NIPT options. As susceptibility CNVs are not the primary reason for invasive testing they were not included in the number of cases with structural anomalies that would be missed by NIPT

Type of NIPT testing	Percentage of patients in our cohort that would show false negative results with NIPT	95 % CI for percentage LL, UL	Number of cases that would be missed in our cohort
Targeted approach for trisomy 13, 18 and 21	10 % (37/362)	7.48, 13.80	34 + 3/362 (20x monosomy X, 5x other sex chromosomal aneuploidy, 3x triploidy, 6x structural anomalies + 3/362 (0.8 %) based on placental mosaicism)
Targeted approach for common aneuploidies of chromosomes 13, 18, 21, X/Y	4 % (14/362)	2.26, 6.44	11 + 3/362 (2x mosaic sex chromosomal aneuploidy, 3x triploidy, 6x structural anomalies + 3/362 (0.8 %) based on placental mosaicism)
Targeted approach for common aneuploidies of chromosomes 13, 18, 21, X/Y and triploidy	3 % (11/362)	1.64, 5.42	8 + 3/362 (2x mosaic sex chromosomal aneuploidy, 6x structural anomalies + 3/362 (0.8 %) based on placental mosaicism)
Whole genome profiling with a resolution of ca. 10 Mb	2 % (7/362)	0.09, 4.02	4 + 3/362 (3x triploidy and 1x submicroscopic anomaly will be missed + 3/362 (0.8 %) based on placental mosaicism)

CI confidence interval, LL lower limit, UL upper limit

conflicting conclusions [42, 43]. These differences in frequencies of chromosomal aberrations in published cohorts were observed before [42] and it may be a consequence of both cohort selection and differences in array design. Many of previously reported cohorts were either retrospectively tested and highly selected [38, 39] or included a heterogeneous group of fetuses with and without additional ultrasound anomalies detected in both first and second trimester [36, 38, 44, 45]. Our results show that the prevalence of submicroscopic aberrations in fetuses with enlarged NT resembles the prevalence in fetuses without ultrasound anomalies. This confirms previous results published by Huang and colleagues [39]. Therefore, in our opinion larger unselected cohorts with enlarged NT should be published to assess the actual risk of a pathogenic submicroscopic unbalanced chromosome aberration when an enlarged NT is diagnosed in the first trimester.

Susceptibility loci for neurodevelopmental disorders

We did not take the susceptibility loci for neurodevelopmental disorders into account for the calculations shown in Table 3. Susceptibility CNVs are quite often found in prenatal array testing [46], however there is no study that showed any relationship with an enlarged NT. Finding additional predisposition factors may play a role in decision making in pregnancy, however it is less likely that one would choose invasive testing with a primary aim to investigate these. Therefore we assume that missing these findings is not the most important incentive for deciding on the prenatal test. Moreover the frequency of susceptibility CNVs in this cohort (0.8 % 3/362) resembles more the frequency in fetuses without

ultrasound anomalies (1.3 %) [47] than those with ultrasound anomalies (2.7 %) [10].

Conclusions

Since most (73 %; 100/137) chromosome aberrations in cases of an enlarged NT (≥ 3.5 mm) in the first trimester involved trisomy 21, 18 and 13, NIPT at first sight seems to be an appropriate test. However, our study confirms the previously published data by Lichtenbelt and colleagues [48] and shows that because of current limitations of NIPT (depending on the type of analysis) in ca. 2–10 % of cases with an enlarged NT a chromosome aberration will be missed by non-invasive testing. Moreover since the risk for a chromosome aberration is high (1:3) and since aberrant NIPT requires confirmatory studies due to the origin of the cfDNA, therefore NIPT as compared to invasive testing will delay a final diagnosis in about 30 % of patients. The limitations of NIPT should be clearly addressed in the pre-test counseling: possible diagnostic delay, the risk for false negative and false positive results and the fact that false-positive cases of monosomy X in enlarged NT fetuses may cause additional anxiety.

Acknowledgements

We would like to thank all clinicians for referring the patients and laboratory technicians for their dedicated work to achieve rapid prenatal results. We would like to thank Marike Polak for the statistical calculations done during the manuscript preparation.

Funding

There was no funding available for this study.

Availability of data and materials

The data supporting the conclusions of this article is included within the article.

Authors' contributions

MIS conceived the study, made substantial contributions to conception and design, analysis and interpretation of genomic data and drafted the manuscript. KEMD, LCPG, MJ, MJB, GAGL, MK and DVO made substantial contributions to acquisition of data, analysis and interpretation of genomic data. MJ, ATJIG and RJHG coordinated the counseling of the patients. MCDw, KEMD, LCPG, MJ, MFCMK and ATJIG made substantial contributions to acquisition of clinical data. MCDw, MFCMK and ATJIG performed pre-test counseling, invasive testing, perinatal management and contributed to the acquisition of phenotypic data (prenatal ultrasound scans). DVO supervised the study and carried literature search. MIS and DVO were responsible for the final diagnoses and reports. All authors revised the manuscript critically for important intellectual content, approved the final version and agreed to be accountable for all aspects of the work in ensuring that questions related to the accuracy or integrity of any part of the work are appropriately investigated and resolved.

Competing interests

The authors declare that they have no competing interests.

Consent for publication

According to the Research Codes of Erasmus MC data that cannot be traced to an individual may be used for research. Patients undergoing prenatal diagnosis at Erasmus MC are informed that we may investigate/publish their medical data as long as all data remained anonymous and cannot lead to the identification of the individual persons. Each patient had the opportunity to object to their inclusion (opting out on the individual request form for the cytogenetic prenatal investigation). No objections were made. All presented data were obtained during routine diagnostic procedure and the researchers are in fact the involved clinicians or laboratory specialists. All presented data are anonymous and do not allow identification of the individual patients.

Author details

¹Department of Clinical Genetics, Erasmus Medical Center, Wytemaweg 80, 3015, CN, Rotterdam, The Netherlands. ²Department of Obstetrics and Gynecology, Erasmus Medical Center, Wytemaweg 80, 3015, CN, Rotterdam, The Netherlands. ³Foundation Prenatal Screening Southwest region of The Netherlands, Wytemaweg 80, Na-1509, 3015, CN, Rotterdam, The Netherlands.

Received: 1 June 2016 Accepted: 26 August 2016

Published online: 07 September 2016

References

- Nicolaides KH, Azar G, Byrne D, Mansur C, Marks K. Fetal nuchal translucency: ultrasound screening for chromosomal defects in first trimester of pregnancy. *BMJ*. 1992;304(6831):867–9.
- Snijders RJ, Noble P, Sebire N, Souka A, Nicolaides KH. UK multicentre project on assessment of risk of trisomy 21 by maternal age and fetal nuchal-translucency thickness at 10–14 weeks of gestation. Fetal medicine foundation first trimester screening group. *Lancet*. 1998;352(9125):343–6.
- Souka AP, Von Kaisenberg CS, Hyett JA, Sonek JD, Nicolaides KH. Increased nuchal translucency with normal karyotype. *Am J Obstet Gynecol*. 2005; 192(4):1005–21.
- Senat MV, Bussieres L, Couderc S, Roume J, Rozenberg P, Bouyer J, et al. Long-term outcome of children born after a first-trimester measurement of nuchal translucency at the 99th percentile or greater with normal karyotype: a prospective study. *Am J Obstet Gynecol*. 2007;196(1):53. e1–6.
- McAuliffe FM, Hornberger LK, Winsor S, Chitayat D, Chong K, Johnson JA. Fetal cardiac defects and increased nuchal translucency thickness: a prospective study. *Am J Obstet Gynecol*. 2004;191(4):1486–90.
- Burger NB, Bekker MN, de Groot CJ, Christoffels VM, Haak MC. Why increased nuchal translucency is associated with congenital heart disease: a systematic review on genetic mechanisms. *Prenat Diagn*. 2015;35(6):517–28.
- Bilardo CM, Muller MA, Pajkr E, Clur SA, van Zalen MM, Bijlsma EK. Increased nuchal translucency thickness and normal karyotype: time for parental reassurance. *Ultrasound Obstet Gynecol*. 2007;30(1):11–8.
- Srebniak MI, Boter M, Oudsluijs GO, Cohen-Overbeek T, Govaerts LC, Diderich KE, et al. Genomic SNP array as a gold standard for prenatal diagnosis of foetal ultrasound abnormalities. *Mol Cytogenet*. 2012;5(1):14.
- Srebniak M, Boter M, Oudsluijs G, Joosten M, Govaerts L, Van Opstal D, et al. Application of SNP array for rapid prenatal diagnosis: implementation, genetic counselling and diagnostic flow. *Eur J Hum Genet*. 2011; 19(12):1230–7.
- Srebniak MI, Diderich KE, Joosten M, Govaerts LC, Knijnenburg J, de Vries FA, et al. Prenatal SNP array testing in 1000 fetuses with ultrasound anomalies: causative, unexpected and susceptibility CNVs. *Eur J Hum Genet*. 2016; 24(5):645–51.
- Boon EM, Faas BH. Benefits and limitations of whole genome versus targeted approaches for noninvasive prenatal testing for fetal aneuploidies. *Prenat Diagn*. 2013;33(6):563–8.
- Straver R, Sistermans EA, Holstege H, Visser A, Oudejans CB, Reinders MJ. WISECONDOR: detection of fetal aberrations from shallow sequencing maternal plasma based on a within-sample comparison scheme. *Nucleic Acids Res*. 2014;42(5):e31.
- Zhao C, Tynan J, Ehrlich M, Hannum G, McCullough R, Saldivar JS, et al. Detection of fetal subchromosomal abnormalities by sequencing circulating cell-free DNA from maternal plasma. *Clin Chem*. 2015;61(4):608–16.
- Agresti A, Coull BA. Approximate is better than “exact” for interval estimation of binomial proportions. *Am Stat*. 1998;52(2):119–26.
- Brown LD, Cai TT, DasGupta A, Agresti A, Coull BA, Casella G, et al. Interval estimation for a binomial proportion - comment - rejoinder. *Stat Sci*. 2001; 16(2):101–33.
- Verhagen JM, Diderich KE, Oudsluijs G, Mancini GM, Eggink AJ, Verkleij-Hagoort AC, et al. Phenotypic variability of atypical 22q11.2 deletions not including TBX1. *Am J Med Genet A*. 2012;158A(10):2412–20.
- Srebniak MI, Van Opstal D, Joosten M, Diderich KE, de Vries FA, Riedijk S, et al. Whole-genome array as a first-line cytogenetic test in prenatal diagnosis. *Ultrasound Obstet Gynecol*. 2015;45(4):363–72.
- Sepulveda W. Discordant results between fetal cell-free DNA in maternal plasma and chorionic villus sampling in a first-trimester fetus with increased nuchal translucency and megacystis. *Ultrasound Obstet Gynecol*. 2014; 44(3):369.
- van den Berg C, Van Opstal D, Polak-Knook J, Galjaard RJ. (Potential) false-negative diagnoses in chorionic villi and a review of the literature. *Prenat Diagn*. 2006;26(5):401–8.
- Van Opstal D, Srebniak MI, Polak J, de Vries F, Govaerts LC, Joosten M, et al. False negative NIPT results: risk figures for chromosomes 13, 18 and 21 based on chorionic villi results in 5967 cases and literature review. *PLoS One*. 2016;11(1):e0146794.
- Dar P, Curnow KJ, Gross SJ, Hall MP, Stosic M, Demko Z, et al. Clinical experience and follow-up with large scale single-nucleotide polymorphism-based noninvasive prenatal aneuploidy testing. *Am J Obstet Gynecol*. 2014; 211(5):527. e1– e17.
- Nicolaides KH, Syngelaki A, Gil M, Atanasova V, Markova D. Validation of targeted sequencing of single-nucleotide polymorphisms for non-invasive prenatal detection of aneuploidy of chromosomes 13, 18, 21, X, and Y. *Prenat Diagn*. 2013;33(6):575–9.
- Ryan A, Hunkapiller N, Banjevic M, Vankayalapati N, Fong N, Jinnett KN, et al. Validation of an Enhanced Version of a Single-Nucleotide Polymorphism-Based Noninvasive Prenatal Test for Detection of Fetal Aneuploidies. *Fetal Diagn Ther*. 2016. [Epub ahead of print]
- Gil MM, Quezada MS, Revello R, Akolekar R, Nicolaides KH. Analysis of cell-free DNA in maternal blood in screening for fetal aneuploidies: updated meta-analysis. *Ultrasound Obstet Gynecol*. 2015;45(3):249–66.
- Forabosco A, Percesepe A, Santucci S. Incidence of non-age-dependent chromosomal abnormalities: a population-based study on 88965 amniocenteses. *Eur J Hum Genet*. 2009;17(7):897–903.
- Russell LM, Strike P, Browne CE, Jacobs PA. X chromosome loss and ageing. *Cytogenet Genome Res*. 2007;116(3):181–5.
- Wang Y, Chen Y, Tian F, Zhang J, Song Z, Wu Y, et al. Maternal mosaicism is a significant contributor to discordant sex chromosome aneuploidies associated with noninvasive prenatal testing. *Clin Chem*. 2014;60(1):251–9.
- Benn P, Cuckle H, Pergament E. Non-invasive prenatal testing for aneuploidy: current status and future prospects. *Ultrasound Obstet Gynecol*. 2013;42(1):15–33.
- Futch T, Spinosa J, Bhatt S, de Feo E, Rava RP, Sehnert AJ. Initial clinical laboratory experience in noninvasive prenatal testing for fetal aneuploidy from maternal plasma DNA samples. *Prenat Diagn*. 2013;33(6):569–74.
- Samango-Sprouse C, Banjevic M, Ryan A, Sigurjonsson S, Zimmermann B, Hill M, et al. SNP-based non-invasive prenatal testing detects sex

- chromosome aneuploidies with high accuracy. *Prenat Diagn.* 2013;33(7):643–9.
31. Yu SC, Chan KC, Zheng YW, Jiang P, Liao GJ, Sun H, et al. Size-based molecular diagnostics using plasma DNA for noninvasive prenatal testing. *Proc Natl Acad Sci U S A.* 2014;111(23):8583–8.
 32. Van Opstal D, Srebniak MI. Cytogenetic confirmation of a positive NIPT result: evidence-based choice between chorionic villus sampling and amniocentesis depending on chromosome aberration. *Expert Rev Mol Diagn.* 2016;16(5):513–20.
 33. Arigita M, Grande M, Mula R, Borobio V, Sanchez A, Soler A, et al. Nuchal translucency thickness in the prediction of unbalanced translocations. *Prenat Diagn.* 2014;34(10):982–5.
 34. Christiansen M, Ekelund CK, Petersen OB, Hyett J, Eastwood N, Ball S, et al. Nuchal translucency distributions for different chromosomal anomalies in a large unselected population cohort. *Prenat Diagn.* 2016;36(1):49–55.
 35. Bayindir B, Dehaspe L, Brison N, Brady P, Ardui S, Kammoun M, et al. Noninvasive prenatal testing using a novel analysis pipeline to screen for all autosomal fetal aneuploidies improves pregnancy management. *Eur J Hum Genet.* 2015;23:1286–93.
 36. Schou KV, Kirchhoff M, Nygaard U, Jorgensen C, Sundberg K. Increased nuchal translucency with normal karyotype: a follow-up study of 100 cases supplemented with CGH and MLPA analyses. *Ultrasound Obstet Gynecol.* 2009;34(6):618–22.
 37. Pan M, Han J, Zhen L, Yang X, Li R, Liao C, et al. Prenatal diagnosis of fetuses with increased nuchal translucency using an approach based on quantitative fluorescent polymerase chain reaction and genomic microarray. *Eur J Obstet Gynecol Reprod Biol.* 2015;197:164–7.
 38. Leung TY, Vogel I, Lau TK, Chong W, Hyett JA, Petersen OB, et al. Identification of submicroscopic chromosomal aberrations in fetuses with increased nuchal translucency and apparently normal karyotype. *Ultrasound Obstet Gynecol.* 2011;38(3):314–9.
 39. Huang J, Poon LC, Akolekar R, Choy KW, Leung TY, Nicolaides KH. Is high fetal nuchal translucency associated with submicroscopic chromosomal abnormalities on array CGH? *Ultrasound Obstet Gynecol.* 2014;43(6):620–4.
 40. Scott F, Murphy K, Carey L, Greville W, Mansfield N, Barahona P, et al. Prenatal diagnosis using combined quantitative fluorescent polymerase chain reaction and array comparative genomic hybridization analysis as a first-line test: results from over 1000 consecutive cases. *Ultrasound Obstet Gynecol.* 2013;41(5):500–7.
 41. Lund IC, Christensen R, Petersen OB, Vogel I, Vestergaard EM. Chromosomal microarray in fetuses with increased nuchal translucency. *Ultrasound Obstet Gynecol.* 2015;45(1):95–100.
 42. de Wit MC, Srebniak MI, Govaerts LC, Van Opstal D, Galjaard RJ, Go AT. Additional value of prenatal genomic array testing in fetuses with isolated structural ultrasound abnormalities and a normal karyotype: a systematic review of the literature. *Ultrasound Obstet Gynecol.* 2014;43(2):139–46.
 43. Grande M, Jansen FA, Blumenfeld YJ, Fisher A, Odibo AO, Haak MC, et al. Genomic microarray in fetuses with increased nuchal translucency and normal karyotype: a systematic review and meta-analysis. *Ultrasound Obstet Gynecol.* 2015;46(6):650–8.
 44. Rooryck C, Toutain J, Cailley D, Bouron J, Horovitz J, Lacombe D, et al. Prenatal diagnosis using array-CGH: a French experience. *Eur J Med Genet.* 2013;56(7):341–5.
 45. Yang X, Li R, Fu F, Zhang Y, Li D, Liao C. Submicroscopic chromosomal abnormalities in Fetuses with Increased Nuchal Translucency and Normal Karyotype. *J Matern Fetal Neonatal Med.* 2016;19:1–5.
 46. Wapner RJ, Martin CL, Levy B, Ballif BC, Eng CM, Zachary JM, et al. Chromosomal microarray versus karyotyping for prenatal diagnosis. *N Engl J Med.* 2012;367(23):2175–84.
 47. Van Opstal D, de Vries F, Govaerts L, Boter M, Lont D, van Veen S, et al. Benefits and burdens of using a SNP array in pregnancies at increased risk for the common aneuploidies. *Hum Mutat.* 2015;36(3):319–26.
 48. Lichtenbelt KD, Diemel BD, Koster MP, Manten GT, Siljee J, Schuring-Blom GH, et al. Detection of fetal chromosomal anomalies: does nuchal translucency measurement have added value in the era of non-invasive prenatal testing? *Prenat Diagn.* 2015;35(7):663–8.
 49. Grati FR, Malvestiti F, Ferreira JC, Bajaj K, Gaetani E, Agrati C, et al. Fetoplacental mosaicism: potential implications for false-positive and false-negative noninvasive prenatal screening results. *Genet Med.* 2014;16(8):620–4.
 50. Taylor-Phillips S, Freeman K, Geppert J, Agbebiyi A, Uthman OA, Madan J, et al. Accuracy of non-invasive prenatal testing using cell-free DNA for detection of Down, Edwards and Patau syndromes: a systematic review and meta-analysis. *BMJ Open.* 2016;6(1):e010002.
 51. Srebniak MI, Bos MJ, de Vries FA, Heydanus R, Wessels MW, Van Opstal D. SNP array detects chromosome aberrations that we thought do not exist: the first case of an isochromosome Xp (i(X)(p10)). *Prenat Diagn.* 2014;34(8):806–8.

Submit your next manuscript to BioMed Central and we will help you at every step:

- We accept pre-submission inquiries
- Our selector tool helps you to find the most relevant journal
- We provide round the clock customer support
- Convenient online submission
- Thorough peer review
- Inclusion in PubMed and all major indexing services
- Maximum visibility for your research

Submit your manuscript at
www.biomedcentral.com/submit

