

CASE REPORT

Open Access



# Pulmonary embolism in a patient with eltrombopag-treated aplastic anaemia and paroxysmal nocturnal haemoglobinuria clone during COVID-19 pneumonia

Alessandro Bosi<sup>1,2</sup>, Wilma Barcellini<sup>1</sup> and Bruno Fattizzo<sup>1,2\*</sup>

## Abstract

Thrombosis in patients with thrombocytopenia has several risk factors, both disease-related and treatment-associated. Recently, COVID-19 infection was recognized as an additional risk factor, further complicating the delicate balance between thrombosis and bleeding in these patients. Here we describe the case of a patient with aplastic anaemia on eltrombopag who developed pulmonary embolism during COVID-19 pneumonia, despite receiving oral anticoagulation with edoxaban. Notably, he was also carrying a large paroxysmal nocturnal haemoglobinuria clone, although without evidence of haemolysis. The presented case recapitulates some of the open questions in thrombotic risk management of cytopenic patients, such as the management of thrombopoietin receptor agonists and the choice of anticoagulation in PNH, while also accounting for the additional thrombotic risk linked to COVID-19.

**Keywords:** Aplastic anemia, Paroxysmal nocturnal hemoglobinuria, COVID-19, Eltrombopag, Thrombosis

## Background

COVID-19 has been associated with an increased incidence of thrombosis and pulmonary embolism [1, 2], even in patients under anticoagulation [3]. This adds to the several known risk factors for thrombosis, complicating the management of haematological conditions with an instable haemostatic balance. Here we report the case of a patient with severe aplastic anaemia (SAA) carrying a paroxysmal nocturnal haemoglobinuria (PNH) clone which is a known thrombophilic condition [4]. The patient developed a major thrombotic event during COVID-19 infection, despite direct oral anticoagulation (DOAC). Additionally, he was receiving a thrombopoietin receptor agonist (eltrombopag), which has been

associated with an increased thrombotic risk in patients with immune thrombocytopenia (ITP) [5].

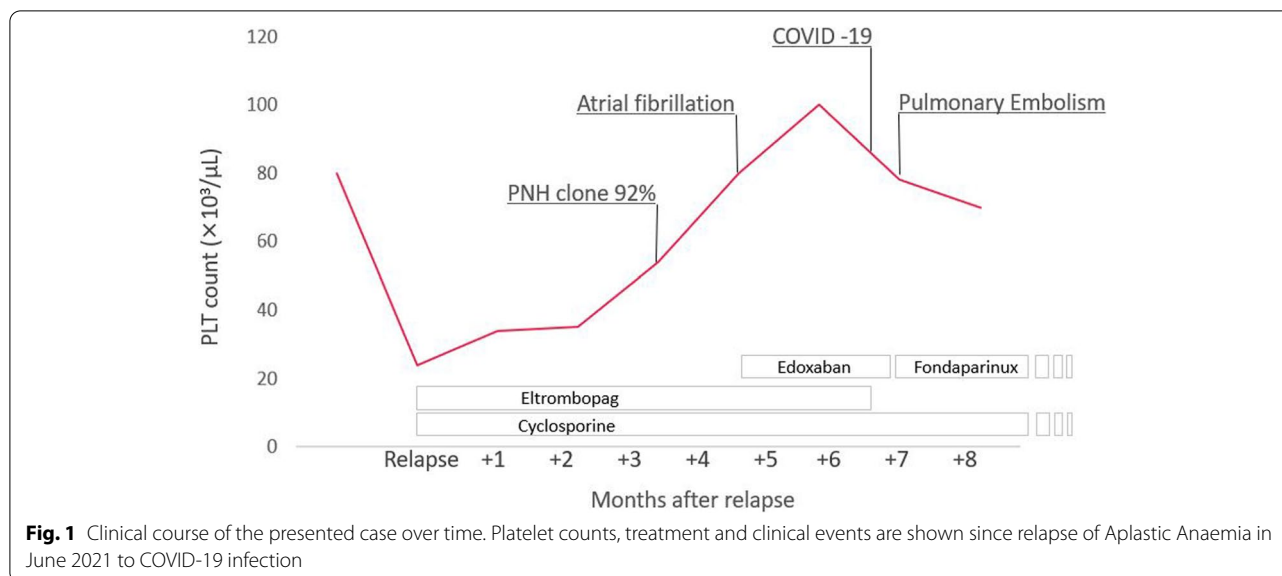
## Case presentation

A 74-year-old Caucasian man was diagnosed with SAA and treated with antithymocyte globulin, cyclosporine A and corticosteroids, which was followed by complete remission. Oral prednisone and cyclosporine were slowly tapered off until complete interruption after 3 years from diagnosis. Seven years later, due to worsening thrombocytopenia (platelets, PLT:  $24 \times 10^3/\mu\text{L}$ ), a bone marrow trephine biopsy was repeated, showing hypocellularity (15–20%), absence of megakaryocytes and a polyclonal T-cell infiltrate (15% of cellularity). A relapse of aplastic anaemia was diagnosed and oral cyclosporine (2.5 mg/kg day), combined with low-dose prednisone and eltrombopag (150 mg/day after initial up-titration) were initiated, leading to a progressive increase of PLT count (Fig. 1). Additionally, fluorescent aerolysin (FLAER)

\*Correspondence: bruno.fattizzo@unimi.it

<sup>1</sup> Haematology Unit, Fondazione IRCCS Ca' Granda Ospedale Maggiore Policlinico, Via Francesco Sforza 35, 20100 Milan, Italy  
Full list of author information is available at the end of the article





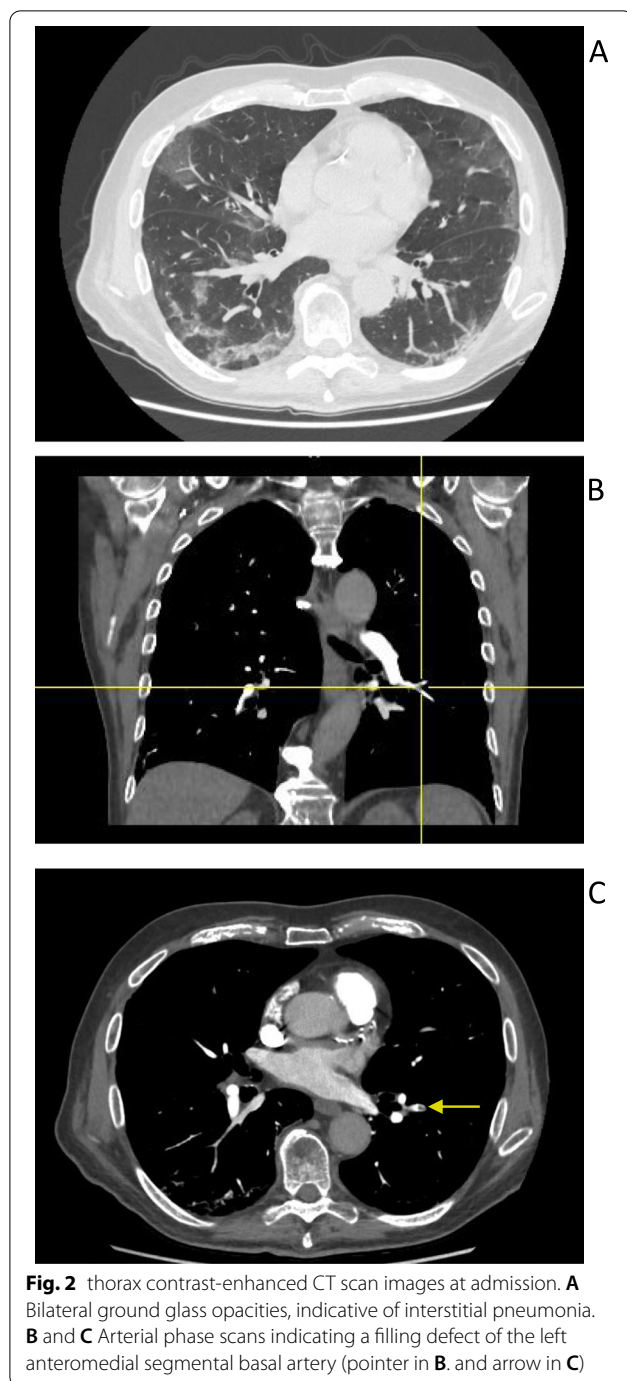
analysis on peripheral blood revealed a large PNH clone (92% on granulocytes and monocytes), which was absent at diagnosis. Parameters of haemolysis were only mildly altered, with a serum lactate dehydrogenase (LDH) level of 1.19 x the upper limit of normality (ULN) and total bilirubin level of 1.19 mg/dL, along with mild anaemia (Hb 12.5 g/dL), so that complement inhibition was not started. Likewise, prophylactic anticoagulation was not started, also considering the low PLT value (about  $50 \times 10^3/\mu\text{L}$ ). Four months after relapse, the patient developed atrial fibrillation and began oral anticoagulation with edoxaban 60 mg/day (PLT values were permissive). Two months later, he developed COVID-19 (positive PCR-based nasopharyngeal swab) requiring access to the Emergency Room due to fever and respiratory failure. Notably, he was not vaccinated against SARS-CoV-2. At time of presentation, Hb was 13.5 g/dL, PLT were  $77 \times 10^3/\mu\text{L}$ , WBC were  $6.12 \times 10^3/\mu\text{L}$ , with  $5.37 \times 10^3/\mu\text{L}$  neutrophils, whereas LDH was 341 U/L (1.39 times ULN). A contrast-enhanced CT-scan revealed bilateral ground glass opacities and a filling defect of the left anteromedial segmental basal artery, indicative of pneumonia and pulmonary embolism (Fig. 2). Respiratory failure appeared to be more related to pneumonia than to pulmonary embolism, considering the extension of lung opacities and, conversely, the non-massive nature of the embolism. Low flow oxygen therapy was started and subsequently escalated to continuous positive airway pressure (CPAP) ventilation. A transthoracic echocardiography showed a normal ejection fraction with a Pulmonary Artery systolic Pressure (PAPs) of 25 mmHg. Edoxaban was interrupted and replaced by subcutaneous fondaparinux (7.5 mg/day), whereas eltrombopag was discontinued. No

antiviral treatment for COVID-19 was administered. His general conditions progressively improved, until interruption of non-invasive ventilation and oxygen therapy. Notably, PLT counts remained stably  $>50 \times 10^3/\mu\text{L}$  throughout hospital stay and no transfusion was needed. At last follow-up, 2 months past COVID-19 infection, the patient had stable blood counts (Hb 12 g/dL, WBC  $5.26 \times 10^3/\mu\text{L}$ , PLT  $92 \times 10^3/\mu\text{L}$ , absolute reticulocyte count  $76 \times 10^3/\mu\text{L}$ ) and was counselled to continue fondaparinux. Of interest, thrombophilia screening, including antiphospholipid antibodies, was negative.

## Discussion and conclusions

The presented case is paradigmatic of the complex interplay of risk factors that can lead to thrombosis in a haematological patient experiencing COVID-19. It also raises questions on how to properly manage eltrombopag and anti-coagulation in such an uncharted territory. Regarding eltrombopag, manufacturer's brochure advises a dose reduction or interruption in case of thrombocytosis (i.e.  $\text{PLT} > 250 \times 10^3/\mu\text{L}$ ) ([https://www.ema.europa.eu/en/documents/product-information/revolade-epar-product-information\\_en.pdf](https://www.ema.europa.eu/en/documents/product-information/revolade-epar-product-information_en.pdf)), whilst no advice is given in case of thrombosis. The risk-benefit ratio of discontinuing eltrombopag should be weighed on a case-by-case basis, considering PLT count stability, risk of rebound thrombocytopenia and consequent probability of bleeding. In addition, no clear-cut indications are provided by the recently published guidelines for ITP [6].

Similarly, there is lack of guidance on how to manage eltrombopag during COVID-19 infection, which is a recognized thrombophilic condition. In ITP, published guidelines do not advise eltrombopag discontinuation



and suggest prophylactic heparin in hospitalized patients with permissive PLT values [7, 8]. In our case, eltrombopag was interrupted after diagnosis of pulmonary embolism; nonetheless, the patient maintained stable and safe PLT counts.

Another open question is the role of complement inhibition in preventing thrombosis in patients with large PNH clones, yet without ongoing haemolysis [9].

In our case, the presence of a large PNH clone, together with the occurrence of a thrombotic event, may have warranted the initiation of life-long complement inhibition. However, the patient had neither evidence of anaemia nor of significant haemolysis, except a mild LDH elevation, possibly confounded by severe COVID-19 pneumonia. Therefore, the specific contribution of haemolytic PNH to thrombosis was questionable. Additionally, considering timing and site (pulmonary arteries), the thrombotic event was considered as triggered by COVID-19, hence by a transient cause, and the decision to start complement inhibition was deferred. Beyond the specific case, it should be noted that a clear reduction of thrombotic risk in PNH has been demonstrated only by anti-complement treatment [10], while the role of primary thromboprophylaxis is still controversial [11, 12].

A further consideration is that, in our patient, thromboembolism was not prevented by the therapeutic doses of edoxaban, which was in fact replaced by fondaparinux. In this respect, a question arises as whether PNH patients who are therapeutically anticoagulated or are receiving thromboprophylaxis with a DOAC should be switched to therapeutic heparinoids during COVID-19 infection, before they develop overt thrombosis. This approach should be considered, particularly in patients requiring hospital admission, and may be supported by the putative anti-inflammatory role of heparinoids [13], which may be relevant for COVID-19 related thromboinflammation. As a matter of fact, patients with COVID-19 who required hospital admission had better outcomes if started on therapeutic heparins [14], which were also shown to interfere with SARS-CoV-2 infection [15], while no similar evidence is available for DOACs. Additionally, heparinoids may also exert a modulatory effect on complement cascade, supporting their use in PNH-related thrombosis. Poor evidence exists in this setting about the efficacy of DOACs [16–18], that also proved inferior in patients with anti-phospholipid syndrome [19, 20].

In conclusion, our case highlights that the management of thrombosis in patients with several predisposing conditions (large PNH clone, eltrombopag, COVID-19) is challenging. It also advocates for future studies to clarify the role of DOACs in subjects with multiple risk factors, including PNH.

#### Abbreviations

CPAP: Continuous positive airway pressure; DOAC: Direct oral anticoagulation; ITP: Immune thrombocytopenia; Hb: Haemoglobin; PLT: Platelet; PNH: Paroxysmal nocturnal haemoglobinuria; SAA: Severe aplastic anaemia; WBC: White blood cells.

#### Acknowledgements

Not applicable.

**Authors' contributions**

All authors equally contributed to the conceiving, writing and final approval of the article.

**Funding**

This work was partially funded by the Italian Ministry of Health, Current Research 2021.

**Availability of data and materials**

Not applicable.

**Declarations****Ethics approval and consent to participate**

Not applicable.

**Consent for publication**

The patient gave his consent for publication.

**Competing interests**

The authors declare that they have no conflict of interest inherent to the present article.

**Author details**

<sup>1</sup>Haematology Unit, Fondazione IRCCS Ca' Granda Ospedale Maggiore Policlinico, Via Francesco Sforza 35, 20100 Milan, Italy. <sup>2</sup>Department of Oncology and Haemato-oncology, University of Milan, Milan, Italy.

Received: 2 June 2022 Accepted: 26 July 2022

Published: 24 August 2022

**References**

- Roncon L, Zuin M, Barco S, Valerio L, Zuliani G, Zonzin P, et al. Incidence of acute pulmonary embolism in COVID-19 patients: systematic review and meta-analysis. *Eur J Int Med.* 2020;82:29–37.
- Nopp S, Moik F, Jilma B, Pabinger I, Ay C. Risk of venous thromboembolism in patients with COVID-19: a systematic review and meta-analysis. *Res Pract Thrombosis Haemostasis.* 2020;4(7):1178–91.
- Klok FA, Kruip MJ, Van der Meer NJ, Arbous MS, Gommers DA, Kant KM, et al. Incidence of thrombotic complications in critically ill ICU patients with COVID-19. *Thromb Res.* 2020;191:145–7.
- Devalet B, Mullier F, Chatelain B, Dogné JM, Chatelain C. Pathophysiology, diagnosis, and treatment of paroxysmal nocturnal hemoglobinuria: a review. *Eur J Haematol.* 2015;95(3):190–8.
- Saleh MN, Bussel JB, Wong RS, Meddeb B, Salama A, El-Ali A, et al. Hepatobiliary and thromboembolic events during long-term EXTEN Ded treatment with eltrombopag in adult patients with chronic immune thrombocytopenia (ITP). *Blood.* 2016;128(22):1368.
- Neunert C, Terrell DR, Arnold DM, Buchanan G, Cines DB, Cooper N, et al. American Society of Hematology 2019 guidelines for immune thrombocytopenia. *Blood advances.* 2019;3(23):3829–66.
- Pavord S, Thachil J, Hunt BJ, Murphy M, Lowe G, Laffan M, et al. Practical guidance for the management of adults with immune thrombocytopenia during the COVID-19 pandemic. *Br J Haematol.* 2020;189(6):1038–43. <https://doi.org/10.1111/bjh.16775> Epub 2020 Jun 2. PMID: 32374026; PMCID: PMC7267627.
- Rodeghiero F, Cantoni S, Carli G, Carpenedo M, Carrai V, Chiurazzi F, De Stefano V, Santoro C, Siragusa S, Zaja F, Vianelli N. Practical recommendations for the management of patients with ITP during the COVID-19 pandemic. *Mediterranean journal of hematology and infectious diseases.* 2021;13(1).
- Hill A, Kelly RJ, Hillmen P. Thrombosis in paroxysmal nocturnal hemoglobinuria. *Blood.* 2013;121(25):4985–96.
- de Fontbrune FS, de Latour RP. Ten years of clinical experience with eculizumab in patients with paroxysmal nocturnal hemoglobinuria. *In Seminars Hematol.* 2018;55(3):124–9 WB Saunders.
- Hall C, Richards S, Hillmen P. Primary prophylaxis with warfarin prevents thrombosis in paroxysmal nocturnal hemoglobinuria (PNH). *Blood.* 2003;102(10):3587–91.
- Parker C, Omine M, Richards S, Nishimura JI, Bessler M, Ware R, et al. Diagnosis and management of paroxysmal nocturnal hemoglobinuria. *Blood.* 2005;106(12):3699–709.
- Mousavi S, Moradi M, Khorshidahmad T, Motamedi M. Anti-inflammatory effects of heparin and its derivatives: a systematic review. *Advances in pharmacological sciences.* 2015;2015.
- ATTACC, ACTIV-4a, and REMAP-CAP Investigators. Therapeutic anticoagulation with heparin in noncritically ill patients with Covid-19. *N Engl J Med.* 2021;385(9):790–802.
- Paardi G, Richter S, Oreste P, Urbinati C, Rusnati M, Wade RC. The binding of heparin to spike glycoprotein inhibits SARS-CoV-2 infection by three mechanisms. *J Biol Chem.* 2022;298(2).
- Griffin M, Munir T. Management of thrombosis in paroxysmal nocturnal hemoglobinuria: a clinician's guide. *Therapeutic Advances in Hematology.* 2017;8(3):119–26.
- Brodsky RA. How I treat paroxysmal nocturnal hemoglobinuria. *Blood.* 2009;113(26):6522–7.
- Dragoni F, Chiarotti F, Iori AP, La Rocca U, Cafolla A. Antithrombotic therapy with rivaroxaban in five patients with paroxysmal nocturnal hemoglobinuria and thrombotic events. *Thromb J.* 2018;16:26. <https://doi.org/10.1186/s12959-018-0181-5> PMID: 30377413; PMCID: PMC6196560.
- Pengo V, Denas G, Zoppellaro G, Jose SP, Hoxha A, Ruffatti A, et al. Rivaroxaban vs warfarin in high-risk patients with antiphospholipid syndrome. *Blood.* 2018;132(13):1365–71.
- Ordi-Ros J, Sáez-Comet L, Pérez-Conesa M, Vidal X, Riera-Mestre A, Castro-Salomó A, et al. Rivaroxaban versus vitamin K antagonist in antiphospholipid syndrome: a randomized noninferiority trial. *Ann Intern Med.* 2019;171(10):685–94.

**Publisher's Note**

Springer Nature remains neutral with regard to jurisdictional claims in published maps and institutional affiliations.

**Ready to submit your research? Choose BMC and benefit from:**

- fast, convenient online submission
- thorough peer review by experienced researchers in your field
- rapid publication on acceptance
- support for research data, including large and complex data types
- gold Open Access which fosters wider collaboration and increased citations
- maximum visibility for your research: over 100M website views per year

At BMC, research is always in progress.

Learn more [biomedcentral.com/submissions](https://biomedcentral.com/submissions)

