

CORRECTION

Open Access



Correction: Detection and description of a novel *Psychrobacter glacincola* infection in some Red Sea marine fishes in Hurghada, Egypt

Mohamed Raafat El-Sayed^{1*}, Arafah M. Emam², Ahmed Elsayed Osman³, Mohamed Abd El-Aziz Ahmed Abd El-Galil¹ and Haitham Helmy Sayed⁴

Correction: *BMC Vet Res* 19, 23 (2023)

<https://doi.org/10.1186/s12917-022-03542-8>

Following publication of the original article [1], the authors identified an error in Fig. 5. The correct figure is given below.

The online version of the original article can be found at <https://doi.org/10.1186/s12917-022-03542-8>.

*Correspondence:

Mohamed Raafat El-Sayed
mohamed.rafat2018@vet.sohag.edu.eg

¹Department of Fish Diseases and Management, Faculty of Veterinary Medicine, Sohag University, Sohag, Egypt

²National Institute of Oceanography and Fisheries, NIOF, Cairo, Egypt

³Department of Biochemistry, Faculty of Veterinary Medicine, Sohag University, Sohag, Egypt

⁴Department of Microbiology, Faculty of Veterinary Medicine, Sohag University, Sohag, Egypt



© The Author(s) 2023. **Open Access** This article is licensed under a Creative Commons Attribution 4.0 International License, which permits use, sharing, adaptation, distribution and reproduction in any medium or format, as long as you give appropriate credit to the original author(s) and the source, provide a link to the Creative Commons licence, and indicate if changes were made. The images or other third party material in this article are included in the article's Creative Commons licence, unless indicated otherwise in a credit line to the material. If material is not included in the article's Creative Commons licence and your intended use is not permitted by statutory regulation or exceeds the permitted use, you will need to obtain permission directly from the copyright holder. To view a copy of this licence, visit <http://creativecommons.org/licenses/by/4.0/>. The Creative Commons Public Domain Dedication waiver (<http://creativecommons.org/publicdomain/zero/1.0/>) applies to the data made available in this article, unless otherwise stated in a credit line to the data.

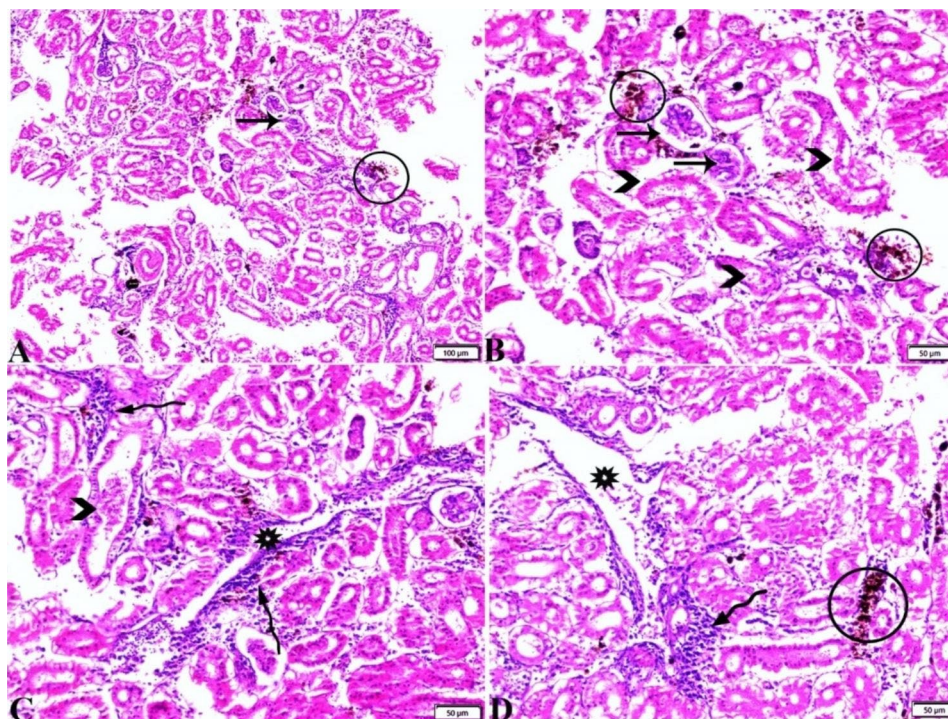


Fig. 5 Photomicrograph (A magnified in B, C&D) of the posterior kidney sections from *Rhabdosargus haffara* infected with *psychrobacter glacincola* shows veins congestion (stars), melanomacrophage hyperplasia (circle), glomerular atrophy (arrows), renal tubular epithelium necrosis and detachment (arrow-heads), and interstitial mononuclear inflammatory cellular infiltration. H&E stain. The bar size was indicated under pictures

Published online: 15 September 2023

Publisher's Note

Springer Nature remains neutral with regard to jurisdictional claims in published maps and institutional affiliations.

References

1. El-Sayed MR, Emam AM, Osman AE, et al. Detection and description of a novel *Psychrobacter glacincola* infection in some Red Sea marine fishes in Hurghada, Egypt. *BMC Vet Res.* 2023;19:23. <https://doi.org/10.1186/s12917-022-03542-8>.