

RESEARCH

Open Access



# Reconstruction of the temporomandibular joint using a vascularized medial femoral condyle osteocartilaginous flap: an experimental investigation in miniature pigs

Tianyi Lin<sup>1,2,3,4,5†</sup>, Shuo Chen<sup>1,2,3,4,5†</sup>, Long Xia<sup>1,2,3,4,5</sup>, Bimeng Jie<sup>1,2,3,4,5</sup>, Yi Zhang<sup>1,2,3,4,5</sup> and Yang He<sup>1,2,3,4,5\*</sup>

## Abstract

**Background** Reconstruction of the temporomandibular joint (TMJ) is a significant challenge in maxillofacial surgery. A vascularized medial femoral condyle (MFC) osteocartilaginous flap is a good choice for TMJ reconstruction. In this study, we evaluated the radiographic and histological changes of MFC after TMJ reconstruction.

**Methods** A ramus-condyle unit (RCU) defect was created unilaterally in five adult male Bama miniature pigs. The ipsilateral vascularized MFC osteocartilaginous flap was used to reconstruct the TMJ, and the non-operative sides served as controls. Multislice spiral computed tomography (CT) was performed preoperatively, immediately postoperatively, and at two weeks, three months, and six months postoperatively. Three animals were euthanized at 6 months postoperatively. Their reconstructed condyles, natural condyles and the MFCs on the opposite side were collected and subjected to  $\mu$ CT and histological evaluation.

**Results** In the miniature pigs, the vascularized MFC osteocartilaginous flap was fused to the mandible, thus restoring the structure and function of the RCU. The postoperative radiographic changes and histological results showed that the reconstructed condyle was remodeled toward the natural condyle, forming a similar structure, which was significantly different from the MFC.

**Conclusions** In miniature pigs, the RCU can be successfully reconstructed by vascularized osteocartilaginous MFC flap. The reconstructed condyle had almost the same appearance and histological characteristics as the natural condyle.

**Keywords** Temporomandibular joint, Mandibular reconstruction, Medial femoral condyle flap, Pig

<sup>†</sup>Tianyi Lin and Shuo Chen contributed equally to this work.

\*Correspondence:

Yang He  
fridaydust1983@163.com

<sup>1</sup>Department of Oral and Maxillofacial Surgery, Peking University School and Hospital of Stomatology, No.22 Zhongguancun South Avenue, Haidian District, Beijing 100081, PR China

<sup>2</sup>National Center for Stomatology, Beijing, PR China

<sup>3</sup>National Clinical Research Center for Oral Diseases, Beijing, PR China

<sup>4</sup>National Engineering Research Center of Oral Biomaterials and Digital Medical Devices, Beijing, PR China

<sup>5</sup>Beijing Key Laboratory of Digital Stomatology, Beijing, PR China



## Background

The temporomandibular joint (TMJ) has a number of important functions, such as mastication and speech. The articular system comprises the condyles, intra-articular discs, mandibular muscles and the occlusion. Due to the 'knock-on effect', abnormalities in any side or in any single part of the system can exert an overall impact on the joint [1]. Malformations [2, 3], tumors [4, 5], and ankylosis [6] are among the conditions that may cause a ramus-condyle unit (RCU) defect, which requires reconstruction [7]. The complex anatomic and physiologic features of TMJ make its reconstruction challenging. Chondro-costal graft (CCG), vascularized autogenous tissue transfer, and alloplastic TMJ replacement have been applied for TMJ reconstruction [8].

Although various reconstruction methods have been implemented in the past, each of them has had its limitations. Hence, new alternative techniques need to be explored and established. In this respect, in 2014, Thiele et al. proposed that vascularized medial femoral condyle (MFC) flaps can supply the bone, cartilage, and skin with minimal donor site morbidity and have the potential for TMJ reconstruction [9]. In the same year, Lee et al. reported a successful TMJ reconstruction using the femoral medial epicondyle free flap to treat malunion of a subcondylar fracture without the use of articular cartilage [10]. Further, in 2015, Wong et al. introduced the application of a vascularized lateral femoral condyle (LFC) flap, a new flap similar to the MFC flap, in hand surgery [11]. Subsequently, Enzinger et al. used a vascularized LFC osteochondral flap to repair mandibular condyle defects with good functional and morphological outcomes [12]. Since 2019, we have reconstructed TMJs using vascularized MFC osteochondral flaps in TMJ ankylosis and tumor patients. Our three-year follow-up data indicate that satisfactory treatment results have been achieved [13].

The mandible and long bones have different developmental mechanisms, structures and functions. The surface of the medial femoral condyle is covered with hyaline cartilage, which is compatible with the function of the knee joint, having cushioning and friction-reducing functions [14]. Unlike most joints, the condyle surface is covered by fibrocartilage rather than hyaline cartilage [15]. Condylar cartilage plays an important role in mandible development and is adapted to the motional characteristics of the TMJ [1, 16, 17]. However, it is unclear whether post-transplantation MFC is structurally modified to accommodate the new function.

Among the large animals used for TMJ reconstruction research, pigs are the most suitable, since their joint, disc morphology and mandibular movement patterns are similar to those of humans [18]. Moreover, the vascularized MFC flap has only been studied in miniature pigs

[19, 20]. In the present study, we developed a miniature pig model of a unilateral vascularized MFC osteochondral flap to regenerate an RCU defect. Then we studied the postoperative remodeling of the reconstructed condyle.

## Methods

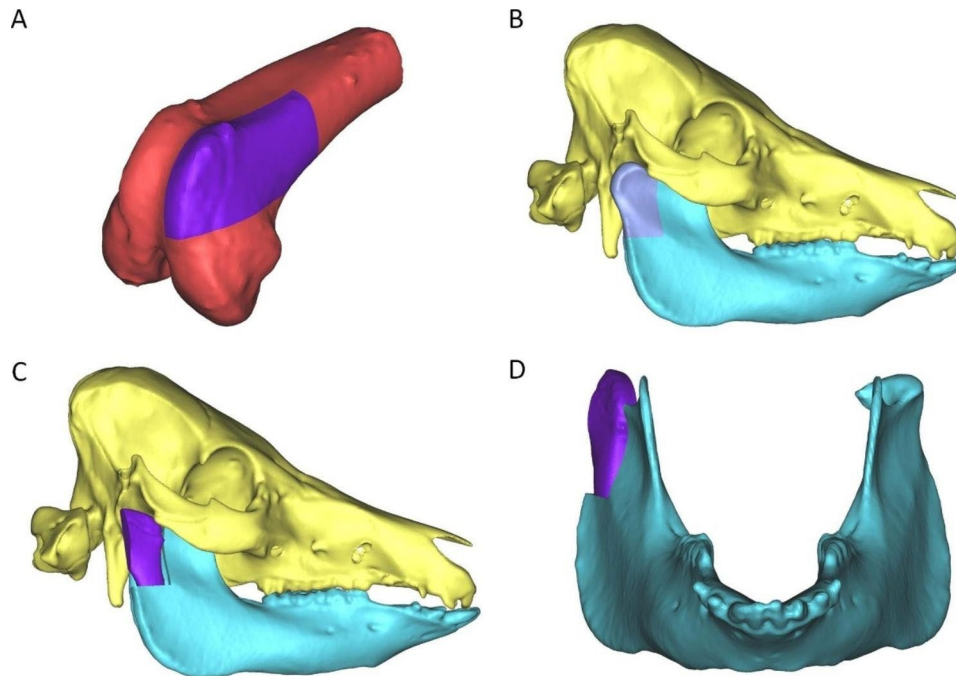
### Animals

Five adult male Bama miniature pigs, aged 12–18 months and weighing 30–40 kg, were used in this experiment. All experiments were approved by the Biomedical Ethical Committee of Peking University (No. LA2022367). The experimental animals were normal grade, produced by Tianjin Binong Experimental Animal Breeding Technology Co., Ltd. They were raised and operated on in a barrier environment in Beijing Tonghe Litai Biotechnology Co., Ltd. The experimental animals were acclimated and observed for two weeks before the operation to ensure their health. The experimental animals were raised in iron cages with sufficient space to move around, supplemented with water and feed by specially assigned staff. All animals were treated as the experimental group with the nonoperative side as the control. The animals were euthanized by excessive anesthesia after six months. The data of animals with serious adverse events, such as accidental death, condylar fracture, necrosis, and infection, were excluded ( $n \geq 3$  after exclusion) during the analysis of the results.

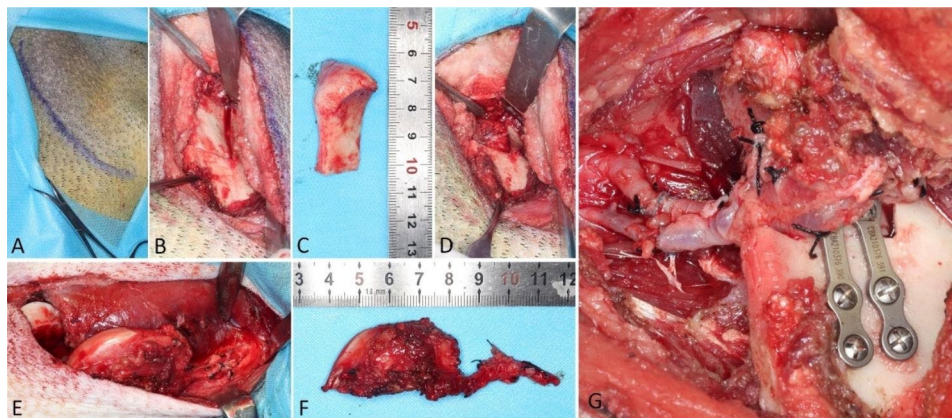
### Surgical protocols

All operations were performed by one surgical team. Dr. He completed the core operation steps, and other authors participated in the operations as assistants. The surgical team has completed more than 10 cases of TMJ reconstruction using MFC flap in clinic. The animals were fasted for 12 h before surgery preoperatively, and anesthesia was induced by intramuscular injection of xylazine hydrochloride (40 mg/kg) and Zoletil 50 (zolazepam+tiletamine) (5 mg/kg). Preoperative multislice spiral computed tomography (CT) was performed after preparing the skin of the right face and hind limb. Then, an MFC osteochondral flap and RUC reconstruction were designed using CT data (Fig. 1). Next, the experimental animal was placed on the operating table, with the upper body in the right lateral position and the lower body in the supine position. After tracheal intubation, the respiratory anesthesia machine was connected, and anesthesia was maintained with isoflurane inhalation throughout the operation.

After the animal was fixed, intravenous access was obtained from the dorsal auricular vein. Penicillin and ibuprofen were injected before the operation, and 1000 mL of glucose and sodium chloride were infused intravenously during the operation. The operation area was



**Fig. 1** Diagrams of RCU reconstruction by vascularized MFC osteocartilaginous flap. **A** Range of the vascularized MFC osteocartilaginous flap. **B** Defect range of RCU. **C** and **D** TMJ reconstruction result



**Fig. 2** Surgical procedure. **A** Incision marked for the retromandibular approach. **B** The mandibular ramus and condyle were exposed, and osteotomy was performed. **C** The removed RCU. **D** RCU defect. **E-F** Collection of the MFC osteocartilaginous flap. **G** Vascular anastomosis and bone flap fixation

disinfected with povidone-iodine, and sterile sheets were placed. The incision of the retromandibular approach was marked (Fig. 2A), and the skin and subcutaneous tissue were incised. The mandibular angle and the posterior margin of the ramus were exposed, and the attachment of the masseter muscle was cut off; the lateral surface of the ramus and condyle were then exposed (Fig. 2B). The ramus was sawed downward along the anterior margin of the condyle, at an approximate width of the bone of 2 cm. A horizontal osteotomy was performed at approximately 4 cm from the apex of the condyle; the RCU was removed, but the articular disc was retained (Fig. 2C, D).

The maxillary artery and its accompanying vein located medial to the ramus were dissected and reserved.

A 10-cm incision was made on the medial side of the right hind limb above the knee. The medial femoris muscle was stripped forward to expose the medial femur, the descending genicular artery and its accompanying vein were dissected, and then part of the femoral artery and vein were separated and carried toward the proximal end. The approximate pedicle length was 5 cm. An osteocartilaginous flap with a length of 4 cm, a width of 2 cm and a thickness of 0.8 cm was cut off and transferred to the facial surgery area (Fig. 2E-F). The leg wound was sutured layer-by-layer.

The femoral artery and vein of the osteocartilaginous flap were anastomosed end-to-end with the maxillary artery and vein, and the blood supply and reflux were checked. The osteocartilaginous flap was fixed with two CIBEI (Ningbo, China) 4-hole short-bridge mini titanium plates and eight 8-mm screws (Fig. 2G). The wound was sutured layer-by-layer.

Isoflurane was stopped, and the endotracheal tubes were extubated after spontaneous breathing recovered. The animals were returned to the cage after postoperative spiral CT examination. After the operation, penicillin and ibuprofen were injected intramuscularly for 14 days, and body temperature was monitored for five days. For the first week after the operation, the pigs were given a semi-liquid diet: the feed was broken up and soaked into a paste. A normal solid diet was resumed one week afterwards.

#### Multi-slice spiral CT

To examine the results of TMJ reconstruction and observe postoperative condylar remodeling, all the animals were subjected to five CT examinations: preoperatively, immediately postoperatively, and at two weeks, three months, and six months postoperatively. The examination procedure performed preoperatively and immediately postoperatively has been described above. Anesthesia induction via intramuscular injection was performed at other time points before CT examination. A 64-row, 128-slice CT scanner (United Imaging uCT 760; Shanghai, China) was employed for the examinations at 238 mA and 120 kV, and a layer thickness of 0.625 mm.

#### $\mu$ CT examination

After the animals were euthanized, the entire mandibles were isolated, and the left MFCs were cut within the MFC flap range. After the samples were photographed, the reconstructed RCUs and the nonoperative RCUs were cut according to the osteotomy range of the intraoperative RCU defect and fixed with 10% formalin along with the MFCs.  $\mu$ CT examinations of the samples were conducted by Xi'an Aoyun Electronic Technology Co., Ltd. with  $\mu$ CT, the equipment was Always Imaging AX2000, at 15- $\mu$ m resolution. Data of the following parameters were collected and analyzed in this study: bone volume to total volume (BV/TV), bone surface to bone volume (BS/BV), trabecular thickness (Tb.Th.), trabecular number (Tb.N.), and trabecular spacing (Tb.Sp.).

#### Histologic examination

The samples subjected to  $\mu$ CT examination were dissected by the dynamic system along the sagittal plane in the middle of the condyle and then decalcified with EDTA decalcified solution for three months. After full decalcification, five-micron-thick sections were prepared

after the samples were embedded in paraffin. Then, the slides were subjected to H&E and Safranin O-fast green staining using standard protocols, followed by photographing under a microscope.

#### Statistical analysis

All quantitative data are expressed as mean  $\pm$  S.D. Friedman test and Dunn's multiple comparisons test were employed for comparison among groups. A P-value  $< 0.05$  was considered to indicate a statistically significant difference. Statistical analysis was performed using GraphPad Prism 9.0.

## Results

#### Animal health

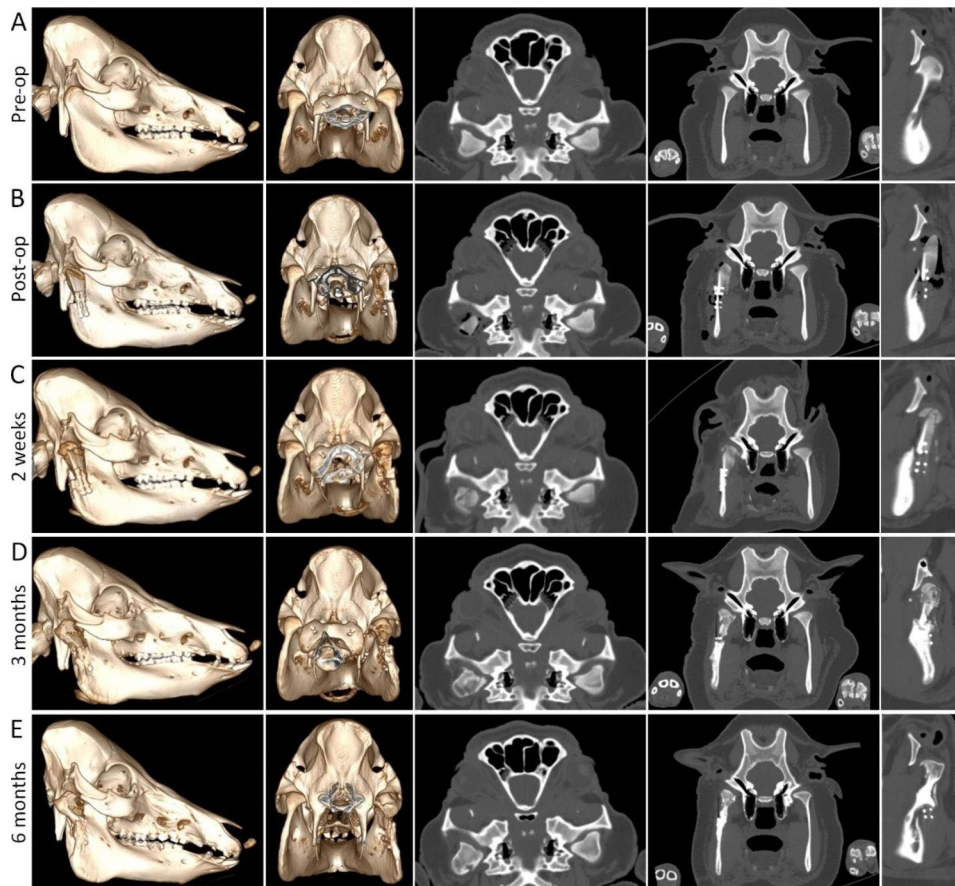
All the animals were alive with a normal body temperature five days after the operation (Additional Fig. 1). The normal dry weight food intake was resumed from 3 to 5 days postoperatively. The pigs recovered to normal activities 1–2 weeks postoperatively. CT examinations revealed that the reconstructed condyle in one pig had split at two weeks. In another case, the operative area had been infected and failed to recover after debridement. These aforementioned two pigs were removed from the study due to complications that could have affected the experimental results. The three remaining pigs survived to 6 months postoperatively, when each of them weighed approximately 40 kg (Additional Fig. 2).

#### Multi-slice spiral CT images

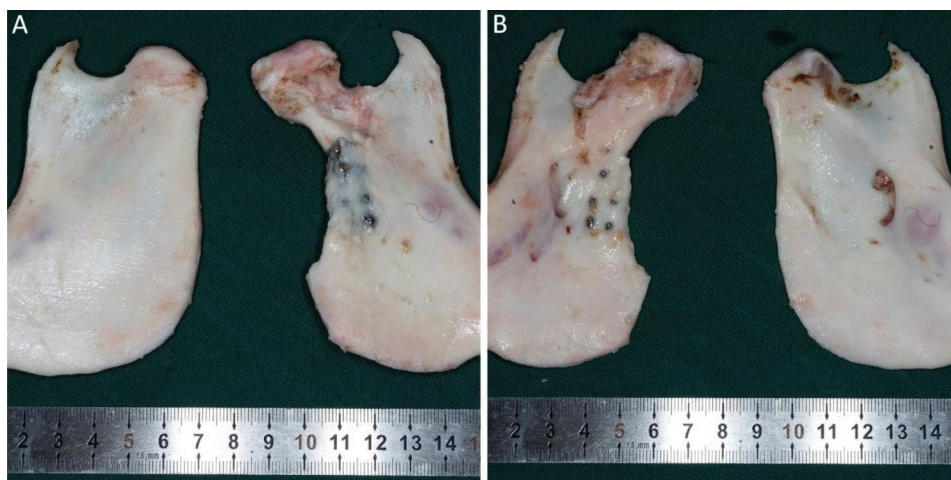
The comparison between the preoperative (Fig. 3A) and immediately postoperative (Fig. 3B) CT images showed that a symmetrical shape of the mandible and a well-recovered ramus height had been achieved. Bone formation around the reconstructed condyle was observed at two weeks after the operation (Fig. 3C). At three months postoperatively, the reconstructed condyle was obviously remodeled, with a natural condyle appearance. The shape and width of the two condyles were very similar, but the bone density was still uneven (Fig. 3D). At six months after the operation, the shape of the reconstructed condyle had no significant change when compared with that at three months, but the bone density of the reconstructed condyle was more uniform, which was close to that of the natural condyle (Fig. 3E).

#### Sample observation

Visual observation showed that the bone flap had fully fused with the ramus of the mandible without an obvious boundary; some titanium plates and screws were covered by the newly formed bone. The shape and texture of the reconstructed condyle were similar to those of the natural condyle. The articular surface of the reconstructed condyle was smooth and light red, which was significantly



**Fig. 3** CT imaging at different stages. CT images acquired before (A), immediately after the operation (B), and at 2 weeks (C), 3 months (D) and 6 months (E) after the operation

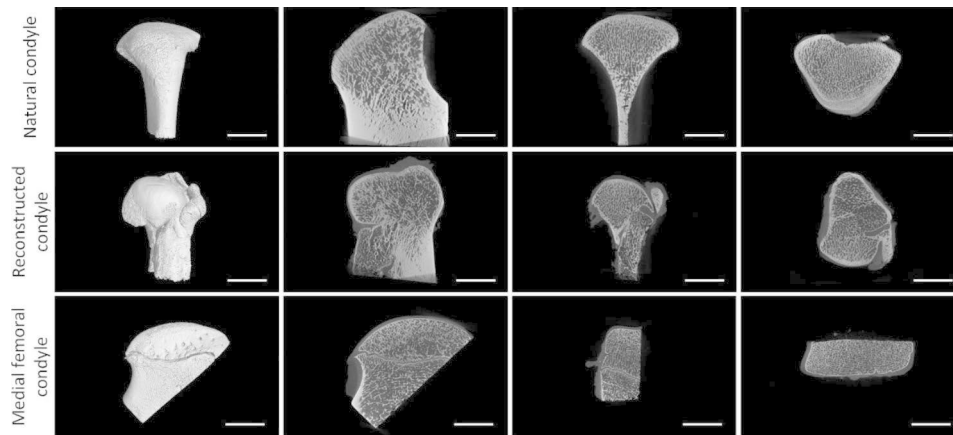


**Fig. 4** Mandibular samples. A Lateral view of the mandibular ramus. B Medial view of the mandibular ramus

different from the pure white articular surface of the MFC. The unstressed area of the reconstructed condyle retained some articular cartilage without obvious remodeling (Fig. 4).

**μCT images**

The morphology and trabecular distribution of the reconstructed condyle were consistent with those of the natural condyle but were significantly different from those of the MFC (Fig. 5). The results of the quantitative analysis supported this basic impression. There



**Fig. 5** μCT examination results, μCT images of the natural condyle, reconstructed condyle and MFC. Scale bars, 10 mm

**Table 1** μCT quantification of the subchondral bone

	Mean ± S.D.			Friedman test		Dunn's multiple comparisons test					
	NC	RC	MFC	P-value	Summary	NC vs. RC		NC vs. MFC		RC vs. MFC	
						P-value	Summary	P-value	Summary	P-value	Summary
BV/TV (%)	0.4254 ± 0.06317	0.4759 ± 0.06980	0.3174 ± 0.02780	0.0278	*	0.662	ns	0.662	ns	0.0429	*
BS/BV (1/mm)	14.28 ± 1.276	12.31 ± 1.069	17.36 ± 0.3773	0.0278	*	0.662	ns	0.662	ns	0.0429	*
Tb.Th. (mm)	0.1411 ± 0.01171	0.1656 ± 0.01575	0.1167 ± 0.005774	0.0278	*	0.662	ns	0.662	ns	0.0429	*
Tb.N. (1/mm)	3.008 ± 0.1840	2.843 ± 0.1571	2.756 ± 0.2480	0.1944	ns	0.3074	ns	0.1237	ns	>0.9999	ns
Tb.Sp. (mm)	0.1967 ± 0.03180	0.1867 ± 0.03215	0.2467 ± 0.03215	0.1944	ns	>0.9999	ns	0.3074	ns	0.1237	ns

Bone volume to total volume (BV/TV), bone surface to bone volume (BS/BV), trabecular thickness (Tb.Th.), trabecular number (Tb.N.), and trabecular spacing (Tb.Sp.) of the natural condyle (NC), reconstructed condyle (RC) and medial femoral condyle (MFC).

\*P-value < 0.05

were significant differences in BV/TV, BS/BV and Tb.Th. between the reconstructed condyles and the MFC, but no significant difference in Tb.N. and Tb.Sp was found. The reconstructed condyles had larger BV/TV and Tb.Th., but lower BS/BV values. (Table 1).

**Histologic analysis**

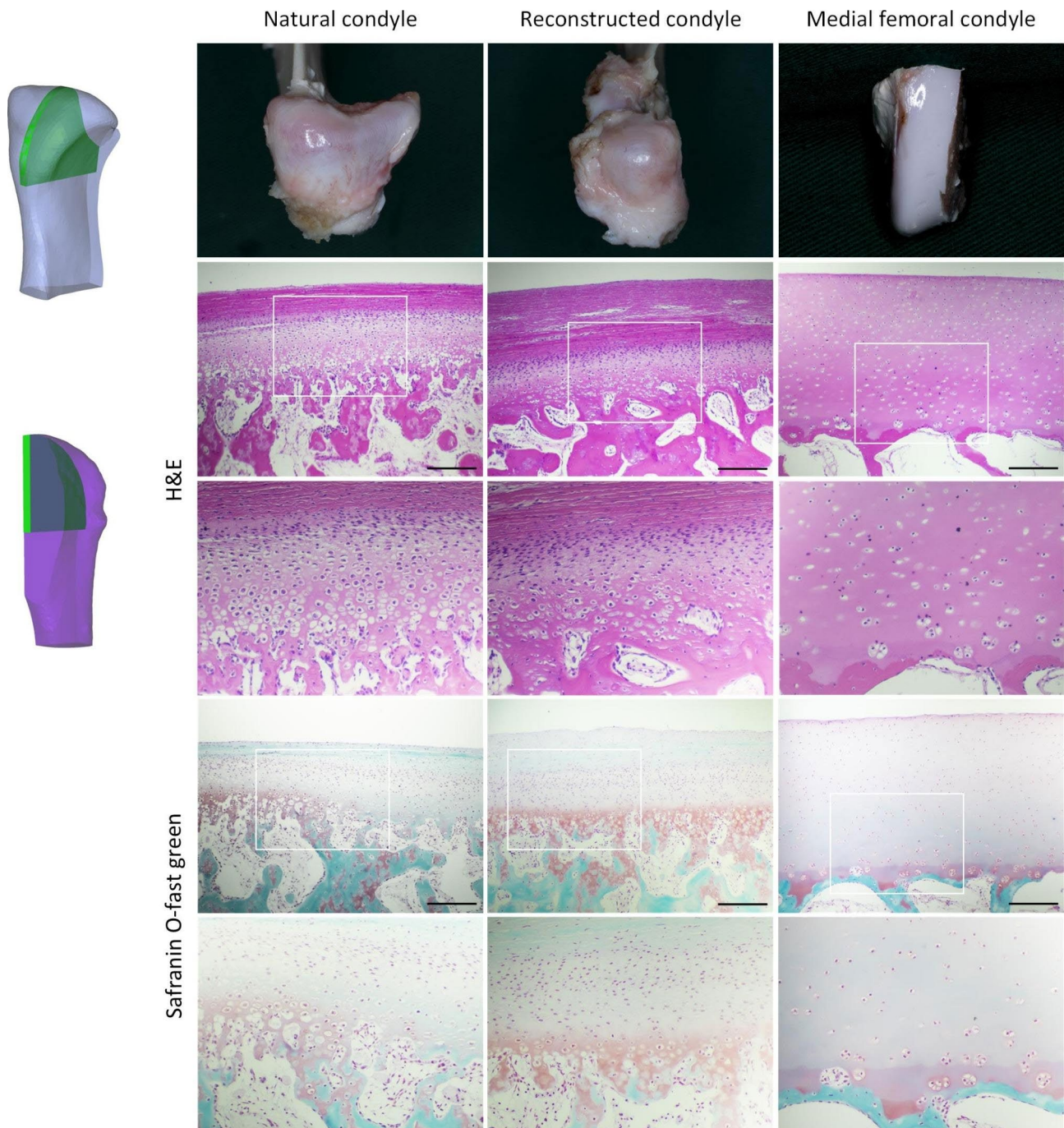
The articular cartilage of the reconstructed condyle was similar to that of the natural condyles, and could be divided into the following zones: fibrous articular surface zone, cellular rich zone, fibrocartilaginous zone, and cartilage calcified zone. While the articular cartilage of MFC was not significantly stratified, no fibrous tissue was observed on the cartilage surface. In addition, the cartilage layers of the reconstructed condyle and the natural condyle were significantly thinner than that of the MFC.

Similar to the μCT findings, the bone trabeculae of the MFC were significantly thinner and sparser, with a lower bone density (Fig. 6).

**Discussion**

Although there are several methods for TMJ reconstruction, it is still a great challenge for maxillofacial surgeons [7, 21–23]. In this study, we evaluated the radiographic and histological changes of MFC osteocartilaginous flap after graft to TMJ in miniature pigs and obtained satisfactory results.

In 1991, Sakai et al. reported the utility of a vascularized MFC flap that was supplied by the descending genicular artery, containing periosteum and thin cortical bone, for the treatment of nonunion after fracture of the ulna, humerus, and metacarpals; the skin was also taken in one



**Fig. 6** Schematic and representative photographs and H&E, Safranin O-fast green staining of the natural condyle, reconstructed condyle and MFC from the sagittal condylar cross sections. The white box indicates the range below. Scale bar, 100  $\mu$ m

case [24]. The vascularized MFC flap is multifunctional and provides bone, cartilage, periosteum, fascia, muscle, tendon, and skin. This technique is commonly applied for the repair of complex defects of the extremities [25–27]. In 2020, Deng et al. reported a series of cases of patients treated with vascularized MFC flaps for small bone defects and post-fracture nonunion in three centers in three countries. The recipient areas included the

scaphoid, lunate, metacarpal, tibia, ulna, navicular bone, and clavicle [28].

In the head and neck, the MFC flap was used for the reconstruction of orbital, alveolar, maxillary, mandibular, skull, and laryngotracheal scaffolds, but none contained cartilage [29, 30]. In 2014, Thiele et al. proposed that the vascularized MFC flap could provide articular cartilage and could be used for the repair of TMJ defects [9]. In

the same year, Lee et al. reported a TMJ reconstruction with a vascularized MFC flap but without articular cartilage [10]. In 2021, we published our results from the use of vascularized MFC osteocartilaginous flaps for TMJ reconstruction in a series of patients with TMJ ankylosis and tumors, which achieved good therapeutic results [13].

To date, animal experimental studies on the MFC flap have been performed only in pigs. In 2016, Borumandi et al. studied the long-term impact of arterialized venous bone flaps employed in pig MFC [19]. In 2018, Higgins et al. compared the long-term cartilage quality of vascularized versus nonvascularized osteocartilaginous flaps of the MFC [20]. In these two studies, the MFC flap was left in situ without transfer, but the feasibility of harvesting vascularized MFC flaps in pigs was reported. To the best of our knowledge, there is no animal experimental study in which the MFC flap was transferred to the recipient site. Therefore, the present study is the first animal experimental investigation of the use of vascularized MFC osteocartilaginous flaps in TMJ reconstruction.

Alternative techniques and grafts, including CCG and distraction osteogenesis, have been explored for TMJ reconstruction in animals. A study on the reconstruction of the TMJ by CCG in growing pigs showed no significant difference in the growth of the ribs between the joint area and the non-stressed area; only growth plate compression was established [31]. A rhesus monkey study was conducted, in which the condyle was reconstructed via distraction osteogenesis (with disc removal). At 24 weeks after the operation, the surface of the reconstructed condyle was covered by a thick fibrous cap, and a thick cartilage layer was formed below it, which was also different from that of the natural condyle [32]. Later, research attention has been focused on the importance of articular cartilage regeneration through tissue engineering. In 2020, Chen et al. used tissue engineering to implant osteocytes and chondrocytes in layers on a bovine bone RCU scaffold and created an appearance of the reconstructed condyles that was close to that of the natural condyle in miniature pigs [33]. The reconstruction of the condyle using MFC osteocartilaginous flap had the closest histological resemblance to that of the natural condyle as compared to ones achieved in previous studies, and the histological structure was highly ordered. The remodeling of this structure may allow for better adaptation to the TMJ function.

The bone regeneration rate of the minipig mandible (1.2–1.5  $\mu\text{m}/\text{day}$ ) has been reported to be comparable to that of humans (1.0–1.5  $\mu\text{m}/\text{day}$ ) [34]. However, in clinical cases, of middle-aged and elderly patients mainly, the reconstructed condyles rarely turned into a shape similar to that of the natural condyle, and only a certain degree of bone density change can be observed [13]. Therefore,

the results of animal experiments are only of certain comparative and reference value, and the actual clinical effect should not be overestimated. The experimental results in obtained miniature pigs suggest that vascularized MFC flap can have high clinical applications opportunities after validation in further clinical trials.

CCG and TMJ prosthesis are also widely accepted methods of joint reconstruction [22, 23]. CCG has the advantage of preserving growth potential in young patients, especially suitable for hemifacial microsomia [2]. Total TMJ prosthesis is the mainstream temporomandibular joint reconstruction method and research direction for adults, with good therapeutic effect and wide application [39]. We defined the medial femoral condylar flap as an alternative technique, although it is not optimal in many cases and not suitable for children and adolescents. Given that commercial TMJ prostheses are rare, expensive and not readily available in many hospitals in developing countries, vascularized flaps can be alternative methods. In addition, vascularized flaps can carry a variety of tissues and withstand radiotherapy, which has unique advantages in tumor patients.

Maintenance or reconstruction of the articular disc is considered a part of TMJ reconstruction. However, patients requiring condylar reconstruction often do not have an available articular disc (ankylosis) or cannot retain the disc (tumors) [35, 36]. In clinical practice, we generally use temporalis myofascial flap and abdominal fat graft to replace the buffering function of the articular disc [37, 38]. Relevant researches on artificial TMJ disc have achieved satisfactory results in animal models [40–42]. However, no clinical study has been performed, which is one of the research directions in the future.

## Conclusions

The MFC reconstructed condyle had almost the same appearance and histological characteristics as the natural condyle in miniature pigs. Therefore, MFC has the potential to serve as an alternative method for TMJ reconstruction.

## Abbreviations

BS/BV	Bone surface/bone volume ratio
BV/TV	Bone volume/total volume ratio
CCG	Costochondral grafts
CT	Computed tomography
LMC	Lateral femoral condyle
MFC	Medial femoral condyle
RCU	Ramus-condyle unit
Tb. N.	Trabecular number
Tb. Sp.	Trabecular separation
Tb. Th.	Trabecular thickness
TMJ	Temporomandibular joint

## Supplementary Information

The online version contains supplementary material available at <https://doi.org/10.1186/s12903-023-03341-z>.



Supplementary Material 1

**Acknowledgements**

Not applicable.

**Author contributions**

Under the guidance of YZ and YH, all authors contributed to the study conception and design. Material preparation, data collection, and analysis were performed by TYL and SC. TYL, SC, LX, BMJ, YH were involved in the animal surgery. The first draft of the manuscript was written by TYL, revised by SC and YH, and all authors commented on previous versions of the manuscript. All authors read and approved the final manuscript.

**Funding**

The article was supported by the Program for New Clinical Techniques and Therapies of Peking University School and Hospital of Stomatology (Grant PKUSSNCT-21G01) and the National Program for Multidisciplinary Cooperative Treatment on Major Diseases (PKUSSNMP-202007).

**Data Availability**

The data sets used and/or analyzed during the current study are available from the corresponding author upon reasonable request.

**Declarations****Competing interests**

The authors declare no competing interests.

**Ethics approval and consent to participate**

This study was carried out with the approval of the Biomedical Ethical Committee of Peking University (Beijing, China. Approval No. LA2022367) and complied with the ARRIVE 2.0 (Animal Research: Reporting of In Vivo Experiments 2.0) guidelines for animal studies. All methods were performed in accordance with the relevant guidelines and regulations.

**Consent for publication**

Not applicable.

Received: 11 April 2023 / Accepted: 22 August 2023

Published online: 01 September 2023

**References**

- Wilkie G, Al-Ani Z. Temporomandibular joint anatomy, function and clinical relevance. *Br Dent J*. 2022;233(7):539–46. <https://doi.org/10.1038/s41415-022-5082-0>.
- Bertin H, Mercier J, Cohen A, Giordanetto J, Cohen N, Lee SH, et al. Surgical correction of mandibular hypoplasia in hemifacial microsomia: a retrospective study in 39 patients. *J Cranio-Maxillofacial Surg*. 2017;45(6):1031–8. <https://doi.org/10.1016/j.jcms.2017.03.016>.
- Anquetil M, Mercier J, Leveau S, Mrabet S, Durand T, Salagnac J-M, et al. Evaluation of vertical ramus osteotomy for the surgical correction of unilateral mandibular posterior vertical insufficiency: long-term follow-up results. *J Cranio-Maxillofacial Surg*. 2020;48(4):349–56. <https://doi.org/10.1016/j.jcms.2020.02.013>.
- Horen SR, Hansdorfer MA, Seu M, Murphy J, Figueroa A, Tragos C. Alloplastic Temporomandibular Joint Reconstruction following recurrent Ameloblastoma Resection. *J Craniofac Surg*. 2022;33(1):e667–e9. <https://doi.org/10.1097/SCS.00000000000008564>.
- Movahed R, Mercuri LG. Management of temporomandibular joint ankylosis. *Oral Maxillofac Surg Clin North Am*. 2015;27(1):27–35. <https://doi.org/10.1016/j.coms.2014.09.003>.
- Vega LG, Gonzalez-Garcia R, Louis PJ. Reconstruction of acquired temporomandibular joint defects. *Oral Maxillofac Surg Clin North Am*. 2013;25(2):251–69. <https://doi.org/10.1016/j.coms.2013.02.008>.
- Imola MJ, Liddell A. Temporomandibular joint reconstruction. *Curr Opin Otolaryngol Head Neck Surg*. 2016;24(4):336–42. <https://doi.org/10.1097/MOO.0000000000000282>.
- Thiele OC, Kremer T, Kneser U, Mischkowski RA. Indications for the microvascular medial femoral condylar flap in craniomaxillofacial surgery. *Br J Oral Maxillofac Surg*. 2014;52(6):569–71. <https://doi.org/10.1016/j.bjoms.2014.04.006>.
- Lee CC, Hackenberg B, Halvorson EG, Cateson EJ. Vascularized treatment options for reconstruction of the ascending mandible with introduction of the femoral medial epicondyle free flap. *J Craniofac Surg*. 2014;25(5):1690–7. <https://doi.org/10.1097/SCS.0000000000001192>.
- Wong VW, Bürger HK, Iorio ML, Higgins JP. Lateral femoral condyle flap: an alternative source of vascularized bone from the distal femur. *J Hand Surg*. 2015;40(10):1972–80. <https://doi.org/10.1016/j.jhbs.2015.06.106>.
- Enzinger S, Bürger H, Gaggli A. Reconstruction of the mandibular condyle using the microvascular lateral femoral condyle flap. *Int J Oral Maxillofac Surg*. 2018;47(5):603–7. <https://doi.org/10.1016/j.ijom.2017.12.002>.
- Xia L, Jie B, Zhang Y, An J, Zheng L, He Y. Temporomandibular joint reconstruction with medial femoral condyle osseocartilaginous flap: a case series. *Int J Oral Maxillofac Surg*. 2021;50(5):604–9. <https://doi.org/10.1016/j.ijom.2020.09.017>.
- Poole CA. Articular cartilage chondrons: form, function and failure. *J Anat*. 1997;191 (Pt 1)(Pt 1).
- Katzberg RW, Dolwick MF, Helms CA, Hopens T, Bales DJ, Coggs GC. Arthrography of the temporomandibular joint. *AJR Am J Roentgenol*. 1980;134(5).
- Copray JC, Dibbets JM, Kantomaa T. The role of condylar cartilage in the development of the temporomandibular joint. *Angle Orthod*. 1988;58(4):369–80.
- Biosse Duplan M, Komla-Ebri D, Heuzé Y, Estivals V, Gaudas E, Kaci N, et al. Meckel's and condylar cartilages anomalies in achondroplasia result in defective development and growth of the mandible. *Hum Mol Genet*. 2016;25(14):2997–3010.
- Almarza AJ, Brown BN, Arzi B, Ângelo DF, Chung W, Badylak SF, et al. Preclinical animal models for Temporomandibular Joint tissue Engineering. *Tissue Eng Part B: Reviews*. 2018;24(3):171–8. <https://doi.org/10.1089/ten.teb.2017.0341>.
- Borumandi F, Higgins JP, Buerger H, Vasilyeva A, Benlidayi ME, Sencar L, et al. Arterialized venous bone flaps: an experimental investigation. *Sci Rep*. 2016;6:31970. <https://doi.org/10.1038/srep31970>.
- Higgins JP, Borumandi F, Burger HK, Benlidayi ME, Vasilyeva A, Sencar L, et al. Nonvascularized cartilage grafts Versus Vascularized Cartilage Flaps: comparison of Cartilage Quality 6 months after transfer. *J Hand Surg Am*. 2018;43(2):188. <https://doi.org/10.1016/j.jhbs.2017.09.014>. e1–e8.
- Imola MJ, Liddell A. Temporomandibular joint reconstruction. *Curr Opin Otolaryngol Head Neck Surg*. 2016;24(4):336–42. <https://doi.org/10.1097/MOO.0000000000000282>.
- Resnick CM. Temporomandibular Joint Reconstruction in the growing child. *Oral Maxillofac Surg Clin North Am*. 2018;30(1):109–21. <https://doi.org/10.1016/j.coms.2017.08.006>.
- Anderson SR, Pak KY, Vincent AG, Ong A, Ducic Y. Reconstruction of the Mandibular Condyle. *Facial Plast Surg*. 2021;37(06):728–34. <https://doi.org/10.1055/s-0041-1726444>.
- Sakai K, Doi K, Kawai S. Free vascularized thin corticoperiosteal graft. *Plast Reconstr Surg*. 1991;87(2):290–8.
- Sananpanich K, Kraissarin J. Descending genicular artery free flaps: multi-purpose tissue transfers in limb reconstruction. *J Plast Reconstr Aesthetic Surg*. 2015;68(6):846–52. <https://doi.org/10.1016/j.bjps.2015.02.003>.
- Haddock NT, Wapner K, Levin LS. Vascular bone transfer options in the Foot and Ankle. *Plast Reconstr Surg*. 2013;132(3):685–93. <https://doi.org/10.1097/PRS.0b013e31829acedd>.
- Rahmanian-Schwarz A, Spetzler V, Amr A, Pfau M, Schaller H-E, Hirt B. A Composite Osteomusculocutaneous Free Flap from the medial femoral Condyle for Reconstruction of Complex defects. *J Reconstr Microsurg*. 2011;27(04):251–60. <https://doi.org/10.1055/s-0031-1275489>.
- Deng AD, Innocenti M, Arora R, Gabl M, Tang JB. Vascularized small-bone transfers for fracture Nonunion and Bony defects. *Clin Plast Surg*. 2020;47(4):501–20. <https://doi.org/10.1016/j.cps.2020.06.005>.

29. Brandtner C, Hachleitner J, Bottini GB, Buerger H, Gaggl A. Microvascular medial femoral condylar flaps in 107 consecutive reconstructions in the head and neck. *Br J Oral Maxillofac Surg.* 2016;54(6):614–8. <https://doi.org/10.1016/j.bjoms.2016.03.007>.
30. Banaszewski J, Gaggl A, Andruszko A. Medial femoral condyle free flap for head and neck reconstruction. *Curr Opin Otolaryngol Head Neck Surg.* 2019;27(2):130–5. <https://doi.org/10.1097/MCO.0000000000000517>.
31. Svensson B, Adell R, Johansson C, Albrektsson T, Holm S. Growth of costochondral grafts in reconstruction of the mandibular condyle: an experimental study in domestic pigs. *Scand J Plast Reconstr Surg Hand Surg.* 2001;35(3):261–70. <https://doi.org/10.1080/028443101750523168>.
32. Zhu S, Hu J, Li J, Ying B. Reconstruction of mandibular condyle by transport distraction osteogenesis: experimental study in rhesus monkey. *J Oral Maxillofac Surg.* 2006;64(10):1487–92. <https://doi.org/10.1016/j.joms.2006.03.037>.
33. Chen D, Wu JY, Kennedy KM, Yeager K, Bernhard JC, Ng JJ, et al. Tissue engineered autologous cartilage-bone grafts for temporomandibular joint regeneration. *Sci Transl Med.* 2020;12(565). <https://doi.org/10.1126/scitranslmed.abb6683>.
34. Ma J-L, Pan J-L, Tan B-S, Cui F-Z. Determination of critical size defect of minipig mandible. *J Tissue Eng Regen Med.* 2009;3(8):615–22. <https://doi.org/10.1002/term.203>.
35. He D, Yang C, Chen M, Zhang X, Qiu Y, Yang X, et al. Traumatic temporomandibular joint ankylosis: our classification and treatment experience. *J Oral Maxillofac Surg.* 2011;69(6):1600–7. <https://doi.org/10.1016/j.joms.2010.07.070>.
36. Hamza A, Gidley PW, Learned KO, Hanna EY, Bell D. Uncommon tumors of temporomandibular joint: an institutional experience and review. *Head Neck.* 2020;42(8):1859–73. <https://doi.org/10.1002/hed.26106>.
37. DeMerle M, Nafiu OO, Aronovich S. Temporomandibular Joint Discectomy with Abdominal Fat Graft Versus Temporalis Myofascial Flap: a comparative study. *J Oral Maxillofac Surg.* 2017;75(6):1137–43. <https://doi.org/10.1016/j.joms.2016.11.028>.
38. Younis M, Shah AA, Hassan S, Kapoor M, Rashid A. Abdominal Dermis-Fat Graft Versus Conventional Temporalis Myofascial Flap Interposition in Temporomandibular Joint Ankylosis: a prospective clinical comparative study. *J Maxillofac Oral Surg.* 2021;20(1):54–62. <https://doi.org/10.1007/s12663-020-01455-3>.
39. Amarista FJ, Mercuri LG, Perez D. Temporomandibular Joint Prosthesis Revision and/or replacement survey and review of the literature. *J Oral Maxillofac Surg.* 2020;78(10):1692–703. <https://doi.org/10.1016/j.joms.2020.05.021>.
40. Donahue RP, Hu JC, Athanasiou KA. Remaining hurdles for Tissue-Engineering the Temporomandibular Joint Disc. *Trends Mol Med.* 2019;25(3):241–56. <https://doi.org/10.1016/j.molmed.2018.12.007>.
41. Vapniarsky N, Huwe LW, Arzi B, Houghton MK, Wong ME, Wilson JW, et al. Tissue engineering toward temporomandibular joint disc regeneration. *Sci Transl Med.* 2018;10(446). <https://doi.org/10.1126/scitranslmed.aag1802>.
42. Jiang N, Chen H, Zhang J, Cao P, Wang P, Hou Y, et al. Decellularized-disc based allograft and xenograft prosthesis for the long-term precise reconstruction of temporomandibular joint disc. *Acta Biomater.* 2023;159:173–87. <https://doi.org/10.1016/j.actbio.2023.01.042>.

### Publisher's Note

Springer Nature remains neutral with regard to jurisdictional claims in published maps and institutional affiliations.