

RESEARCH

Open Access



Needle tract seeding and abdominal recurrence following pre-treatment biopsy of gastrointestinal stromal tumors (GIST): results of a systematic review

Jens Jakob^{1*†}, Rashad Salameh^{2†}, David Wichmann³, Nicos Charalambous², Anne-Christine Zygmunt³, Inga Kreisel³, Judith Heinz⁴, Michael Ghadimi³ and Ulrich Ronellenfitsch⁵

Abstract

Background: Gastrointestinal stromal tumors (GIST) are rare abdominal tumors. Pretreatment biopsies may be used to diagnose a GIST and enable tailored treatment. Some experts are skeptical about biopsies because they fear tumor cell seeding. The objective of this study was to determine if pretreatment biopsy is associated with increased tumor recurrence.

Methods: We performed a systematic literature search and included studies assessing the oncological outcome of GIST patients who underwent a pre-treatment core needle biopsy or fine needle aspiration. We assessed methodological quality with the Newcastle-Ottawa-Scale for non-randomized studies. This review was registered in the PROSPERO database (CRD42021170290).

Results: Three non-randomized studies and eight case reports comprising 350 patients were eligible for inclusion. No prospective study designed to answer the review question was found. One case of needle tract seeding after percutaneous core needle biopsy of GIST was reported. None of the studies reported an increased rate of abdominal recurrence in patients with pretreatment biopsy.

Conclusions: The existing evidence does not indicate a relevant risk of needle tract seeding or abdominal recurrence after pre-treatment biopsy of GIST. Biopsy can safely be done to differentiate GIST from other tumors and to select the most appropriate treatment.

Keywords: Core needle biopsy, Fine needle aspiration, FNA, Preoperative biopsy, Metastasis, GIST

Introduction

Gastrointestinal stromal tumor (GIST) is the most frequent mesenchymal malignancy of the gastrointestinal tract [1]. The estimated worldwide incidence is 10–15

per million per year [2]. Most GIST are characterized by a gain of function mutation of c-kit and the platelet derived growth factor receptor (PDGFR) [3, 4]. Prognosis of locally advanced or metastatic GIST has improved remarkably after introduction of targeted therapy with receptor tyrosine kinase inhibitors (RTKI) [5–7].

The cornerstone of successful treatment of localized GIST is complete resection [8–10]. In locally advanced cases, preoperative treatment with the RTKI imatinib frequently leads to pronounced tumor response and

[†]Jens Jakob and Rashad Salameh contributed equally to this work

*Correspondence: Jens.Jakob@umm.de

¹Department of Surgery, Sarcoma Unit, University Medical Center Mannheim, Th.-Kutzer-Ufer 1–3, 68163 Mannheim, Germany
Full list of author information is available at the end of the article



reduced extent of the operation and surgical morbidity [11–15]. A prerequisite of imatinib efficacy is pre-treatment biopsy yielding proof of a sensitive mutation in c-kit or PDGFR. About 20–30% of all GIST are lacking KIT/PDGFR mutations; these tumors may yield defects in the succinate dehydrogenase (SDH) complex. [16] They may respond to treatment with other RTKI than imatinib. Nevertheless, a neoadjuvant treatment approach is not recommended in these cases.

Small GIST without mitotic activity (e.g. gastric GIST of less than 2 cm size) is frequently found as incidentaloma [17, 18]. Its prognosis is excellent and usually a watch-and-wait strategy is sufficient. A biopsy proving GIST and pointing towards a low risk of recurrence is helpful in decision-making in these cases. Many other GISTs are suspected after cross sectional imaging or endoscopy indicated for (occult) gastrointestinal bleeding, pain, or gastrointestinal passage disorders [19]. Differential diagnoses are benign lesions but also lymphoma, neuroendocrine carcinoma, or other sarcoma subtypes [20–22]. Multimodal treatment of these tumors is different and surgical strategies vary in those patients who require resection (e.g., lymphadenectomy, e.g., dimension of resection margins etc.) [23–25].

In summary, pre-treatment biopsies may help to guide treatment decisions and improve shared decision making in GIST patients. However, some experts are skeptical about biopsies because they fear tumor seeding and increased recurrence rates. Needle tract seeding has in fact been reported for various other abdominal tumors [26–30]. However, the incidence of needle tract seeding after pre-treatment biopsy of GIST remains unknown. Furthermore, current NCCN, ESMO and UK guidelines do not cite prospective studies evaluating the risk of recurrence after pretreatment biopsy considering different biopsy techniques, adjuvant treatment and tumor-associated risk of recurrence [8–10]. We therefore initiated this systematic review to evaluate the rate of abdominal wall and peritoneal recurrences after pre-treatment biopsy of GIST.

Materials and methods

This review was conducted according to the Preferred Reporting Items for Systematic Reviews and Meta-Analyses (PRISMA) and registered in the PROSPERO database, an international register of systematic reviews (register number CRD42021170290). The registration is accessible online (https://www.crd.york.ac.uk/prosp/ero/display_record.php?ID=CRD42021170290). The PRISMA checklist is provided in the Additional file 1. No financial or non-financial support was given for the review.

Review question and eligibility criteria

The primary review question was evaluating the risk of needle tract seeding and recurrence after pretreatment biopsy of suspected GIST. Studies evaluating adult patients (18 years or older) with suspected GIST were included. Studies with at least one patient with suspected GIST and pre-treatment biopsy were included. Studies without information on oncological outcome (e.g., survival, rate, or number of local or distant recurrences, rate or number of needle tract seeding) were excluded. Assumed influencing factors such as biopsy technique, adjuvant treatment and tumor-associated risk of recurrence were documented and analyzed. Eligible studies were searched for the outcome of patients who did not undergo pre-treatment biopsies for comparison.

Information sources and search strategy

As of 3rd of November 2021, the PubMed database was searched for eligible studies (search strategy in Table 1). Additionally, the bibliographies of the included studies were hand-searched for eligible references. Moreover, data and references from the NCCN, UK and ESMO guideline for diagnosis and treatment of GIST were searched [8–10]. Prospective and retrospective studies of any design as well as case reports and reviews were included. Publications in English and German-language were included into the analysis. No restrictions were made for publication date.

Study selection and data extraction

Two investigators (JJ, RS) reviewed all selected abstracts independently. Disagreement was resolved by consensus. Data were extracted from the full text articles of the selected abstracts independently by two investigators (JJ, RS). If available, the following pre-specified data were extracted: name of first author and year of publication, type of study, number of patients, number of patients with GIST, tumor associated risk of recurrence, number of patients with GIST undergoing pre-treatment biopsy, type of biopsy (percutaneous core needle biopsy (CNB) vs. percutaneous fine needle aspiration (p-FNA) vs. endoscopic ultrasound guided fine needle aspiration (EUS-FNA)), number of patients with adjuvant imatinib treatment, number of patients with seeding along the biopsy tract, number of patients with recurrence, number of patients with recurrence possibly associated with pre-treatment biopsy, number or procedure associated complications, accuracy/sensitivity/specificity of pre-treatment biopsy.

Table 1 Search strategy

Search #	Title	Terms	Hits
1	GIST	"gastrointestinal"[Title/Abstract] AND "stromal"[Title/Abstract] AND ("tumor"[Title/Abstract] OR "tumors"[Title/Abstract] OR "neoplasm"[Title/Abstract] OR "neoplasms"[Title/Abstract] OR "sarcoma"[Title/Abstract] OR "sarcomas"[Title/Abstract] OR "cancer"[Title/Abstract] OR "cancers"[Title/Abstract])	9760
2	Biopsy	"biop*"[Title/Abstract] OR "fine needle"[Title/Abstract] OR "core needle"[Title/Abstract]	569,221
3		#1 AND #2	877
4	Survival	survival[Title/Abstract] OR mortality[Title/Abstract] OR death[Title/Abstract]	2,293,766
5	Recurrence	"recurrence"[Title/Abstract]	321,063
6	Seeding	"seeding"[Title/Abstract] OR "metastasis"[Title/Abstract] OR "metastases"[Title/Abstract]	406,051
7		#4 OR #5 OR #6	2,748,749
8		#3 AND #7	264
9		#3 AND #7 Filters: Humans	205
10		#3 AND #7 Filters: Humans; English	150

Assessment of methodological quality

Assessment of methodological quality was done at study level. Since most studies were expected to be cohort studies, we performed assessment of methodological quality with the Newcastle-Ottawa-Scale (NOS) [31]. The NOS contains eight items for cohort studies, categorized into three dimensions: selection, comparability, and outcome. Studies that received a score of seven or above were considered as high quality. Three reviewers (RS, UR, JJ) performed quality assessment. Disagreements were resolved by discussion and consensus.

Statistical analysis

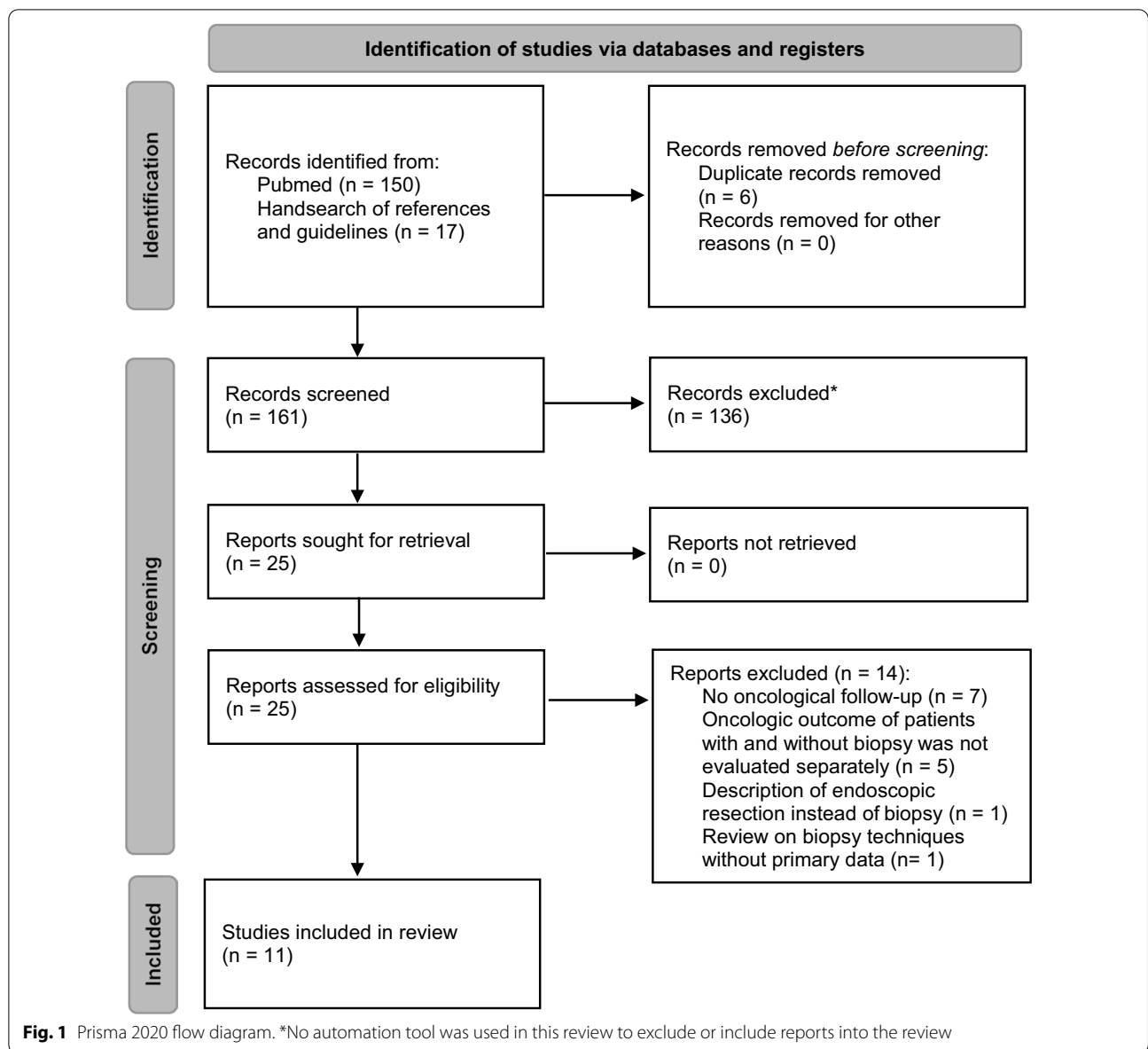
Data are presented descriptively as numbers of patients, median or mean and range. Due to the heterogeneous study designs and the poor data availability a quantitative data synthesis and analysis was not feasible.

Results

The database searches produced 150 articles (Fig. 1: PRISMA flow diagram). Seventeen additional articles were identified through retrieval and search of the references and the NCCN, UK and ESMO guidelines [8–10]. Twenty-five full-text articles were assessed for eligibility. Fourteen full text articles were excluded from the review [32–45]. Excluded manuscripts either reported technical aspects of but not oncological follow up after GIST biopsies ($n=7$), described cases of endoscopic resection instead of biopsy ($n=1$), summarized the oncologic outcome of patients with and without biopsy without addressing who had more recurrences

($n=5$) or comprised reviews on biopsy techniques without presenting primary data ($n=1$).

The literature review did not identify any prospective study that evaluated the association between biopsy and recurrence in GIST. Besides eight case reports [46–53], three retrospective studies [54–56] were included in the review (compare Table 2): Akahoshi et al. evaluated the oncological outcome of patients with small gastric GIST who had undergone pretreatment EUS-FNA prior to tumor resection [56]. The authors reported correctness of the pretherapeutic biopsies in 32 of 44 cases (73%), and there were no biopsy-associated complications and no recurrences. The authors concluded that pretreatment EUS-FNA is safe and efficient in small gastric GIST. Eriksson et al. performed a post hoc analysis of the SSG/AIO adjuvant trial for GIST [55]. All patients had high risk GIST and all patients received adjuvant imatinib. Forty-seven of the 389 patients in the study had undergone a pretherapeutic biopsy (CNB or FNA or both). At a median follow-up of 54 months, there was no difference in tumor-free survival as a function of biopsy. In subgroup analysis, recurrence free survival was improved in patients with GIST larger than 10 cm who had undergone pretreatment biopsies. The authors concluded that pretreatment biopsy of a suspected GIST may not increase the risk for recurrence in patients who receive adjuvant imatinib after the biopsy. Houdt et al. evaluated prospective GIST databases from two referral centers [54]. They included 220 patients in the analysis, 186 of whom had received a pretherapeutic biopsy (CNB, FNA or both). In multivariate analysis adjusting for tumor and treatment-associated factors (including adjuvant imatinib and risk of recurrence), pretherapeutic biopsy



did not increase the recurrence rate. Of the 186 patients with biopsy, one patient had a biopsy-associated local recurrence after percutaneous core needle biopsy; comparison of computed tomography scans during the biopsy and at the time of recurrence show that the local recurrence was located immediately in the needle tract of the biopsy.

Eight case reports describe surgical or multimodal treatment of GIST after pre-treatment biopsy. Tumor recurrence was not reported in any of the case reports (Table 3). No case report of needle tract seeding after pretreatment biopsy of GIST was published.

Assessment of methodological quality using the Newcastle-Ottawa Scale is displayed in Table 4. The overall

methodological quality of studies revealed that three studies were of high quality. One study was of moderate quality because of a lack of comparability.

Discussion

A pre-treatment histology is the prerequisite and cornerstone of shared decision making and multimodal treatment considerations. There is strong evidence of a survival advantage for patients who were treated according to multidisciplinary tumor board decisions before surgery and who had surgery at expert centers [57–59]. Nevertheless, the risk of tumor cell dissemination is frequently discussed in the context of GIST biopsies. The current NCCN guideline acknowledges these concerns

Table 2 Details of the selected studies

First author and year of publication	Houdt 2021 [54]	Akahoshi 2014 [56]	Eriksson 2016 [55]
Study type	Retrospective analysis of two prospectively kept databases	Retrospective analysis of one prospectively kept database	Posthoc analysis of a randomized trial
Aim of the study	to evaluate local recurrence free survival and disease specific survival of GIST patients with or without pretreatment biopsy	To define diagnostic accuracy and safety of and tumor recurrence after EUS-FNA of gastric GIST	To evaluate if percutaneous tumor biopsy has an impact on RFS and OS in patients with GIST receiving adjuvant imatinib after tumor resection
Number of patients	228	44	389
Risk of recurrence (low, intermediate, high)	86, 43, 80, (19 unknown)	33, 10, 0	0, 0, 389
Patients with (neo-) adjuvant imatinib	Neoadjuvant 100 adjuvant 158	0	Adjuvant 389
Patients with biopsy	186	44	47
Biopsy technique	CNB = 166, FNA = 20, Transcutaneous = 70, Endoluminal = 116	EUS-FNA = 44	CNB = 33, FNA = 22, CNB and FNA = 8
Complications of biopsy	N/A	0	N/A
Number of correct diagnoses from pretreatment biopsies	N/A	32	N/A
Recurrence related to biopsy	1	0	N/A ^b
Total number of abdominal wall or peritoneal recurrences	25	0	N/A ^b
Follow-up (months)	Median = 53	Mean = 35, range = 2–108	Median = 54 ^a

^a Median follow-up was not reported in the manuscript of Eriksson et al. We report median follow-up as reported in the primary publication of the trial [55]

^b Only recurrence free survival (RFS) and overall survival (OS) presented

Table 3 Details of the selected case reports

First author and year of publication	Cecka 2011	Min Wang 2020	Suzuki 2011	Wollina 2015	Kane 2019	Nakamura 2012	Yin 2018	Zhang 2021
Risk of recurrence (low, intermediate, high)	High risk	High risk	High risk	Intermediate risk	Intermediate risk	Intermediate risk	High risk	High risk
Adjuvant imatinib	0	0	1	1	1	1	1	1
Patients with biopsy	1	1	1	1	1	1	1	1
Complications of biopsy	N/A	N/A	N/A	N/A	N/A	N/A	N/A	0
Number of correct diagnoses from pretreatment biopsies	1	1	1	1	1	1	1	1
Recurrence related to biopsy	0	0	0	0	0	0	0	0
Total number of abdominal wall or peritoneal recurrences	0	0	0	0	0	0	0	0
Follow-up (months)	66	12	14	8	18	30	48	20

and considers endoscopic biopsy to be advantageous over percutaneous biopsy due to the assumed lower risk of intra-abdominal tumor dissemination [8]. Therefore, the

primary question of this systematic review was whether there is evidence for an increased risk of recurrence of needle tract seeding after pretreatment biopsy of GIST.

Table 4 Assessment of methodological quality with the Newcastle-Ottawa-Scale

Publication (first author, year)	Selection (up to ****)	Comparability (up to **)	Outcome (up to ***)
Eriksson 2016 [55]	****	**	***
Akahoshi 2014 [56]	***		**
Houdt 2021 [54]	****	**	***

As main results, this systematic review revealed that the association of biopsy and recurrence of GIST was never evaluated in a prospective trial, that only one case of needle tract seeding has been reported so far, and that no study reported increased recurrence rates after pretreatment GIST biopsy.

In other malignancies, systematic reviews and meta-analyses point towards a certain risk of needle tract seeding. The highest risk is reported for hepatocellular carcinoma (HCC) with 2.7% [60]. The estimated incidence of needle tract seeding in other tumors is much lower than 1% [61, 62]. The estimated incidence in other soft tissue sarcomas was evaluated in a pooled analysis of four cohorts evaluating 547 patients with retroperitoneal sarcomas [63]. The authors reported two cases of needle tract seeding resulting in an estimated incidence of 0.37% that is comparable to the results of this review.

Apart from tumor biology, the biopsy technique itself may influence the risk of needle tract seeding and recurrence. Regarding biopsy route and technique, percutaneous core needle biopsies may have the highest risk for needle tract seeding. In concordance, the only case of needle tract seeding in our review was documented after percutaneous CNB – if a coaxial sheathed biopsy needle was used as recommended was not reported [54, 64]. We did also include cases with endoscopic fine needle aspirations in this analysis for two reasons: First, there were case reports of bleeding into the abdominal cavity after EUS-FNA, and we assume that if bleeding into the abdominal cavity occurs, the same might be true for tumor seeding [65, 66]. There was one cohort study reporting oncological results after EUS-FNA of small GIST without any recurrence [56]. Although the risk of recurrence in small gastric GIST is low or very low in general, we still think this is an important piece of information since a single recurrence would be a very strong indicator of a clinically relevant tumor cell dissemination after EUS-FNA in small gastric GIST. Thus, EUS-FNA may be safely used in these tumors to confirm the diagnosis or differentiate these lesions from other gastric tumors.

Tumor risk of recurrence and the administration of adjuvant treatment may have an impact on the incidence of tumor growth after biopsy-related tumor cell

dissemination. Both factors are related to each other. Patients with intermediate or high risk GIST frequently receive adjuvant treatment [8–10]. According to the post-hoc analysis of the SSG-AIO adjuvant trial, these patients do not have an increased risk of recurrence [55]. In general, the data identified and summarized in this review are not sufficient to stratify the risk of recurrence after biopsy according to general risk of recurrence and administration of adjuvant treatment. If preoperative imatinib treatment may lead to less invasive surgery and organ preservation in intermediate or high risk GIST, patients are recommended to undergo a biopsy to enable tailored treatment [8–10]. Several studies are available on neoadjuvant treatment of GIST [11–15, 67–70]. We assumed that biopsies had been taken before preoperative treatment and screened the full text manuscripts. None of the studies explicitly discussed the methodology of pre-therapeutic biopsies. Neither described a case of needle tract seeding.

It arises the question if those who receive surgery as the only treatment are exposed to an increased risk of recurrence after pretreatment biopsy. For small GIST, there does not seem to be any increased risk (see above). Yet, it is one limitation of this review that we cannot present data for patients with intermediate or high risk GIST who underwent surgery alone. Upfront resection may be an alternative provided that resection morbidity is low (e.g. laparoscopic gastric wedge resection) and other histologies have been taken into account (e.g. lymphoma, neuroendocrine tumors).

This systematic review has limitations. No prospective study was found which was designed to answer the review question with its primary endpoint. Only retrospective studies, post hoc analyses and case reports were available. This systematic review relied on a limited number of databases for the identification of potentially eligible studies. The included studies lack clear correlations or information on the risk of metastasis, adjuvant therapy, type of biopsy as well as localization of tumor recurrence. Due to the limited and heterogeneous data, no statistical analysis in the sense of a meta-analysis or a subgroup analysis was possible. The total number of patients included is small and we only included GIST patients and no patients with other abdominal tumors. These limitations may be overcome by conducting a well-designed randomized prospective trial evaluating the risks and benefits of pretreatment biopsies in general. Such a prospective trial should comprise not only GIST patients but patients with any abdominal mass suspected to be a malignant tumor. It would require thorough statistical preparation taking into account the incidence of various tumors, the relevance of preoperative treatment and the known or estimated risk of needle tract seeding.

Despite these limitations, the results of the present literature review and evidence synthesis may help patients and physicians decide whether to perform a biopsy in the presence of an abdominal mass.

Conclusions

There is a strong rationale to perform pretreatment biopsies in GIST. Histological proof of GIST enables shared decision making and multimodal treatment according to guidelines after discussion in multidisciplinary tumor boards – ultimately leading to potentially improved survival. This systematic literature review revealed no increased recurrence rates after EUS-FNA of low risk GIST treated by surgery and no increased recurrence rates after biopsy of intermediate and high risk GIST treated with combined medical and surgical treatment. For patients with intermediate- or high-risk GIST treated by surgery alone, this review contains only few data, and the safety of pretreatment biopsy cannot formally be proven. On the other hand, no cases of biopsy-associated recurrence were reported. In conclusion, the following pragmatic conclusions may be drawn from this systematic review: technically correctly performed GIST biopsies are safe and have a very low risk of needle tract seeding. Upfront resection as an alternative may be performed if resection morbidity is expected to be low (e.g. laparoscopic gastric wedge resection), other histologies (e.g. lymphoma, neuroendocrine tumors) are taken into account, and preoperative treatment is unlikely to decrease the extent of surgery.

Abbreviations

CNB: Core needle biopsy; ESMO: European society of medical oncology; FNA: Fine needle aspiration; GIST: Gastrointestinal stromal tumor; NCCN: National comprehensive cancer network; NOS: Newcastle Ottawa Scale; RTKI: Receptor tyrosine kinase inhibitor; UK: United Kingdom.

Supplementary information

The online version contains supplementary material available at <https://doi.org/10.1186/s12893-022-01648-2>.

Additional file 1: The following supporting information can be downloaded: Prisma statements CRD42021170290.

Acknowledgements

The authors thank Anne Wöhl (University Medical Center Göttingen) and Gabriele Pospiech (University Medical Center Mannheim) for administrative support.

Author contributions

Conceptualization, RS and JJ; methodology, JH; validation, UR and MG; formal analysis, JH, UR, RS and JJ; investigation, RS, DW, NC, AZ and IK; resources, MG; data curation, RS, DW, NC, AZ, IK and JJ; writing—original draft preparation, RS, and JJ; writing—review and editing, JH, MG and UR; visualization, JJ; supervision, UR. All authors have read and agreed to the published version of the manuscript.

Funding

Open Access funding enabled and organized by Projekt DEAL. This research received no external funding.

Availability of data and materials

Further data are available from the corresponding author upon reasonable request.

Declarations

Ethics approval and consent to participate

Not applicable.

Consent for publication

Not applicable.

Competing interests

JJ received travel grants and honoraria from Novartis Pharma. Novartis Pharma had no role in the design of the study; in the collection, analyses, or interpretation of data; in the writing of the manuscript, or in the decision to publish the results.

Author details

¹Department of Surgery, Sarcoma Unit, University Medical Center Mannheim, Th.-Kutzer-Ufer 1–3, 68163 Mannheim, Germany. ²Department of Visceral, Thoracic, Vascular and Transplant Surgery, University Hospital Dresden, Dresden, Germany. ³Department of General, Visceral and Pediatric Surgery, University Medical Center, Goettingen, Germany. ⁴Department of Medical Statistics, University Medical Center Goettingen, Goettingen, Germany. ⁵Department of Surgery, University Hospital Halle, Halle, Germany.

Received: 7 April 2022 Accepted: 12 May 2022

Published online: 21 May 2022

References

1. Rensing M, Wardelmann E, Hohenberger P, Jakob J, Kasper B, Emrich K, et al. Strengthening health data on a rare and heterogeneous disease: sarcoma incidence and histological subtypes in Germany. *BMC Public Health*. 2018;18(1):235.
2. Soreide K, Sandvik OM, Soreide JA, Giljaca V, Jureckova A, Bulusu VR. Global epidemiology of gastrointestinal stromal tumours (GIST): a systematic review of population-based cohort studies. *Cancer Epidemiol*. 2016;40:39–46.
3. Nakahara M, Isozaki K, Hirota S, Miyagawa J, Hase-Sawada N, Taniguchi M, et al. A novel gain-of-function mutation of c-kit gene in gastrointestinal stromal tumors. *Gastroenterology*. 1998;115(5):1090–5.
4. Huss S, Pasternack H, Ihle MA, Merkelbach-Bruse S, Heitkötter B, Hartmann W, et al. Clinicopathological and molecular features of a large cohort of gastrointestinal stromal tumors (GISTs) and review of the literature: BRAF mutations in KIT/PDGFRα wild-type GISTs are rare events. *Hum Pathol*. 2017;62:206–14.
5. Demetri GD, von Mehren M, Blanke CD, Van den Abbeele AD, Eisenberg B, Roberts PJ, et al. Efficacy and safety of imatinib mesylate in advanced gastrointestinal stromal tumors. *N Engl J Med*. 2002;347(7):472–80.
6. Joensuu H, Roberts PJ, Sarlomo-Rikala M, Andersson LC, Tervahartiala P, Tuveson D, et al. Effect of the tyrosine kinase inhibitor STI571 in a patient with a metastatic gastrointestinal stromal tumor. *N Engl J Med*. 2001;344(14):1052–6.
7. Rizzo A, Nannini M, Novelli M, Dalia Ricci A, Scioscio VD, Pantaleo MA. Dose reduction and discontinuation of standard-dose regorafenib associated with adverse drug events in cancer patients: a systematic review and meta-analysis. *Ther Adv Med Oncol*. 2020;12:1758835920936932.
8. NCCN. National Comprehensive Cancer Network. Gastrointestinal stromal tumors (GISTs) (Version 1.2021). https://www.nccn.org/login?ReturnURL=https://www.nccn.org/professionals/physician_gls/pdf/gist.pdf. Assessed 16 Aug 2021.
9. Casali PG, Abecassis N, Aro HT, Bauer S, Biagini R, Bielack S, et al. Soft tissue and visceral sarcomas: ESMO–EURACAN Clinical Practice Guidelines

- for diagnosis, treatment and follow-up. *Ann Oncol.* 2018;29(Suppl 4):iv51–67.
10. Judson I, Bulusu R, Seddon B, Dangoor A, Wong N, Mudan S. UK clinical practice guidelines for the management of gastrointestinal stromal tumours (GIST). *Clin Sarcoma Res.* 2017;7:6.
 11. Cavnar MJ, Seier K, Gönen M, Curtin C, Balachandran VP, Tap WD, et al. Prognostic factors after neoadjuvant imatinib for newly diagnosed primary gastrointestinal stromal tumor. *J Gastrointest Surg.* 2020.
 12. Jakob J, Hohenberger P. Neoadjuvant therapy to downstage the extent of resection of gastrointestinal stromal tumors. *Visc Med.* 2018;34(5):359–65.
 13. Kurokawa Y, Yang HK, Cho H, Ryu MH, Masuzawa T, Park SR, et al. Phase II study of neoadjuvant imatinib in large gastrointestinal stromal tumours of the stomach. *Br J Cancer.* 2017;117(1):25–32.
 14. Rutkowski P, Gronchi A, Hohenberger P, Bonvalot S, Schoffski P, Bauer S, et al. Neoadjuvant imatinib in locally advanced gastrointestinal stromal tumors (GIST): the EORTC STBSG experience. *Ann Surg Oncol.* 2013;20(9):2937–43.
 15. Wang SY, Wu CE, Lai CC, Chen JS, Tsai CY, Cheng CT, et al. Prospective evaluation of neoadjuvant imatinib use in locally advanced gastrointestinal stromal tumors: emphasis on the optimal duration of neoadjuvant imatinib use, safety, and oncological outcome. *Cancers (Basel).* 2019;11(3).
 16. Indio V, Schipani A, Nannini M, Urbini M, Rizzo A, De Leo A, et al. Gene expression landscape of SDH-deficient gastrointestinal stromal tumors. *J Clin Med.* 2021;10(5).
 17. Fernandez JA, Gomez-Ruiz AJ, Olivares V, Ferri B, Frutos MD, Soria T, et al. Clinical and pathological features of “small” GIST ($\leq 2\text{ cm}$). What is their prognostic value? *Eur J Surg Oncol.* 2018;44(5):580–6.
 18. Apte SS, Radonjic A, Wong B, Dingley B, Boulva K, Chatterjee A, et al. Preoperative imaging of gastric GISTs underestimates pathologic tumor size: a retrospective, single institution analysis. *J Surg Oncol.* 2021;124(1):49–58.
 19. Menge F, Jakob J, Kasper B, Smakic A, Gaiser T, Hohenberger P. Clinical presentation of gastrointestinal stromal tumors. *Visc Med.* 2018;34(5):335–40.
 20. Kang HC, Menias CO, Gaballah AH, Shroff S, Taggart MW, Garg N, et al. Beyond the GIST: mesenchymal tumors of the stomach. *Radiographics.* 2013;33(6):1673–90.
 21. Lin YM, Chiu NC, Li AF, Liu CA, Chou YH, Chiou YY. Unusual gastric tumors and tumor-like lesions: radiological with pathological correlation and literature review. *World J Gastroenterol.* 2017;23(14):2493–504.
 22. Shinya T, Inai R, Tanaka T, Akagi N, Sato S, Yoshino T, et al. Small bowel neoplasms: enhancement patterns and differentiation using post-contrast multiphasic multidetector CT. *Abdom Radiol (NY).* 2017;42(3):794–801.
 23. Casali PG, Abecassis N, Aro HT, Bauer S, Biagini R, Bielack S, et al. Gastrointestinal stromal tumours: ESMO-EURACAN Clinical Practice Guidelines for diagnosis, treatment and follow-up. *Ann Oncol.* 2018;29(Suppl 4):iv68–78.
 24. Pavel M, Öberg K, Falconi M, Krenning EP, Sundin A, Perren A, et al. Gastroenteropancreatic neuroendocrine neoplasms: ESMO Clinical Practice Guidelines for diagnosis, treatment and follow-up. *Ann Oncol.* 2020;31(7):844–60.
 25. Romain B, Delhorme JB, Manceau G, Lefevre JH, Tresallet C, Mariani P, et al. Is nonanatomic rectal resection a valid therapeutic option for rectal gastrointestinal stromal tumors? A proposed decision algorithm. *J Surg Oncol.* 2020;122(8):1639–46.
 26. Bergenfeldt M, Genell S, Lindholm K, Ekberg O, Aspelin P. Needle-tract seeding after percutaneous fine-needle biopsy of pancreatic carcinoma. Case report. *Acta Chir Scand.* 1988;154(1):77–9.
 27. Lee IS, Nguyen S, Shanberg AM. Needle tract seeding after percutaneous biopsy of Wilms tumor. *J Urol.* 1995;153(3 Pt 2):1074–6.
 28. Pasieka JL, Thompson NW. Fine-needle aspiration biopsy causing peritoneal seeding of a carcinoid tumor. *Arch Surg.* 1992;127(10):1248–51.
 29. Takahashi N, Taniguchi T, Adachi M. A case of needle tract seeding of an intraductal papillary neoplasm of the bile duct (IPNB) after percutaneous biopsy. *Eur J Dermatol.* 2014;24(1):128–30.
 30. Vergara V, Garripoli A, Marucci MM, Bonino F, Capussotti L. Colon cancer seeding after percutaneous fine needle aspiration of liver metastasis. *J Hepatol.* 1993;18(3):276–8.
 31. GA Wells BS, D’O’Connell, J Peterson, V Welch, M Losos, P Tugwell. The Newcastle-Ottawa Scale (NOS) for assessing the quality of nonrandomised studies in meta-analyses. http://www.ohri.ca/programs/clinical_epidemiology/oxford.asp. Accessed 16 Aug 2021.
 32. Akahoshi K, Sumida Y, Matsui N, Oya M, Akinaga R, Kubokawa M, et al. Preoperative diagnosis of gastrointestinal stromal tumor by endoscopic ultrasound-guided fine needle aspiration. *World J Gastroenterol.* 2007;13(14):2077–82.
 33. Ando N, Goto H, Niwa Y, Hirooka Y, Ohmiya N, Nagasaka T, et al. The diagnosis of GI stromal tumors with EUS-guided fine needle aspiration with immunohistochemical analysis. *Gastrointest Endosc.* 2002;55(1):37–43.
 34. He Z, Sun C, Wang J, Zheng Z, Yu Q, Wang T, et al. Efficacy and safety of endoscopic submucosal dissection in treating gastric subepithelial tumors originating in the muscularis propria layer: a single-center study of 144 cases. *Scand J Gastroenterol.* 2013;48(12):1466–73.
 35. Sato T, Peiper M, Fritscher-Ravens A, Gocht A, Soehendra N, Knoefel WT. Strategy of treatment of submucosal gastric tumors. *Eur J Med Res.* 2005;10(7):292–5.
 36. Vander Noot MR, Eloubeidi MA, Chen VK, Eltoun I, Jhala D, Jhala N, et al. Diagnosis of gastrointestinal tract lesions by endoscopic ultrasound-guided fine-needle aspiration biopsy. *Cancer.* 2004;102(3):157–63.
 37. Yang Z, Feng X, Zhang P, Chen T, Qiu H, Zhou Z, et al. Clinicopathological features and prognosis of 276 cases of primary small ($\leq 2\text{ cm}$) gastric gastrointestinal stromal tumors: a multicenter data review. *Surg Endosc.* 2019;33(9):2982–90.
 38. Terada T. Gastrointestinal stromal tumor of the digestive organs: a histopathologic study of 31 cases in a single Japanese institute. *Int J Clin Exp Pathol.* 2009;3(2):162–8.
 39. Scarpa M, Bertin M, Ruffolo C, Polese L, D’Amico DF, Angriman I. A systematic review on the clinical diagnosis of gastrointestinal stromal tumors. *J Surg Oncol.* 2008;98(5):384–92.
 40. Madden JF, Burchette JL, Raj GV, Daly JT, Tannenbaum M. Anterior rectal wall gastrointestinal stromal tumor presenting clinically as prostatic mass. *Urol Oncol.* 2005;23(4):268–72.
 41. Kakkar A, Mathur SR, Jain D, Iyer VK, Nalwa A, Sharma MC. Utility of DOG1 immunomarker in fine needle aspirates of gastrointestinal stromal tumor. *Acta Cytolog.* 2015;59(1):61–7.
 42. Dhaliwal A, Kolli S, Dhindsa BS, Devani K, Ramai D, Sayles H, et al. Clinical efficacy and safety of mucosal incision-assisted biopsy for the diagnosis of upper gastrointestinal subepithelial tumors: a systematic review and meta-analysis. *Ann Gastroenterol.* 2020;33(2):155–61.
 43. Blum MG, Bilimoria KY, Wayne JD, de Hoyos AL, Talamonti MS, Adley B. Surgical considerations for the management and resection of esophageal gastrointestinal stromal tumors. *Ann Thorac Surg.* 2007;84(5):1717–23.
 44. Artigiani Neto R, Logullo AF, Stávale JN, Lourenço LG. Ki-67 expression score correlates to survival rate in gastrointestinal stromal tumors (GIST). *Acta Cirurg Brasileira.* 2012;27(5):315–21.
 45. Hølmekjær T, Hompland I, Bjerkehaugen B, Stoldt S, Bruland ØS, Hall KS, et al. Recurrence-free survival after resection of gastric gastrointestinal stromal tumors classified according to a strict definition of tumor rupture: a population-based study. *Ann Surg Oncol.* 2018;25(5):1133–9.
 46. Čečka F, Jon B, Ferko A, Šubrt Z, Nikolov DH, Tyčová V. Long-term survival of a patient after resection of a gastrointestinal stromal tumor arising from the pancreas. *Hepatobiliary Pancreat Dis Int.* 2011;10(3):330–2.
 47. Kane WJ, Friel CM. Diagnosis and treatment of rectal gastrointestinal stromal tumors. *Dis Colon Rectum.* 2019;62(5):537–40.
 48. Nakamura T, Mitomi H, Onozato W, Sato T, Ikeda A, Naito M, et al. Laparoscopic resection of a gastrointestinal stromal tumor of the rectum after treatment with imatinib mesylate: report of a case. *Surg Today.* 2012;42(11):1096–9.
 49. Suzuki T, Sadahiro S, Tanaka A, Okada K, Okamura H, Machida T, et al. Gastrointestinal stromal tumor of the rectum: report of three cases. *Tokai J Exp Clin Med.* 2011;36(3):58–62.
 50. Wang M, Qiu X, He X, Tian C. Characteristic of extra luminal gastric stromal tumor arising from the lesser curvature of the stomach: a case report. *Medicine (Baltimore).* 2020;99(16):e19885.
 51. Wollina U, Hansel G, Zimmermann F, Schönlebe J, Nowak A. Merkel cell carcinoma of the lower leg with retroperitoneal GIST: a very rare association. *Wien Klin Wochenschr.* 2015;127(9–10):402–5.

52. Yin X, Shen C, Yin Y, Cai Z, Chen Z, Zhang B. Giant gastric stromal tumor mimicking as a posterior mediastinal mass: a case report and literature review. *Medicine (Baltimore)*. 2018;97(41):e12816.
53. Zhang Q, Zhao JY, Zhuang H, Lu CY, Yao J, Luo Y, et al. Transperineal core-needle biopsy of a rectal subepithelial lesion guided by endorectal ultrasound after contrast-enhanced ultrasound: a case report. *World journal of gastroenterology*. 2021;27(13):1354–61.
54. van Houdt WJ, NS IJ, Marjolein Schrijver A, Huis In 't Veld E, Thway K, Jones RL, et al. Oncological Outcome After Diagnostic Biopsies in Gastrointestinal Stromal Tumors: A Retrospective Cohort Study. *Ann Surg*. 2021;274(6):e1093–e8.
55. Eriksson M, Reichardt P, Sundby Hall K, Schutte J, Cameron S, Hohenberger P, et al. Needle biopsy through the abdominal wall for the diagnosis of gastrointestinal stromal tumour—does it increase the risk for tumour cell seeding and recurrence? *Eur J Cancer*. 2016;59:128–33.
56. Akahoshi K, Oya M, Koga T, Koga H, Motomura Y, Kubokawa M, et al. Clinical usefulness of endoscopic ultrasound-guided fine needle aspiration for gastric subepithelial lesions smaller than 2 cm. *J Gastrointest Liver Dis*. 2014;23(4):405–12.
57. Gronchi A, Bonvalot S, Poveda Velasco A, Kotasek D, Rutkowski P, Hohenberger P, et al. Quality of surgery and outcome in localized gastrointestinal stromal tumors treated within an international intergroup randomized clinical trial of adjuvant imatinib. *JAMA Surg*. 2020;155(6):e200397.
58. Blay JY, Honore C, Stoeckle E, Meeus P, Jafari M, Gouin F, et al. Surgery in reference centers improves survival of sarcoma patients: a nationwide study. *Ann Oncol*. 2019;30(7):1143–53.
59. Blay JY, Soibinet P, Penel N, Bompas E, Duffaud F, Stoeckle E, et al. Improved survival using specialized multidisciplinary board in sarcoma patients. *Ann Oncol*. 2017;28(11):2852–9.
60. Silva MA, Hegab B, Hyde C, Guo B, Buckels JA, Mirza DF. Needle track seeding following biopsy of liver lesions in the diagnosis of hepatocellular cancer: a systematic review and meta-analysis. *Gut*. 2008;57(11):1592–6.
61. Polyzos SA, Anastasilakis AD. A systematic review of cases reporting needle tract seeding following thyroid fine needle biopsy. *World J Surg*. 2010;34(4):844–51.
62. Volanis D, Neal DE, Warren AY, Gnanapragasam VJ. Incidence of needle-tract seeding following prostate biopsy for suspected cancer: a review of the literature. *BJU Int*. 2015;115(5):698–704.
63. Van Houdt WJ, Schrijver AM, Cohen-Hallaleh RB, Memos N, Fotiadis N, Smith MJ, et al. Needle tract seeding following core biopsies in retroperitoneal sarcoma. *Eur J Surg Oncol*. 2017;43(9):1740–5.
64. Renshaw AA, Powell A, Caso J, Gould EW. Needle track seeding in renal mass biopsies. *Cancer Cytopathol*. 2019;127(6):358–61.
65. Carrara S, Arcidiacono PG, Giussani A, Testoni PA. Acute hemorrhage with retroperitoneal hematoma after endoscopic ultrasound-guided fine-needle aspiration of an intraductal papillary mucinous neoplasm of the pancreas. *Am J Gastroenterol*. 2009;104(6):1610–1.
66. Lew SQ, Khan AA, Rieders B, Agrawal ST. Haemoperitoneum after an endoscopic ultrasound-guided fine-needle aspiration (EUS-FNA) of a pancreatic lesion in a peritoneal dialysis patient. *BMJ Case Reports*. 2020;13(11).
67. Vassos N, Jakob J, Kähler G, Reichardt P, Marx A, Dimitrakopoulou-Strauss A, et al. Preservation of organ function in locally advanced non-metastatic gastrointestinal stromal tumors (GIST) of the stomach by neoadjuvant imatinib therapy. *Cancers (Basel)*. 2021;13(4).
68. Hohenberger P, Langer C, Wendtner CM, Hohenberger W, Pustowka A, Wardelmann E, et al. Neoadjuvant treatment of locally advanced GIST: Results of APOLLON, a prospective, open label phase II study in KIT- or PDGFRA-positive tumors. *J Clin Oncol*. 2012;30(15_suppl):10031.
69. Blesius A, Cassier PA, Bertucci F, Fayette J, Ray-Coquard I, Bui B, et al. Neoadjuvant imatinib in patients with locally advanced non metastatic GIST in the prospective BFR14 trial. *BMC Cancer*. 2011;11:72.
70. Eisenberg BL, Harris J, Blanke CD, Demetri GD, Heinrich MC, Watson JC, et al. Phase II trial of neoadjuvant/adjuvant imatinib mesylate (IM) for advanced primary and metastatic/recurrent operable gastrointestinal stromal tumor (GIST): early results of RTOG 0132/ACRIN 6665. *J Surg Oncol*. 2009;99(1):42–7.

Publisher's Note

Springer Nature remains neutral with regard to jurisdictional claims in published maps and institutional affiliations.

Ready to submit your research? Choose BMC and benefit from:

- fast, convenient online submission
- thorough peer review by experienced researchers in your field
- rapid publication on acceptance
- support for research data, including large and complex data types
- gold Open Access which fosters wider collaboration and increased citations
- maximum visibility for your research: over 100M website views per year

At BMC, research is always in progress.

Learn more biomedcentral.com/submissions

