





RESEARCH ARTICLE

Open Access



Multidisciplinary team efforts to improve the pregnancy outcome of pregnancy complicated with primary hyperparathyroidism: case series from a single hospital

Hai-ning Jiao^{1†} , Li-hao Sun^{2†} , Yan Liu¹, Jian-qiao Zhou³, Xi Chen⁴, Jian-min Liu^{2*}  and Hui-ping Zhong^{1*} 

Abstract

Background: There is no consensus or management algorithm for primary hyperparathyroidism (PHPT) in pregnancy.

Methods: This study comprises a retrospective case series. From August 2014 to December 2020, 9 cases of PHPT in pregnancy were diagnosed by a multidisciplinary team (MDT) consultation center of obstetrics in our hospital. Their clinical manifestations, treatment strategies, and maternal and infant outcomes were analyzed.

Results: The median onset age of the patients was 32 (25 ~ 38) years. PHPT was diagnosed in two cases before pregnancy, in six cases during pregnancy and in one case postpartum. The main clinical manifestations were nausea, vomiting, and other nonspecific symptoms, with anemia as the most common maternal complication. Hypercalcemia crisis was developed in one case. The median levels of preoperative serum calcium and parathyroid hormone (PTH) were 3.08 (2.77 ~ 4.21) mmol/L and 300.40 (108.80 ~ 2603.60) pg/ml, respectively. The parathyroid ultrasonography tests were positive in eight cases and negative in one patient who had an ectopic lesion localized by ^{99m}Tc-MIBI. Parathyroidectomy was conducted in 7 cases during the 2nd trimester, including 2 patients diagnosed before pregnancy who refused surgery, 1 patient during the 1st trimester, and 1 patient postpartum, with a significant reduction in serum concentrations of calcium and PTH. A management algorithm was developed.

Conclusion: This case series suggests that pregnant women with PHPT should be managed by MDT according to the algorithm. If PHPT is confirmed in fertile women before pregnancy, parathyroidectomy should be strongly suggested and performed. If PHPT is diagnosed during pregnancy, even in its mild form, surgical treatment, optimally during the 2nd trimester, is effective and safe for pregnancy and neonatal outcome.

Keywords: Multidisciplinary team, Pregnancy, Primary hyperparathyroidism, Prognosis

* Correspondence: ljm10586@rjh.com.cn; zhp10392@rjh.com.cn

†Hai-ning Jiao and Li-hao Sun contributed equally to this work.

²Department of Endocrine and Metabolic Disease, Ruijin Hospital, Shanghai Jiao Tong University School of Medicine, Shanghai, China

¹Department of Obstetrics and Gynecology, Ruijin Hospital, Shanghai Jiao Tong University School of Medicine, 197 Ruijin Er Road, Shanghai 200025, China

Full list of author information is available at the end of the article



© The Author(s). 2021 **Open Access** This article is licensed under a Creative Commons Attribution 4.0 International License, which permits use, sharing, adaptation, distribution and reproduction in any medium or format, as long as you give appropriate credit to the original author(s) and the source, provide a link to the Creative Commons licence, and indicate if changes were made. The images or other third party material in this article are included in the article's Creative Commons licence, unless indicated otherwise in a credit line to the material. If material is not included in the article's Creative Commons licence and your intended use is not permitted by statutory regulation or exceeds the permitted use, you will need to obtain permission directly from the copyright holder. To view a copy of this licence, visit <http://creativecommons.org/licenses/by/4.0/>. The Creative Commons Public Domain Dedication waiver (<http://creativecommons.org/publicdomain/zero/1.0/>) applies to the data made available in this article, unless otherwise stated in a credit line to the data.

Background

Primary hyperparathyroidism (PHPT) is an endocrine disorder characterized by high serum calcium levels, high parathyroid hormone (PTH) levels and low serum phosphorus concentration [1]. PHPT is the most common cause of hypercalcemia during pregnancy. Exposure to higher than normal levels of PTH can cause various hypercalcemia-related clinical manifestations, with an incidence of maternal complications of approximately 67% and that of fetal or neonatal complications of approximately 80%, leading to 30% fetal or neonatal deaths [2]. The clinical manifestations of PHPT during pregnancy are atypical, including nausea, vomiting, constipation, and fatigue, which overlap pregnancy reactions and are overlooked. Currently, the reports of PHPT in pregnancy are usually case reports or small series, and no consensus has been reached on the management of this special disorder [3].

The multidisciplinary team (MDT) is an effective medical model that integrates the advantages of multiple clinical specialists for the comprehensive diagnosis and treatment of diseases [4]. For the management of high-risk pregnancy patients with PHPT, physicians and surgeons from obstetrics, endocrinology, surgery and other disciplines should jointly evaluate the patient's condition and determine the treatment plan. In the past 20 years, our hospital, as a tertiary university teaching hospital, has accumulated some experience in the diagnosis and treatment of PHPT [5–7]. To improve the care of PHPT in pregnancy, this study summarizes the clinical features, diagnosis and treatment experience of this disorder at our MDT center and proposes a diagnosis and treatment algorithm for this disease.

Patients and methods

Patients

We retrospectively reviewed 11 pregnant patients with PHPT between August 2014 and December 2020 at our MDT consultation center of obstetrics. This study was approved by the Ethics Committee of Ruijin Hospital at Shanghai Jiaotong University (KY2020–100). Among these 11 pregnant patients with PHPT, 10 patients conceived naturally, and 1 patient used in vitro fertilization (IVF). To analyze the effect of PHPT during pregnancy, including the effect of surgery during pregnancy on disease prognosis, we excluded two patients who underwent parathyroid surgery after induced labor.

The median onset age was 32 (25 ~ 38) years. There were six cases of primipara and three cases of pluripara (including one case of a scarred uterus). Two patients came to our center for consultation due to a history of missed abortion and were diagnosed with PHPT. Surgical treatment was recommended, but both patients were reluctant to undergo surgery and received follow-up

care. However, both patients had to undergo surgery during their 2nd trimester. One case of PHPT was retrospectively diagnosed by us 5 months postpartum because the baby was born with hypocalcemic convulsions at another hospital. Her serum calcium level was increased during pregnancy, but no particular management was taken. The other six patients were diagnosed with PHPT in their second trimester. The study protocol was approved by the Institutional Review Board of the Rui-jin Hospital in Shanghai.

Methods

MDT: Two rounds of multidisciplinary (obstetrics, endocrinology, surgery, ultrasound, anesthesiology, intensive medicine and others) discussions were conducted. The first discussion was held when the patients visited for the first time (usually during the first trimester or second trimester) to confirm the diagnosis and determine whether they should be treated surgically. The second discussion was initiated during the patient's late pregnancy (38 weeks of pregnancy) to determine the timing and method of delivery. We encouraged patients to have a vaginal delivery. For patients with obstetrical factors, a cesarean section at 39 weeks of gestation pregnancy was recommended. All the decisions were fully communicated with the patients and their family members.

Laboratory tests: For all pregnant women with suspected PHPT, routine blood tests, hepatic and renal function, serum electrolytes, PTH (reference range: 15–68.3 pg/ml; 8 K25 ARCHITECT intact PTH; Abbott Diagnostics) and 25OHD (reference range: 50 nmol/L; Elecsys and Cobas E analyzer; Roche Diagnostics) were measured. If the patient's serum calcium or albumin adjusted calcium level increased with the elevation of serum PTH after excluding secondary hyperparathyroidism due to renal failure or vitamin D deficiency, the diagnosis of PHPT in pregnancy was made.

Serum osteocalcin (OC), β -carboxy-terminal telopeptide of type I collagen (CTX) and procollagen type I N-terminal propeptide (PINP) were measured (OC reference range: 1.8 ~ 8.4 ng/ml, PINP reference range: 15.13 ~ 58.59 ng/ml; CTX reference range: 0.025 ~ 0.573 ng/ml, Cobas 601, Roche Diagnostics).

Imaging tests: All pregnant women underwent neck ultrasound. ^{99m}Tc -MIBI single-photon emission computed tomography (SPECT/CT) was only performed in patients before pregnancy ($n = 1$), in patients with no intention to continue pregnancy ($n = 1$, 2nd trimester) and in patients after labor ($n = 1$).

Follow-up: Follow-up was conducted for postoperative pregnant patients with PHPT, either by face-to-face consultation or phone interview, to monitor conditions including postoperative blood electrolytes, neonatal blood electrolyte levels and complications.

Statistical analysis: Normally distributed data are expressed as the means \pm SD, while nonnormally distributed data are expressed as medians (range). All the data were processed using SAS 9.0 statistical software (SAS Institute Inc). $P < 0.05$ was considered to be statistically significant.

Results

Clinical manifestations and maternal complications

The main symptoms were nausea, vomiting, fatigue, anorexia, and other pregnancy reactions, which were present in 6 of 9 patients (66.67%) in early pregnancy. Anemia was present in four patients (44.44%), with Hb levels ranging from 84 g/L to 103 g/L. One patient (11.11%) developed a hypercalcemia crisis.

Two patients had bilateral knuckle and knee joint pain in early pregnancy; bone pain was also noticed in another patient (case 1) who did not undergo surgery after delivery, with multiple osteoporotic lesions in the ilium, femur and spine as revealed by MRI.

The general characteristics and clinical symptoms of the patients are outlined in Table 1.

Biochemical and imaging tests

The median serum calcium level was 3.08 (2.77 ~ 4.21) mmol/L, with a median serum PTH level of 300.40 (108.80 ~ 2603.60) pg/ml. The median serum 25OHD concentration was 22.27 (13.50 ~ 39.45) nmol/l. For the bone biochemical markers, the serum OC level was 7.60 (3.92 ~ 14.10) ng/ml, the PINP level was 85.43 (65.69 ~ 233.7) ng/ml, and the serum CTX level was 0.53 (0.4 ~ 1.73) ng/ml (Tables 2 and 3).

Neck ultrasonography revealed the presence of low-density lesions in 8 of 9 cases. ^{99m}Tc -MIBI SPECT/CT imaging was conducted in three patients. Low-density foci suggestive of a parathyroid lesion were revealed by MIBI in all cases, including one ectopic lesion anterior superior mediastinal (posterior right of the sternum hilum) in one patient.

All 9 patients underwent kidney, ureteral, ureter, and adrenal ultrasonography, and only 1 patient was found to have a left kidney stone with a diameter of approximately 8 mm.

Treatment of pregnant patients with PHPT

Preoperative management with oral or intravenous administration of large amounts of normal saline was adopted to reduce the serum calcium concentration. Calcitonin and furosemide were not administered to pregnant patients.

Parathyroidectomy was performed uneventfully in all 9 cases with general anesthesia, including 7 patients who underwent surgery during the 2nd trimester (9 ~ 26 weeks), 1 patient who underwent surgery during the 1st trimester and 1 patient who underwent surgery postpartum. The median operation time was 65 mins (50 ~ 80 mins), and the median blood loss was 50 ml (20 ~ 1100 ml). Parathyroid surgery was successful in all cases, and no complications occurred. The median percentage decrease of PTH on the first day after parathyroid surgery was 95.49% (72.95% ~ 99.65%). The serum calcium concentrations in these patients gradually decreased to the lowest levels on the 3rd and 4th days after the operation (Fig. 1). Calcium/vitamin D (Caltrate) supplementation and/or an active vitamin D analog (Calcitriol) was prescribed according to the serum calcium levels.

Postoperative pathology examination showed single parathyroid adenoma in eight cases and parathyroid carcinoma in one case.

Pregnancy outcome and neonatal complications

There was one case of patient-requested labor induction in this series. The remaining eight cases were full-term pregnancies. Among them, three cases were vaginal deliveries, and five cases were terminated by cesarean section due to obstetric indications (scarred uterus, macrosomia, cephalopelvic disproportion, and twin pregnancy).

Table 1 Clinical manifestation and maternal complications of pregnant patients with PHPT

Case	Time of diagnosis	Clinical manifestation	Maternal complication
1	5 months postpartum	No obvious manifestations	Multiple bone destruction and osteoporosis
2	before pregnancy	Bilateral knuckle and knee joint pain	Anemia (99 g/L)
3	2nd trimester	nausea, vomiting, fatigue, anorexia	Anemia (89 g/L)
4	2nd trimester	nausea, vomiting,	Anemia (84 g/L), hypercalcemia crisis with renal failure
5	before pregnancy	nausea, vomiting, fatigue, anorexia	None
6	2nd trimester	nausea, vomiting, fatigue, anorexia	Asymptomatic left kidney stone
7	2nd trimester	nausea, vomiting, fatigue, anorexia	Anemia (103 g/L)
8	2nd trimester	Bilateral knuckle and knee joint pain	None
9	1nd trimester	nausea, vomiting, fatigue, anorexia	None

Table 2 Preoperation biochemical markers of pregnant patients with PHPT

Case	Ca (mmol/L)	P (mmol/L)	ALP (IU/ml)	Cr (μmol/L)	Albumin (g/L)	RBC (× 10 ⁹ /L)	HGB (g/L)
1	2.87	0.64	538	37	39	4.63	144
2	2.95	1.04	59	54	28	2.94	99
3	3.28	0.65	59	56	36	2.89	89
4	4.21	1.39	84	223	31	2.74	84
5	2.77	0.69	54	43	37	3.6	117
6	3.00	0.66	176	47	36	4.32	139
7	3.49	0.59	78	29	33	3.86	103
8	3.17	0.81	85	39	37	3.83	126
9	3.08	0.72	120	42	45	3.76	115

For patients undergoing parathyroidectomy during pregnancy at our hospital, the Apgar scores for all the infants at 1 and 5 min after birth were 10 points, with no distinct abnormality. However, one child was diagnosed with autism at the age of 4 (Table 4).

Discussion

Clinical manifestations and diagnosis of pregnant patients with PHPT

PHPT is characterized by elevated serum PTH concentration and hypercalcemia [8], with varying degrees of severity from asymptomatic to hypercalcemic crisis [9, 10]. Among pregnant patients with PHPT [11], 80% develop nausea, vomiting, and frequent (nocturnal) urination, which overlap with normal physiological reactions during pregnancy and are easily overlooked, complicating or delaying the diagnosis of PHPT [11]. Similar findings were also noticed in our series. The high percentage of anemia detected in our series was due to either PHPT [5] or physiological hemodilution during pregnancy.

The use of the albumin-adjusted serum calcium level [11, 12] is important in patients with low serum albumin

levels, especially in pregnant women who may have a 10% decrease in serum calcium level [11]. However, in our series, all women with PHPT still had an elevated serum calcium level (median: 3.08 mmol/L). In China, although the clinical and biochemical patterns of PHPT are becoming milder, PHPT is still more severe than in Western countries [5, 6], which seems to also be the case for pregnant women with PHPT.

Postoperative pathology showed one case (case 4) of parathyroid carcinoma with a serum calcium level of 4.21 mmol/L and serum PTH level of 2603.6 pg/ml. Parathyroid carcinoma is a rare cause of PHPT, accounting for less than 1% of Western PHPT patients and 6%

Table 3 Preoperation bone biochemical markers of pregnant patients with PHPT

Case	PTH (pg/ml)	25-OH-VitD (nmol/L)	OC (ng/ml)	PINP (ng/ml)	CTX (ng/ml)
1	1524.1	13.50	12.00	233.70	1.73
2	108.8	20.69	6.50	212.60	0.90
3	300.4	39.45	7.60	83.52	0.53
4	2603.6	38.63	7.53	79.20	0.57
5	201.0	25.12	9.20	85.43	0.52
6	494.3	22.27	3.92	65.69	0.40
7	208.9	16.68	4.68	127.20	0.44
8	158.2	35.35	14.10	85.52	0.97
9	305.2	19.82	8.19	73.41	0.29

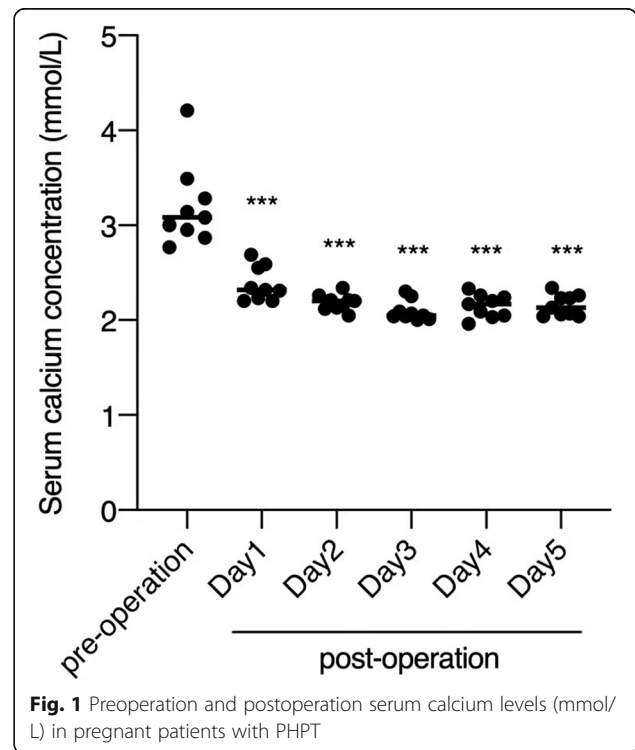


Table 4 Pregnancy outcome and neonatal complications of pregnant patients with PHPT

Case	gestational age at delivery(weeks)	delivery mode	birth weight(g)	neonatal complications
1	39 ⁺¹	vaginal delivery	2800	The baby was born with hypocalcemic convulsions
2	39	cesarean section	3455	The child was diagnosed with autism at the age of 4
3	39 ⁺²	cesarean section	3075	normal
4	14	labor induction	/	/
5	38 ⁺²	vaginal delivery	2910	normal
6	39 ⁺⁵	vaginal delivery	3310	normal
7	39	cesarean section	3620	normal
8	39 ⁺²	cesarean section	3690	normal
9	39 ⁺¹	cesarean section	3110	normal

of Chinese patients [5]. However, in this series, parathyroid carcinoma accounted for 11.1% (1/9), and we are not sure whether such a high rate in pregnant women has any physiological and pathophysiological relationship with pregnancy. The clinical manifestations of parathyroid carcinoma are mainly moderate to severe hypercalcemia and symptoms of renal and skeletal involvement. Whether malignant tumors are considered at the time of initial diagnosis is critical for the patient's prognosis. Serum calcium and serum PTH levels in patients with parathyroid carcinoma are significantly higher than those in parathyroid adenoma. When serum calcium exceeds 12 mg/dL (3 mmol/L), serum PTH levels exceed the normal upper limit by 3–10 times, and awareness of the possibility of parathyroid carcinoma is necessary [13]. The clinical symptoms of parathyroid carcinoma are usually more severe than those of parathyroid adenoma and often involve the kidneys and bones. If the patient has severe renal and skeletal complications, the possibility of malignancy should be considered.

The method for determining the location of parathyroid lesions in pregnancy with PHPT differs from that of ordinary PHPT; the commonly applied ^{99m}Tc-MIBI and neck CT examinations are limited during pregnancy. The sensitivities of ^{99m}Tc-MIBI and color Doppler neck ultrasonography to localize parathyroid lesion(s) are 94.1 and 85.1%, respectively; if they are combined, the sensitivity will increase to 98.9% [14].

The use of ^{99m}Tc-MIBI in pregnant women remains controversial [15]. A case report [16] suggested that pregnancy is not a contraindication to ^{99m}Tc-MIBI examination due to the short half-life of the radioisotope, ensuring the safety of ^{99m}Tc-MIBI examination, especially when ultrasound cannot accurately localize the lesion during pregnancy [17]. However, in another case series, the authors suggested avoiding the use of radioactive imaging modalities [15]. In our series, ^{99m}Tc-MIBI was only employed in patients before conception or with no intention to continue pregnancy or in patients after labor, with 100% positive findings. An

ectopic lesion was fortunately and coincidentally revealed by MIBI in one case (case 1), which was not identified by ultrasound. However, due to the lack of solid clinical data, the use of ^{99m}Tc-MIBI in pregnant women with the intention to continue pregnancy should be cautious.

According to our results, neck ultrasonography can localize all the parathyroid lesions in the neck in 8 cases, except an ectopic lesion. The accuracy of the ultrasound positioning was further confirmed during surgery. From our experience and other similar case reports [18], neck ultrasonography for pregnant patients with PHPT is recommended as the first choice of treatment and is effective for preoperative positioning and surgical guidance.

Treatment of pregnant patients with PHPT

For pregnant patients with PHPT with asymptomatic, mildly elevated, serum calcium levels or patients who do not accept surgery, close observation without surgical intervention is feasible [19, 20]. The first-line medication is oral or intravenous rehydration with or without furosemide, which is safe, can avoid iatrogenic placental hypoperfusion or oligohydramnios caused by dehydration [21] and will not increase the risk of obstetric complications, such as abortion. However, there is still a need to closely monitor the serum calcium level and disease progression.

PHPT is usually caused by a single parathyroid tumor, and the most effective treatment is surgery [22]. For pregnant women, surgery should be implemented in the second trimester (13 ~ 26 weeks of gestation) because the fetal organs have completely developed and the spontaneous abortion rate is the lowest at this point [23], effectively reducing the risk of maternal and fetal complications. A study of 77 pregnant women revealed that even if serum calcium is maintained at a median level of approximately 2.67 mmol/L, a 12% risk of fetal death still exists [24]; if the serum calcium level is sustained at 2.70 ~ 2.75 mmol/L, the risk of fetal death will increase [25]. It is suggested that PHPT patients with a history of miscarriage and a serum calcium level

exceeding 2.75 mmol/L, even without distinct elevation or symptoms, should undergo surgery and should not wait until postpartum to avoid neonatal hypocalcemia and convulsion [26].

From our experience and that of others [15], parathyroidectomy conducted in the 2nd trimester, especially when guided by experienced MDT, is safe and effective. However, for patients with serious hypercalcemia, such as hypercalcemia crisis (case 4) or an uncontrollable elevated serum calcium level (case 9), timely surgery is still needed [27], even in the 1st trimester (case 9) in our series.

In nonpregnant PHPT patients, the parathyroid lesion could be confirmed to be removed if the serum PTH level was decreased more than 50 and 60% at 5 min and 15 min, respectively, after lesion resection. Intraoperative PTH was measured in our series in two cases (case 8 and case 9), showing a 65.53% ~ 78.19% decrease 10 min after parathyroidectomy.

Surgical therapy is also the most frequent option for the treatment of parathyroid carcinoma. Primary operation is crucial for adequate local excision. The tumor was removed in one block with ipsilateral thyroid gland lobectomy. During the operation, the surgeon should avoid rupture of the capsule. It would be preferable to perform an ipsilateral thyroid gland lobectomy with parathyroid tissue and neck block dissection [28].

It should be stressed that PHPT can be diagnosed biochemically, not necessarily to be confirmed by localization imaging results [29]. For cases with inconsistent or negative imaging findings, if surgery is indicated, the patient should still undergo surgery. For patients with positive preoperative localization, focused parathyroidectomy could be performed, while for patients with negative imaging results, bilateral cervical exploration (BCE) could be performed, which has a cure rate in excess of 95% for experienced surgeons [30, 31].

Notably, there was a case of PHPT in our patient (case 2) diagnosed 4 years before pregnancy at our hospital. Surgery was recommended, although her serum calcium level was at the normal upper limit. However, the patient refused the operation. During pregnancy, her serum calcium level increased to 2.95 mmol/L, and she had to undergo surgery at 23⁺⁵ weeks of gestation, with a normal delivery at full term. However, her child was diagnosed with autism at the age of 4. Because the child's father had premature Parkinson's disease, we are not sure whether a relationship exists between this child's autism and his parents' diseases. However, based on our experience with this case, we believe that whenever a diagnosis of PHPT is made for women of reproductive age, surgery should be strongly suggested to the patients.

Other methods are available to manage parathyroid lesions in pregnant women. Alcohol ablation could be

considered in the case of ineffective drug therapy or when a pregnant woman cannot tolerate surgery [32, 33]. This method was not attempted in our series.

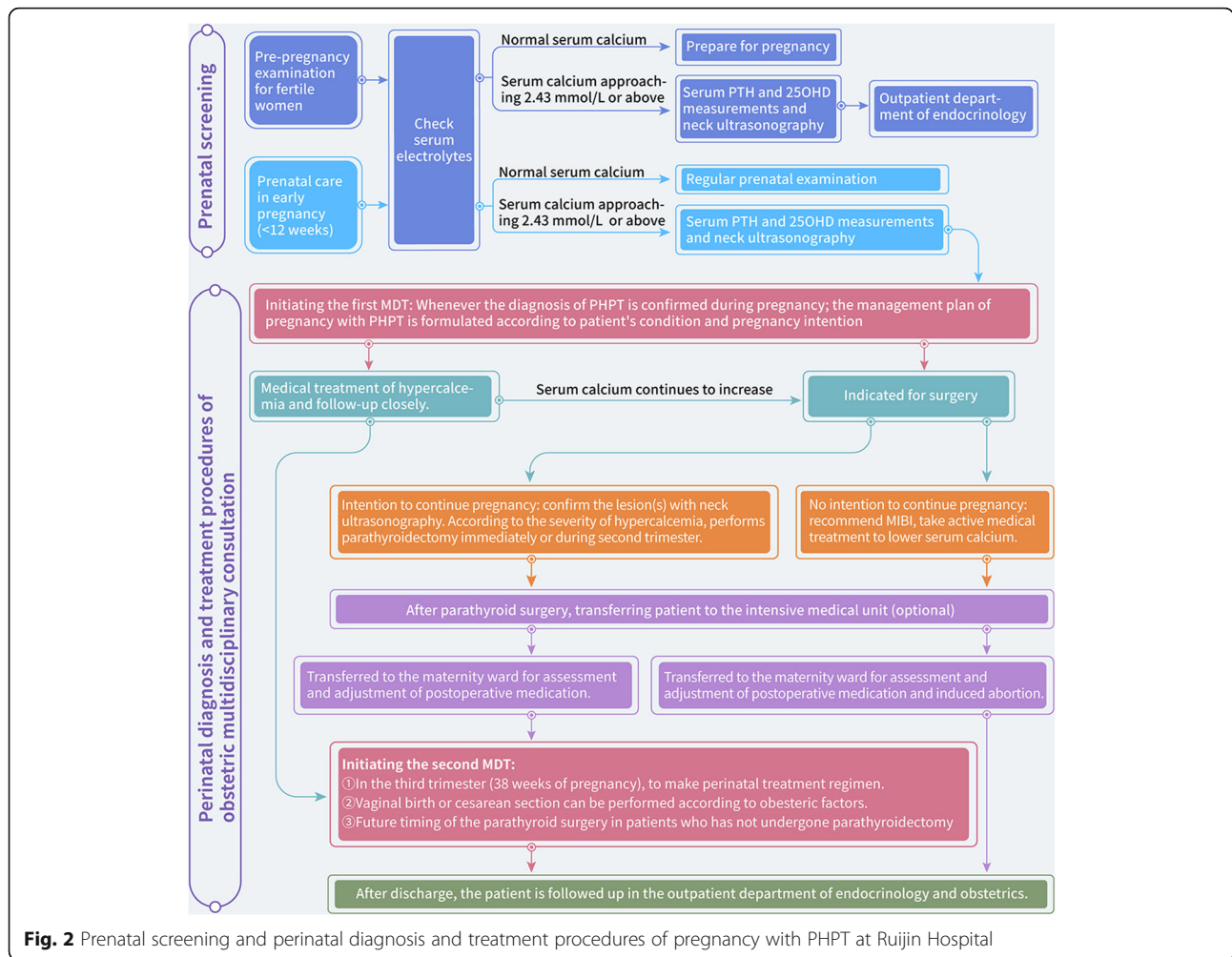
Timing and method of pregnancy termination of patients with PHPT during pregnancy

Presently, no consensus exists on the timing and delivery method of pregnancy termination in patients with PHPT. Vaginal delivery can be performed under close supervision, but obstetric factors should be considered first. After the diagnosis of pregnancy with PHPT, we fully communicated with the patients and their families during the 2nd trimester and reached a consensus on pregnancy intention (labor induction or continued pregnancy), parathyroid surgery treatment and surgery timing. One patient was fertile and had concerns about the safety of the fetus after parathyroid surgery and requested the termination of pregnancy. There were eight cases of full-term pregnancy, among which three cases were delivered naturally under close monitoring and four cases were terminated by cesarean section under lumbar anesthesia at approximately 39 weeks of gestation due to obstetric factors.

Screening and perinatal production inspection patterns for pregnant patients with PHPT

Pregnancy with PHPT can cause severe maternal and infant complications, especially the development of hypercalcemia crisis, which can lead to perinatal maternal death. With our previous experience in PHPT diagnosis and treatment [5–7], we suggest that serum electrolytes should be checked during prepregnancy examination for fertile women. If the serum calcium level is higher than 2.43 mmol/L [5], serum PTH testing and other tests should be performed for PHPT screening. If any abnormality occurs, an endocrinologist should be consulted as soon as possible.

We have developed an obstetrical screening program for pregnant women. In early pregnancy (< 12 weeks), the serum electrolyte levels are checked at the hospital during the initial diagnosis. If abnormalities in serum calcium occur, serum PTH testing and other tests are performed for PHPT screening. For suspected cases, MDT consultation is made in time to develop a treatment plan. For patients with PHPT during pregnancy, postoperative monitoring of parathyroid function should be strengthened. In addition to routine parameters, serum calcium and PTH concentrations should be checked every 2 weeks, and postoperative medication should be adjusted to avoid hypocalcemia. The obstetric MDT process for patients with PHPT is illustrated in Fig. 2.



Limitations

There are several limitations in this study. Due to the rareness of PHPT in pregnancy, the sample size in this study was small. Some follow-up data regarding patients' and their children's serum calcium levels were obtained through phone interviews. Intraoperative PTH was not routinely measured in any of our patients. PTH monitoring during surgery is helpful to determine the success of the operation, especially for cases with negative pre-operative localization [34] or multiple adenomas [35]. We did not routinely test for the MEN-1 gene, as in other reports [12, 34]. The test was performed in only one case with a family history in our series, and the result was negative.

Conclusions

Clinical manifestations of PHPT in pregnancy are atypical and prone to be overlooked. It is recommended to focus on serum electrolyte levels during the first trimester, especially in pregnant women with significant nausea and vomiting. If the serum calcium level is increased,

the serum PTH level should be checked to confirm the diagnosis of PHPT, and then an MDT should be organized to make follow-up and treatment plans. If PHPT is diagnosed before pregnancy in women of fertile age, even if it is a mild or asymptomatic case and the patient is reluctant, parathyroidectomy should be strongly recommended. If PHPT is diagnosed during pregnancy, considering the general accuracy of neck ultrasonography examination, timely parathyroidectomy, optimally in the second trimester of pregnancy or even in the first trimester, is effective and safe.

Abbreviations

PHPT: primary hyperparathyroidism; PTH: parathyroid hormone; MDT: multidisciplinary team; IVF: in vitro fertilization; OC: serum osteocalcin; CTX: β-carboxy-terminal telopeptide of type I collagen; PINP: procollagen type I N-terminal propeptide; SPECT/CT: 99mTc-MIBI single-photon emission computed tomography; MRI: magnetic resonance imaging

Acknowledgements

The authors thank the Rui-jin Hospital, Shanghai Jiao Tong University School of Medicine for their assistance with this research.

Authors' contributions

HNJ, LHS, HPZ contributed to the planning, conduction and report of the work. HNJ, JML, HPZ contributed to the conception and design of the work. HNJ, YLJQZ, XC contributed to the acquisition of analysis and interpretation of the results. All authors have read and approved the manuscript.

Funding

This study has been supported by research grants awarded by the National Key Research and Development Program of China (No. 2016YFC0901500; 2016YFC0901503) to establish the cohort and follow up.

Availability of data and materials

The research data used to support the findings of this study were supplied by Prof.Zhong under license and so cannot be made freely available. Requests for access to these data should be made to Prof.Zhong (Email:zhp10392@rjh.com.cn).

Declarations**Ethics approval and consent to participate**

This article does not contain any studies with human participants or animals performed by any of the authors. This study was approved by ethic committee of Ruijin Hospital, Shanghai Jiaotong University. Due to the retrospective nature of the study, informed consent was waived (KY2020–100).

Consent for publication

Written informed consent for publication was obtained from all participants.

Competing interests

The authors declare that they have no competing interest.

Author details

¹Department of Obstetrics and Gynecology, Ruijin Hospital, Shanghai Jiao Tong University School of Medicine, 197 Ruijin Er Road, Shanghai 200025, China. ²Department of Endocrine and Metabolic Disease, Ruijin Hospital, Shanghai Jiao Tong University School of Medicine, Shanghai, China. ³Department of Ultrasonography, Ruijin Hospital, Shanghai Jiao Tong University School of Medicine, Shanghai, China. ⁴Department of Surgery, Ruijin Hospital, Shanghai Jiao Tong University School of Medicine, Shanghai, China.

Received: 26 December 2020 Accepted: 10 August 2021

Published online: 22 August 2021

References

- Godinez-Vidal AR, Oca-Duran EM, Aguirre-Rojano VI, Pulido-Cejudo A, Paul-Basurto-Kuba EO, Hurtado-Lopez LM. Hyperparathyroidism during pregnancy. Is it a diagnostic and therapeutic challenge? *Cir Cir*. 2019;87(51):62–7. <https://doi.org/10.24875/CIRU.19000796>.
- Hirsch D, Kopel V, Nadler V, Levy S, Toledano Y, Tsvetov G. Pregnancy outcomes in women with primary hyperparathyroidism. *J Clin Endocrinol Metab*. 2015;100(5):2115–22. <https://doi.org/10.1210/jc.2015-1110>.
- Zhu M, Lihao S, Yulin Z, Yan L, Wei Z, Bei T, et al. Hypercalcemia in pregnancy: one case report. *Chin J Endocrinol Metab*. 2016;032(005):415–7.
- Merien AE, van de Ven J, Mol BW, Houterman S, Oei SG. Multidisciplinary team training in a simulation setting for acute obstetric emergencies: a systematic review. *Obstet Gynecol*. 2010;115(5):1021–31. <https://doi.org/10.1097/AOG.0b013e3181d9f4cd>.
- Zhao L, Liu JM, He XY, Zhao HY, Sun LH, Tao B, et al. The changing clinical patterns of primary hyperparathyroidism in Chinese patients: data from 2000 to 2010 in a single clinical center. *J Clin Endocrinol Metab*. 2013;98(2):721–8. <https://doi.org/10.1210/jc.2012-2914>.
- Liu JM, Cusano NE, Silva BC, Zhao L, He XY, Tao B, et al. Primary hyperparathyroidism: a tale of two cities revisited - New York and Shanghai. *Bone Res*. 2013;1(2):162–9. <https://doi.org/10.4248/BR201302005>.
- Zhao L, Zhang MJ, Zhao HY, Sun LH, Li JL, Tao B, et al. PTH inhibition rate is useful in the detection of early-stage primary hyperparathyroidism. *Clin Biochem*. 2011;44(10–11):844–8. <https://doi.org/10.1016/j.clinbiochem.2011.03.142>.
- Khan AA, Hanley DA, Rizzoli R, Bollerslev J, Young JE, Rejnmark L, et al. Primary hyperparathyroidism: review and recommendations on evaluation, diagnosis, and management. A Canadian and international consensus. *Osteoporos Int*. 2017;28(1):1–19. <https://doi.org/10.1007/s00198-016-3716-2>.
- Tay YD, Liu M, Bandeira L, Bucovsky M, Lee JA, Silverberg SJ, et al. Occult urolithiasis in asymptomatic primary hyperparathyroidism. *Endocr Res*. 2018;43(2):106–15. <https://doi.org/10.1080/07435800.2018.1431275>.
- Schini M, Jacques RM, Oakes E, Peel NFA, Walsh JS, Eastell R. Normocalcemic Hyperparathyroidism: Study of its Prevalence and Natural History. *J Clin Endocrinol Metab*. 2020;105(4):e1171–e1186. <https://doi.org/10.1210/clinem/dgaa084>.
- Kovacs CS. Maternal mineral and bone metabolism during pregnancy, lactation, and post-weaning recovery. *Physiol Rev*. 2016;96(2):449–547. <https://doi.org/10.1152/physrev.00027.2015>.
- Song A, Wang W, Chen S, Wang Y, Liu S, Nie M, et al. Primary hyperparathyroidism during pregnancy: a case series of eight patients. *Endocr Pract*. 2019;25(11):1127–36. <https://doi.org/10.4158/EP-2019-0035>.
- Goswamy J, Lei M, Simo R. Parathyroid carcinoma. *Curr Opin Otolaryngol Head Neck Surg*. 2016;24(2):155–62. <https://doi.org/10.1097/MOO.0000000000000234>.
- Ning ZW, Wang O, Xu JY, Zhang JX, Li F, Xing XP, et al. Guan H et al: [assessment of preoperative localization techniques for patients with primary hyperparathyroidism]. *Zhongguo Yi Xue Ke Xue Yuan Xue Bao*. 2003;25(3):280–4.
- DiMarco AN, Meeran K, Christakis I, Sodhi V, Nelson-Piercy C, Tolley NS, et al. Seventeen cases of primary hyperparathyroidism in pregnancy: a call for management guidelines. *J Endocr Soc*. 2019;3(5):1009–21. <https://doi.org/10.1210/je.2018-00340>.
- Saad AF, Pacheco LD, Costantine MM. Management of ectopic parathyroid adenoma in pregnancy. *Obstet Gynecol*. 2014;124(2 Pt 2 Suppl 1):478–80.
- Malheiro E, Chabbert-Buffet N, Talbot JN, Perie S. Hyperparathyroidism in pregnancy and (99m)Tc-MIBI scintigraphy. *Eur Ann Otorhinolaryngol Head Neck Dis*. 2019;136(6):501–3. <https://doi.org/10.1016/j.fanorl.2019.05.009>.
- Yanru N, Tianzhong M, Limei W, Bo W. Correlation analysis between bone metabolic markers and bone mineral density in the primary osteoporosis. *J Taishan Med Coll*. 2017;38(8):848–59.
- Gehlert J, Morton A. Hypercalcaemia during pregnancy: review of maternal and fetal complications, investigations, and management. *Obstet Med*. 2019;12(4):175–9. <https://doi.org/10.1177/1753495X18799569>.
- Diaz-Soto G, Linglart A, Senat MV, Kamenicky P, Chanson P. Primary hyperparathyroidism in pregnancy. *Endocrine*. 2013;44(3):591–7. <https://doi.org/10.1007/s12020-013-9980-4>.
- Rigg J, Gilbertson E, Barrett HL, Britten FL, Lust K. Primary hyperparathyroidism in pregnancy: maternofetal outcomes at a quaternary referral obstetric hospital, 2000 through 2015. *J Clin Endocrinol Metab*. 2019;104(3):721–9. <https://doi.org/10.1210/jc.2018-01104>.
- Arnez L, Lawrence V. Complex management decisions in a woman with concurrent primary hyperparathyroidism and metastatic papillary thyroid carcinoma, both presenting during pregnancy. *Endocrinol Diabetes Metab Case Rep*. 2019;2019:19–0110. <https://doi.org/10.1530/EDM-19-0110>.
- Hession P, Walsh J, Gaffney G. Two cases of primary hyperparathyroidism in pregnancy. *BMJ Case Rep*. 2014;2014:bcr2013202883. <https://doi.org/10.1136/bcr-2013-202883>.
- Kokrdova Z. Pregnancy and primary hyperparathyroidism. *J Obstet Gynaecol*. 2010;30(1):57–9. <https://doi.org/10.3109/01443610903315611>.
- McMullen TP, Learoyd DL, Williams DC, Sywak MS, Sidhu SB, Delbridge LW. Hyperparathyroidism in pregnancy: options for localization and surgical therapy. *World J Surg*. 2010;34(8):1811–6. <https://doi.org/10.1007/s00268-010-0569-2>.
- Bendinelli C, Nebauer S, Quach T, McGrath S, Acharya S. Is minimally invasive parathyroid surgery an option for patients with gestational primary hyperparathyroidism? *BMC Pregnancy Childbirth*. 2013;13(1):130. <https://doi.org/10.1186/1471-2393-13-130>.
- Sharma SG, Levine SN, Yatavelli RK, Shaha MA, Nathan CAO. Parathyroidectomy in First Trimester of Pregnancy. *J Endocr Soc*. 2020;4(3):bvaa015.
- Libánský P, Adámek S, Broulík P, Fialová M, Kubinyi J, Lischke R, Naňka O, Pafko P, Šedý J, Bobek V: Parathyroid Carcinoma in Patients that Have Undergone Surgery for Primary Hyperparathyroidism. In vivo (Athens, Greece). 2017;31(5):925–30. <https://doi.org/10.21873/in vivo.11148>.

29. W KJ, Robert U. Rational use of localization studies in the management of primary hyperparathyroidism. *Chin J Endocrinol Metab.* 2016;32(8):637–8.
30. Udelsman R, Lin Z, Donovan P. The superiority of minimally invasive parathyroidectomy based on 1650 consecutive patients with primary hyperparathyroidism. *Ann Surg.* 2011;253(3):585–91. <https://doi.org/10.1097/SLA.0b013e318208fed9>.
31. Laird AM, Libutti SK. Minimally invasive parathyroidectomy versus bilateral neck exploration for primary hyperparathyroidism. *Surg Oncol Clin N Am.* 2016;25(1):103–18. <https://doi.org/10.1016/j.soc.2015.08.012>.
32. Bansal S, Kaushik RM, Kaushik R, Modi S, Raghuvanshi S, Kusum A. Primary hyperparathyroidism presenting as severe hypercalcemia with acute pancreatitis in pregnancy. *Gynecol Endocrinol.* 2020;36(5):469–72. <https://doi.org/10.1080/09513590.2019.1698028>.
33. Ye J, Huang W, Huang G, Qiu Y, Peng W, Lan N, et al. Efficacy and safety of US-guided thermal ablation for primary hyperparathyroidism: a systematic review and meta-analysis. *Int J Hyperth.* 2020;37(1):245–53. <https://doi.org/10.1080/02656736.2020.1734673>.
34. McCarthy A, Howarth S, Khoo S, Hale J, Oddy S, Halsall D, et al. Management of primary hyperparathyroidism in pregnancy: a case series. *Endocrinol Diabetes Metab Case Rep.* 2019;2019:19–0039. <https://doi.org/10.1530/EDM-19-0039>.
35. Zhang Y, Ding JW, Yu LY, Luo DC, Sun JL, Lei ZK, et al. Twin pregnancy with triple parathyroid adenoma: a case report and review of literature. *World J Clin Cases.* 2018;6(11):466–71. <https://doi.org/10.12998/wjcc.v6.i11.466>.

Publisher's Note

Springer Nature remains neutral with regard to jurisdictional claims in published maps and institutional affiliations.

Ready to submit your research? Choose BMC and benefit from:

- fast, convenient online submission
- thorough peer review by experienced researchers in your field
- rapid publication on acceptance
- support for research data, including large and complex data types
- gold Open Access which fosters wider collaboration and increased citations
- maximum visibility for your research: over 100M website views per year

At BMC, research is always in progress.

Learn more biomedcentral.com/submissions

