


CASE REPORT

Open Access

# A rare case of persistent air leak: beware of all the tubes



Amarja Ashok Havalдар<sup>\*</sup> , Abdul Rahim Fazal and Abhilash Chennabasappa

## Abstract

**Background:** Patients with acute respiratory failure, impaired consciousness, and impaired airway reflexes will require invasive mechanical ventilation. Monitoring of such patients is important. The use of ventilator scalars and loops help in monitoring, diagnosing the abnormality, and treating the patients effectively. We report a rare cause one should suspect in a case of persistent and fixed air leak in a patient requiring mechanical ventilation.

**Case presentation:** We describe a 28-year-old young patient requiring ventilator support due to neuromuscular weakness. His neuromuscular weakness was rapidly progressing involving the respiratory muscles. The patient was intubated and put on mechanical ventilator support. He was transferred from another health care center to our hospital. On evaluation, the patient was intubated with ETT no 8. The patient had persistent air leak as observed on the ventilator graphics. We checked for ETT cuff malfunction, ventilator circuit, catheter mount, and HME for any disconnection causing the leak. The air leak which we observed in our patient was due to the malpositioned Ryle's tube.

**Conclusions:** Vigilant monitoring of patients requiring mechanical ventilation is necessary. For the evaluation of the cause of air leak, algorithmic approach will help in correctly identifying the abnormality.

**Keywords:** Air leak, Mechanical Ventilation, Neuromuscular weakness, Respiratory failure

## Background

Monitoring of patients requiring mechanical ventilation is important. The use of Ventilator scalars and loops help in monitoring, diagnosing the abnormality, and treating the patients effectively. The use of Scalars helps in identifying abnormalities of resistance and compliance, presence of secretions, autopeep, and air leak. Similar changes will be observed in loops depending on the abnormality.

Presence of air leak is one of the common abnormalities one can come across. Possible causes of air leak could be ETT (Endotracheal tube) cuff leak, ventilator circuit traps which are loose, or ETT, which is of small size than the glottis. These abnormalities can be easily identified and can be corrected.

We report a rare case of persistent air leak in a 28-year-old patient (IEC ref no 006/2020).

## Case presentation

A 28-year-old young male presented with the history of weakness in both lower limbs after viral illness. Neurological assessment showed weakness of both lower limbs which gradually progressed to involve the upper limbs. The possibility of ascending flaccid paralysis was considered. He received 3 cycles of plasmapheresis. Subsequently, the patient developed breathing difficulty and required ventilator support. He was transferred to our hospital. On evaluation, the patient had ET tube and Ryle's tube and was connected to ventilator support.

\* Correspondence: [amarjahavalдар@rediffmail.com](mailto:amarjahavalдар@rediffmail.com)

Department of Critical Care, St. John's Medical College, Bangalore 560034, India



© The Author(s). 2021 **Open Access** This article is licensed under a Creative Commons Attribution 4.0 International License, which permits use, sharing, adaptation, distribution and reproduction in any medium or format, as long as you give appropriate credit to the original author(s) and the source, provide a link to the Creative Commons licence, and indicate if changes were made. The images or other third party material in this article are included in the article's Creative Commons licence, unless indicated otherwise in a credit line to the material. If material is not included in the article's Creative Commons licence and your intended use is not permitted by statutory regulation or exceeds the permitted use, you will need to obtain permission directly from the copyright holder. To view a copy of this licence, visit <http://creativecommons.org/licenses/by/4.0/>. The Creative Commons Public Domain Dedication waiver (<http://creativecommons.org/publicdomain/zero/1.0/>) applies to the data made available in this article, unless otherwise stated in a credit line to the data.

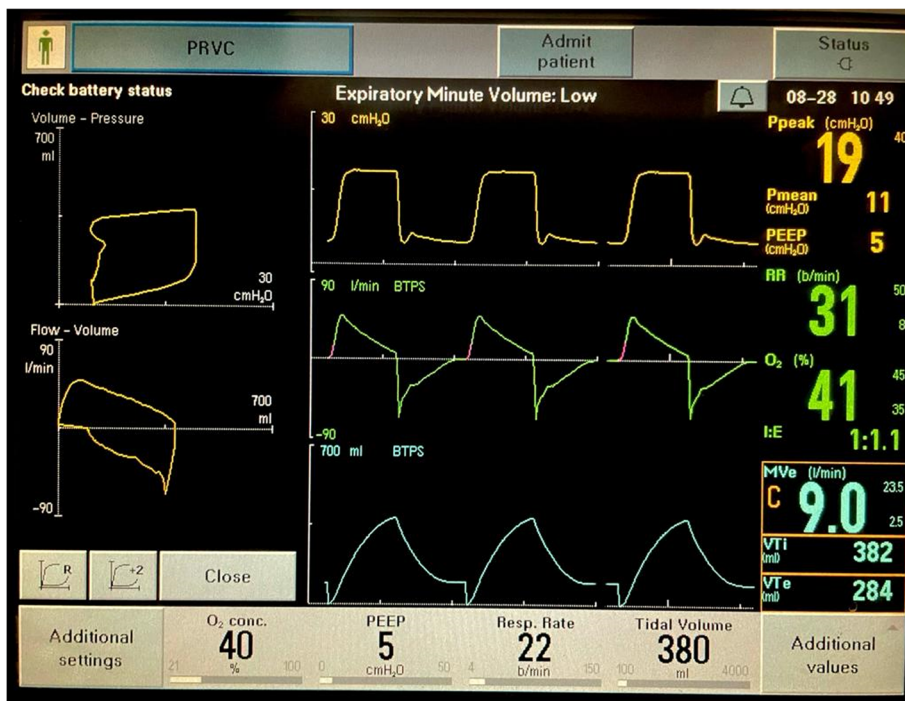

Fig. 1 PRVC mode with air leak

Ventilator settings were as follows: PRVC mode Fio2 40%, RR 22, and TV 380 ml. On the ventilator graphics, air leak was noted (Fig. 1). ET tube position and cuff was checked. It was observed that the ET tube, no. 8, was fixed at around 18 cm. The clinical decision of check laryngoscopy after sedation and paralysis was made. On laryngoscopy, the ET tube cuff was above the glottis, and after deflation of cuff, it was difficult to advance the tube. So, the tube was changed to 8.5 no ETT and fixed at 22 cm H<sub>2</sub>O. Tube position was confirmed by auscultation and subsequently by ETCO<sub>2</sub>.

After the change of ET tube, the leak persisted. So, the ventilator circuit and water traps were checked for any air leak. There was no subcutaneous emphysema, and lung ultrasound showed good lung sliding. So, we planned on doing CXR.

CXR showed that Ryle’s tube is malpositioned (Fig. 2). It was entering into the right main bronchus. Ryle’s tube’s distal end was open, and that was causing persistent leak. So, we planned to remove Ryle’s tube. After Ryle’s tube removal, the leak disappeared (Figs. 3 and 4).

**Discussion**

This case represents various important lessons. First, one should follow algorithmic approach when evaluating for the cause of air leak (Fig. 5). The assessment should begin either from the patient end or ventilator end, so that all possible causes can be easily identified. From the

patient end, when we assess, we look for the endotracheal or tracheostomy cuff for cuff leak. Cuff pressure can be checked with Lange’s pressure monitor. It can become a part of routine monitoring of patients. The catheter mount which has a flip valve can be the commonest site for air leak. The HME (heat moisture exchanger) filter which has a CO<sub>2</sub> sampling port, if open, can cause air leak. Then, check the ventilator circuit and water traps. The attachment of ventilator circuit to the ventilator can be loose and may get disconnected. With the help of imaging such as CXR, ultrasound, or CT scan,

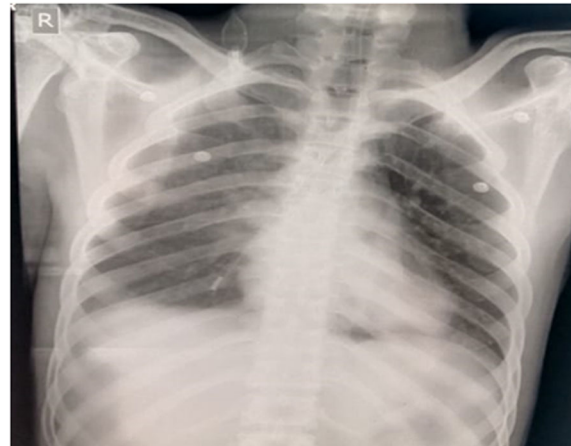
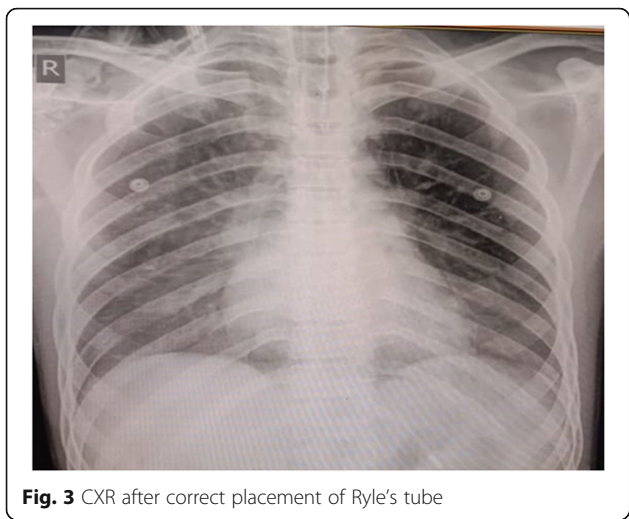


Fig. 2 CXR showing malpositioned Ryle’s tube



**Fig. 3** CXR after correct placement of Ryle's tube

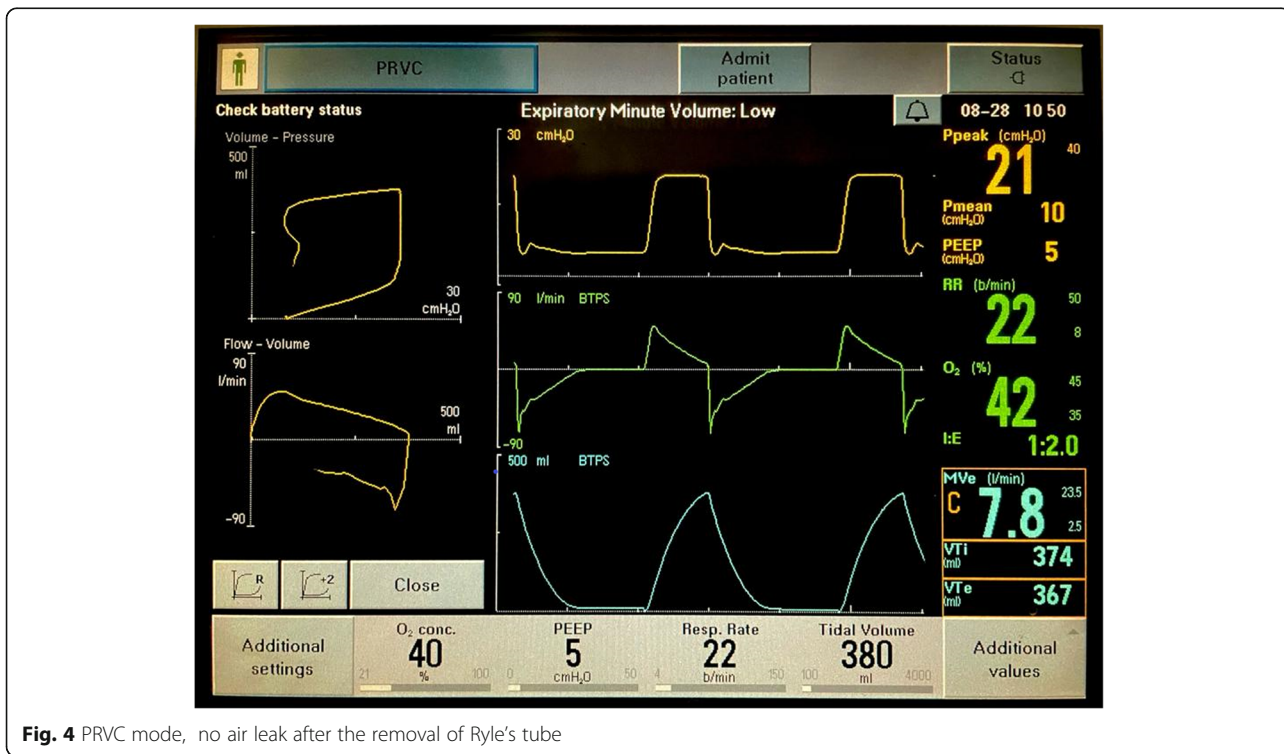
one can identify the anatomical and parenchymal lung diseases causing air leak. If the patient has ICD (intercostal drain), if it is not positioned properly, one of the ports can be in the subcutaneous plane and can lead to air leak. In the patient of chest trauma, the presence of open chest wound can lead to inadequate minute ventilation due to air leak.

Regarding this particular case, malpositioning of Ryle's tube was the cause of air leak. It is not a routine practice across all the hospitals to confirm Ryle's

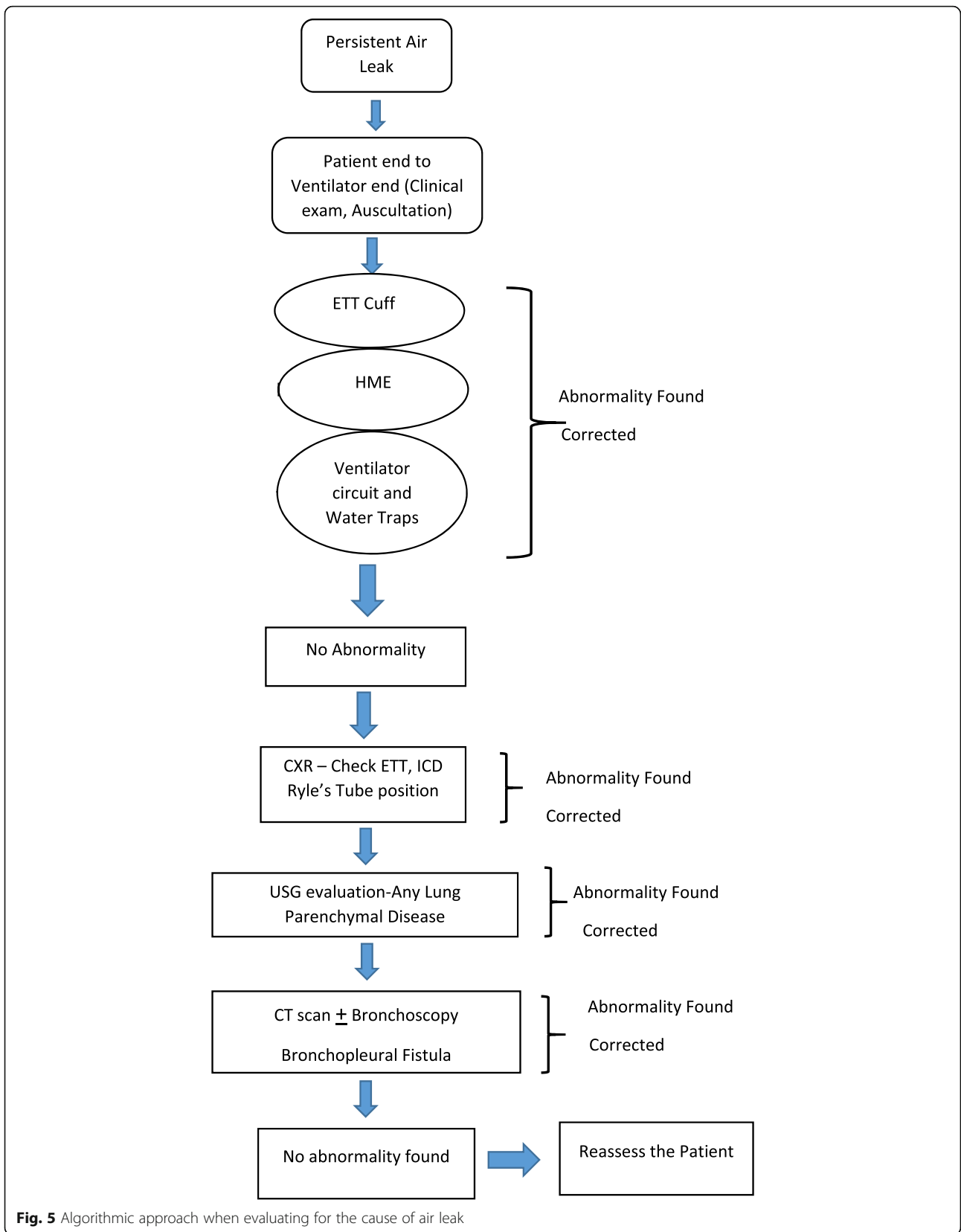
tube position by CXR. The confirmation by auscultation with insufflation of air method is not specific to confirm the placement of tube as the test may be false positive, and also, it may not ensure the correct positioning of Ryle's tube [1].

In the evaluation of air leak in patients requiring mechanical ventilation as shown by Gonzalez et al., air leak can cause persistent hypercapnia, and one can take practical measures to reduce the volume of air leak [2]. McInnis et al. described, a rare case of air leak due to esophageal malignancy invading the left main bronchus [3]. Lazarus et al. described the bronchoscopic management for persistent air leak [4]. There are various causes for persistent air leak in post thoracic surgery patients. Cerfolio's classification is used for the grading of air leaks. Dugan et al. explained various methods used in the management of such patients [5].

Identification of correct etiology is important, in order to decide about the further plan of management. In our case, it was a malpositioned Ryle's tube which led to air leak. Doing CXR for confirmation of tubes and catheters is required. Especially, in case of Ryle's tube, as auscultation is not enough to confirm the position, CXR is considered as an optimum and feasible method [1]. The article by Fan et al. describes various methods for the confirmation of Ryle's tube position and advantages and disadvantages of each [1].



**Fig. 4** PRVC mode, no air leak after the removal of Ryle's tube



**Fig. 5** Algorithmic approach when evaluating for the cause of air leak

## Conclusion

The cause of air leak in a patient described above was due to malpositioned Ryle's tube. The physician should follow an algorithmic approach to identify the etiology correctly and manage accordingly. This case report also highlights the limitations of routine auscultation method used for confirming Ryle's tube position.

## Acknowledgements

The authors would like to thank the MICU staff who helped in the data collection.

## Authors' contributions

AH has helped in collecting the data and writing the manuscript and approved the final draft. AF has helped in the data collection. AC has helped in the data collection. The author(s) read and approved the final manuscript.

## Author's information

AH is working as an associate professor in the Department of Critical Care Medicine.

AF and AC were working as senior residents in the department when study was done.

## Funding

Not applicable

## Availability of data and materials

Available upon reasonable request

## Declarations

### Ethics approval and consent to participate

Formal consent was obtained from a legally acceptable representative (LAR), provisionally approved by the Institutional Ethics Committee.

### Consent for publication

Written informed consent was obtained from the LAR for publication of this case report and any accompanying images. A copy of the written consent is available for review by the Editor-in-Chief of this journal.

### Competing interests

The authors declare that they have no competing interests.

Received: 1 March 2021 Accepted: 3 September 2021

Published online: 22 September 2021

## References

1. Fan EM, Tan SB, Ang SY. Nasogastric tube placement confirmation: where we are and where we should be heading. *Proc Singapore Healthcare*. 2017; 26(3):189–95. <https://doi.org/10.1177/2010105817705141>.
2. Gonzalez J, Sharshar T, Hart N, Chadda K, Raphaël JC, Lofaso F. Air leaks during mechanical ventilation as a cause of persistent hypercapnia in neuromuscular disorders. *Intensive Care Med*. 2003;29(4):596–602. <https://doi.org/10.1007/s00134-003-1659-5>.
3. McInnis I, Walter R. 1165: an unusual case of air leak in a mechanically ventilated patient. *Crit Care Med*. 2019;47(1):559. <https://doi.org/10.1097/01.ccm.0000551910.05745.5e>.
4. Lazarus DR, Casal RF. Persistent air leaks: a review with an emphasis on bronchoscopic management. *J Thoracic Dis*. 2017;9(11):4660–70. <https://doi.org/10.21037/jtd.2017.10.122>.
5. Dugan KC, Laxmanan B, Murgu S, Hogarth DK. Management of persistent air leaks. *Chest*. 2017;152(2):417–23. <https://doi.org/10.1016/j.chest.2017.02.020>.

## Publisher's Note

Springer Nature remains neutral with regard to jurisdictional claims in published maps and institutional affiliations.

**Ready to submit your research? Choose BMC and benefit from:**

- fast, convenient online submission
- thorough peer review by experienced researchers in your field
- rapid publication on acceptance
- support for research data, including large and complex data types
- gold Open Access which fosters wider collaboration and increased citations
- maximum visibility for your research: over 100M website views per year

**At BMC, research is always in progress.**

Learn more [biomedcentral.com/submissions](https://biomedcentral.com/submissions)

