

ORIGINAL ARTICLE

Open Access



# A novel approach to minimally invasive hysterectomy without the use of a uterine manipulator: Kamran's TLH

Ahmed M. Gendia , Noel E. Donlon and Waseem M. Kamran

## Abstract

**Background:** Hysterectomy remains one of the most common major gynaecological procedures, with total laparoscopic hysterectomy (TLH) now established as the technique of choice over conventional open approaches. This approach depends on the use of a uterine manipulator to facilitate uterine retraction and colpotomy. This study describes a novel approach in performing total laparoscopic hysterectomy without the use of uterine manipulator or vaginal tubes and reports the intra- and postoperative outcome of this technique.

**Methods:** A single-centre retrospective analysis of patients who underwent TLH without uterine manipulator or vaginal tube "Kamran's TLH" for benign conditions was performed from January 2017 to October 2019. Data collected included patients' demographics, intraoperative finding and postoperative course.

**Results:** A total of eighty-six hysterectomies were performed utilizing the Kamran's TLH (KTLH) approach. Mean age was 52.2 ( $\pm$  11) years old and BMI was 28.2 ( $\pm$  7). TLH with bilateral salpingo-oophorectomy was performed in 63 (73.3%) patients and TLH with preservation of ovaries in 23 (26.7%) patients. Mean operative time was 64.7 ( $\pm$  27.9) min and estimated blood loss was 46.2 ( $\pm$  54.6) ml. No intraoperative complications were recorded and there was no conversion to open surgery. Only one patient required readmission and surgery for vaginal vault dehiscence during their postoperative course.

**Conclusion:** Uterine manipulator is a key component in performing laparoscopic hysterectomy. However, our approach demonstrated that TLH can be safely performed without the use of any uterine or vaginal manipulation.

**Keywords:** Kamran's TLH, Uterine manipulator, Hysterectomy, TLH, Laparoscopic surgery, Total laparoscopic hysterectomy

## Background

Hysterectomy remains the most common major gynaecological procedure. Since the introduction of minimally invasive techniques in hysterectomy, several modifications have been adapted including vaginal and abdominal approaches [1]. Total laparoscopic hysterectomy (TLH) has been established as the procedure of choice among many laparoscopic surgeons. When compared to abdominal hysterectomy, laparoscopic approach provides a quicker recovery, a less blood loss, a shorter

hospital stay and less rate of infections [2]. Various TLH approaches has been described for both benign and malignant gynaecological diseases. Almost all of those techniques are dependent on the use of uterine manipulator or vaginal tubes [3]. Also, uterine manipulators are reported to offer the easiest way to manoeuvre the uterus [4]. Although, there is extensive literature published regarding TLH, only few studies reported TLH without the use of uterine manipulator or vaginal tube [5–7].

The aim of this study is to evaluate our technique in performing TLH without the use of uterine or vaginal manipulation and also to report our intra- and postoperative experience and to compare the results with the

\* Correspondence: [agandia@live.com](mailto:agandia@live.com)  
Beacon Hospital, Sandyford, Dublin, Ireland

data of standard TLH and TLH without uterine manipulation reported in literature.

## Methods

This is a retrospective analysis of patients who underwent TLH, without a uterine or vaginal manipulator, utilizing our technique, conducted by the Department of Gynaecology at the Beacon Hospital in Dublin, Ireland. This case series details 86 consecutive Kamran's TLH from January 2017 till October 2019. The inclusion criteria for this study were benign conditions including dysfunctional uterine bleeding, fibroids and endometriosis (Table 1). Exclusion criteria were malignancy involving uterus, cervix or ovary and patients who were deemed unsuitable for laparoscopy.

All data was collected from a prospectively maintained database and included patient's demographics, indication for hysterectomy, intraoperative findings, postoperative recovery and complications. All procedures were performed in a methodical and identical fashion by the same surgeon (WK) upon an agreed standard. All patients received prophylactic antibiotics. Follow-up included was in form of clinic visit usually 4–6 weeks after surgery, unless complication occurred.

The Clavien-Dindo score [8] was utilized to grade postoperative complications.

Data collected were presented as means or proportions  $\pm$  standard deviation. All statistical analyses were performed using SPSS version 18.0.

## Operative procedure

Patients are placed in lithotomy position; the abdomen, vagina and perineum are prepped and draped. A urinary catheter is inserted and the vagina is loosely packed with a sterile glove containing a swap to preserve the intrabdominal pneumoperitoneum during colpotomy. The energy device used in all cases was THUNDERBEAT®. However, any energy device can be applied according to preference.

Pneumoperitoneum is obtained using Hassan technique; four ports are placed: 12-mm port through umbilical, 5-mm in left lower side of the abdomen (assistant's port) and two 5-mm in the middle and lower right side of the abdomen (surgeon's ports).

The abdominal cavity and organs are inspected; then, Trendelenburg position is obtained to bring the bowel away from the pelvic. A systematic approach is followed to remove any adhesion in order to obtain the optimal view to start hysterectomy.

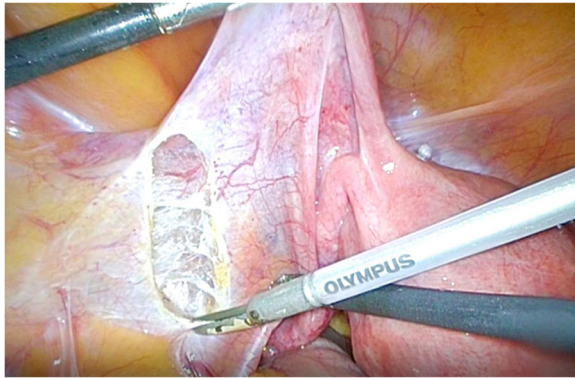
Traction on the broad ligament was applied near the uterine side using a grasper through the assistant's port to bring the uterus toward the anterior abdominal wall in order to stretch the infundibulo-pelvic ligament (Fig. 1). The infundibulo-pelvic ligament is coagulated and

**Table 1** Indications and characteristics of patients ( $n = 86$ )

| Indications                           | Number (%) (SD)  |
|---------------------------------------|------------------|
| Dysfunctional bleeding                | 37 (43)          |
| Pelvic pain                           | 14 (16.3)        |
| Dysmenorrhea                          | 2 (2.3)          |
| Pelvic mass                           | 8 (9.3)          |
| Protective surgery                    | 9 (10.5)         |
| Atypical hyperplasia                  | 12 (14)          |
| CIN1 (+ mild hyperplasia)             | 4 (4.6)          |
| Known fibroids                        | 20 (23.2)        |
| <b>Total</b>                          | <b>86</b>        |
| <b>Patients characteristics</b>       | <b>Data</b>      |
| Age                                   | 52.2 ( $\pm$ 11) |
| BMI                                   | 28.2 ( $\pm$ 7)  |
| Pre-menopause                         | 53 (61.6)        |
| Post-menopause                        | 33 (38.4)        |
| Nullipara                             | 17 (19.8)        |
| One para                              | 18 (20.9)        |
| Multipara                             | 51 (59.3)        |
| <b>ASA</b>                            |                  |
| 1                                     | 47 (54.7)        |
| 2                                     | 37 (43)          |
| 3                                     | 2 (2.3)          |
| 4                                     | 0                |
| <b>Surgical history</b>               |                  |
| Pelvic surgery                        | 23 (26.7)        |
| Vaginal                               | 5 (5.8)          |
| Paramedian incision                   | 12 (13.9)        |
| Pfannensteil                          | 20 (23.2)        |
| Midline laparotomy                    | 3 (3.5)          |
| Laparoscopy/ies                       | 37 (43)          |
| <b>Medical history</b>                |                  |
| Hypothyroid                           | 9 (10.5)         |
| HPN                                   | 16 (18.6)        |
| DM                                    | 1 (1.2)          |
| Anaemia                               | 6 (7)            |
| Non-gynaecological chemo/radiotherapy | 14 (16.3)        |
| Breast cancer                         | 9 (10.5)         |
| Smoker                                | 2 (2.3)          |
| Asthma                                | 11 (12.8)        |
| Anticoagulant/antiplatelet            | 7 (8.1)          |

Values are given as mean  $\pm$  SD (range) or number (percentage) unless stated otherwise

BMI body mass index (calculated as weight in kilogrammes by the square of height in meters)

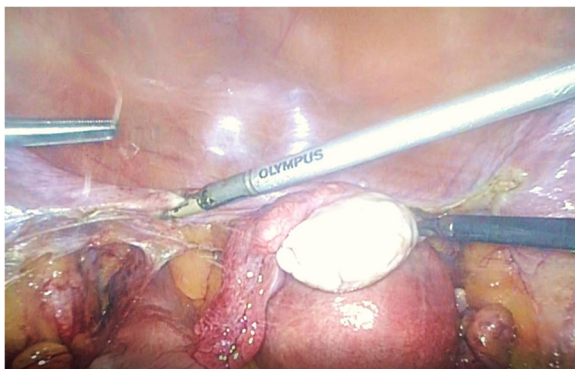


**Fig. 1** Stretching and transection of the infundibulo-pelvic ligament

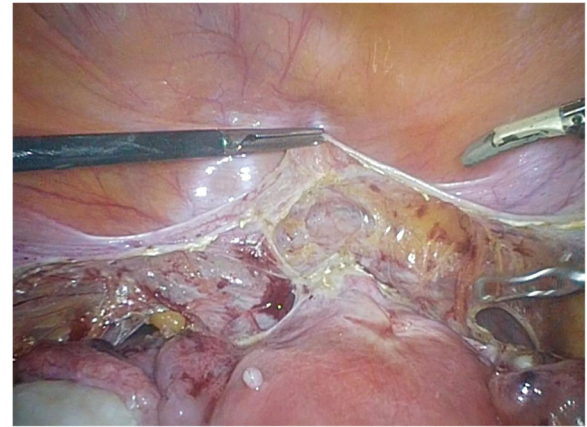
transected, which can be achieved with or without opening the pelvic side wall and is based on surgeon preference. The same step is repeated on the other side.

If salpingo-oophorectomy is planned, the ovarian ligament is coagulated and cut before dissecting the round ligament (Fig. 2). The latter is then dissected and its remnant is retracted to allow anterior peritonectomy until the bladder peritoneum is separated. The bladder is dissected away from the cervix uteri with the assistant applying traction of the bladder peritoneum toward the anterior abdominal wall, allowing the surgeon to dissect the utero-vesical fold (Fig. 3).

Further dissection of broad ligaments is applied toward utero-vesical space allowing uterine vessels to be skeletonized, coagulated and divided on both sides near uterocervical junction anteriorly. Traction on the remnant of round ligament attached to the uterus is applied bilaterally to antevert the uterus toward the anterior abdominal wall, which helps the surgeon to identify and dissect the uterosacral ligament. Further dissection of the latter helps to obtain the view of the demarcation between the vagina and the cervix (Fig. 4). A dip is visualized between the cervix and the vagina to prepare colpotomy. Colpotomy is performed close to cervix either



**Fig. 2** Coagulation and transection of the ovarian ligament



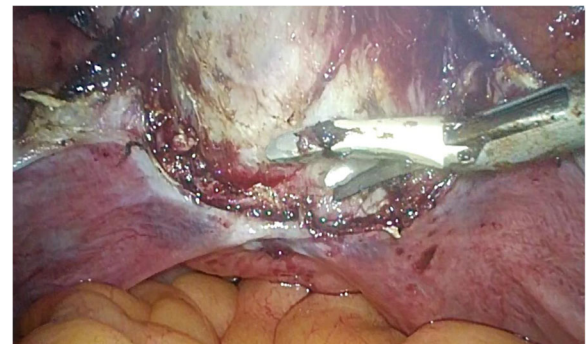
**Fig. 3** Reflection of the bladder away from the cervix uteri

anteriorly or posteriorly and is completed circumferentially before the specimen is extracted vaginally with the help of grasper. Finally, the vagina is closed laparoscopically with Vicryl suture and the bladder is checked by filling it with normal saline and one ampoule of blue dye. The technique was also described in a previous technical video [9].

The operative time was calculated from initial skin incision until wound closure.

## Results

Kamran's TLH (KTLH) was performed on 86 patients during a period of 34 months. Average patients' age was 52.2 ( $\pm 11$ ) years old with a mean BMI ( $\text{Kg/m}^2$ ) of 28.2 ( $\pm 7$ ). Nearly 25% of patients had some sort of previous pelvic surgery including Pfannenstiel laparotomy. The most common indication for hysterectomy was dysfunctional uterine bleeding at 43% (37/86). Fifty-one (59.3%) women were multiparous and 17 (19.8%) were nulliparous (Table 1). Of the 86 hysterectomies, 63 (73.3%) procedures were KTLH with bilateral salpingo-



**Fig. 4** Dissection of the uterosacral ligament to obtain the view of the demarcation between the vagina and the cervix to prepare the colpotomy

oophorectomy and 23 (26.7%) were KTLH and salpingectomy with preservation of ovaries. The overall mean operative time, from incision to closure of skin, was 64.7 ( $\pm$  28) min, with overall estimated blood loss (EBL) of 46.2 ( $\pm$  54.6) ml and total length of stay (LOS) of 3.3 ( $\pm$  1) days. Twenty-five cases required mild (7/8.1%) to complex/extensive (12/13.9%) adhesiolysis (Table 2).

Only 5 (5.8%) patients required insertion of drains which was subsequently removed on postoperative day two. While urinary catheter was kept for average of 1.4 ( $\pm$  0.6) days, bowel motion occurred after 2.2 ( $\pm$  0.75) days on average. Postoperative pain was calculated using visual analogy score (VAS) with 2.4 ( $\pm$  1.7), 3.7 ( $\pm$  2.1) and 1.4 ( $\pm$  1.3) on day 0, 1 and 3 postoperatively. The average days of analgesic requirement was 1.35 ( $\pm$  0.55) days. Table 2 summarizes the intraoperative and postoperative data.

**Table 2** Operative and postoperative data

|                                   | N (%) / (SD)       |
|-----------------------------------|--------------------|
| <b>Type of surgery</b>            |                    |
| TLH BSO                           | 63 (73.3 %)        |
| TLH BS                            | 23 (26.7%)         |
| <b>Total</b>                      | <b>86</b>          |
| <b>Operative data</b>             |                    |
| Unilateral ureterolysis           | 3 (3.5%)           |
| Bilateral ureterolysis            | 18 (20.9%)         |
| <b>Adhesiolysis</b>               | 25 (29%)           |
| Mild                              | 7 (8.1%)           |
| Moderate                          | 6 (6.9%)           |
| Extensive/complex                 | 12 (13.9%)         |
| <b>Operative time (min)</b>       | 64.7 ( $\pm$ 27.9) |
| <b>Estimated bloods loss (ml)</b> | 46.2 ( $\pm$ 54.6) |
| Drain (n)                         | 5 (5.8%)           |
| Mean (days)                       | 2 ( $\pm$ 0)       |
| <b>Postoperative data</b>         |                    |
| HG drop (g/L)                     | 1.2 ( $\pm$ .8)    |
| Average (days)                    |                    |
| Removal of urinary catheter       | 1.4 ( $\pm$ .6)    |
| Bowel motion                      | 2.2 ( $\pm$ .75)   |
| Mean LOS                          | 3.3 ( $\pm$ 1)     |
| <b>VAS (mean)</b>                 |                    |
| POD 0                             | 2.4 ( $\pm$ 1.7)   |
| POD 1                             | 3.7 ( $\pm$ 2.1)   |
| POD 3                             | 1.4 ( $\pm$ 1.3)   |
| Mean days of analgesic required   | 1.35 ( $\pm$ 0.55) |

Values are given as mean  $\pm$  SD (range) or number (percentage) unless stated otherwise

LOS length of stay, VAS visual analogy score

The most common histopathological finding was fibroid uterus (44/86–51.2%) followed by adenomyosis (25.6%) and endometriosis (16.3%). Postoperative complications were classified according to Dindo-Clavien score as demonstrated (Table 3). There was no intraoperative complication nor conversion to open surgery recorded in all included cases. Only one patient required readmission due to vaginal dehiscence which required repair under general anaesthesia. Other complications included extra antibiotics usage during admission (6), vaginal granulomas (2), vaginal vault infection (3), self-resolving pelvic collection (1) and UTI (2). Only 1 (1.1%) woman required postoperative bloods transfusion who was preoperatively anaemic.

## Discussion

Hysterectomy is one of the most commonly performed major gynaecological procedures. Since the introduction of total laparoscopic hysterectomy in 1993 [10], many surgeons have adopted various modifications and tools that could help in making the surgery safer and more accessible. One of the tools is the uterine manipulator which is widely used in various gynaecological procedures. It is regarded as a key instrument in total laparoscopic hysterectomy as it is thought to provide better visualization of surgical field, delineation of colpotomy and reducing risk of ureteric injury [4].

Despite technological advances and the contemporary implementation of laparoscopic hysterectomy as the standard of care, only few studies reported TLH without the use of uterine manipulator or vaginal tubes in the setting of benign conditions. One case study reported the efficacy and the safety in performing TLH without the use of manipulator or tube in two large uteruses, weighting 5700 g and 3670 g. This study highlighted the limitation of the manipulator in case of vaginal stenosis and restricted anatomy [6]. Mebes et al. reported the outcomes of TLH without manipulator between two groups according to uterus size and stated that laparoscopic hysterectomy without uterine manipulator can be more appropriate in cases of vaginal stenosis [11]. A retrospective study by Tinelli et al. compared TLH with and without the use of uterine manipulator in early-stage endometrial cancer and showed no difference in early recurrence between two groups. However, detailed operative technique was not reported [7].

A study on 67 laparoscopic hysterectomies by Kavalari et al. reported that TLH can be safely done without uterine manipulation. This study supported the hypothesis that total laparoscopic hysterectomy without manipulator (TLHwM) was appropriate and feasible in patients with vaginal stenosis and small cervix, where the application of instruments is inaccessible. Furthermore, this technique avoids the potential of short vagina

**Table 3** Postoperative complications

| Dindo-Clavien score (7) | Description   |                         | N = 86, N (%) |
|-------------------------|---|-------------------------|---------------|
| IIIB                    | Issues requiring intervention under general anaesthesia   | Vaginal dehiscence      | 1 (1.2)       |
| <b>Total</b>            |   |                         | 1 (1.2)       |
| IIIA                    | Issues requiring intervention not under general anaesthesia   | Vaginal granuloma       | 2 (2.3)       |
| <b>Total</b>            |   |                         | 2 (2.3)       |
| II                      | Issues requiring pharmacological treatment with drugs other than those allowed for grade I complications. Blood transfusions and total parenteral nutrition are also included.  | Vaginal infection       | 3             |
|                         |   | Pelvic collection       | 1             |
|                         |   | Extra antibiotics       | 6             |
|                         |   | Blood transfusion       | 1             |
|                         |   | Urinary tract infection | 2             |
| <b>Total</b>            |   |                         | 13 (15.1)     |
| I                       | Any deviation from the normal postoperative course not requiring therapy (allowed therapeutic regimens are drugs as antiemetics, antipyretics, analgesics, diuretics, electrolytes and physiotherapy; wound infections opened at the bedside) | --                      |               |
| <b>Total</b>            |   |                         |               |
| <b>Overall total</b>    |   |                         | 16 (18.6)     |

syndrome by incising it close to cervix, under direct visualization [5]. However, a limitation of the technique reported by both Kavallaris et al. [5] and Mebes et al. [11] was the requirement of digital vaginal manipulation and guidance at the stage of colpotomy. In contrast to this, our approach (KTLH) did not apply any vaginal instrumentation or manipulation during colpotomy which is guided by the demarcation between the cervix and vagina.

It is reported in the literature that uterine manipulator helps to reduce lower urinary tract injury by lateralization of uterus allowing perpendicular dissection of uterine arteries [12, 13]. According to a literature review on laparoscopic hysterectomy, the overall incidence of urinary tract injury was 0.73%, while ureteral injuries ranged from 0.02 to 0.4% and bladder injuries were 0.05–0.66% [14]. However, our present data demonstrated neither ureteric nor bladder injuries in all 86 women. Similarly, both Kavallaris et al. [5] and Mebes et al. [11] reported no lower urinary injury in their reports which shared the same technique of TLH without uterine manipulator. However, Tinelli et al. reported lower urinary tract injury in 5 (9%) patients undergoing TLH without manipulator for early endometrial cancer [7].

In the present study, the mean operative (64.7 min) time was shorter than reported in standard TLH (99.3 [15] and 126 min [16]). This is also less than reports by Kavallaris et al. (80–90 min) and Mebes et al. (90–111 min) [5, 7]. Additionally, we observed less intraoperative

blood loss comparing with TLH with uterine manipulator; Jugent et al. [17] and Candiani et al. [15] reported bloods loss of 98 ml and 83 ml, respectively, which were almost twice as much as our bloods loss ( $46.2 \pm 54.6$  ml). Kavallaris et al. (TLHwM) reported a similar estimated blood loss of 50 ml [5].

On analysing postoperative recovery, our reported pain and the requirement for analgesia were comparable to previous studies on TLH with the use of uterine manipulator [15, 18, 19]. Additionally, our length of stay ( $3.3 \pm 0.97$  days) was comparable to that reported in literature [2, 20, 21]. Under normal conditions, our patients could be discharged on postoperative day 1 or 2. This is keeping with a publication by Candiani et al. advocating the 33% of patient undergoing TLH could be discharged on day 2 after surgery. Moreover, hospitalization time does not entirely represent postoperative recovery, as it is often driven by economic aspects, hospital setting, patient's tolerance and local policies [2].

In the present study, similarly to Kavallaris et al. and Mebes et al. [5, 7], there were no intraoperative complications; intraoperative complications in TLH include bladder injury (1.2–2%), ureteral injury (0.6–0.9%), bowel injury (0.2–0.8%) and other laparoscopic-related injuries [22]. In many studies on total laparoscopic hysterectomy, intraoperative complications were not grouped and these are reported as overall postoperative complications [2]. Moreover, none of the 86 TLH in our

current study required conversion to open surgery. In previous reports, the rate of conversion was up to 5.8% [23–25]. This is mostly related to technical difficulties, extensive adhesion, uncontrolled bleeding and the experience of the surgeon.

In our series, postoperative complications were categorized according to the Clavien-Dindo score. There was only 1 (1.2%) grade IIIB complication; a patient with a vaginal wall dehiscence as a consequence of premature sexual intercourse. It required a vaginal-approached repair under general anaesthesia. This was the only complication requiring reintervention or admission. A review on 47 laparoscopic hysterectomy studies concluded that the incidence of vaginal dehiscence was up to 0.64% [26]. Grade IIIA complications occurred in 2 (2.3%) patients in the form of a vaginal granuloma which was excised in the outpatient clinic.

The rest of the complications were grade II (13/86 15.1%): 6 patients required extra antibiotics coverage, 3 patients developed vaginal vault infection, one pelvic collection which was spontaneously resorbed, one patient required bloods transfusion postoperatively for pre-operative anaemia and 2 urinary tract infections. Overall, the total number of all grades of complications was 16/86 (18.6%). Our reported complication rate is favourable when compared to Mereu et al. who retrospectively reviewed 361 TLH with similar overall complications rate (53/361–14.6%) [2].

Although uterine manipulator has several reported benefits, total laparoscopic hysterectomy without uterine manipulator (KTLH) is a systematic approach to perform TLH without uterine or vaginal manipulation. Our technique illustrated reduced operative time, reduced cost of procedural costs, obviates the need for an assistant for the manipulation and less intraoperative complications. KTLH is also beneficial in situations when application of uterine manipulator is inaccessible such as those with vaginal stenosis or huge uterus.

## Conclusion

Our experience in total laparoscopic hysterectomy demonstrated a safe, feasible and easily reproducible technique without the use of any uterine or vaginal manipulation that can be adopted universally by trainee and already practicing surgeon as well.

## Acknowledgements

None

## Authors' contributions

AG<sup>a</sup>, NED<sup>b</sup>, WK<sup>c</sup> <sup>a</sup>Data collection, data revalidation, writing manuscript and corresponding author. <sup>b</sup>Revising of manuscript. <sup>c</sup>Supervision and revision of manuscript/technique developer. The authors read and approved the final manuscript.

## Availability of data and materials

The data that support the findings of this study are available but restrictions apply to the availability of these data, which were used under licence for the current study and so are not publicly available. Data are however available from the authors upon reasonable request.

## Declarations

### Ethics approval and consent to participate

Approval to conduct retrospective auditing was obtained from the local auditing committee as a part of local audit and due to the nature of the retrospective study no further ethical approval or consenting was needed.

### Consent for publication

Consent for supplementary figures was obtained.

### Competing interests

The authors declare that they have no competing interests.

Received: 20 July 2020 Accepted: 9 June 2021

Published online: 21 June 2021

## References

- Elkington NM, Chou D (2006) A review of total laparoscopic hysterectomy: role, techniques and complications. *Curr Opin Obstet Gynecol* 18(4):380–384
- Mereu L et al (2018) Total laparoscopic hysterectomy for benign disease: outcomes and literature analysis. *Gynecol Surg* 15(1):19
- Popa A, Copaescu C, Horhoianu V (2019) Laparoscopic total hysterectomy still not routinely chosen Operative description and available instruments. *J Med Life* 12(3):301–307
- van den Haak L et al (2015) Efficacy and safety of uterine manipulators in laparoscopic surgery: a review. *Arch Gynecol Obstet* 292(5):1003–1011
- Kavallaris A et al (2011) Total laparoscopic hysterectomy without uterine manipulator: description of a new technique and its outcome. *Arch Gynecol Obstet* 283(5):1053–1057
- Macciò A et al (2018) Feasibility and safety of total laparoscopic hysterectomy for huge uteri without the use of uterine manipulator: description of emblematic cases. *Gynecol Surg* 15(1):6–6
- Tinelli R et al (2016) Laparoscopic treatment of early-stage endometrial cancer with and without uterine manipulator: our experience and review of literature. *Surg Oncol* 25(2):98–103
- Clavien PA, Sanabria JR, Strasberg SM (1992) Proposed classification of complications of surgery with examples of utility in cholecystectomy. *Surgery* 111(5):518–526
- Gendia AM, Donlon NE, Kamran WM (2020) A novel approach to minimally invasive hysterectomy without the use of a uterine manipulator: Kamran's TLH technique. *Gynecol Surg* 17(1):14
- Reich H (1997) In: Azziz R, Murphy AA (eds) *Laparoscopic hysterectomy, in Practical manual of operative laparoscopy and hysteroscopy*. Springer New York, New York, pp 194–208
- Mebes I, Diedrich K, Banz-Jansen C (2012) Total laparoscopic hysterectomy without uterine manipulator at big uterus weight (>280 g). *Arch Gynecol Obstet* 286(1):131–134
- Hohl MK, Hauser N (2010) Safe total intrafascial laparoscopic (TAIL™) hysterectomy: a prospective cohort study. *Gynecol Surg* 7(3):231–239
- Mueller A et al (2012) The Hohl instrument for optimizing total laparoscopic hysterectomy: results of more than 500 procedures in a university training center. *Arch Gynecol Obstet* 285(1):123–127
- Adelman MR, Bardsley TR, Sharp HT (2014) Urinary tract injuries in laparoscopic hysterectomy: a systematic review. *J Minim Invasive Gynecol* 21(4):558–566
- Mebes I et al (2009) Laparoscopic vs vaginal hysterectomy for benign pathology. *Am J Obstet Gynecol* 200(4):368.e1–368.e7
- Allam IS et al (2015) Total laparoscopic hysterectomy, vaginal hysterectomy and total abdominal hysterectomy using electrosurgical bipolar vessel sealing technique: a randomized controlled trial. *Arch Gynecol Obstet* 291(6):1341–1345
- Jugnet N et al (2001) Comparing vaginal and coelioscopic total or subtotal hysterectomies: prospective multicentre study including 82 patients. *Gynaecol Endosc* 10(5-6):315–321

18. Eggemann H et al (2018) Laparoscopic-assisted vaginal hysterectomy versus vaginal hysterectomy for benign uterine diseases: a prospective, randomized, multicenter, double-blind trial (LAVA). *Arch Gynecol Obstet* 297(2):479–485
19. Garry R et al (2004) EVALUATE hysterectomy trial: a multicentre randomised trial comparing abdominal, vaginal and laparoscopic methods of hysterectomy. *Health Technol Assess* 8(26):1–154
20. Wallwiener M et al (2013) Laparoscopic supracervical hysterectomy (LSH) versus total laparoscopic hysterectomy (TLH): an implementation study in 1,952 patients with an analysis of risk factors for conversion to laparotomy and complications, and of procedure-specific re-operations. *Arch Gynecol Obstet* 288(6):1329–1339
21. Morelli M et al (2007) Total laparoscopic hysterectomy versus vaginal hysterectomy: a prospective randomized trial. *Minerva Ginecol* 59(2):99–105
22. Moria A, Tulandi T (2011) A critical review of laparoscopic total hysterectomy versus laparoscopic supracervical hysterectomy. *Gynecol Surg* 8(1):7–12
23. Mousa A, Zarei A, Tulandi T (2009) Changing practice from laparoscopic supracervical hysterectomy to total hysterectomy. *J Obstet Gynaecol Can* 31(6):521–525
24. Harmanli OH et al (2009) A comparison of short-term outcomes between laparoscopic supracervical and total hysterectomy. *Am J Obstet Gynecol* 201(5):536.e1–536.e7
25. van Evert JS et al (2010) Laparoscopic subtotal hysterectomy versus laparoscopic total hysterectomy: a decade of experience. *Gynecol Surg* 7(1): 9–12
26. Uccella S et al (2011) Vaginal cuff closure after minimally invasive hysterectomy: our experience and systematic review of the literature. *Am J Obstet Gynecol* 205(2):119.e1–119.12

### Publisher's Note

Springer Nature remains neutral with regard to jurisdictional claims in published maps and institutional affiliations.

**Submit your manuscript to a SpringerOpen<sup>®</sup> journal and benefit from:**

- ▶ Convenient online submission
- ▶ Rigorous peer review
- ▶ Open access: articles freely available online
- ▶ High visibility within the field
- ▶ Retaining the copyright to your article

---

Submit your next manuscript at ▶ [springeropen.com](https://www.springeropen.com)

---