

ORIGINAL ARTICLE

Open Access



# An evaluation of a Myomscore in the preoperative assessment of uterus myomatosis: a new diagnostic standard? The experience at the Mathilden Hospital in Herford, Germany

R. Wojdat<sup>1\*†</sup> and E. Malanowska<sup>2†</sup>

**Keywords:** Myomscore, minimally invasive surgery, uterine fibroids, uterine sarcoma

## Introduction

Preoperative diagnosis of unsuspected malignant mesenchymal tumors is often challenging [1]. They can occasionally be confused with benign fibroids, which are the most common tumors in women of reproductive age [2, 3].

A wide variety of technologies and tools are involved in the diagnostic of uterine fibroids [4, 5]. However, we often choose expensive MRI, which cannot reliably distinguish between benign and malignant soft tissue masses [5, 6]. Also, specific serum biomarkers did not appear to be beneficial for diagnosis [7].

Minimally invasive procedures are gaining growing popularity in the treatment of uterine fibroids [1, 8]. However, methods such as “morcellation” carry the risk of deterioration of prognosis in case of a sarcoma [9].

The accidental discovery of malignant mesenchymal uterine tumors during surgery is unfortunately, still very common. The diversity and rarity of sarcomas, as well as the lack of preoperative identification may constitute a risk for any type of uterine surgery. Hence, minimally invasive methods are increasingly questioned [9–13].

After strong and repeated warnings by the FDA in 2014, rates of laparotomy have increased, without

improving patient outcomes [9–13]. At this point, question arises: does the fear of finding sarcoma explain choosing more health-impacting method of treatment even though there is no rationale for that?

Currently, only a few scoring systems are available to differentiate benign fibroids from malignant sarcomas [14, 15]. Unfortunately, it does not make the surgeon's task any simple. Collecting multiple epidemiological, anamnestic, and clinical variables in order to make a proper decision about the probability of sarcoma, do not help to undertake right decision about the surgery. Also, not every diagnostic technique is available in every center, and different techniques are advocated in different countries. Creating measurable, attainable preoperative scheme could improve the standardization of uterine fibroid diagnostics, without exposing the large number of low-risk patients to unnecessary surgical procedures.

The aim of this study was to determine the feasibility and preliminary effectiveness of preoperative score in patients, primary diagnosed with uterine fibroid, and qualified for surgery. Our intention was to identify group of patients who could benefit from such proceeding and through preoperative consulting take advantage of the entire range of operative procedures.

## Materials and methods

The study was approved by the Ethics Committee on Clinical Studies of Medical University of Münster (UKM).

\* Correspondence: [richard.wojdat@mathilden-hospital.de](mailto:richard.wojdat@mathilden-hospital.de)

†R. Wojdat and E. Malanowska contributed equally to this work.

<sup>1</sup>Clinic for Gynecology and Obstetrics, Mathilden Hospital Herford, Rennormauer 1-3, 32052 Herford, Germany

Full list of author information is available at the end of the article

**Table 1** Myomscore

Age	< 49	1	> 49	2
Bleeding history	Regular or heavy menstrual bleeding	1	Irregular	2
Growth history	“Static”	1	“Fast” or growth during therapy	2
Myoma size	< 5 cm	1	> 5 cm	2
Echogenicity	Ordered	1	Bizarre	2
Borders	Sharp	1	Fuzzy	2
Elastosonography	Hard	1	Soft	2
Doppler power mode	Peripheral circular circulation patterns	1	Diffuse, disordered circulation	2
Resistant index	RI > 0.4	1	RI < 0.4	2
LDH 1.2 x reference	Lower	1	Higher	2
Score	Score up to 12 points: morcellation possible (after consultation and explanation of a residual risk).		13 points or higher: surgery with oncological caution. Risk counselling!	

This prospective study included all women consecutively referred to our department from January 2016 to October 2018, who were diagnosed to have uterine fibroids and were all qualified for primary surgical treatment.

Objective evaluations were performed with pre-operative scoring system (Myomscore) with 10 individual criteria, giving each of them 1 or 2 points, presented in Table 1.

For our assessment, we included criteria that were described in the literature as sufficiently evaluated, safe, and easily ascertainable and reproducible [14, 15]. During the interview, we collected data about “myoma rapid growth.” “Fast growth fibroid” was defined as a double increase of fibroid’s diameter in a short time of observation (6 to 18 months) or growing of fibroids in

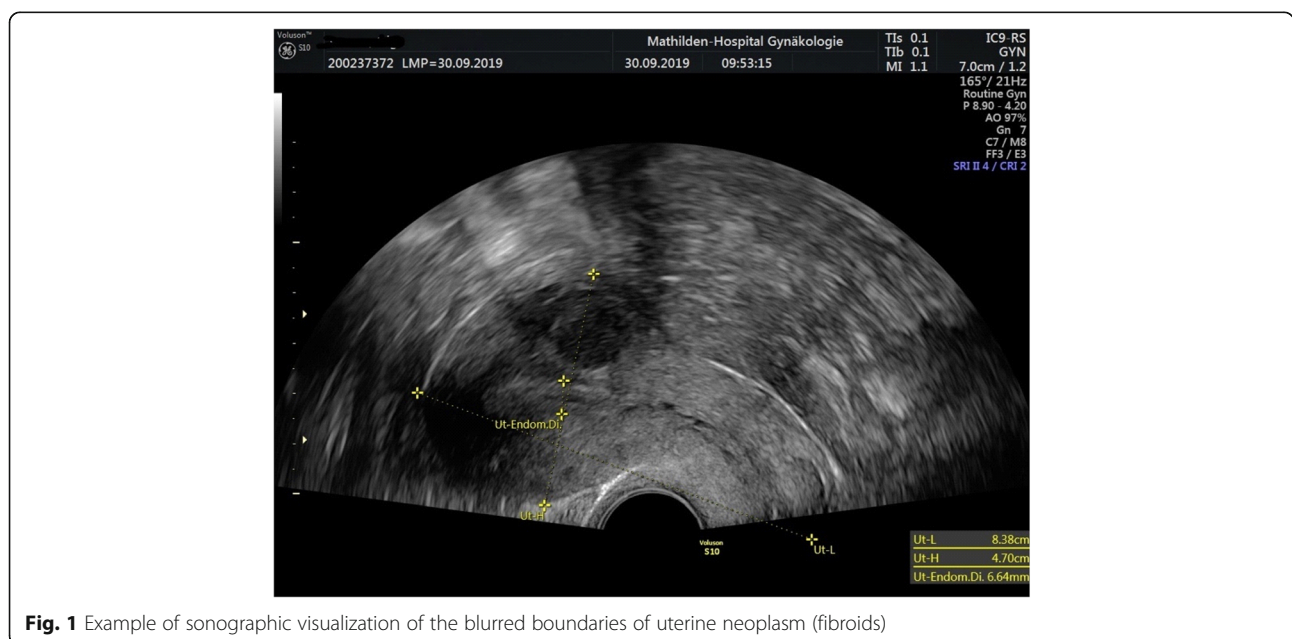
postmenopausal women. We excluded patients diagnosed with endometrial or cervical carcinoma.

All patients were examined by experienced gynecologist and underwent a standardized transvaginal sonography to exclude an endometrial lesion. Diagnostic hysteroscopy with curettage was used to evaluate abnormal endometrial findings.

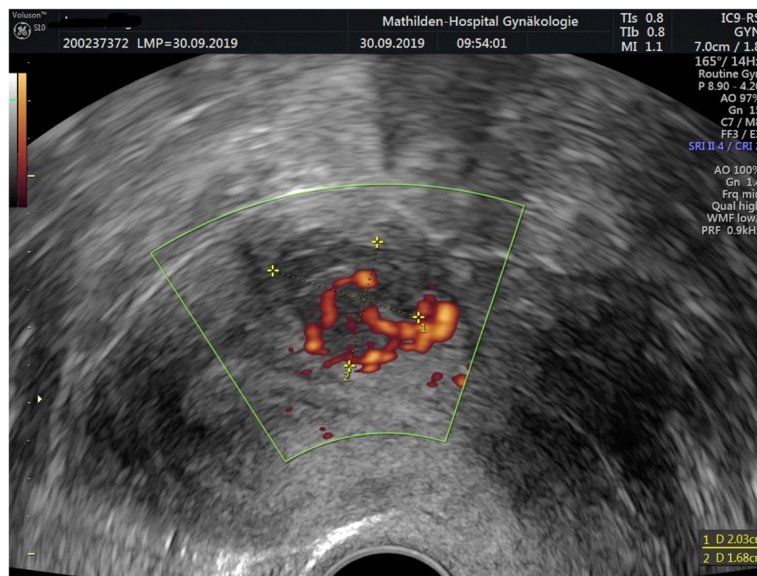
Ultrasound protocol included the following:

- Power Doppler mode (the mean intratumoral resistance index (RI))
- Real-time tissue elastosonography

In ultrasound protocol, we assessed in great detail elastic properties of uterine fibroids.



**Fig. 1** Example of sonographic visualization of the blurred boundaries of uterine neoplasm (fibroids)



**Fig. 2** Example of a diffuse vascular distribution in the fibroid

Elastography is a quantitative method for imaging the elasticity of biological tissues. It is an additional criterion for density and blood flow of uterine tissue. Tissue hardness can be read directly on the scale of the color gradation in elastosonography [16].

We defined as bizarre echogenicity: numerous of central and peripheral hypoechoic spaces, small cysts and necrosis of as assumed fibroid, as fuzzy borders—poorly defined margins to the myometrium, which suggests tumor infiltration of surrounding tissue.

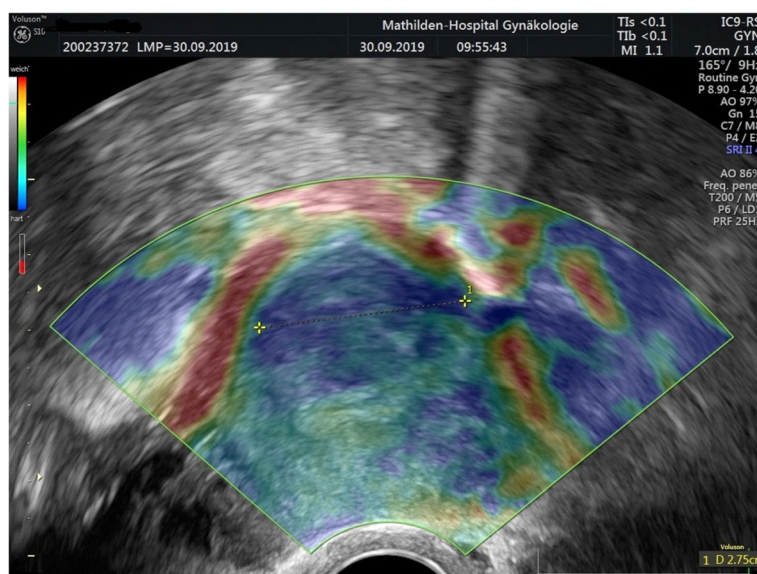
Figures 1, 2, 3, and 4 show sonographic characteristics.

### Preoperative counseling

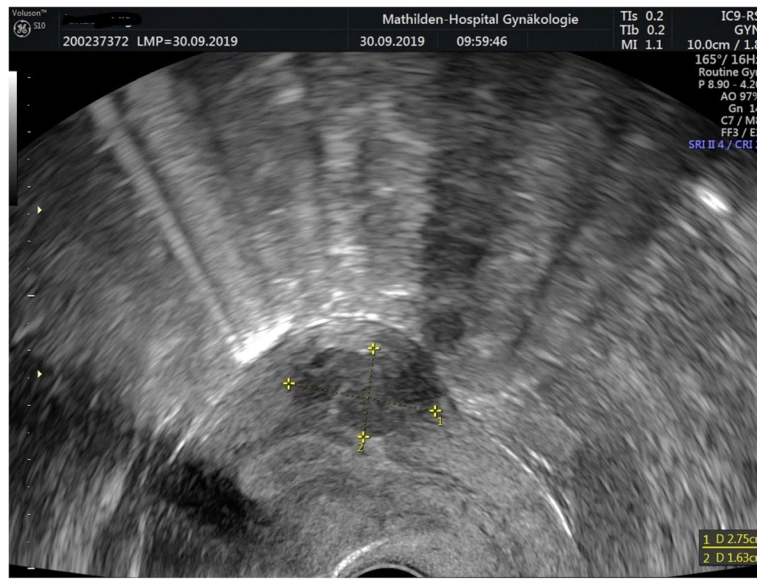
We offered all patients comprehensive preoperative patient-centered counseling providing them with information and allowing them to participate in the decision-making process.

All patients were informed about the possibility of a second opinion.

Standardized preoperative examination was performed and individualized surgical therapy was offered. Figure 5 depicts algorithm for the preoperative management of symptomatic uterine fibroids. The



**Fig. 3** Example of elasticity assessment of the fibroid tissue using elastosonography. According to the scale in the picture: red corresponds to soft tissue, blue corresponds to hard tissue



**Fig. 4** Example of homogeneity assessment of the uterine neoplasm, potential fibroids' tissue

decision about the surgery was made after carefully weighing all pros and cons.

The treatment corresponds to good medical practice and did not require randomization. All patients were informed about the evaluation of the current standards of care.

**Scoring system**

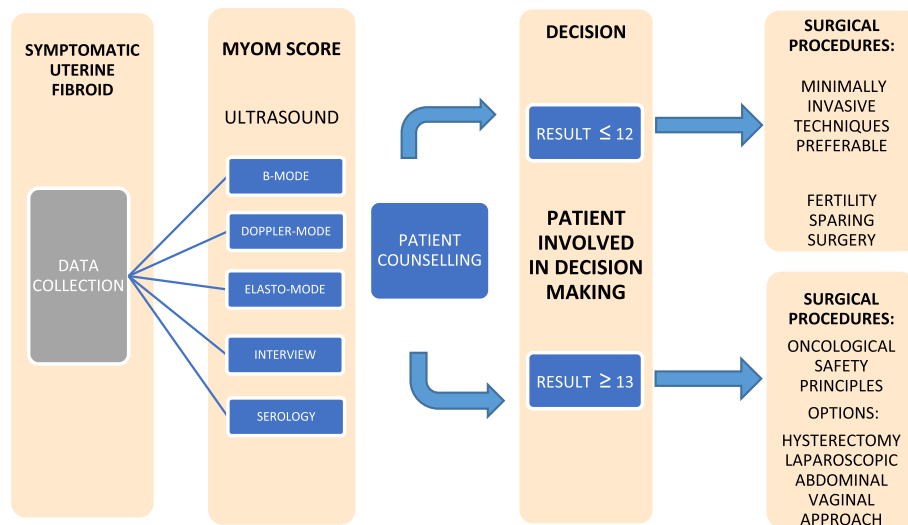
The patients' assignment into the groups was based upon the scores obtained.

We divided the patients to low- and high-risk groups. Patients were divided into 2 risk groups based on the score: low-risk ( $\leq 12$ ) and high-risk group ( $\geq 13$ ).

Low-risk group was offered all the range of laparoscopic procedures including fertility preserving procedures (like myoma enucleation) with or without morcellation, total and subtotal hysterectomy. This group of patients was informed about the lower risk of incidence of malignancy.

As a primary cutoff point, we have chosen score 13 intuitively.

Patients with score more than 13 were informed about the higher possibility of malignancy in this group. Total hysterectomy (laparoscopic, abdominal, vaginal approach) was offered as a method of first choice.



**Fig. 5** Algorithm for the preoperative management of symptomatic uterine fibroids



MRI was not the integral part of scoring system. It was an additional examination for patients with the history of pelvic disorders. We performed MRI to better determine fibroid boundaries and also to exclude potential metastatic process.

The preoperatively determined score was retrospectively compared with the histological result.

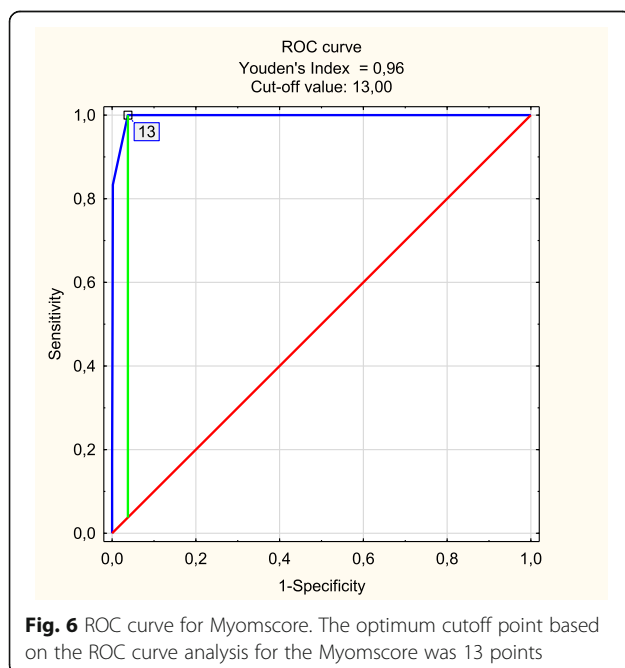
### Statistical evaluation

The Statistica 13 software was used for the analysis.  $p < 0.05$  was considered statistically significant.

The Shapiro-Wilk test was used to check the normality of the distributions. ROC analysis was performed for the method and the cutoff value was calculated.

First, data on the number of points obtained in terms of normality of distribution was examined. The hypothesis of the normal distribution of data should be rejected (Shapiro-Wilk test  $W = 0.850$ ,  $p = 0.000$ ).

The cutoff values for the Myomscore were derived from a receiver operating characteristic (ROC) curve. A value of 13 (Fig. 6, Youden index = 0.962, 95% CI (0.9448, 0.9974) was indicated as a statistically significant cutoff point for score, which confirmed the assumptions made in the method. Positive predictive value (PPV for this point) was equal to 0.122 and NPV 1000, sensitivity 1.00, and specificity 0.962. Accuracy ACC method is 0.963. False positive ratio was 0.038 and false negative ratio 0.000. Total error rate for the model is 0.037.



Data were entered into the database by one author (RW) and double-checked by another author (EM).

### Results

One thousand one hundred forty-three patients with diagnosis of symptomatic uterine fibroid were consecutively included in the study (Fig. 7). One thousand ninety-five were qualified preoperatively to low-risk group, and 48 to high-risk group (according to Myomscore). The results were painstakingly reconciled by a two-evaluator team (RW, EM).

More than 95% of all patients could receive desired minimally invasive method.

Our analysis revealed Myomscore cutoff value 13, what depicts Figs. 6 and 8.

The cutoff values for the Myomscore were derived from a receiver operating characteristic (ROC).

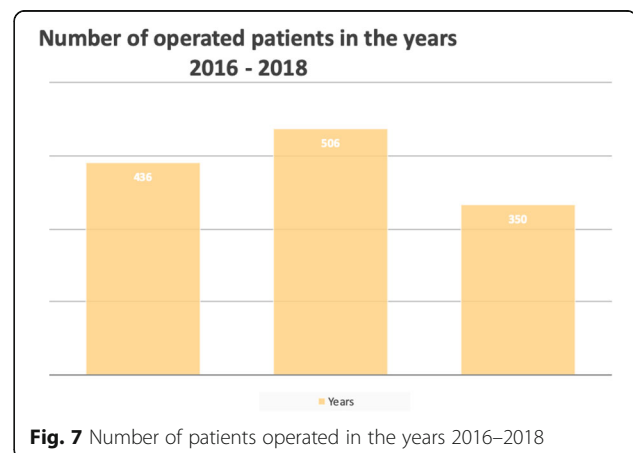
ROC analysis and its associated summary measures are placed in Table 2.

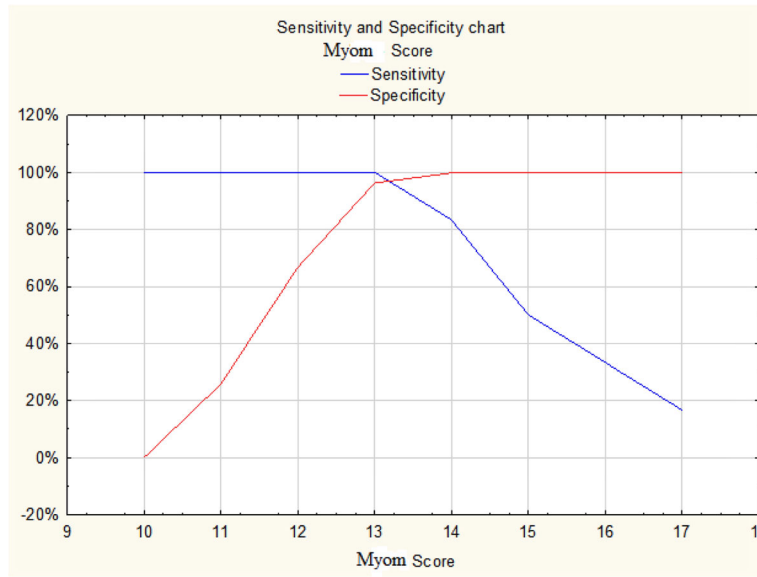
To better illustrate our results, we describe Myomscore distribution by age in age categories (Fig. 9). We also evaluated the relationship between Myomscore  $\geq 13$  and age with the use of z-test (Table 3). In all cases, the  $p$  values are greater than the adopted level of significance, and therefore no significant relationship with age was found ( $p > 0.05$ ).

Probability of finding a non-benign mesenchymal uterine tumor in the whole study group was 0.525%. Only 4.4% of all patients were included in the high-risk group.

The risk incidence of malignancy in the high-risk group was 12.5%. This was the result of Myomscore estimation.

We have found 6 uterine sarcomas postoperatively in the high-risk group of patients. Figure 10 describes ultrasonographic and histological findings in detail. All the patients undergone total hysterectomy (3 laparoscopic, 3 laparotomy). All sarcomas and smooth muscle tumors of uncertain malignant potential (STUMPs) had scores significantly greater than 13.





**Fig. 8** Myomscore sensitivity and specificity chart and cutoff value (sensitivity, 1.00 and specificity, 0.962)

**Discussion**

Although preoperative imaging and gross appearance are typical for uterine leiomyomas, uterine sarcoma is one of the most misdiagnosed types of cancer [17]. Even though magnetic resonance imaging seems reliable technique for evaluating uterine masses, the differential diagnosis between leiomyomas and leiomyosarcomas based on radiologic findings is difficult [18, 19].

Minimally invasive surgery provides many advantages for the patient. Compared with laparotomy, patients who undergo laparoscopy have reduced intraoperative bleeding, shorter hospitalization, less postoperative pain, and lower rates of postoperative wound infection [20].

According to FDA statement warning against the use of power morcellation, studies showed decreased rates of

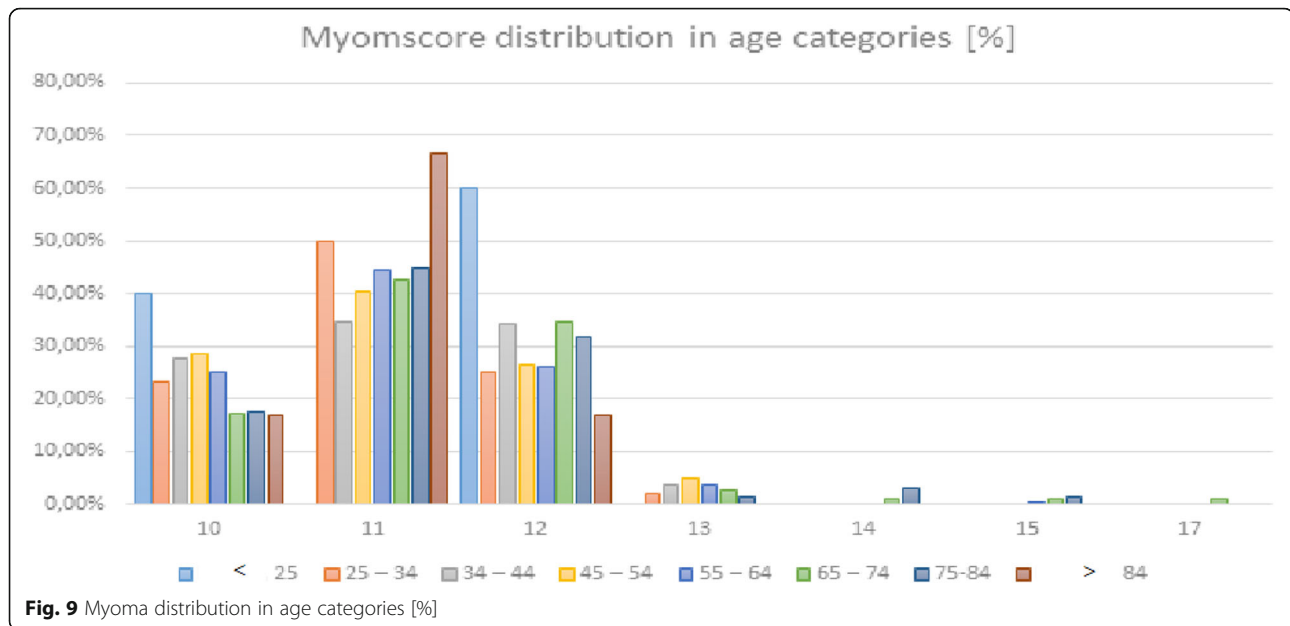
minimally invasive surgery and increased rates of open abdominal hysterectomy [9–13].

In our opinion, decreasing the numbers of minimally invasive procedures following reduced morcellation is not a good solution. In principle, all extirpating procedures used for hysterectomy, whether performed with laparotomy or laparoscopy, involve the risk of disseminating malignant cells in the abdominal cavity. However, gentle surgery, without unnecessary manipulations and without injury to the uterine surface could significantly reduce this risk [9].

Due to an increasing demand for fertility-preserving treatments for symptomatic uterine fibroids, hysterectomy is no more the method of first choice. Therefore, shared decision-making is a key component of patient-centered health care.

**Table 2** ROC analysis for Myomscore method

Myomscore	Sensitivity	Specificity	Accuracy (ACC)	PPV	NPV	False positive ratio	False negative ratio	Error rate	Youden index
17	0.167	1.000	0.996	1.000	0.996	0.000	0.833	0.004	0.167
15	0.500	0.999	0.997	0.750	0.997	0.001	0.500	0.003	0.499
14	0.833	0.998	0.997	0.714	0.999	0.002	0.167	0.003	0.832
13	<b>1.000</b>	<b>0.963</b>	<b>0.963</b>	<b>0.125</b>	<b>1.000</b>	<b>0.037</b>	<b>0.000</b>	<b>0.037</b>	<b>0.963</b>
12	1.000	0.667	0.669	0.016	1.000	0.333	0.000	0.331	0.667
11	1.000	0.258	0.262	0.007	1.000	0.742	0.000	0.738	0.258
10	1.000	0.000	0.005	0.005		1.000	0.000	0.995	0.000



In our study, we offered all patients comprehensive preoperative patient-centered counseling, allowing them to participate in the decision-making process. To improve this process, we need reliable diagnostic tools for decision management. Our aim should not be avoiding of minimally invasive techniques, but to find the individualized treatment option for each patient.

Involving patient in decision-making process is a very important issue of every preoperative counseling [21]. Patient shared responsibility allows us to avoid future medicolegal issues. Also, medical societies play a huge role to inform our patients about the state of the art therapy.

Scoring systems have been developed in response to an increasing emphasis on the evaluation of uterine sarcoma preoperatively [14, 15].

Our analysis showed a statistically significant cutoff point for Myomscore, which confirmed the assumptions made in the method. In contrast with other studies, we did not check each sarcoma predictor separately [14, 15]. Our purpose was to estimate the method, and results proofed the standardized method as valuable. Attained results support the conclusions of previous studies, which determined that preoperative scoring systems may improve diagnosis of uterine sarcoma [14, 15].

The weakness of the score is that in preoperative counseling, we inform all the patients with symptomatic fibroids about potential occurrence of malignancy, exposing low-risk patients to unnecessary stress. In

this regard, it is particularly important to provide sufficient information about surgical strategies. However, our low-risk patients could take another benefit by offering them non-surgical therapeutic options like embolisation, MR—guided focused ultrasound, or pharmacological treatment.

The problem of the scoring is the patients in the high-risk group who feel bound to the uterus, and want to preserve their organ. Patients should be informed about the increased risk of malignancy when the score is greater than 13. This proceeding relieves surgeon's responsibility from difficult decisions and makes patient to be more involved in the decision process.

The scoring application does not require any special instrument or skills. It does not generate any additional costs and offers a basis for discussion during patient consultation.

The Myomscore may be easily implemented into the routine preoperative examination, especially as a part of vaginal sonography. As there are many pitfalls in uterine fibroid sonography, transvaginal ultrasonography should be more standardized in myoma evaluation.

To establish correct result of interpretation of the sonographic patterns, it is also essential to avoid interobserver and intraobserver variability in the sonographic assessment of uterine fibroids. It is conceivable to use AI as future perspective.

As a standard of preoperative examination Myomscore could bring additional value for medical training and

**Table 3** The correlation between Myomscore with age ( $p > 0.05$ )

Myomscore $\geq 13$			
1st age group	2nd age group	z-test	p value
< 25, 0%	25–34, 1.8%	– 0.3013	0.76418
< 25, 0%	35–44, 3.5%	– 0.4286	0.6672
< 25, 0%	45–54, 4.6%	– 0.4909	0.62414
< 25, 0%	55–64, 4.0%	– 0.4539	0.65272
< 25, 0%	65–74, 5.5%	– 0.5364	0.5892
< 25, 0%	75–84, 5.8%	– 0.5536	0.58232
< 25, 0%	> 84, 0%	-	-
25–34, 1.8%	35–44, 3.5%	– 0.6781	0.4965
25–34, 1.8%	45–54, 4.6%	– 0.9783	0.32708
25–34, 1.8%	55–64, 4.0%	– 0.7848	0.4354
25–34, 1.8%	65–74, 5.5%	– 1.1121	0.267
25–34, 1.8%	75–84, 5.8%	– 1.1381	0.25428
25–34, 1.8%	> 84, 0%	0.4664	0.63836
35–44, 3.5%	45–54, 4.6%	– 0.6826	0.4965
35–44, 3.5%	55–64, 4.0%	– 0.2375	0.31034
35–44, 3.5%	65–74, 5.5%	– 0.858	0.38978
35–44, 3.5%	75–84, 5.8%	– 0.8564	0.38978
35–44, 3.5%	> 84, 0%	0.6637	0.50926
45–54, 4.6%	55–64, 4.0%	0.3639	0.71884
45–54, 4.6%	65–74, 5.5%	– 0.3731	0.71138
45–54, 4.6%	75–84, 5.8%	– 0.4316	0.6672
45–54, 4.6%	> 84, 0%	0.7602	0.44726
55–64, 4.0%	65–74, 5.5%	– 0.6091	0.54186
55–64, 4.0%	75–84, 5.8%	– 0.6403	0.52218
55–64, 4.0%	> 84, 0%	0.7026	0.48392
65–74, 5.5%	75–84, 5.8%	– 0.0971	0.92034
65–74, 5.5%	> 84, 0%	0.8297	0.40654
75–84, 5.8%	> 84, 0%	0.8554	0.38978

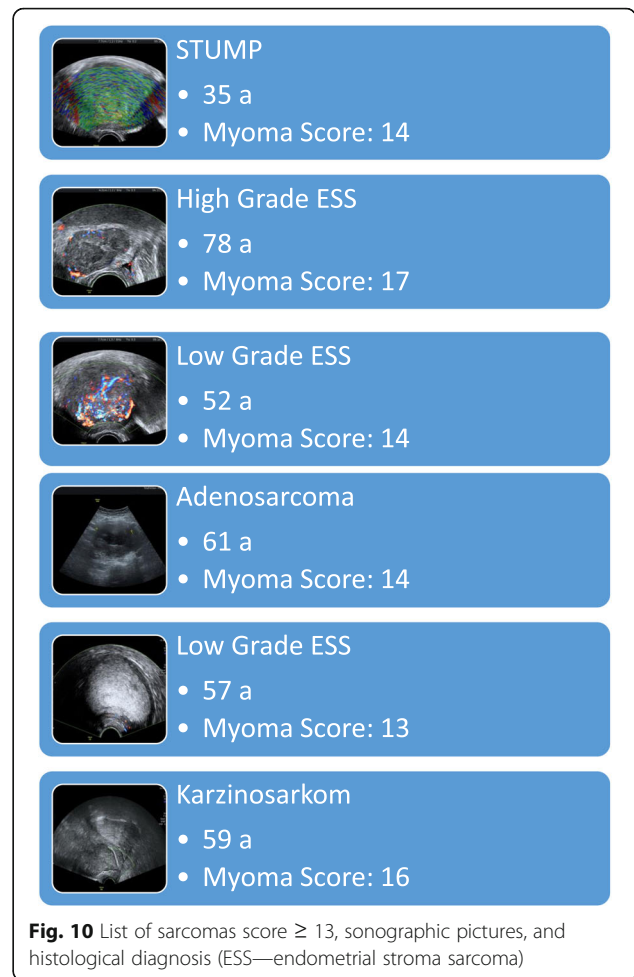
encourage gynecologists to examine uterine fibroids more carefully.

Finally, the use of score’s potential in the future is very promising. Collecting and analyzing data allow comparison of different groups of patients and will help to select which patients are in the group of high probability of malignancy.

Our aim was to find a score that can be easily used by every physician in daily practice. Although, we are fully aware of its limitations, we believe score will raise awareness among gynecologists of the importance of accurate assessment of uterine fibroids.

**Conclusions**

Myomscore defines different risk groups of patients who could benefit from optimal and safe surgical procedures.



Involving patients in decision-making process is score’s included value. This may help preventing medical issues in clinical practice.

Myomscore is a feasible and helpful tool, which can be used by every gynecologist in decision-making process.

**Abbreviations**

STUMP: Smooth muscle tumors of uncertain malignant potential; AI: Artificial intelligence

**Acknowledgements**

Thanks to all of the colleagues for their help with a project.

**Authors’ contributions**

R.W. developed the theoretical formalism and carried out the investigation. E.M. performed the methodology and analytic calculations. R.W. supervised the project. Both R.W. and E.M. authors contributed to the conception of the work, drafted the paper, approved the version to be published, and are accountable for all aspects of the work. The author(s) read and approved the final manuscript.

**Authors’ information**

R.W. is a head of a certified training center for gynecological MIS (EMICMa). He is involved in the development of medical and operative standards in operative gynecology, with strong emphasis on minimally invasive procedures. Myomscore is the result of his entire work and R.W. played a crucial role in developing the theory of this project.



E.M. is an assistant and a researcher at the Department of Gynecology in Szczecin, Poland. She is a supervisor and a collaborator of national and international research projects and reviewer in scientific journals in the field of gynecology. She contributed to the design and implementation of the research, to the analysis of the results, and to the writing of the manuscript.

#### Funding

This research has not been externally funded. Both authors declare that they have no conflict of interest and they have not received any financial support or honorarium.

#### Availability of data and materials

All data generated or analyzed during this study are included in this published article.

#### Ethics approval and consent to participate

The study was approved by the Ethics Committee on Clinical Studies of Medical University of Münster (UKM). AZ 2019-702-f-S

#### Consent for publication

Not applicable

#### Competing interests

The authors declare that they have no competing interests.

#### Author details

<sup>1</sup>Clinic for Gynecology and Obstetrics, Mathilden Hospital Herford, Renntormauer 1-3, 32052 Herford, Germany. <sup>2</sup>Department of Gynecology, Endocrinology and Gynecologic Oncology, Pomeranian Medical University, Unii Lubelskiej 1, 70-001 Szczecin, Poland.

Received: 3 October 2019 Accepted: 29 May 2020

Published online: 06 July 2020

#### References

- Kitty Pavlakis, Irimi Messini, Petros Yiannou et. al. Morcellating uterine mesenchymal tumors: The pathologist's View. *J. Obstet. Gynaecol. Res.* 2017
- Baird DD, Dunson DB, Hill MC, Cousins D, Schectman JM (2003) High cumulative incidence of uterine leiomyoma in black and white women: ultrasound evidence. *Am J Obstet Gynecol.* 188:100–107
- Laughlin SK, Schroeder JC, Baird DD (2010) New directions in the epidemiology of uterine fibroids. *Semin Reprod Med.* 28(3):204–217
- De La Cruz MS, Buchanan EM (2017) Uterine Fibroids Diagnosis and Treatment. *Am Fam Physician.* 95(2):100–107
- Lumsden MA, Hamoodi I, Gupta J, Hickey M (2015) Fibroids: diagnosis and management. *BMJ:h4887*
- Heidi Buvarp Dyrop, Peter Vedsted, Mathias Rædkjær, Akmal Safwat, Johnny Keller Imaging investigations before referral to a sarcoma center delay the final diagnosis of uculoskeletal sarcoma. *Acta Orthop.* 2017 Apr; 88(2): 211–216.
- Levy G., J. Hill M, Plowden TC, Biomarkers in uterine leiomyoma. *Fertil Steril.* 2013 Mar 15; 99(4): 1146–1152.
- Gingold JA, Gueye NA, Falcone T (2018) Minimally Invasive Approaches to Myoma Management. *J Minim Invasive Gynecol.* 25(2):237–250
- M. W. Beckmann, I. Juhasz-Böss, D. Denschlag, et al. Surgical Methods for the Treatment of Uterine Fibroids - Risk of Uterine Sarcoma and Problems of Morcellation : Position paper of the DGGG. 2015 Feb; 75(2): 148–164.
- <http://www.fda.gov/MedicalDevices/Safety/AlertsandNotices/ucm393576.htm>; last access 31.01.2017.
- <http://www.fda.gov/MedicalDevices/Safety/AlertsandNotices/ucm424443.htm>; last access 31.01.2017.
- Lum DA, Sokol ER, Berek JS et al (2016) Impact of the 2014 Food and Drug Administration Warnings Against Power Morcellation. *J Minim Invasive Gynecol.* 23(4):548–556
- Multinu F, Casarin J, Hanson KT, Angioni S, Mariani A, Habermann EB, Laughlin-Tommaso SK. Practice Patterns and Complications of Benign Hysterectomy Following the FDA Statement Warning Against the Use of Power Morcellation. *JAMA Surg.* 2018 Jun 20;153(6) :e 180141. Epub 2018 Jun 20.
- Köhler G, Vollmer M et al (2019 Dec) Benign uterine mass—discrimination from leiomyosarcoma by a preoperative risk score: a multicenter cohort study. *Archives of Gynecology and Obstetrics.* 300(6):1719–1727
- Nagai T, Takai Y, Akahori T, Ishida H, Hanaoka T, Uotani T et al (2015) Highly improved accuracy of the revised PREoperative sarcoma score (rPRESS) in the decision of performing surgery for patients presenting with a uterine mass. *Springerplus* 4:520
- Furukawa S, Soeda S, Watanabe T, et al. The measurement of stiffness of uterine smooth muscle tumor by elastography. *Springerplus.* 2014; 3: 294. Published online 2014 Jun 11.
- Cui RR, Wright JD (2016) Risk of Occult Uterine Sarcoma in Presumed Uterine Fibroids. *Clinical Obstetrics and Gynecology* 59(1):103–118
- Schwartz LB, Zawin M, Carcangiu ML, Lange R, McCarthy S (1998) Does pelvic magnetic resonance imaging differentiate among the histologic subtypes of uterine leiomyomata? *Fertil Steril* 70:580–587
- Arakawa A, Yasunaga T, Yano S, Morishita K, Nakashima K, Sato R et al (1993) Radiological findings of retroperitoneal leiomyoma and leiomyosarcoma: report of two cases. *Comput Med Imaging Graph* 17:125–131
- Obermair A, Manolitsas TP, Leung Y, Hammond IG, McCartney AJ (2005) Total laparoscopic hysterectomy versus total abdominal hysterectomy for obese women with endometrial cancer. *Int J Gynecol Cancer* 15:319–324
- Johnson BE, Porter J (2008 May) Preoperative evaluation of the gynecologic patient: considerations for improved outcomes. *Obstet Gynecol.* 111(5):1183–1194

#### Publisher's Note

Springer Nature remains neutral with regard to jurisdictional claims in published maps and institutional affiliations.

Submit your manuscript to a SpringerOpen® journal and benefit from:

- Convenient online submission
- Rigorous peer review
- Open access: articles freely available online
- High visibility within the field
- Retaining the copyright to your article

Submit your next manuscript at ► [springeropen.com](https://www.springeropen.com)