

Review

Application of magnetic resonance imaging to angiogenesis in breast cancer

Martin O Leach

CRC Clinical Magnetic Resonance Research Group, The Institute of Cancer Research and The Royal Marsden NHS Trust, Sutton, Surrey, UK

Correspondence: Martin O Leach, CRC Clinical Magnetic Resonance Research Group, The Institute of Cancer Research and The Royal Marsden NHS Trust, Downs Road, Sutton, Surrey, SM2 5PT, UK. Tel: +44 208 661 3338; fax: +44 208 643 3812; e-mail: Martin@icr.ac.uk

Received: 23 October 2000

Breast Cancer Res 2001, **3**:22–27

Revisions requested: 3 November 2000

Revisions received: 16 November 2000

Accepted: 16 November 2000

© BioMed Central Ltd on behalf of the copyright holder
(Print ISSN 1465-5411; Online ISSN 1465-542X)

Published: 13 December 2000

Abstract

Magnetic resonance imaging (MRI) techniques enable vascular function to be mapped with high spatial resolution. Current methods for imaging in breast cancer are described, and a review of recent studies that compared dynamic contrast-enhanced MRI with histopathological indicators of tumour vascular status is provided. These studies show correlation between *in vivo* dynamic contrast measurements and *in vitro* histopathology. Dynamic contrast enhanced MRI is also being applied to assessment of the response of breast tumours to treatment.

Keywords: angiogenesis, breast cancer, dynamic contrast enhanced imaging, magnetic resonance imaging, vascular permeability

Introduction

The present review describes the use of MRI to evaluate neoangiogenesis in breast tumours noninvasively. MRI is now widely used to provide anatomical cross-sectional images, with excellent definition of soft-tissue morphology. For many applications, the technique has supplanted computed tomography, particularly for imaging of the central nervous system. Unlike conventional X-ray imaging or computed tomography, which produce images that show the X-ray attenuation of tissues, MRI measures the amount of hydrogenous materials (water and lipid) in tissues. The technique allows the appearance of images to be modulated, allowing a range of different images to be obtained from any given set of tissues. This ability to select and manipulate the contrast between different tissues, as well as to obtain image sections at any orientation, has led to a rapidly growing range of clinical applications.

In imaging breast cancer, MRI is increasingly being used in clinical problem solving, in situations in which X-ray

mammography is equivocal (due for example to dense breast parenchyma, surgery or breast implants) and ultrasound is not informative. Many of the clinical applications to date pertain to morphological evaluation, often based on the use of contrast agents, which highlight areas with increased vascular permeability. Such high-resolution images enable sections through the breast to be observed, typically providing full three-dimensional image sets of both breasts, allowing identification of multifocal and contralateral disease. Such images allow cancer to be detected with high sensitivity, but may not distinguish some benign conditions, particularly fibroadenoma, from malignant disease.

More sophisticated MRI methods have recently been developed that provide additional, functional information about tumours. By observing the uptake and washout of MRI contrast agents, malignant and benign disease can be better discriminated. Using methods that involve measurement of the transit of contrast through the vascular

bed, and fitting the uptake and washout of contrast to mathematical models of tissues, images of tissue perfusion and contrast exchange between tissue and the vascular bed can be calculated. These functional images aid diagnosis, but also provide measures that relate to histological assessments of vascular density, providing a non-invasive method for measuring angiogenesis. Such techniques may help to identify those patients who would benefit from antiangiogenic or antivascular treatments, and are being evaluated as methods for assessing the response to such treatments.

Tumour neoangiogenesis

As tumours develop, their metabolic demand for oxygen and substrates exceeds the capacity of diffusion mechanisms to deliver these substances. It is a necessary condition for further growth (above a few millimetres in diameter) that the tumour develops supporting vasculature [1**]. This is achieved by stress-induced release of growth factors such as vascular endothelial growth factor (VEGF), which can induce the development of a characteristically permeable VEGF-dependent neovasculature. With continued growth, a disordered vascular structure develops, which usually has a large blood volume and which may contain vessels having differing degrees of maturity and physiological control, together with varying perfusion and levels of oxygenation. Maintaining this vascular structure is a dynamic process, with regional changes in growth factor expression in response to local conditions.

Angiogenesis is a complex process that is not yet fully understood. Currently, it is principally assessed by histopathological examination [2**], but MRI technology is providing a promising noninvasive investigational tool.

Magnetic resonance imaging

MRI is a powerful technique for assessing soft tissues, allowing imaging with high spatial resolution. Images comprise a number of slices, which can be acquired in any orientation, and which have a high spatial resolution in the plane (typically 0.5–2 mm), with the slice thickness ranging from 3 to 8 mm. Three-dimensional images can also be acquired by employing thinner slices or isotropic resolution. MRI measures the signal from mobile hydrogen-containing molecules in the body, with the mobility of the molecules modulating the intensity of the signal. In the breast, MRI shows signal from breast parenchyma (predominantly water) and from lipids, the two signals having very different characteristics. By modifying the way in which the MRI scanner performs the measurements (the parameters of pulse sequences), the appearance of tissues in images can be altered dramatically. T1-weighted images show lipid as bright and parenchyma as dark. Tumour also tends to be dark. T2-weighted images show parenchyma as brighter than fat, and tumour also tends to be bright. Recent reviews of MRI in breast cancer [3*–5*] provide more detailed information.

MRI is intrinsically sensitive to movement, which provides a powerful means to assess blood flow. This feature is widely employed in several magnetic resonance angiography techniques. One approach – time of flight angiography – utilizes the difference in magnetization between a slice of tissue being measured and blood flowing into the slice, which allows visualization of major vessels. Another approach – phase-contrast angiography – utilizes a change in the properties of the magnetism as blood moves in the presence of a gradient. These techniques are most helpful in evaluating larger vessels, but the basic techniques contribute to methods for assessing perfusion and the self-diffusion of water. The sensitivity of magnetic resonance angiography can be increased by using contrast agents.

Contrast-enhanced imaging

Advances in the application of MRI to breast cancer have depended predominantly on the use of magnetic resonance contrast agents to enhance the appearance of lesions. The most widely used contrast agents are chelates of gadolinium, a lanthanide with three unpaired electrons that has a very strong magnetic field. Chelates such as diaminotetra-ethyl penta-acetic acid (DTPA) strongly bind the gadolinium, which avoids toxicity while allowing access of water molecules to the gadolinium.

The strongly paramagnetic gadolinium has several effects. It can change (relax) the magnetic state of hydrogen atoms in water molecules; this markedly changes the appearance of tissues, with a high contrast agent uptake in T1-weighted images, causing tissues to appear bright. High concentrations of gadolinium chelates can also induce local changes in the magnetic field (magnetic susceptibility). This is most apparent during the first pass of a bolus of contrast agent after rapid intravenous injection. On gradient echo T2*-weighted images, this effect is apparent as a darkening of the image in well-perfused areas of tissue.

Dynamic measurements, in which the uptake and washout of contrast in tissues is monitored with time, can assist in the diagnosis of breast tumours and can provide information on vascular permeability and perfusion, by quantifying and analyzing image intensity changes, and fitting these to analytical or model functions. Considerable effort is being devoted to the development of new contrast agents; macromolecular agents, which exhibit lower vascular permeability or are limited to the blood pool, are currently being developed and used in preclinical research. Agents that use superparamagnetic or ferrite particles cause large T2* signal losses, and are also being investigated. An area that will grow in importance is the use of agents based on the above approaches that can report on the cellular expression of specific receptors, transfected genes or oncogenes.

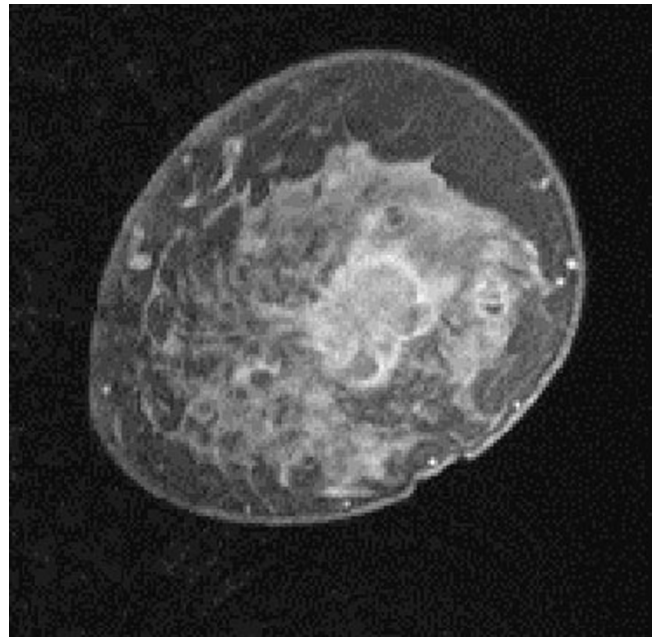
Conventional diagnosis of breast disease utilizes information on contrast-enhanced morphology and on the dynamic behaviour of the contrast agent. T1-weighted multislice sequences, or three-dimensional sequences, provide spatial information, but there is usually a trade off between spatial and temporal resolution. Information from both approaches has been used for diagnosis, with a developing consensus that a combination of morphology and dynamic information will maximize specificity [6*]. Morphological information identifies areas of permeable vasculature, showing the way in which these areas relate to normal breast architecture, and certain benign and malignant lesions have characteristic appearances. Fig. 1 shows an example of an infiltrating ductal carcinoma in a 50-year-old woman, which shows characteristic rim enhancement.

Dynamic information shows the rate at which tissue enhances, and subsequently the rate at which contrast agent washes out. This depends on delivery of the agent (perfusion), the ability of the agent to leak out of the vasculature (vascular permeability), and the extracellular, extravascular volume (v_e – the capacity of the tissue to take up contrast agent). Thus, the contrast agent provides a non-invasive probe of the tissue vasculature, a critical aspect of tumour architecture and regulation. Usually, a region of interest (ROI) is selected within the tumour, and the software that is provided with the magnetic resonance scanner is used to evaluate the change in signal intensity with time in that ROI. Often, if three-dimensional imaging is employed, images are taken at intervals of typically 90s. Permeable, well-perfused tissues exhibit a rapid rise in contrast, followed by evidence of washout by 4–5 min after bolus injection. This is highly suggestive of malignant disease, although some fibroadenomas can show similar features.

Although they aid diagnosis, simple T1-weighted images do not provide quantitative information, and cannot be used directly in models to obtain quantitative parameters that describe uptake.

Quantitative techniques [7*] that are often combined with rapid temporal sampling have been used, together with simple compartmental models of tissues, to obtain parameters such as v_e , the transfer constant (K^{trans}) and the rate constant (k_{ep}) [8*]. These latter two parameters combine information on perfusion and tissue permeability, and provide a way to assess the 'leakiness' of vasculature, which is believed to reflect the degree of angiogenesis within the tumour. K^{trans} describes the flux of contrast agent through the vascular endothelium. If delivery to v_e is not limited by perfusion (ie delivery to the endothelium) but by the leakiness of the endothelium, then K^{trans} is the capillary endothelial permeability surface area product, describing vascular permeability. However, if delivery is limited by perfusion, then when permeability is high K^{trans} is equal to the blood plasma flow per unit volume of tissue. Thus, high values of K^{trans} indicate

Figure 1



A T1-weighted postcontrast image from a three-dimensional fat-suppressed sequence, showing distinctive rim enhancement. Reprinted from *Magn Reson Imaging*, volume 18, Brown *et al*, Magnetic resonance imaging screening in women at genetic risk of breast cancer: imaging and analysis protocol for the UK multicentre study, pp 765–776. Copyright 2000, with permission from Elsevier Science.

high permeability and probably high perfusion. Low values of K^{trans} indicate either low permeability and/or low perfusion. The constant k_{ep} describes the flux of contrast agent between v_e and the blood plasma, and is equal to K^{trans}/v_e .

The accuracy of these parameters in monitoring vascular properties depends on whether quantitative imaging techniques that allow T1 to be calculated are used. When obtained with such methods, these parameters relate closely to tissue properties and are independent of imaging methods and instruments used. However, they are not solely dependent on vascular endothelial permeability, and this needs to be borne in mind when interpreting results. Recent developments have allowed these parameters to be mapped on a pixel-by-pixel basis, providing a colour parametric image and allowing a description of the variation in tumour vasculature throughout the tumour [9]. This is likely to be a more informative approach than taking a tumour average of these parameters or performing a ROI analysis to assess prognosis and response.

Clinical studies that correlate dynamic parameters with histopathology

Several studies have examined the correlation between dynamic imaging parameters and histopathological

assessment. Buckley *et al* [10] compared simple indices of enhancement and parameters from a two-compartmental model with microvessel density (MVD). A significant correlation was found between initial enhancement in the maximally enhancing ROI and MVD ($P=0.002$), and this correlation was stronger in node-positive tumours. A similar study in 73 patients [11] found associations between slope of uptake and MVD ($P<0.001$) and between MVD grade and curve type ($P<0.001$).

Frouge *et al* [12] compared dynamic MRI with quantification of tumour angiogenesis by immunohistological staining in 20 patients with small palpable lumps. After excluding patients with motion artefacts, poor alignment with histology, and benign and nonbreast-originating disease, nine patients were evaluable. One of these showed no contrast enhancement. Factor analysis identified three separable enhancement components, of which the first peaked at 40 s after injection and fell rapidly, and the second peaked at 2 min and decreased more slowly. In four patients, early enhancement (the first factor) was found to correlate with a high concentration of arterioles or intratumour repair processes. In eight patients the second factor was associated with tumour capillaries. The third factor also reached a maximum at about 2 min, but did not then decrease; this was seen in three women and was associated with fibrosis.

A study in 44 women with invasive breast cancer [13] compared dynamic contrast-enhanced measurements with histological assessment of microvessel density using staining with anti-CD34 antibody. The authors found increased microvessel density in the periphery of the tumours, and reported that enhancement correlated with microvessel density and that there was a significant association between histological grade and both the steepest part of the uptake curve and microvessel density. However, it should be noted that the limited time resolution (90 s) for each of the three three-dimensional images provides limited scope for differentiating different uptake rates.

Stomper *et al* [14] compared enhancement parameters with factor VIII staining and vessel density measurement in 48 breast lesions following excisional biopsy. Vessel densities in 25 malignant lesions were not significantly different on histological evaluation from those in 23 benign lesions. Seven out of the eight fibroadenomas had high vessel density. Higher vessel density was associated with increased contrast uptake ($P=0.02$), but the rate and washout of enhancement showed no significant association with vessel density. This is in accord with the limited discrimination of contrast enhancement dynamics between malignant and benign (particularly fibroadenoma) disease. The MRI measurement and analysis technique employed in that study might have been biased by pre-contrast lesion T1, and had limited time resolution. No modelling parameters were derived.

Knopp *et al* [15] compared histological parameters (vascular density using CD31, vascular permeability using VEGF) with enhancement parameters. They were able to show a dependence of enhancement kinetics on VEGF expression, and demonstrated differences in enhancement parameters between different histological tumour types and between malignant and benign disease.

Seventy-one breast lesions were investigated [16] using echo-planar imaging to calculate extraction-flow products, but no significant correlation between MVD and extraction-flow product was identified. Echo-planar imaging is not widely used in breast imaging.

Early enhancement in 36 women with ductal carcinoma *in situ* (DCIS) was investigated [17]. Angiogenesis in the stroma surrounding ducts (as demonstrated by immunoperoxidase staining) was shown to correlate with early contrast enhancement in 34 patients with DCIS, but not in two with comedo-type DCIS.

Experimental studies of dynamic enhanced contrast uptake

Modelling parameters have been obtained [18,19**] using the Tofts and Kermode model (K^{trans} , v_e) in an MCF7 human breast cancer xenograft in nude mice. High values of K^{trans} were found in regions that histologically demonstrated a high density of permeable microcapillaries; these regions were in the tumour periphery and in intratumoural regions that surrounded areas of necrosis. This was believed to represent stress-induced angiogenesis. This induction of angiogenesis was augmented on treatment with tamoxifen.

The same group [20] also used the MCF7 tumour line, together with a three-point assessment of contrast agent uptake, to show that tamoxifen treatment increased the number of voxels that displayed rapid contrast uptake and the number of voxels that showed intermediate clearance (ie a plateau phase). This was believed to result from increased extracellular volume and increased microvascular permeability, which those investigators considered to result from increased necrosis and stress-induced angiogenesis, respectively.

Targeted contrast agents

Pham *et al* [21] have reported on the use of macromolecular contrast medium-enhanced MRI to monitor the effects of anti-VEGF antibody in MDA-MB-435 human breast cancer cells implanted into nude rats. The anti-VEGF antibody was shown to reduce MRI-assessed microvascular permeability.

A novel approach using a novel synthetic protected graft copolymer as a vascular probe in MCF-7 human breast cancer cell line and MCF-7 cells transfected with the

cDNA for the VEGF165 isoform (MV165) in nude mice has been reported [22]. The protected graft copolymer agent showed enhanced vascular fraction in the transfected cell line, which was confirmed on histology, showing the potential of this approach to image angiogenesis specifically.

Sipkins *et al* [23] report a further experimental approach to imaging a specific angiogenic marker, a paramagnetic contrast agent that was targeted to endothelial $\alpha V\beta 3$ via the LM609 monoclonal antibody, in a rabbit model. This provided high-resolution imaging of rabbit carcinoma.

Assessing response to treatment

Little has been published on assessing response to treatment of breast cancer using dynamic contrast-enhanced methods. Preliminary reports have shown that K^{trans} provides an early measure of response to primary medical therapy, with responding tumours showing a reduction in the range of K^{trans} and a reduction in median K^{trans} . Non-responding tumours predominantly showed an increasing range of K^{trans} values; in well-perfused tissues this reflected changes in the microvascular permeability [24]. These techniques have also been employed in a phase 1 clinical trial of a VEGF inhibitor [25], in which tumours that exhibited stasis showed a reduction in K^{trans} .

Conclusion

MRI provides powerful methods for investigating vascular changes associated with neoangiogenesis. These are already gaining currency in diagnosis, and are now being evaluated with regard to their ability to assess tumour response to treatment. Clinical comparisons with histopathology have shown that rapid enhancement is associated with microvascular density. Also, animal studies and one clinical study have demonstrated an association between VEGF and model parameters such as K^{trans} and k_{ep} , reflecting the increased permeability of neo-vasculature. In one clinical study benign and malignant lesions with similar distributions of MVD on histology could not be distinguished on the basis of contrast enhancement, although the amplitude, but not the rate, of contrast enhancement correlated with MVD. A further study using the technique of echo-planar imaging also showed no correlation with MVD.

Although the weight of evidence indicates that correlations between MRI and histological measures of vasculature can be obtained, there is clearly some variation. This is likely to be due to the considerable variation in the MRI approaches used during the development phase of this new application, and emphasizes the need for standardization in MRI measurement and analysis. It is likely that new contrast agents and improvements in measurement and analytic methods will further extend the utility of MRI in investigating the vascular dependence of tumour growth and the activity of vascular-directed therapies.

References

Articles of particular interest have been highlighted as:

- of special interest
- of outstanding interest

1. Folkman J: **The role of angiogenesis in tumor growth.** *Semin Cancer Biol* 1992, **3**:65–71.
This paper provides a description of the significance of angiogenesis in tumour evolution.
2. Weidner N: **Current pathologic methods for measuring intra-tumoral microvessel density within breast carcinoma and other solid tumors.** *Breast Cancer Res Treat* 1995, **36**: 169–180.
Methods of identifying intratumoral vessels and techniques for counting these in pathological samples are reviewed.
3. Rankin SC: **MRI of the breast.** *Br J Radiol* 2000, **73**:806–818.
• Methods and applications of MRI in evaluating breast cancer are reviewed.
4. Kuhl CK: **MRI of breast tumors.** *Eur Radiol* 2000, **10**:46–58.
• This paper reviews methods and applications of MRI in evaluating breast cancer.
5. Orel SG: **MR imaging of the breast.** *Radiol Clin North Am* 2000, **38**:899–913.
• Reviews methods and applications of MRI in evaluating breast cancer.
6. Brown J, Buckley D, Coulthard A, Dixon AK, Dixon JM, Easton DF, Eeles RA, Evans DG, Gilbert FG, Graves M, Hayes C, Jenkins JP, Jones AP, Keevil SF, Leach MO, Liney GP, Moss SM, Padhani AR, Parker GJ, Pointon LJ, Ponder BA, Redpath TW, Sloane JP, Turnbull LW, Walker LG, Warren RM: **Magnetic resonance imaging screening in women at genetic risk of breast cancer: imaging and analysis protocol for the UK multicentre study.** *Magn Reson Imaging* 2000, **18**:765–776.
• This paper describes the combined use of MRI dynamic imaging with dynamic and morphological analysis, using a numerical weighting scheme, to diagnose lesions in a screening context.
7. Parker GJ, Suckling J, Tanner SF, Padhani AR, Revell PB, Husband JE, Leach MO: **Probing tumor microvasculature by measurement, analysis and display of contrast agent uptake kinetics.** *J Magn Reson Imaging* 1997, **7**:564–574.
• This paper demonstrates the use of quantitative imaging techniques and model fitting of dynamic MRI data to derive parameters that describe contrast agent vascular transfer, generating colour-coded maps of these parameters.
8. Tofts PS, Brix G, Buckley DL, Evelhoch JL, Henderson E, Knopp MV, Larsson HB, Lee TY, Mayr NA, Parker GJ, Port RE, Taylor J, Weisskoff RM: **Estimating kinetic parameters from dynamic contrast-enhanced T(1)-weighted MRI of a diffusible tracer: standardized quantities and symbols.** *J Magn Reson Imaging* 1999, **10**:223–232.
• A standardized framework for model fitting that is applicable to a range of diseases, including cancer, is provided.
9. Parker GJM, Suckling J, Tanner SF, Padhani AR, Husband JE, Leach MO: **MR IW: parametric analysis software for contrast-enhanced dynamic MR imaging in cancer.** *Radiographics* 1998, **8**:497–506.
10. Buckley DL, Drew PJ, Mussurakis S, Monson JR, Horsman A: **Microvessel density of invasive breast cancer assessed by dynamic Gd-DTPA enhanced MRI.** *J Magn Reson Imaging* 1997, **7**:461–464.
11. Buadu LD, Murakami J, Murayama S, Hashiguchi N, Sakai S, Masuda K, Toyoshima S, Kuroki S, Ohno S: **Breast lesions: correlation of contrast medium enhancement patterns on MR images with histopathologic findings and tumor angiogenesis.** *Radiology* 1996, **200**:639–649.

12. Frouge C, Guinebretiere JM, Contesso G, Di Paola R, Blery M: **Correlation between contrast enhancement in dynamic magnetic resonance imaging of the breast and tumor angiogenesis.** *Invest Radiol* 1994, **29**:1043–1049.
13. Furuta A, Ishibashi T, Takahashi S, Yamada S, Ohuchi N, Amano G, Goto K, Watanabe M: **Magnetic resonance imaging of breast cancer: correlation between contrast enhancement and tumor angiogenesis.** *Nippon Igaku Hoshasen Gakkai Zasshi* 1999, **59**:682–688.
14. Stomper PC, Winston JS, Herman S, Klippenstein DL, Arredondo MA, Blumenson LE: **Angiogenesis and dynamic MR imaging gadolinium enhancement of malignant and benign breast lesions.** *Breast Cancer Res Treat* 1997, **45**:39–46.
15. Knopp MV, Weiss E, Sinn HP, Mattern J, Junkermann H, Radeleff J, Magener A, Brix G, Delorme S, Zuna I, van Kaick G: **Pathologic basis of contrast enhancement in breast tumors.** *J Magn Reson Imaging* 1999, **10**:260–266.
 This study correlates quantitative measures of contrast agent vascular transfer based on model fitting, with histopathological measures of VEGF levels and MVD, in patients with breast cancer.
16. Hulka CA, Edmister WB, Smith BL, Tan L, Sgroi DC, Campbell T, Kopans DB, Weisskoff RM: **Dynamic echo-planar imaging of the breast: experience in diagnosing breast carcinoma and correlation with tumor angiogenesis.** *Radiology* 1997, **205**:837–842.
17. Gilles R, Zafrani B, Guinebretiere JM, Meunier M, Lucidarme O, Tardivon AA, Rochard F, Vanel D, Neuenschwander S, Arriagada R: **Ductal carcinoma in situ: MR imaging-histopathologic correlation.** *Radiology* 1995, **196**:415–419.
18. Degani H, Gusic V, Weinstein D, Fields S, Strano S: **Mapping pathophysiological features of breast tumors by MRI at high spatial resolution.** *Nature Med* 1997, **3**:780–782.
 This paper describes application of high-resolution imaging and limited time course analysis to assess tumour heterogeneity.
19. Furman-Haran E, Margalit R, Grobgedl D, Degani H: **Dynamic contrast-enhanced magnetic resonance imaging reveals stress-induced angiogenesis in MCF7 human breast tumors.** *Proc Natl Acad Sci USA* 1996, **93**:6247–6251.
 In the MCF7 tumour model, this study correlates quantitative measures of contrast agent vascular transfer based on model fitting with histopathological measurement of MVD, showing evidence for stress-induced angiogenesis.
20. Furman-Haran E, Grobgedl D, Margalit R, Degani H: **Response of MCF7 human breast cancer to tamoxifen: evaluation by the three-time-point, contrast-enhanced magnetic resonance imaging method.** *Clin Cancer Res* 1998, **4**:2299–2304.
21. Pham CD, Roberts TP, van Bruggen N, Melnyk O, Mann J, Ferrara N, Cohen RL, Brasch RC: **Magnetic resonance imaging detects suppression of tumor vascular permeability after administration of antibody to vascular endothelial growth factor.** *Cancer Invest* 1998, **16**:225–230.
22. Lewin M, Bredow S, Sergeyev N, Marecos E, Bogdanov AJ, Weissleder R: **In vivo assessment of vascular endothelial growth factor-induced angiogenesis.** *Int J Cancer* 1999, **83**:798–802.
23. Sipkins DA, Cheresch DA, Kazemi MR, Nevin LM, Bednarski MD, Li KC: **Detection of tumor angiogenesis in vivo by alphaVbeta3-targeted magnetic resonance imaging.** *Nature Med* 1998, **4**:623–626.
24. Padhani AR, Hayes C, Assersohn L, Powles T, Leach MO, Husband JE: **Response of breast carcinoma to chemotherapy: MR permeability changes using histogram analysis.** In: *Proceedings of the Eighth International Society of Magnetic Resonance in Medicine, April 3–7 2000, Denver.* Berkeley: ISMRM; 2000:2160.
25. Padhani AR, O'Donnell A, Hayes C, Judson I, Workman P, Hannah A, Leach MO, Husband JE: **Changes in tumour vascular permeability with antiangiogenesis therapy: observations on histogram analysis.** In: *Proceedings of the Eighth International Society of Magnetic Resonance in Medicine, April 3–7 2000, Denver.* Berkeley: ISMRM; 2000:108.