

From the State Veterinary Serum Laboratory, Copenhagen, Denmark.

MYCOPLASMA DISPAR AS A CAUSATIVE AGENT IN PNEUMONIA OF CALVES

By

N. F. Friis

FRIIS, N. F.: *Mycoplasma dispar* as a causative agent in pneumonia of calves. Acta vet. scand. 1980, 21, 34—42. — Three field strains of *Mycoplasma dispar* were inoculated, by aerosol inhalation, into a total of eight naturally-born, colostrum-deprived calves. All three strains produced macroscopic pneumonia, each in one calf. Histopathologically an exudative bronchitis accompanied by moderate interstitial cell proliferations was found.

Reisolation studies indicated that the entire respiratory tract is the natural habitat of *Mycoplasma dispar*, which apparently does not spread via the blood stream.

bovine pneumonia; *Mycoplasma dispar*.

Mycoplasma dispar (*M. dispar*) was described as a separate species in 1970 by *Gourlay & Leach*. Since then it has been found associated with calf pneumonia in various countries (*Gourlay et al.* 1970, *St. George et al.* 1973, *Ose & Muenster* 1975, *Bitsch et al.* 1976, *Kuniyasu et al.* 1977). Most of the authors found that the frequency with which pneumonic lungs yielded this mycoplasma was about 50 %. Also macroscopically normal lungs have been found to harbor *M. dispar* (*Thomas & Smith* 1972).

The significance of *M. dispar* in the pneumonia complex of young cattle is still obscure. However, the observations of *St. George et al.*, who in groups of calves found subclinical pneumonia associated with the presence of *M. dispar*, indicate a possible pathogenic capacity of this organism. Further, experimental induction of pneumonia in gnotobiotic calves has been achieved by *Howard et al.* (1976) with *M. dispar*, both in pure culture and in combination with ureaplasmas.

As *M. dispar* is very common in calf pneumonia in this country (*Bitsch et al.*) it was found worth-while to examine its pathogenicity also for naturally born calves. The result is given in the present paper.

MATERIAL AND METHODS

Experimental animals

The animals were colostrum-deprived male calves of the Jersey breed originating from two small farms where no respiratory disorders were detectable. They were brought to the institute immediately after birth and kept in isolation. They were brought through their critical first 14 days in the way described by *Friis & Pedersen* (1979).

Experimental mycoplasmas

Three strains of *M. dispar*: Mk223, Mk355 and Mk548, were used. They were recovered from pneumonic calf lungs sent to the institute for routine diagnostic purposes. After isolation the strains were passed through a membrane filter (Gelman, TCM, pore size 0.45 μm) and cloned once on solid medium. They were used for inoculation in the 7th to 10th passage, which represented a 10^{17} - to 10^{25} -fold dilution of the original material. By the conventional DGI test using rabbit hyperimmune antiserum for the type strain (NCTC 10125) of *M. dispar* all three strains were identified as typical strains of this species. No cross reaction was noted with antiserum for a representative strain, Md26, of the variant serogroup of *M. dispar* (*Friis* 1978). The medium described by *Bitsch et al.* (1976) was used.

Experimental procedure

The three strains of *M. dispar* (Mk223, Mk355, Mk548) were inoculated each into two calves about three weeks old, which were necropsied 22 days later (Experiment I). Moreover, two of the strains (Mk223, Mk355) were inoculated each into one calf about three months old, which was necropsied 34 days later (Experiment II). About 20 ml of culture containing at least 10^8 color-changing units per ml was applied as an aerosol for inhalation via a 10-liter reservoir. Several pre- and postinoculation swabs from the nasal and the preputial cavities were examined for mycoplasmas (for media, see *Bitsch et al.*). Preinoculation blood samples and samples drawn at necropsy were examined for antibodies against *M. dispar* by Meyling's indirect hemagglutination test (*Mandrup et al.* 1975). During the experimental period rectal temperatures were recorded three times a week.

For necropsy the animals were anesthetized with Mebumal i.v. and bled to death from a brachial artery. In Experiment I the following organs were gross-examined and cultivated for mycoplasmas: lung, trachea, larynx, pharynx, nasal cavity, conjunctival sac, olfactory bulb, cerebrum, pleural, pericardial and peritoneal cavity, liver, spleen, right stifle and right hock joint, preputial cavity and urethra. In Experiment II just the nasal cavities and the lungs were examined. Aerobic bacteriologic examination on ordinary blood plates was made from most of the sites mentioned. In cases of gross consolidation of the lungs samples were also examined for anaerobic bacteria, virus* and chlamydia (Friis & Pedersen 1979). Histopathologic examination was performed on the lungs and the nasal mucosa of each calf. At least six different lung areas were examined in each animal. Staining was made with hemalum-eosin and after van Gieson. Consolidated lung tissue of Calf V was examined by an indirect immunofluorescence technique. Cryostat sections on glass slides were fixed in acetone for 10 min and stained by the method described by Rosendal & Black (1972) for staining of mycoplasma colonies on agar.

RESULTS

Three out of eight calves (III, V, VII) displayed macroscopic pneumonic lesions at necropsy (Table 1). Two of them were inoculated at about three weeks of age and necropsied 22 days later. The third one was inoculated when three months old and necropsied 34 days later. Each of the three strains of *M. dispar* which had been used was found to have induced pneumonia in one calf. No clinical signs of disease were noted in any of the eight calves after inoculation, and no significant rise in temperature was recorded.

The lesions (Diagram 1) noted in Calf III consisted of two small, dark red areas each affecting about 1 cm² of the costal surface of the right apical lobe. Both were found to extend through the tissue to the mediastinal surface. In Calf V eight lesions were found scattered in the apical lobes, the cardiac lobes and the right diaphragmatic lobe. They were dark red and varied in size from 1 to 10 cm². Most of them involved both the costal

* For the virological and bacteriological examinations the author is indebted to Dr. V. Bitsch, Dr. P. Høgh and Dr. H. V. Krogh, all of this institute.

Table 1. Results of inoculation experiments with three strains of *Mycoplasma dispar* on colostrum-deprived male Jersey calves.

Exp.	Strain	Calf	Age in days at inoculation	Gross lesions	Reisolation* of <i>M. dispar</i> from											
					lung						other sites**					
					normal area		consolidated area		pharynx	larynx	trachea	nasal cavity	olfactory bulb	cerebrum	other sites**	
a	c	d	a	c	d	a	c	d	a	c	d	a	c	d		
I	Mk355	I	223	43	0	7	8	5	4	8	8	7	4	1	0	
		II	18	40	0	3	5	4	2	7	8	4	0	0	0	
	Mk355	III	15	37	+(a)	nd	7	5	3	nd	nd	7	2	2	0	
		IV	18	40	0	6	9	5	6	8	nd	7	1	0	0	
	Mk548	V	28	50	+(a,c,d)	5	5	5	6	6	5	3	6	7	2	1
		VI	25	47	0	4	4	3	4	8	8	5	0	0	0	
II	Mk223	VII	92	126	+(d)	2	5	5	7	nd	nd	4	nd	nd		
	Mk355	VIII	73	107	0	3	6	7	nd	nd	nd	6	nd	nd		

a,c,d = apical, cardiac, diaphragmatic lobe.

* log color-changing units as estimated per 0.2 ml 10 % tissue homogenate.

** conjunctival sac, pleural, pericardial and peritoneal cavity, liver, spleen, stifle and hock joint, preputial cavity, urethra.

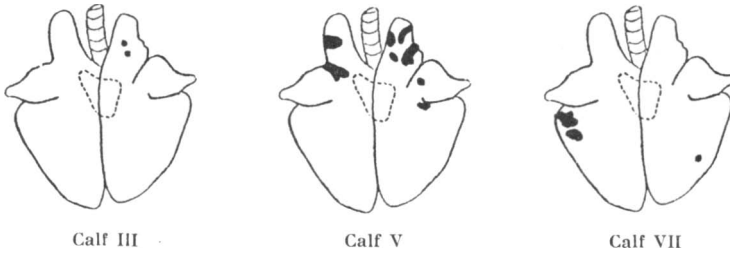


Diagram 1. Distribution of gross lesions in the lungs of three experimental calves infected with different field strains of *Mycoplasma dispar*.

and the mediastinal surfaces. In Calf VII two dark red lesions each measuring about 8 cm² were found cranio-ventrally in the left diaphragmatic lobe. They involved both the costal and the mediastinal surfaces. Further, a small lesion involving only the costal surface was located in the right diaphragmatic lobe.

Histopathologic examination of the diseased lung tissue showed distinct lesions in the bronchi and bronchioli (Fig. 1).

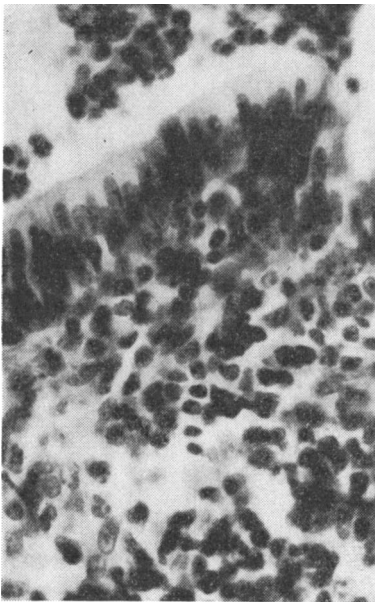


Figure 1. Small bronchus of experimental Calf VII with exudate in the lumen (top) and lympho-histiocytic cell proliferations in the peribronchial tissue. Linear magnification 550 ×.

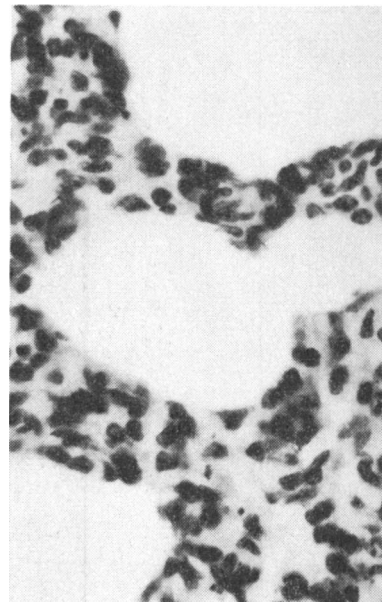


Figure 2. Lung parenchyma of experimental Calf VII with emphysema and interstitial proliferations. Linear magnification 550 ×.

Often the lumen was filled with exudate containing granulocytes, probably neutrophils, and debris of such. Further, lympho-histiocytic cell proliferations were found in the propria mucosae and also in the peribronchial tissue. No defects of the epithelial lining were noted. The changes found in the parenchyma were dominated by atelectasis and emphysema, and by thickening of the alveolar walls from infiltration with mononuclear cells (Fig. 2). In small areas of the affected tissue small numbers of cells, mainly mononuclear, were found lying free in the alveolar lumina. In the five animals without macroscopic lesions the lung tissue showed minor lympho-histiocytic cell proliferations related to the bronchi, and a moderate thickening of alveolar walls in some areas. Immunofluorescent staining (Fig. 3) of the lung lesions in Calf V revealed distinct, luminous particles in the bronchial lumen. Some of them were lining the bronchial epithelium, others were mixed with the exudate. Little fluorescence was noted in bronchi without inflammation and in the parenchyma. In the lamina propria of the nasal mucosa of most of the animals lympho-histiocytic proliferations were noted.

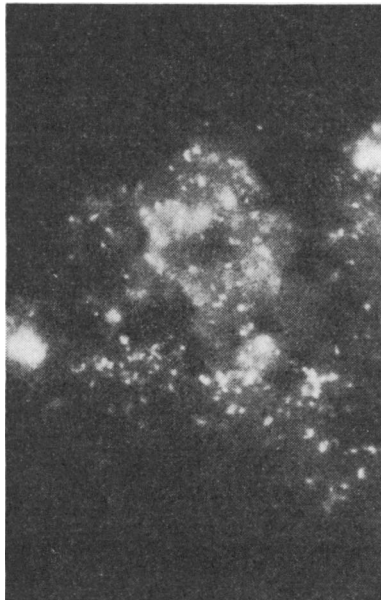


Figure 3. Part of small bronchus of experimental Calf V showing specific immunofluorescence related to epithelial lining and exudate. Lumen at the top. Linear magnification 550 \times .

M. dispar was reisolated from all parts of the respiratory tract of all eight calves, irrespective of the presence or non-presence of pneumonia. The number of organisms in lung tissue of animals without lesions was often high. Outside the respiratory tract *M. dispar* was found only in the brain.

The pre- and postinoculation swabs showed the presence of a ureaplasma in the preputial and nasal cavities of Calf IV and in the preputial cavity of Calf V. On examination of the two calves post mortem, ureaplasmas were recovered from the same sites, and in the case of Calf IV also from the pharynx and larynx. Apart from this no members of the order Mycoplasmatales other than *M. dispar* were isolated either from the swabs or post mortem.

The general microbiologic examination of consolidated lung tissue revealed a not readily identifiable corynebacterium in Calf III. Apart from this, neither aerobic or anaerobic bacteria, nor virus or chlamydiae could be demonstrated in any of the three calves displaying lung lesions.

On serological examination by the indirect hemagglutination test, neither the pre- nor the postinoculation serum samples of the calves were found to contain antibodies against *M. dispar* in serum dilution 1/20 or higher. A rabbit hyperimmune antiserum for *M. dispar* was found positive in dilution 1/40,000.

DISCUSSION

Three Danish field strains of *M. dispar* were inoculated into a total of eight naturally-born, colostrum-deprived calves by aerosol inhalation, i.e. by a "natural" route of infection. Since the three strains induced consolidation of lung tissue in one calf each, it appears that *M. dispar* possesses a certain degree of pathogenicity for the young bovine. Histopathologically the lesions appeared in all three cases as an exudative catarrhal-purulent inflammation of the bronchi/bronchioli with lympho-histiocytic cell proliferations related to the bronchial wall. Moreover, parenchymatous changes characterized by atelectasis, emphysema and interstitial cell proliferations were noted.

Production of pneumonia with *M. dispar* has been described earlier by *Howard et al.* (1976) who inoculated three gnotobiotic calves intrabronchially and found pneumonia in all of them. The histopathologic lesions described by these authors correspond very well with those observed in the present work.

On microbiologic screening of the pneumonic tissue *M. dispar* was the only finding in two of the calves (V, VII) which suggests that it is the cause of the lesions. This notion was further corroborated by the specific luminescence of diseased bronchi after immunofluorescent staining. In Calf III it cannot be excluded that the presence of other organisms have contributed to the development of the lesions. However, against this hypothesis stands the histopathologic picture, which was indistinguishable from that seen in the other two animals.

Some of the calves (I, IV, VIII) showed a remarkably high reisolation titer of *M. dispar* without having pneumonia. The high titers of reisolation of *M. dispar* from the respiratory tract of all animals post mortem, held together with its consistent occurrence in this tract, support the view that the entire respiratory tract should be regarded as the natural habitat of *M. dispar*. Apart from an irregular occurrence in brain tissue *M. dispar* was not found outside the respiratory tract. On the assumption that the invasion of the brain had taken place via the olfactory nerves, as has also been suggested in the cases of *Mycoplasma suis* pneumoniae and *Mycoplasma flocculare* (Friis 1974), it seems that *M. dispar* has little tendency to metastasize hematogeneously.

By the disc growth inhibition test all three strains of *M. dispar* used in the present study were found related to the type strain of the species without cross reaction to the variant serogroup (Friis 1978). It still remains to be examined whether the variant serogroup has a differing pattern of pathogenicity.

REFERENCES

- Bitsch, V., N. F. Friis & H. V. Krogh: A microbiological study of pneumonic calf lungs. *Acta vet. scand.* 1976, 17, 32—42.
- Friis, N. F.: *Mycoplasma suis* pneumoniae and *Mycoplasma flocculare* in comparative pathogenicity studies. *Acta vet. scand.* 1974, 15, 507—518.
- Friis, N. F.: Heterogeneity of *Mycoplasma dispar*. *Acta vet. scand.* 1978, 19, 407—412.
- Friis, N. F. & K. B. Pedersen: Isolation of *Mycoplasma bovoculi* from cases of infectious bovine keratoconjunctivitis. *Acta vet. scand.* 1979, 20, 51—59.
- Gourlay, R. N. & R. H. Leach: A new mycoplasma species isolated from pneumonic lungs of calves (*Mycoplasma dispar* sp. nov.). *J. med. Microbiol.* 1970, 3, 111—123.

- Gourlay, R. N., A. Mackenzie & J. E. Cooper:* Studies of the microbiology and pathology of pneumonic lungs of calves. *J. comp. Path.* 1970, 80, 575—584.
- Howard, C. J., R. N. Gourlay, L. H. Thomas & E. J. Stott:* Induction of pneumonia in gnotobiotic calves following inoculation of *Mycoplasma dispar* and ureaplasmas (T-mycoplasmas). *Res. vet. Sci.* 1976, 21, 227—231.
- Kuniyasu, C., Y. Yoshida, H. Ueda, H. Sugawara & Y. Ito:* Isolation of *Mycoplasma dispar* from pneumonic calf lungs in Japan. *Nat. Inst. Anim. Hlth Quart.* 1977, 17, 75—76.
- Mandrup, M., N. F. Friis, A. Meyling & J. H. Meding:* Studies on the possible occurrence of mycoplasmas in boar semen. *Nord. Vet.-Med.* 1975, 27, 557—561.
- Ose, E. E. & O. A. Muenster:* Isolation of *Mycoplasma dispar* from cattle in the United States. *Vet. Rec.* 1975, 97, 97.
- Rosendal, S. & F. T. Black:* Direct and indirect immunofluorescence of unfixed and fixed mycoplasma colonies. *Acta path. microbiol. scand. Section B* 1972, 80, 615—622.
- St. George, T. D., Nicola Horsfall & N. D. Sullivan:* A subclinical pneumonia of calves associated with *Mycoplasma dispar*. *Aust. vet. J.* 1973, 49, 580—586.
- Thomas, L. H. & G. S. Smith:* Distribution of mycoplasmas in the non-pneumonic bovine respiratory tract. *J. comp. Path.* 1972, 82, 1—4.

SAMMENDRAG

Mycoplasma dispar som årsag til pneumoni hos kalve.

Tre nysisolerede stammer af *Mycoplasma dispar* blev brugt til podningsforsøg på ialt 8 kalve, som straks efter fødselen blev isoleret og opdrættet uden brug af kolostrum. Podningen blev foretaget ved inhalation af mykoplasmer i aerosol.

Ved obduktionen fandtes for hver af de 3 stammers vedkommende 1 kalv med makroskopiske tegn på pneumoni. De histopatologiske forandringer var domineret af en eksudativ bronkitis ledsaget af moderate interstitielle celleproliferationer.

For alle 8 kalves vedkommende viste hyppigheden med hvilken reisolationsforsøgene lykkedes, at såvel øvre som nedre luftveje må anses for det naturlige habitat for *Mycoplasma dispar*, samt at denne mykoplasmaart ikke synes at spredes i organismen via blodbanerne.

(Received May 28, 1979).

Reprints may be requested from: N. F. Friis, the State Veterinary Serum Laboratory, Bülowsvej 27, DK-1870 Copenhagen V, Denmark.