

Case report

Open Access

## An unusual foreign body migrating through time and tissues

Basile N Landis\* and Roland Giger

Address: Service d'ORL et de Chirurgie cervico-faciale, Hôpitaux Universitaires de Genève, Switzerland

Email: Basile N Landis\* - Basile.Landis@hcuge.ch; Roland Giger - Roland.Giger@hcuge.ch

\* Corresponding author

Published: 11 September 2006

Received: 13 February 2006

Head & Face Medicine 2006, 2:30 doi:10.1186/1746-160X-2-30

Accepted: 11 September 2006

This article is available from: <http://www.head-face-med.com/content/2/1/30>

© 2006 Landis and Giger; licensee BioMed Central Ltd.

This is an Open Access article distributed under the terms of the Creative Commons Attribution License (<http://creativecommons.org/licenses/by/2.0>), which permits unrestricted use, distribution, and reproduction in any medium, provided the original work is properly cited.

### Abstract

**Background:** Beside infections, foreign body incidences are amongst the most frequently encountered pathologies in pediatric otolaryngology. While inhaled foreign bodies represent an acute emergency, symptoms of ingested foreign bodies sometimes appear with some delay. Typically fishbones tend to go unnoticed in a first examination and become symptomatic by fever, odynodysphagia and torticollis. Exceptionally, foreign bodies migrate and become manifest with a considerable delay.

**Case report:** We present a case of a young girl who presented with an unusual foreign body which migrated through the cervical tissues causing repeated cervical tumescence's before being diagnosed.

**Conclusion:** Repeated cervical abscesses or tumescence's in children or young patients should alert the treating physician to seek for an underlying pathology such as unnoticed foreign bodies or malformations (e.g. cysts). Further the scarce literature on these migrating foreign bodies is discussed.

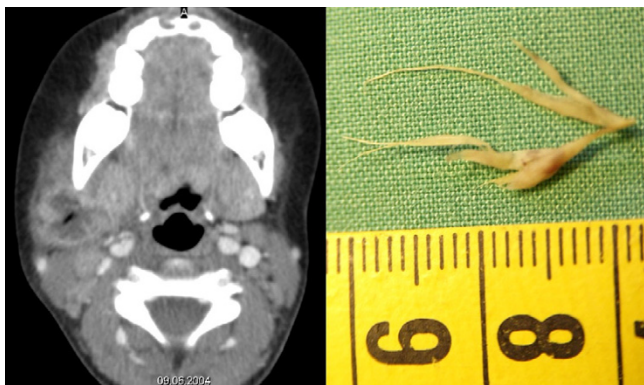
### Background

The most frequent ingested foreign bodies in the Ear Nose and Throat sphere are chicken and fish bones [1]. The symptoms are immediate and patients quickly seek for medical help after a few unsuccessful trials to extract the foreign body by themselves. Beside the tonsils, the base of the tongue and the upper esophagus are the places where usually the impacted foreign bodies are found [1]. Their removal is essential to prevent super-infections, abscesses and perforations with potentially life threatening mediastinal complications in case of esophageal foreign bodies [2]. Although rarely, foreign bodies sometimes migrate within the tissues and become symptomatic after a certain time lapse [3]. In those cases, the direct relation between the suspected foreign body ingestion and the first symp-

toms is rarely established due to the latency and unusual clinical presentation [4,5].

### Case report

We report the case of a 4-year old girl who was admitted to our ENT outpatient clinic with a cervical neck mass without other signs and symptoms. The patient's history revealed, that she had previously been treated several times for odynophagia with cervical tumescence within the last two months. Symptoms and swelling disappeared temporally after the antibiotic treatments. However, the cervical mass rapidly reappeared after the end of the treatment. Otolaryngological examination showed no particularity, beside a firm lateral cervical mass. A cervical CT scan (Fig 1a) revealed a deep subcutaneous collection, suggesting the presence of a cervical abscess. Potential



**Figure 1**  
a: Computed tomography (CT) of the cervical abscess. b: Extracted foreign body. A grass blade of 2 cm of length.

infectious origins such as the tonsils, the salivary glands, teeth or the facial skin were calm. Despite an intravenous antibiotic treatment with decrease of the cervical mass, an ultrasound control 10 days later showed a persistent subcutaneous liquid collection. We then opted for incision and drainage of this collection. The drainage and cleaning of the abscess cavity unearthed a blade of grass within the purulent discharge (Fig 1b).

Reviewing the patients history, the parents suddenly recalled she had complained of a transitory foreign body feeling during several days after chewing a blade of grass two months ago. Follow-up showed no further recurrence of the neck swelling.

## Discussion

Ingested foreign bodies (FB) in children vary in shape and size, whereas coins, nonmetallic sharp objects and other blunt objects seem to be the favorite items (for a detailed overview see [6]). A majority of ingested FB pass through the gastrointestinal tract uneventfully. Severe complications are rare and often associated with delayed discovery due to silent and protracted clinical manifestations such as new onset asthma, excessive salivation or recurrent upper respiratory infections [3]. These undetected FB tend to create fistulas to the surrounding structures (e.g. aorta, bronchia, etc.) leading to potential life-threatening situations [3]. In contrast to adults, where symptoms and information on the swallowed object facilitates the diagnostic and therapeutic approach, children often present with few or absent symptoms and absence of symptoms does not preclude the presence of a FB [6]. However the detection of a foreign body and the follow-up of the clinical course is crucial, especially since complications even sometimes occur after it has been extracted [7].

Impacted foreign bodies within the ENT sphere, typically fish bones, have been reported to cause upper respiratory airway tract abscesses [8]. However, the migration through the entire pharyngeal wall ending in a superficial cervical abscess several months later is uncommon but has to be considered [1,5,9,10]. Repeated abscesses which seem resistant to treatment should always evoke the possibility of a foreign body or an underlying congenital malformation such as branchial cleft cysts [8], even if radiological examination fails to evidence its presence. While FB migration has been reported in adults [1,9], the present case reports this rare complication in a child. Particularly, the FB's nature – a grass blade – seems uncommon, even amongst adult reports [9]. Even though a glass blade is not solid or hard, depending on the ingestion angle, it can exhibit a considerable sharpness. In the present case this might have facilitated the initial tissue penetration.

Similar to foreign bodies in the ear [11] or nose [12], ingested FB in children are prone to lead to chronic and delayed symptoms [3]. Thus the possibility of a ingested foreign body should always been considered even when initial investigations where negative.

## References

- Chee LW, Sethi DS: **Diagnostic and therapeutic approach to migrating foreign bodies.** *Ann Otol Rhinol Laryngol* 1999, **108**:177-180.
- Brinster CJ, Singhal S, Lee L, Marshall MB, Kaiser LR, Kucharczuk JC: **Evolving options in the management of esophageal perforation.** *Ann Thorac Surg* 2004, **77**:1475-1483.
- Gilchrist BF, Valerie EP, Nguyen M, Coren C, Klotz D, Ramenofsky ML: **Pearls and perils in the management of prolonged, peculiar, penetrating esophageal foreign bodies in children.** *J Pediatr Surg* 1997, **32**:1429-1431.
- Tsunoda K, Sakai Y, Watanabe T, Suzuki Y: **Pseudo vocal paralysis caused by a fish bone.** *Lancet* 2002, **360**:907.
- Barzilai G, Braverman I, Karmeli R, Greenberg E: **How did it get there? A coiled metal foreign body in an unusual cervical position.** *Otolaryngol Head Neck Surg* 2001, **124**:590-591.
- Cheng W, Tam PK: **Foreign-body ingestion in children: experience with 1,265 cases.** *J Pediatr Surg* 1999, **34**:1472-1476.
- Wadie GM, Konefal SH, Dias MA, McLaughlin MR: **Cervical spondylodiscitis from an ingested pin: a case report.** *J Pediatr Surg* 2005, **40**:593-596.
- Nusbaum AO, Som PM, Rothschild MA, Shugar JM: **Recurrence of a deep neck infection: a clinical indication of an underlying**

Publish with **BioMed Central** and every scientist can read your work free of charge

"BioMed Central will be the most significant development for disseminating the results of biomedical research in our lifetime."

Sir Paul Nurse, Cancer Research UK

Your research papers will be:

- available free of charge to the entire biomedical community
- peer reviewed and published immediately upon acceptance
- cited in PubMed and archived on PubMed Central
- yours — you keep the copyright

Submit your manuscript here:  
[http://www.biomedcentral.com/info/publishing\\_adv.asp](http://www.biomedcentral.com/info/publishing_adv.asp)



- congenital lesion.** *Arch Otolaryngol Head Neck Surg* 1999, **125**:1379-1382.
9. Gertner R, Bar'el E, Fradis M, Podoshin L: **Unusual complication of an ingested foreign body.** *J Laryngol Otol* 1991, **105**:146-147.
  10. Kumar BN, Walsh RM, Courteney-Harris RG: **Laryngeal foreign body: an unusual complication of percutaneous tracheostomy.** *J Laryngol Otol* 1997, **111**:652-653.
  11. Jegoux F, Legent F, Beauvillain de Montreuil C: **Chronic cough and ear wax.** *Lancet* 2002, **360**:618.
  12. Botma M, Bader R, Kubba H: **'A parent's kiss': evaluating an unusual method for removing nasal foreign bodies in children.** *J Laryngol Otol* 2000, **114**:598-600.

Publish with **BioMed Central** and every scientist can read your work free of charge

*"BioMed Central will be the most significant development for disseminating the results of biomedical research in our lifetime."*

Sir Paul Nurse, Cancer Research UK

Your research papers will be:

- available free of charge to the entire biomedical community
- peer reviewed and published immediately upon acceptance
- cited in PubMed and archived on PubMed Central
- yours — you keep the copyright

Submit your manuscript here:  
[http://www.biomedcentral.com/info/publishing\\_adv.asp](http://www.biomedcentral.com/info/publishing_adv.asp)

